

**SEMMELWEIS EGYETEM  
DOKTORI ISKOLA**

**Ph.D. értekezések**

**3065.**

**NGUYEN TIN DAT**

**Klinikai és kísérletes angiológiai kutatások  
című program**

Programvezető: Dr. Sótonyi Péter, egyetemi tanár

Témavezető: Dr. Dósa Edit, egyetemi docens

# **THE EFFECTIVENESS OF INVASIVE THERAPY OF STENO-OCCLUSIVE LESIONS OF THE INTERNAL CAROTID ARTERY AND POPLITEAL ARTERY**

**Ph.D. Thesis**

**Dat Tin Nguyen, M.D.**

Károly Rácz Doctoral School of Clinical Medicine  
Semmelweis University



Supervisor: Edit Dósa, M.D., Ph.D.

Official Reviewers: Arnold Tóth, M.D., Ph.D.

Attila Doros, M.D., Ph.D.

Head of the Complex Examination Committee:

László Entz, M.D., Ph.D.

Members of the Complex Examination Committee:

Zoltán Járai, M.D., Ph.D.

Ákos Pál Deák, M.D., Ph.D.

Budapest

2024

2

## Table of contents

List of abbreviations	5
1. Introduction	6
1.1. Internal carotid artery stenosis	6
1.1.1. Incidence, etiology, risk factors, and symptoms	6
1.1.2. Diagnosis	7
1.1.3. Treatment	8
1.1.3.1. Best medical treatment	8
1.1.3.2. Open surgical reconstruction	8
1.1.3.3. Endovascular intervention	9
1.1.3.4. Invasive treatment-related early complications	10
1.1.3.4.1. Possible early complications of open surgical reconstructions	10
1.1.3.4.2. Possible early complications of endovascular interventions	10
1.1.3.5. Invasive treatment-related late complications	11
1.2. Popliteal artery steno-occlusive disease	12
1.2.1. Incidence, etiology, risk factors, and symptoms	12
1.2.2. Diagnosis	13
1.2.3. Treatment	14
1.2.3.1. Best medical treatment	14
1.2.3.2. Open surgical reconstruction	14
1.2.3.3. Endovascular intervention	14
1.2.3.4. Possible early complications of endovascular interventions	15
1.2.3.5. Possible late complications of endovascular interventions	15
2. Objectives	
2.1. Study I (Restenosis rates in patients with ipsilateral carotid endarterectomy and contralateral carotid artery stenting)	17
2.2. Study II (Short- and mid-term outcomes of stenting in patients with isolated distal internal carotid artery stenosis or post-surgical restenosis)	17
2.3. Study III (Mid-term results and predictors of restenosis in patients undergoing endovascular therapy for isolated popliteal artery steno-occlusive disease)	17
3. Methods	19

3.1. Study I (Restenosis rates in patients with ipsilateral carotid endarterectomy and contralateral carotid artery stenting)	19
3.1.1. Study design	19
3.1.2. Procedure characteristics	19
3.1.3. Follow-up visits	20
3.1.4. Evaluated parameters and their definitions	20
3.1.5. Statistical analysis	21
3.2. Study II (Short- and mid-term outcomes of stenting in patients with isolated distal internal carotid artery stenosis or post-surgical restenosis)	21
3.2.1. Study design	21
3.2.2. Procedure characteristics	22
3.2.3. Follow-up visits	22
3.2.4. Evaluated parameters and their definitions	22
3.2.5. Statistical analysis	23
3.3. Study III (Mid-term results and predictors of restenosis in patients undergoing endovascular therapy for isolated popliteal artery steno-occlusive disease)	23
3.3.1. Study design	23
3.3.2. Procedure characteristics	24
3.3.3. Follow-up visits	24
3.3.4. Evaluated parameters and their definitions	25
3.3.5. Statistical analysis	25
4. Results	27
4.1. Study I (Restenosis rates in patients with ipsilateral carotid endarterectomy and contralateral carotid artery stenting)	27
4.1.1. Patient data	27
4.1.2. Lesion characteristics	27
4.1.3. Procedures	29
4.1.4. Early ( $\leq 30$ days) post-procedural period	31
4.1.5. Follow-up	31
4.2. Study II (Short- and mid-term outcomes of stenting in patients with isolated distal internal carotid artery stenosis or post-surgical restenosis)	34
4.2.1. Patient data	34

4.2.2. Lesion characteristics	36
4.2.3. Procedure data	36
4.2.4. Early ( $\leq 30$ days) post-procedural period	38
4.2.5. Follow-up	39
4.3. Study III (Mid-term results and predictors of restenosis in patients undergoing endovascular therapy for isolated popliteal artery steno-occlusive disease)	42
4.3.1. Patient data	42
4.3.2. Lesion, balloon, and stent characteristics	44
4.3.3. Early ( $\leq 30$ days) post-procedural period	46
4.3.4. Follow-up	46
4.3.5. Predictors of restenosis	50
5. Discussion	53
5.1. Study I (Restenosis rates in patients with ipsilateral carotid endarterectomy and contralateral carotid artery stenting)	53
5.2. Study II (Short- and mid-term outcomes of stenting in patients with isolated distal internal carotid artery stenosis or post-surgical restenosis)	55
5.3. Study III (Mid-term results and predictors of restenosis in patients undergoing endovascular therapy for isolated popliteal artery steno-occlusive disease)	59
6. Conclusions	62
6.1. Study I (Restenosis rates in patients with ipsilateral carotid endarterectomy and contralateral carotid artery stenting)	62
6.2. Study II (Short- and mid-term outcomes of stenting in patients with isolated distal internal carotid artery stenosis or post-surgical restenosis)	62
6.3. Study III (Mid-term results and predictors of restenosis in patients undergoing endovascular therapy for isolated popliteal artery steno-occlusive disease)	62
7. Summary	63
8. References	64
9. Bibliography of the candidate's publications	85
10. Acknowledgements	89

## List of abbreviations

<b>ABI:</b>	ankle-brachial index
<b>AS:</b>	atherosclerotic
<b>BMI:</b>	body mass index
<b>CAS:</b>	carotid artery stenting
<b>CCA:</b>	common carotid artery
<b>CEA:</b>	carotid endarterectomy
<b>CI:</b>	confidence interval
<b>CKD:</b>	chronic kidney disease
<b>CTA:</b>	computed tomography angiography
<b>DM:</b>	diabetes mellitus
<b>DSA:</b>	digital subtraction angiography
<b>FMD:</b>	fibromuscular dysplasia
<b>GSM:</b>	gray-scale median
<b>HR:</b>	hazard ratio
<b>ICA:</b>	internal carotid artery
<b>IQR:</b>	interquartile range
<b>ISR:</b>	in-stent restenosis
<b>LDL:</b>	low-density lipoprotein
<b>LEAD:</b>	lower extremity arterial disease
<b>MRA:</b>	magnetic resonance angiography
<b>PA:</b>	popliteal artery
<b>PSV:</b>	peak systolic velocity
<b>PTA:</b>	percutaneous transluminal angioplasty
<b>RES:</b>	restenotic
<b>SF:</b>	stent fracture
<b>TASC:</b>	TransAtlantic Inter-Society Consensus
<b>TIA:</b>	transient ischemic attack
<b>US:</b>	ultrasound
<b>VSMC:</b>	vascular smooth muscle cell

## 1. Introduction

Diseases resulting from arterial stenoses/occlusions continue to be associated with high rates of disability and are among the leading causes of death worldwide. (1) This dissertation addresses the short- and mid- or long-term effectiveness of invasive treatment of steno-occlusive lesions of both the internal carotid artery (ICA) and popliteal artery (PA) and the factors influencing it.

### 1.1. Internal carotid artery stenosis

#### 1.1.1. Incidence, etiology, risk factors, and symptoms

There are about 1.4 million new ischemic strokes in Europe each year, (2) of which approximately 10% are related to extracranial ICA stenoses. (3, 4) Luminal narrowing of the carotid artery >50% occurs in around 2% of the European population. (2)

Internal carotid artery stenoses can be caused by external compression, such as hyoid bone or chemodectoma. (5, 6) However, in most patients, luminal narrowing is due to pathological changes in the vessel wall. In the majority of cases, atherosclerosis is responsible for the development of ICA stenoses. (7) Atherosclerosis consists of complex pathophysiological alterations originating from the intimal layer. The formation of atherosclerotic lesions is based on endothelial dysfunction leading to vasoconstriction, lipid infiltration, leukocyte adhesion, and platelet activation in regions, especially in bifurcations, where turbulent flow generates low or oscillating shear stress. (7, 8) The early phase of the atherosclerotic process is characterized by the appearance of fatty streaks. Fatty streaks contain foam cells, which are in fact macrophages that have taken up oxidized low-density lipoprotein (LDL) particles trapped in the subendothelial space. (9) The presence of plaques consisting of a necrotic core and a fibrous cap indicates a more advanced stage of atherosclerosis. (8, 9) Another feature of a more advanced atherosclerosis is the occurrence of calcium deposits in the plaques triggered by matrix vesicles released from macrophages and vascular smooth muscle cells (VSMCs). (8, 9) It should be noted that low shear stress also causes positive remodelling and an increase in vessel diameter to compensate for the decrease in the luminal diameter, but this process only provokes further plaque growth. (10) Plaques with a large, cell-free, lipid-rich necrotic core, a thin fibrous cap, microcalcifications,

and inflammatory cells are “vulnerable” (“unstable”), as they are prone to rupture, fragmentation, and consequent local thrombosis and/or distal embolization. (11) In contrast, carotid plaques with extensive calcification are less likely to rupture and are therefore considered “stable”. (12)

Other etiologies of ICA stenosis include restenosis, which can be early (occurring within about 2 years after invasive treatment) or late (so-called “neoatherosclerosis”, occurring beyond 2 years after invasive treatment), (13, 14) cervical radiation-induced arteriopathy, (15) fibromuscular dysplasia (FMD), (16) and large-vessel vasculitis (Takayasu's arteritis and Horton's disease). (17) Atherosclerotic and restenotic lesions are mostly located in the bifurcation and origin of the ICA, whereas FMD mainly affects the distal part of the ICA, and arteritis affects the common carotid artery (CCA). The localization of radiation-induced arteriopathy can be highly variable. (7, 15–17)

Several risk factors for atherosclerosis, such as male sex, age, obesity, sedentary lifestyle, smoking, hypertension, hyperglycemia, and dyslipidemia have been identified through the Framingham Heart Study. (18)

Not all patients with carotid artery stenosis develop symptoms. Among the symptoms, which may be transient or persistent, ipsilateral amaurosis fugax, chronic ocular ischemia, aphasia, and contralateral hemiparesis/hemiplegia deserve mention. Impaired hemodynamic function of the brain and/or downstream microembolization from vulnerable plaques may be responsible for the symptoms. (19)

### 1.1.2. Diagnosis

Auscultation has a low sensitivity for the detection of carotid artery stenoses >50% and does not provide information on the exact location and grade of the stenoses or the morphology of the plaques, therefore imaging techniques must be used. (20) The primary imaging modality for extracranial carotid arteries is ultrasound (US). The high spatial resolution and standardized velocity parameters allow low-cost and radiation-free characterization of the vessel wall and plaques, as well as grading of stenoses in the cervical segment, with the trade-off that the evaluation of the lumen is limited in heavily calcified lesions. (21) Computed tomography angiography (CTA) can visualize the anatomy of the arteries from the aortic arch to the intracranial vasculature, which is essential for planning invasive procedures. Its drawbacks include the potential for



iodine contrast nephrotoxicity and radiation exposure. (22) Contrast-enhanced magnetic resonance angiography (MRA) serves a similar purpose to CTA, but has limited ability to assess calcification and, like CTA, can only be used in exceptional cases in patients with chronic kidney disease (CKD). (22, 23) An alternative to CTA and contrast-enhanced MRA can be non-contrast MRA, of which several variants already exist. (24, 25) Digital subtraction angiography (DSA) is practically no longer used to confirm ICA stenoses. Current guidelines recommend a combination of two different imaging methods to safely determine the extent and severity of carotid artery stenoses. (2)

### 1.1.3. Treatment

In addition to cardiovascular risk factor management and statin and antiplatelet therapy, invasive treatment is the basis for reducing the risk of stroke in patients with significant ICA stenosis. (2) Invasive therapy is considered for asymptomatic patients with  $\geq 60\%$  ICA stenosis and for symptomatic patients with  $\geq 50\%$  ICA stenosis. (2) In the last decade, however, a less aggressive approach to invasiveness has evolved, particularly in asymptomatic patients. (26)

#### 1.1.3.1. Best medical treatment

The management of classic atherosclerotic risk factors means, among other things, optimizing body weight, prioritizing a Mediterranean-type diet, exercising, avoiding smoking, blood pressure-lowering treatment (ideal blood pressure in patients under 65 years of age: 120–129/70–79 mm Hg; ideal blood pressure in patients over 65 years of age: 130–139/70–79 mm Hg), glycemic control, and statin therapy (with or without elevated serum LDL-cholesterol). (2) Low-dose aspirin (100 mg/day) is recommended for asymptomatic patients with significant ICA stenosis ( $\geq 70\%$ ), and clopidogrel (75 mg/day) in case of aspirin intolerance. (2) Symptomatic patients with ICA stenosis ( $\geq 50\%$ ) require at least 21 days of dual antiplatelet therapy followed by clopidogrel monotherapy if the patient cannot receive invasive treatment for any reason. (2)

#### 1.1.3.2. Open surgical reconstruction

Surgery remains the gold standard in patients with significant ICA stenosis who are symptomatic or asymptomatic but at an average surgical risk. (2) Several techniques

have been described for the surgical treatment of significant carotid artery stenosis since it was first performed by Michael E. DeBakey in 1953 and published by Eastcott et al. in 1954. (27) The most common are vertical arteriotomy (with primary closure or patch angioplasty) and oblique transection followed by eversion with or without the use of a shunt. (28) In our institute, eversion endarterectomy is preferred under general anesthesia or, rarely, under locoregional anesthesia. During endarterectomy, plaques are removed from the ICA, the bifurcation, and the distal third of the CCA, along with the intima and part of the media. (28)

#### 1.1.3.3. Endovascular intervention

Antegrade ICA stenting was first described in 1989. (29) Initially, there was great enthusiasm for the method, but randomized controlled trials, which also included data from centers without sufficient experience, reported worse periprocedural results than open surgery. (30) Thanks to these trials, the number of ICA stentings has significantly decreased and in the last few years they have been used mainly in cases of high-surgical risk, unfavorable anatomical conditions from the point of view of open surgery (e.g., low or high carotid bifurcation and distal ICA stenosis), contralateral CCA and/or ICA occlusion, radiation-induced arteriopathy, or post-surgical restenosis. (2) However, the number of carotid artery stentings (CASs) is expected to rise again, as the recently published Second Asymptomatic Carotid Surgery Trial showed that serious complications are similarly uncommon after competent stenting and open surgery, and the long-term effects of these two carotid artery procedures on fatal or disabling stroke are comparable. (31)

Antegrade stenting of the ICA is performed under local anesthesia with self-expanding bare metal stents or, occasionally, with covered stents, mostly through femoral or radial access. The intervention can take place without embolic protection or with embolic protection. In the case of the latter, distal (filter or occlusion balloon) and proximal (occlusion balloon) types can be distinguished. (2) In our institute, a filter is most often used as protection against embolism.

#### 1.1.3.4. Invasive treatment-related early complications

Post-procedural complications can be divided into early ( $\leq 30$  days) and late ( $> 30$  days) types.

##### 1.1.3.4.1. Possible early complications of open surgical reconstructions

Insufficient hemostasis of the incision site can lead to the formation of a wound hematoma; this usually occurs within the first 6 hours after surgery. (2, 32) The preparation of the carotid artery can cause injury to the adjacent cranial nerves in 4.9% of cases, the most common being damage to the vagus (X), facial (VII), hypoglossal (XII), and glossopharyngeal nerves (IX). (2, 33, 34) New ischemic brain lesions, whether silent or symptomatic, may develop as a result of hemodynamic factors (e.g., carotid artery clamping), distal embolization of plaque material after restoration of blood flow, or thrombosis of the ICA; their incidence is about 7%. (2) Hemodynamic instability is also a common complication, which can manifest as hypotension (due to loss of the dampening effect of removed plaques on baroreceptors) or hypertension (due to general anesthesia or denervation of the carotid bulb). (2) The most serious complication of untreated hypertension that develops in approximately 1% of patients in the first 12 hours is hyperperfusion syndrome, which presents as headache, confusion, seizures, hypertension, nausea, vomiting, and loss of consciousness. It can also lead to intracerebral bleeding. Causes of hyperperfusion syndrome include vasogenic edema due to impairment of autoregulation, as well as baroreceptor and blood-brain barrier dysfunction. (2, 35, 36)

##### 1.1.3.4.2. Possible early complications of endovascular interventions

Endovascular therapy can cause both systemic (e.g., allergic reactions) and local complications. (37) Insufficient closure of the access site may result in hematoma or pseudoaneurysm development. (38) Rapid and large extravasation can lead to retroperitoneal hematoma after femoral artery puncture or limb-threatening compartment syndrome after brachial artery puncture. (39) Other complications related to the access site include arteriovenous-fistula and occlusion of the punctured artery. Intraluminal maneuvering with the devices can cause vessel wall injury and, in patients with diffuse atherosclerosis, plaque fragmentation, local thrombus formation, and/or

distal embolization. The consequence of the latter can be a stroke. (40) Stroke can be expected primarily in patients with type III aortic arch, bovine arch, severe aortic atherosclerosis, tortuous carotid artery, and long or tandem carotid lesions. (2) Hemodynamic instability is also an important periprocedural complication. Hypotension, bradycardia, and even temporary asystole may occur during the intervention. (2) As with open surgical reconstruction, hyperperfusion syndrome is a real risk, affecting 3% of patients undergoing CAS. (2, 41)

#### 1.1.3.5. Invasive treatment-related late complications

In about 1% of cases, an average of 3 months after open surgical reconstruction, infection of the patch or graft can occur, mostly by *Staphylococcus aureus* and *Staphylococcus epidermidis* colonies. (2) Restenosis is the most common late complication of invasive carotid artery procedures, which may require reintervention. (42) Early recurrent luminal narrowing is caused by local thrombus formation, remodelling, and intimal hyperplasia. (43) In the first weeks after intimal and medial injury, due to the interaction of subintimal tissue factors and circulating platelets, local thrombus formation dominates as the cause of recurrent luminal narrowing. In addition, after invasive procedures, the antiproliferative function of endothelial cells also decreases as a result of apoptosis or denudation of the inner surface of the arterial wall. (44) Consequently, VSMCs change to a de-differentiated phenotype with increased extracellular matrix production, migration, and proliferation, causing mostly intimal and medial hyperplasia, reaching a maximum within 8 weeks and then showing a slight decrease after 6 months. (45) Vessel wall inflammation and leukocyte infiltration also play a major role in extracellular matrix formation and VSMC proliferation. (45) Restenosis that appears years after invasive treatment is called “neoatherosclerosis”, which is similar to atherosclerosis in terms of its morphology and other characteristics, with the difference that it develops faster than an ordinary atherosclerotic lesion due to incomplete or damaged endothelization. (14) Recurrence of atherosclerotic plaques in the treated ICA can lead to a late ipsilateral ischemic cerebral event. However, ischemic brain lesions may be due not only to restenosis, but also to the progression of stenosis of the ipsilateral supra-aortic trunks or to other (e.g., cardiac) causes. (2)

According to the results of large randomized clinical trials, it can be clearly stated, that regarding long-term outcomes, there is no significant difference between carotid endarterectomy (CEA) and CAS in the incidence of ipsilateral stroke. (2, 33) However, literature data on restenosis are quite contradictory: while randomized clinical trials have shown that CAS has a higher rate of restenosis, (33, 46) observational studies have noted that CEA has a higher rate of restenosis. (47–49)

## 1.2. Popliteal artery steno-occlusive disease

### 1.2.1. Incidence, etiology, risk factors, and symptoms

Lower extremity arterial disease (LEAD) affects approximately 40 million people in Europe; prevalence increases with age. Patients with untreated LEAD have increased rates of amputation and mortality. (50) Isolated PA stenosis/occlusion is rare, occurring in only about 1% of all LEADs. (51)

Similar to ICA stenoses, the background of PA steno-occlusive disease is usually the atherosclerotic process, but entrapment syndrome, FMD, or cystic adventitial disease can also lead to isolated PA stenosis/occlusion. (52, 53)

The risk factors of popliteal atherosclerosis are practically identical to the risk factors listed in connection with carotid artery stenosis (see subsection 1.1.1.).

Roughly 20–50% of LEAD patients are asymptomatic. (54) In the case of poor collateralization, insufficient blood flow causes sural intermittent claudication, rest pain, and in severe cases non-healing ulcers and gangrene. Symptoms can be categorized using the Rutherford and Fontaine classification. (55) (Table 1)

**Table 1. Rutherford and Fontaine classification of chronic peripheral artery disease (55)**

<b>Rutherford category</b>	<b>Fontaine stage</b>	<b>Clinical presentation</b>
<i>0</i>	<i>I</i>	No symptoms
<i>1</i>	<i>IIa</i>	Claudication: mild (>200 m)
<i>2</i>	<i>IIb</i>	Claudication: moderate
<i>3</i>	<i>IIb</i>	Claudication: severe
<i>4</i>	<i>III</i>	Ischemic rest pain
<i>5</i>	<i>IV</i>	Tissue loss: minor
<i>6</i>	<i>IV</i>	Tissue loss: major

### 1.2.2. Diagnosis

Diagnostic workup includes palpation of peripheral pulses and measurement of ankle-brachial or toe-brachial index. In LEAD, peripheral pulses are weak or absent distal to the stenosis/occlusion. An ankle-brachial index (ABI) value of <0.90 and >1.40 and a toe-brachial index value of <0.70 is considered pathological. (50) The pencil probe Doppler blood flow detector can reveal sounds characteristic of tardus-parvus-like flow in the arteries below the knee. (50) Duplex US provides additional information on the location, morphology, and severity of steno-occlusive disease, however, alone it is usually not sufficient to comprehensively map the vascular anatomy and plan invasive treatment. (50) Computed tomography angiography is often the first-line imaging modality with extensive calcification and low spatial resolution (especially in the below-knee region), being the main limitation in assessing lesions. (50) A new, non-contrast quiescent-interval single-shot MRA technique is gaining ground in daily clinical practice, but this method also does not have the best diagnostic value in terms of evaluating calcification and the stented segments; (56) furthermore, the benefits of this technique have not yet been proven in randomized controlled trials. However, digital subtraction angiography with iodinated or (in CKD) CO<sub>2</sub> contrast from a puncture of the radial artery or other artery is still performed today because of the excellent visibility of the arteries below the knee. (57)

### 1.2.3. Treatment

#### 1.2.3.1. Best medical treatment

Conservative therapy consists of exercise training, modification of cardiovascular risk factors (see subsection 1.1.3.1.), and statin and antiplatelet therapy. (50) In patients with intermittent claudication, exercise training can significantly improve walking distance by 50–200%. (50) Statin therapy targeting serum LDL-cholesterol <1.8 mmol/L also has beneficial effects on cardiovascular events and all-cause mortality, even in asymptomatic patients. (50) Current evidence supports the efficacy of antiplatelet therapy only in symptomatic patients. (50) Dual antiplatelet therapy is justified only after endovascular interventions for at least 1 month. (50) In patients without heart failure, the use of cilostazol should also be considered. (50) Invasive therapy can be recommended to the patient if exercise training does not bring sufficient results or the symptoms significantly affect the quality of life. (50)

#### 1.2.3.2. Open surgical reconstruction

Open surgical reconstruction is indicated for TransAtlantic Inter-Society Consensus (TASC) type D lesions in patients with a life expectancy greater than 2 years and an average surgical risk. (50) (TASC type D lesion: chronic occlusion of the PA and trifurcation arteries >25 cm in length.) (55) For short PA stenoses/occlusions, the following open surgical options exist: conventional or eversion endarterectomy with direct suture or patch angioplasty, interposition grafting, or popliteal bypass grafting. (58–60)

#### 1.2.3.3. Endovascular intervention

Endovascular intervention is performed in patients with TASC type A–C lesions and high-surgical risk TASC type D lesions. (50) Several techniques have been described for endovascular procedures from contralateral retrograde femoral or ipsilateral antegrade femoral, or ipsilateral retrograde (dorsal pedal, distal posterior tibial, anterior tibial, or peroneal) access. (61) Dedicated guidewires can be used to attempt intraluminal crossing of chronic total occlusions through their microchannels. (62) If the intraluminal crossing fails, subintimal recanalization should be done. (62) Return from the subintimal space to the true lumen is often difficult, however, there are many

methods and devices to facilitate this (e.g., SAFARI technique, RENDEZVOUS technique, and GoBack catheter). (62–64) Plain balloon angioplasty is usually not sufficient as a stand-alone treatment; in the case of a high-grade residual stenosis or flow-limiting dissection, implantation of self-expanding stents becomes inevitable. (65) Plain balloon angioplasty is even less likely to provide satisfactory morphological results in patients with heavily calcified PA lesions. Intraluminal lithotripsy and atherectomy devices offer great options for plaque debulking. (66, 67) Drug-coated technology is also spreading and shows good short- and mid-term patency rates in the femoropopliteal artery segment. (68)

#### 1.2.3.4. Possible early complications of endovascular interventions

Adverse events related to the access site and device manipulation have already been discussed in subsection 1.1.3.4.2. Distal embolization and resulting acute ischemia occur in approximately 1–2% of lower extremity interventions and require endovascular or open surgical embolectomy in the vast majority of cases. (69, 70)

#### 1.2.3.5. Possible late complications of endovascular interventions

The two most important late complications are restenosis and stent fracture (SF). (71, 72) The pathophysiology of PA restenosis, which includes local thrombus formation, remodelling, intimal hyperplasia, and “neoatherosclerosis”, is analogous to that of ICA restenosis. Due to its location, among the arteries of the lower extremity, the femoropopliteal segment is the most deformed by biomechanical forces (torsion, axial compression, and bending) during movement. (73) Loss of elasticity of the vessel after stent implantation reduces axial compressibility, resulting in kinking at the ends of the stents during knee flexion. (74) Excessive kinking leads to microtrauma, intimal injury, restenosis, and consequent loss of patency. (74–76) Increased biomechanical forces also contribute to the development of SF, but there is conflicting evidence regarding the extent to which SF plays a role in inducing restenosis. (77–80) Of the five types of SF, (81) (Table 2) only complex type III–V fractures are likely to be associated with an extra risk of restenosis. (77)



**Table 2. Types of stent fracture (80)**

<b>Type</b>	<b>Fluoroscopic appearance</b>
<i>I</i>	Fracture of one strut
<i>II</i>	Focal fracture of multiple struts
<i>III</i>	Complete fracture of the stent with preserved alignment
<i>IV</i>	Complete fracture of the stent with malalignment
<i>V</i>	Trans-axial spiral fracture of the stent

## 2. Objectives

2.1. Study I (Restenosis rates in patients with ipsilateral carotid endarterectomy and contralateral carotid artery stenting – Institutional Review Board Approval No. 222/2017)

Because there are two ICAs, it is possible to evaluate the short- and long-term success of CEA and CAS in the same patient (ipsilateral CEA versus contralateral CAS). Since there are few such publications (we found a total of four), with a small sample size (up to 63 subjects), (82–85) we considered it worthwhile to conduct an intra-patient comparison of restenosis on a larger sample size.

2.2. Study II (Short- and mid-term outcomes of stenting in patients with isolated distal internal carotid artery stenosis or post-surgical restenosis – Institutional Review Board Approval No. 222/2017)

Atherosclerosis and restenosis rarely affect the distal part of the ICA. Distal ICA lesions can only be approached with great difficulty through open surgery, either from the retromandibular fossa or in other ways (e.g., mobilization of the parotid gland, double mandibular osteotomy, or mandibular subluxation with styloidectomy). This makes stenting an invasive alternative to open surgery in these patients, even those who are symptomatic. Since there is no available literature data on the short- and mid-term efficacy of stenting in atherosclerotic or post-surgical restenotic distal ICA stenosis, we aimed to provide information on this topic.

2.3. Study III (Mid-term results and predictors of restenosis in patients undergoing endovascular therapy for isolated popliteal artery steno-occlusive disease – Institutional Review Board Approval No. 138/2013)

In the majority of studies, atherosclerotic PA stenosis was defined as isolated if the patient did not have ipsilateral femoral artery stenosis requiring invasive therapy. However, the publications are heterogeneous with respect to the arterial runoff and the type of radiological intervention used. Studies also seem to be inconsistent on the structure of the deployed (mainly self-expanding) stents. Therefore, we aimed to examine the mid-term results of PA endovascular techniques and to identify predictors

of restenosis in a single-center, homogeneous population in terms of arterial runoff and type of stent implanted.

### 3. Methods

3.1. Study I (Restenosis rates in patients with ipsilateral carotid endarterectomy and contralateral carotid artery stenting)

#### 3.1.1. Study design

In this single-center (Heart and Vascular Center, Semmelweis University) retrospective study, 117 consecutive patients who underwent CEA on one side and CAS on the other side between January 2001 and January 2019 were included.

#### 3.1.2. Procedure characteristics

Indications for CEA and CAS were based on international guidelines that were in force at the time of the intervention. (50, 86–88) In general, asymptomatic patients with  $\geq 70\%$  ICA stenosis and symptomatic patients with  $\geq 50\%$  ICA stenosis were treated invasively. (50, 86–88) Following the guidelines, a team of vascular surgeons, interventional radiologists, and angiologists decided on the type of invasive therapy.

The type of open surgery was an eversion endarterectomy without routine shunt use, which was carried out under general anesthesia. The indication for the use of the shunt was at the discretion of the operating surgeon. If the patient had not previously taken platelet aggregation inhibitor drug regularly, antiplatelet therapy was initiated at least 7 days before the procedure and continued indefinitely post-surgically. Technical success was defined as the absence of visible plaque remnants and successful restoration of blood flow at the completion of the endarterectomy. (89)

Antegrade CAS, which meant the deployment of a self-expanding stent, was executed in a standard manner via the common femoral, brachial, or radial artery. Embolic protection systems were routinely used, and postdilation of the stent was inevitable. The puncture sites were treated with a pressure bandage, compressed manually, or sealed with a closure device. If not already administered, patients were premedicated with dual antiplatelet therapy for 5 days before the intervention and up to 3 months after the procedure. If the patient did not have heart disease, monotherapy was sufficient thereafter. Technical success was achieved if no extravasation, dissection, or  $>30\%$  residual stenosis was seen on the final angiographic images. (90)

### 3.1.3. Follow-up visits

The follow-up assessments consisted of interviewing the patient and US examination of the cervical arteries. Carotid US was due 6 weeks, 6 months, and 12 months after the procedure, and then once a year. These dates were changed in the event of symptoms/complaints or contralateral invasive carotid artery treatment. On the operated side, restenosis was considered 50–69% when the peak systolic velocity (PSV) was 210–270 cm/s and  $\geq 70\%$  when the PSV was  $>270$  cm/s, (91) while on the stented side, restenosis was considered 50–69% when the PSV was 225–350 cm/s and  $\geq 70\%$  when the PSV was  $>350$  cm/s. (92)

### 3.1.4. Evaluated parameters and their definitions

Symptoms were categorized as amaurosis fugax, transient ischemic attack (TIA), minor stroke, major stroke, or no symptoms. (89)

Information on the presence and duration of atherosclerotic risk factors (93) and the type and duration of medications was obtained from the medical record archiving system (MedSol; T-Systems Hungary Ltd., Budapest, Hungary) or directly from patients who were contacted by phone.

The grade of stenosis, the length of the lesion, and the severity of plaque calcification were evaluated on reformatted CT/CTA images. The percentage of ICA stenosis was determined according to the North American Symptomatic Carotid Endarterectomy Trial criteria. (94) Lesion length was defined as the distance between the proximal and distal point where the degree of stenosis decreased to 80% of its maximum. (95) In terms of calcification, the following groups were distinguished: absent, mild (thin, discontinuous), moderate (thin, continuous or thick, discontinuous), and severe (thick, continuous). (96) Plaque echogenicity was assessed by computer-assisted quantification of gray-scale median (GSM) values by using Adobe Photoshop software (CS3; Adobe System, San Jose, CA, USA). According to the modified Geroulakos classification, depending on the percentage of pixels in the plaque area with GSM values  $>25$ , the plaques were categorized as type 1: uniformly echolucent ( $<15\%$ ), type 2: predominantly echolucent (15–50%), type 3: predominantly echogenic (51–85%), type 4: uniformly echogenic ( $>85\%$ ), and type 5: indeterminable due to the acoustic shadow. (97)

### 3.1.5. Statistical analysis

Statistical analysis was performed with the software Stata 16.0 (StataCorp. 2019. Stata Statistical Software: Release 16. College Station, TX: StataCorp LLC). The distribution of continuous variables in the two treatment groups was compared with paired *t*-tests, while categorical data were compared with Fisher's exact tests. The probability of being free from restenosis was estimated by the Kaplan–Meier method. Restenosis was considered failure in the analysis, while death and the end of observation were considered censoring. As only one death occurred during the 11-year follow-up, the competing risk problem was not considered. The maximum follow-up time was set at 11 years on both sides. Event-free survival curves were compared by using the log-rank test.

First, the crude hazard ratio (HR) comparing the two procedures was estimated by the Cox proportional hazards model. Then, the prognostic factors that could be related to the indication of the procedures were adjusted stepwise. First, age, symptoms, and lesion characteristics, which were significantly associated with procedures at the  $P \leq 0.20$  level in univariate analysis, were considered. To improve estimation efficiency, potential confounders of the treatment effect were stepwise removed from the initial model, starting with those with the largest *P*-values in the Wald-test. The decision rule for elimination was to remove covariates not significant at the  $P < 0.05$  level if the treatment effect coefficient estimate did not change by more than 10% from the initial model of elimination. Next, the lesion characteristics that were not previously included in the model were added back individually and kept in the model if the adjustment to them changed the treatment effect coefficient by more than 10%. Finally, the length of history of smoking, hypertension, diabetes mellitus (DM), and hyperlipidemia were added to the model and the same process of elimination was done.

## 3.2. Study II (Short- and mid-term outcomes of stenting in patients with isolated distal internal carotid artery stenosis or post-surgical restenosis)

### 3.2.1. Study design

This single-center (Heart and Vascular Center, Semmelweis University) retrospective study analyzed patients (N=66) who underwent stenting for atherosclerotic or post-surgical restenotic isolated distal ICA stenosis between January 2001 and January 2020.

### 3.2.2. Procedure characteristics

The vascular team of our center decided on the necessity of stenting for all patients based on the guidelines of the European Society for Vascular Surgery in force at the time. (50, 86–88) Patients were considered symptomatic if they had any ischemic neurological event (amaurosis fugax, TIA, minor or major stroke) in the ipsilateral carotid territory within 6 months prior to the intervention. (89)

Stenting was performed in the standard manner (2) by three interventional radiologists with more than 10 years of experience, with the implantation of self-expanding stents and embolic protection. If the patient did not receive antiplatelet therapy or only received monotherapy, then 100–300 mg of acetylsalicylic acid and/or 75 mg of clopidogrel per day were started at least 5 days before the procedure. In urgent cases, a loading dose of 250–500 mg of acetylsalicylic acid and/or 300–600 mg of clopidogrel was given. In the absence of cardiological or other indications, the dual antiplatelet therapy was continued for a maximum of 3 months after the intervention, followed by monotherapy for an indefinite period. (50, 86–88) Stenting was technically successful if there was no extravasation, dissection, or >30% residual stenosis on the final DSA images. (89)

### 3.2.3. Follow-up visits

A follow-up check-up was planned for the 6th week, 6th and 12th months after the intervention, and then once a year. However, due to complaints, contralateral invasive carotid artery procedure, or other reasons, these dates may have changed. Follow-up visits consisted of a patient interview and an US examination of the cervical arteries. Restenosis was defined as 50–69% if PSV was 225–350 cm/s inside the stent or at either end of the stent, and  $\geq 70\%$  if PSV was  $>350$  cm/s. (92) If the distal part of the stent was not visible by US, but indirect signs (ICA flow volume  $<159$  mL/min, ICA PSV  $<33$  cm/s, and/or CCA PSV  $<42$  cm/s) suggested  $\geq 70\%$  in-stent restenosis (ISR), (98) the patient was submitted to CTA.

### 3.2.4. Evaluated parameters and their definitions

Cardiovascular risk factors and comorbidities (female sex, age  $\geq 80$  years, hypertension, DM, hyperlipidemia, and CKD), (99) previous invasive vascular therapies, lesion- and

intervention-related parameters, neurological events (amaurosis fugax, TIA, minor or major stroke) before and after stenting, ISR characteristics, and primary patency and mortality rates were assessed. Lesion parameters (localization, grade and length of stenosis, presence and severity of plaque calcification) were determined on pre-procedural CTA images. By localization, the affected side and the distance of the narrowest part of the ICA stenosis from the carotid bifurcation was meant. The grade of stenosis, the length of the lesion, and the severity of plaque calcification were defined as described in subsection 3.1.4. Among the intervention-related parameters, the site of the puncture, the type of the embolic protection device, the manufacturer, diameter, and length of the balloons and stents, and the complications were collected. Regarding the definition of neurological events, reference is made to a guideline. (50, 86–89) Characteristics of ISR included ultrasonographic grade, localization (in-stent, persistent, or both), and pattern (focal or diffuse) of restenotic lesions. In-stent restenosis was considered focal if it was shorter than 10 mm. Primary patency was defined as freedom from  $\geq 50\%$  ISR or occlusion.

### 3.2.5. Statistical analysis

Statistical analyses were performed by using SPSS Statistics for Windows (Version 25.0.; IBM Corp., Armonk, NY, USA) and GraphPad Prism 7.01 (GraphPad Software Inc., La Jolla, CA, USA) software. Continuous data were presented as median and interquartile range (IQR) and compared by using the Mann–Whitney *U* test. Categorical data were expressed as numbers (percentages) and compared by using Fisher's exact test. Kaplan–Meier analysis was performed to determine primary patency and mortality rates. Follow-up was maximized at 48 months. Survival curves were compared by using the log-rank test. All statistical tests were two-tailed. The threshold for statistical significance was  $P \leq 0.05$ .

## 3.3. Study III (Mid-term results and predictors of restenosis in patients undergoing endovascular therapy for isolated popliteal artery steno-occlusive disease)

### 3.3.1. Study design

Sixty-one patients from a single institution (Heart and Vascular Center, Semmelweis University) who had intervention between June 2011 and June 2018 for symptomatic



isolated PA *de novo* steno-occlusive disease (no ipsilateral iliofemoral stenosis and at least two patent crural arteries) were retrospectively analyzed.

### 3.3.2. Procedure characteristics

Endovascular interventions were executed through the femoral artery. The choice of approach (antegrade or retrograde) was left to the discretion of the interventional radiologist performing the procedure. All interventions were carried out by three experienced interventional radiologists with more than 10 years of experience in the treatment of peripheral artery occlusive disease. Patients underwent percutaneous transluminal angioplasty (PTA) or stenting (selective or primary). Selective stenting was defined as the placement of a stent after PTA with suboptimal results (>30% residual stenosis or extensive intimal dissection). Primary stenting was defined as the placement of a stent after predilation of the lesion, irrespective of the PTA outcome. (100) In general, PTA was favored for patients with non-occlusive short lesions, while primary stenting was chosen in patients with heavily calcified long lesions or total occlusions. The punctured arteries were compressed manually. In uncomplicated cases, patients were discharged 1–2 days after the procedure. Patients received dual antiplatelet therapy for 1 month, followed by lifelong acetylsalicylic acid or clopidogrel monotherapy. Technical success was defined as <30% residual stenosis without extravasation or flow-limiting dissection. (101) Clinical success was measured as patient-reported subjective betterment and/or improvement in at least one Rutherford category.

### 3.3.3. Follow-up visits

Patients were followed up at 6 weeks, 6 months, and 12 months after the intervention, and annually thereafter, or sooner if symptoms developed. Follow-up examinations included evaluation of symptoms/complaints (Rutherford stage), (55) palpation of peripheral pulses, measurement of ABI, and US scanning. Significant restenosis was defined as PSV  $\geq$ 250 cm/s in the treated PA segment.

#### 3.3.4. Evaluated parameters and their definitions

Two groups of patients were distinguished according to the type of invasive therapy (PTA versus stenting). Both the PTA and stenting groups were divided into restenotic and non-restenotic subgroups and compared in terms of pre-procedural, imaging, procedural, and post-procedural data. The pre-procedural data were as follows: sex, age, anthropometric parameters (weight and height), atherosclerotic risk factors and comorbidities (smoking, hypertension, DM, hyperlipidemia, and CKD), (99) previous medical history (coronary, supra-aortic, and/or lower extremity endovascular interventions and/or open surgical reconstructions), Rutherford grade, (55) ABI values, and medication regimen. Imaging data included lesion parameters (localization [P1: from the intercondylar fossa to the proximal edge of the patella, P2: from the proximal edge of the patella to the center of the knee joint, P3: from the center of the knee joint to the origin of the anterior tibial artery, and multi-segment disease: the above combination], [102] the grade and length of stenosis, and the presence and severity of plaque calcification). The localization of the lesion and the grade and length of the stenosis were assessed on DSA images, while the plaque calcification was detected on the baseline mask DSA images. Lesions were classified as mildly calcified if single or multiple punctate calcifications were present, moderately calcified if single or multiple linear calcifications were seen, and heavily calcified if continuous calcifications were observed without visible breaks. (103) Rutherford category, (55) ABI values, and US findings were collected as post-procedural data. Primary patency was defined as patent PA without further intervention. Secondary patency was defined as open PA after endovascular reintervention or open surgical reconstruction for restenosis/reocclusion.

#### 3.3.5. Statistical analysis

Statistical analyses were performed by using StatSoft Statistica 13.4 (Moonsoft Oy, Espoo, Finland) and GraphPad Prism 7.01 software. Continuous data were expressed in median and IQR (Q1–Q3), and categorical data were expressed in numbers (percentages). Significant differences between groups/subgroups for continuous and categorical data were evaluated with Mann–Whitney *U* and Fisher's exact tests. Patency was calculated by using Kaplan–Meier analysis. Kaplan–Meier curves were compared by the log-rank test. Significant predictors of restenosis were determined by using Cox

regression analysis; HR was presented with 95% confidence interval (CI). The threshold for statistical significance was  $P \leq 0.05$ .

## 4. Results

### 4.1. Study I (Restenosis rates in patients with ipsilateral carotid endarterectomy and contralateral carotid artery stenting)

#### 4.1.1. Patient data

The study group consisted of 39 women and 78 men (median age at CEA, 64.4 years [IQR, 57.8–72.2 years]; median age at CAS, 68.8 years [IQR, 61–76 years]). Neurological symptoms were significantly more frequent ( $P<0.001$ ) before CEA than before CAS. Except for age  $\geq 80$  years ( $P=0.033$ ), there was no significant difference in the presence of atherosclerotic risk factors/comorbidities at the time of CEA and CAS. The duration of smoking ( $P<0.001$ ), hypertension ( $P<0.001$ ), DM ( $P<0.001$ ), and hyperlipidemia ( $P=0.001$ ) was significantly shorter at the time of CEA than at the time of CAS. (Table 3)

#### 4.1.2. Lesion characteristics

With the exception of one stented stenosis (0.9%) presumably caused by radiotherapy, the other lesions (99.1%) were of atherosclerotic origin. There was no difference in the grade and length of stenosis, however, the majority of lesions (79.5%) in the CAS group were mildly or moderately calcified, compared with a balanced distribution of lesions in the CEA group according to the four categories of calcification. In terms of plaque echogenicity, most lesions in both groups were types 3 and 4, however, there were significantly more types 3 and 4 lesions in the CAS group than in the CEA group. The majority of lesions in both groups were in the bulb; suprabulbar lesions were mostly treated with stenting. (Table 4)

**Table 3. Pre-procedural symptoms and the presence and duration of atherosclerotic risk factors/comorbidities at the time of the intervention**

<b>Patient-related parameters</b>	<b>CEA (N=117)</b>	<b>CAS (N=117)</b>	<b>P- value</b>
<b><i>Pre-procedural symptoms, N (%)</i></b>	49 (41.9)	19 (16.2)	<b>&lt;0.001</b>
Amaurosis fugax, N (%)	3 (2.6)	2 (1.7)	>0.999
TIA, N (%)	27 (23.1)	9 (7.7)	<b>0.002</b>
Minor stroke, N (%)	11 (9.4)	6 (5.1)	0.314
Major stroke, N (%)	8 (6.8)	2 (1.7)	0.102
<b><i>Presence of atherosclerotic risk factors/comorbidities</i></b>			
Age ≥80 years, N (%)	5 (4.3)	15 (12.8)	<b>0.033</b>
Obesity (BMI ≥30 kg/m <sup>2</sup> ), N (%)	18 (15.4)	13 (11.1)	0.335
Smoking, N (%)	80 (68.4)	65 (55.6)	0.059
Hypertension, N (%)	108 (92.3)	109 (93.2)	>0.999
DM, N (%)	44 (37.6)	45 (38.5)	0.896
Hyperlipidemia, N (%)	58 (49.6)	56 (47.9)	>0.999
CKD, N (%)	3 (2.6)	6 (5.1)	0.499
<b><i>Duration of atherosclerotic risk factors/comorbidities</i></b>			
*Smoking (years), mean (SD)	30.2 (22.2)	31.8 (23.4)	<b>&lt;0.001</b>
†Hypertension (years), mean (SD)	10.1 (9.8)	13.4 (9.1)	<b>&lt;0.001</b>
†DM (years), mean (SD)	3.9 (6.9)	5.7 (8.9)	<b>&lt;0.001</b>
†Hyperlipidemia (years), mean (SD)	3.6 (6.6)	5 (7.3)	<b>0.001</b>
†CKD (years), mean (SD)	0.1 (1.2)	0.2 (1.7)	0.107

\*Duration: cumulative period of active smoking before the intervention.

†Duration: period between detection of hypertension, DM, hyperlipidemia, or CKD and intervention.

*BMI*, Body mass index; *CAS*, carotid artery stenting; *CEA*, carotid endarterectomy; *CKD*, chronic kidney disease; *DM*, diabetes mellitus; *SD*, standard deviation; *TIA*, transient ischemic attack.

**Table 4. Lesion characteristics**

<b>Lesion-related parameters</b>	<b>CEA (N=117)</b>	<b>CAS (N=117)</b>	<b>P-value</b>
<b><i>Etiology</i></b>			
Atherosclerosis, N (%)	117 (100)	116 (99.1)	>0.999
Radiation-induced arteriopathy, N (%)	0 (0)	1 (0.9)	>0.999
<b><i>Stenosis grade (%), mean (SD)</i></b>	85.9 (6)	85.8 (6.2)	>0.999
<b><i>Lesion length (mm), mean (SD)</i></b>	10.5 (4.9)	10.2 (4.6)	0.523
<b><i>Calcification</i></b>			
Mild, N (%)	28 (23.9)	63 (53.8)	<b>&lt;0.001</b>
Moderate, N (%)	29 (24.8)	30 (25.6)	>0.999
Heavy, N (%)	30 (25.6)	8 (6.8)	<b>&lt;0.001</b>
<b><i>Echogenicity</i></b>			
Types 1 and 2, N (%)	20 (17.1)	10 (8.5)	0.077
Types 3 and 4, N (%)	62 (53)	82 (70.1)	<b>0.011</b>
Type 5, N (%)	35 (29.9)	25 (21.4)	0.178
<b><i>Location</i></b>			
Bifurcation, N (%)	23 (19.7)	16 (13.7)	0.293
Bulb, N (%)	92 (78.6)	75 (64.1)	<b>0.020</b>
Suprabulbar segment, N (%)	2 (1.7)	26 (22.2)	<b>&lt;0.001</b>

CAS, Carotid artery stenting; CEA, carotid endarterectomy; SD, standard deviation.

#### 4.1.3. Procedures

Carotid endarterectomy was the first invasive therapeutic method in 95 patients. The median time interval between the two procedures was 50 months (IQR, 8.5–102 months) if the first procedure was CEA and 2.5 months (IQR, 1–12.8 months) if the first procedure was CAS. The clamping time during CEA was 22.7±8 minutes. A shunt was placed in four patients (3.4%). For CAS, access sites were femoral in 77 patients (65.8%), radial in 37 patients (31.6%), and brachial in three patients (2.6%). In two cases (1.7%) a proximal Mo.Ma (Medtronic Inc., Minneapolis, MN, USA) was used, while in the other patients (98.3%) a distal embolic protection device (FilterWire EZ; Boston Scientific Corp., Marlborough, MA, USA) was used. Predilation was carried out

in six cases (5.1%). The parameters of the balloons and stents are listed in Table 5. The technical success rate of the patients was 100%.

**Table 5. Parameters of balloons and stents**

<b>Balloons/stents</b>	<b>Manufacturer</b>	<b>Size (mm), diameter (min–max) × length (min–max)</b>
<b><i>Balloons used for predilation (N=6)</i></b>		
Sterling (N=3)	Boston Scientific Corp., Marlborough, MA, USA	3–4 × 15–25
Trek Rx (N=1)	Abbott Vascular Inc., Santa Clara, CA, USA	3.5 × 25
Emerge (N=1)	Boston Scientific Corp.	3.5 × 20
Pantera Pro (N=1)	Biotronik AG, Bülach, Switzerland	3 × 25
<b><i>Stents (N=117)</i></b>		
Wallstent (N=102)	Boston Scientific Corp.	7–9 × 30–50
Exact (N=7)	Abbott Vascular Inc.	7–9 × 30–40
Precise Pro (N=6)	Cordis Corp., Johnson & Johnson Co., Miami, FL, USA	7–8 × 30–40
Cristallo Ideale (N=1)	Invatec S.p.A., Roncadelle, Italy	7 × 40
Roadsaver (N=1)	Terumo Corp., Tokyo, Japan	7 × 30
<b><i>Balloons used for postdilation (N=117)</i></b>		
Sterling (N=53)	Boston Scientific Corp.	4–6 × 20–40
Maverick (N=32)	Boston Scientific Corp.	4–6 × 20
Ultra-Soft SV (N=21)	Boston Scientific Corp.	4–6 × 20–25
Viatrac 14 Plus (N=11)	Abbott Vascular Inc.	4–6 × 20–40

#### 4.1.4. Early ( $\leq 30$ days) post-procedural period

No one died during the early follow-up. The following complications occurred after CEA: four wound hematomas (3.4%), two of which required surgical evacuation, five cranial nerve injuries (4.3%), two cases of hemodynamic instability (1.7%; hypotension, N=1; hypertension, N=1), one myocardial infarction (0.9%), and five neurological ischemic events (4.3%; TIA, N=1; ipsilateral minor stroke, N=1; ipsilateral major stroke, N=3). Two of the five neurological ischemic events were due to acute occlusion of the operated ICA; both patients underwent reoperation.

The following complications were observed after CAS: one post-puncture pseudoaneurysm (0.9%), which was eliminated by thrombin injection, four cases of hemodynamic instability (3.4%; hypotension, N=3; hypertension, N=1), and six ocular or neurological ischemic events (5.1%; amaurosis fugax, N=1; TIA, N=5). One of the six neurological ischemic events was caused by acute stent occlusion; the patient had the stent surgically removed. There was no significant difference ( $P=0.683$  and  $P>0.999$ , respectively) between CEA and CAS in either hemodynamic instability or early post-procedural neurological complications.

#### 4.1.5. Follow-up

Median follow-up was 10 years (IQR, 5.5–14 years) after CEA and 6 years (IQR, 3–10 years) after CAS. One death occurred during the follow-up period. The cause of death was ventricular fibrillation. Ocular or neurological ischemic events corresponding to the operated side were reported in five patients (4.3%; amaurosis fugax, N=1; TIA, N=2; minor stroke, N=2), and neurological symptoms corresponding to the stented side were reported in one patient (0.9%; TIA, N=1). The difference between the two sides was not statistically significant ( $P=0.213$ ).

After CEA, there were eight cases of 50–69% restenosis (6.8%; symptomatic restenosis, N=0), 30 cases of 70–99% restenosis (25.6%; symptomatic restenosis, N=5), and two cases of occlusion (1.7%; symptomatic occlusion, N=0). Of the 30 patients with 70–99% restenosis, 24 patients underwent radiological intervention (Wallstent implantation [N=24]; Boston Scientific Corp., Marlborough, MA, USA), while the other patients remained on best medical treatment. Three patients (2.6%; symptomatic re-



restenosis, N=1) developed 70–99% re-restenosis; radiological reintervention (PTA) was performed in one of these three patients.

After CAS, there were 12 cases of 50–69% restenosis (10.3%; symptomatic restenosis, N=0), five cases of 70–99% restenosis (4.3%; symptomatic restenosis, N=0), and one case of occlusion (0.9%; symptomatic occlusion, N=1). Of the five patients with 70–99% restenosis, four patients underwent radiological reintervention (PTA), while the others remained on best medical treatment. None had 70–99% re-restenosis.

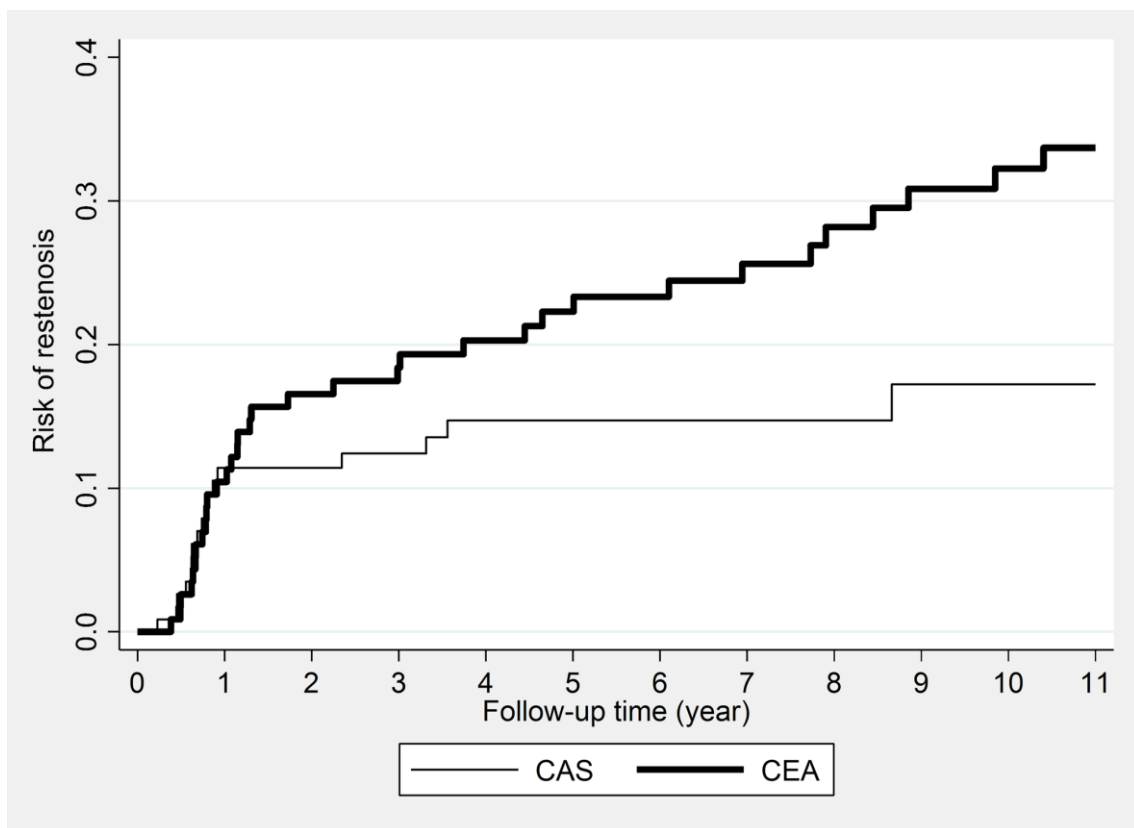
Nine patients developed bilateral restenosis and one of them had bilateral ICA occlusion. The probability of restenosis is displayed in Table 6. The risk of restenosis was the same in the first year after the two procedures, followed by a lower risk throughout the follow-up in the CAS group. (Figure 1) There was a statistically significant difference between the two groups; the P-value of the log-rank test was 0.045. The crude incidence rate of restenosis was 2.5/100 person-years in the CAS group and 4.2/100 person-years in the CEA group, while the crude HR estimated by Cox regression was 1.80 (95% CI, 1.05–3.10; P=0.030). Figure 2 shows the observed and predicted probabilities of being free from restenosis with treatment. The adjusted HR (1.85; 95% CI, 0.95–3.60; P=0.070) differed little from the crude HR. The final model included all important covariates (those that were either significant in the model or whose omission would have changed the effect size by more than 10% [smoking, hypertension, DM, level of calcification and echogenicity, location of lesions, and type of treatment]).

All patients received antiaggregants, 60 of them received long-term dual antiplatelet therapy. Cilostazol therapy was noted in 13 patients (11.1%). Ninety-three patients (79.5%) received statin therapy, 51 of them were on high-intensity therapy. Other lipid-lowering medications (fibrates and ezetimibe) were prescribed to 14 patients (12%).

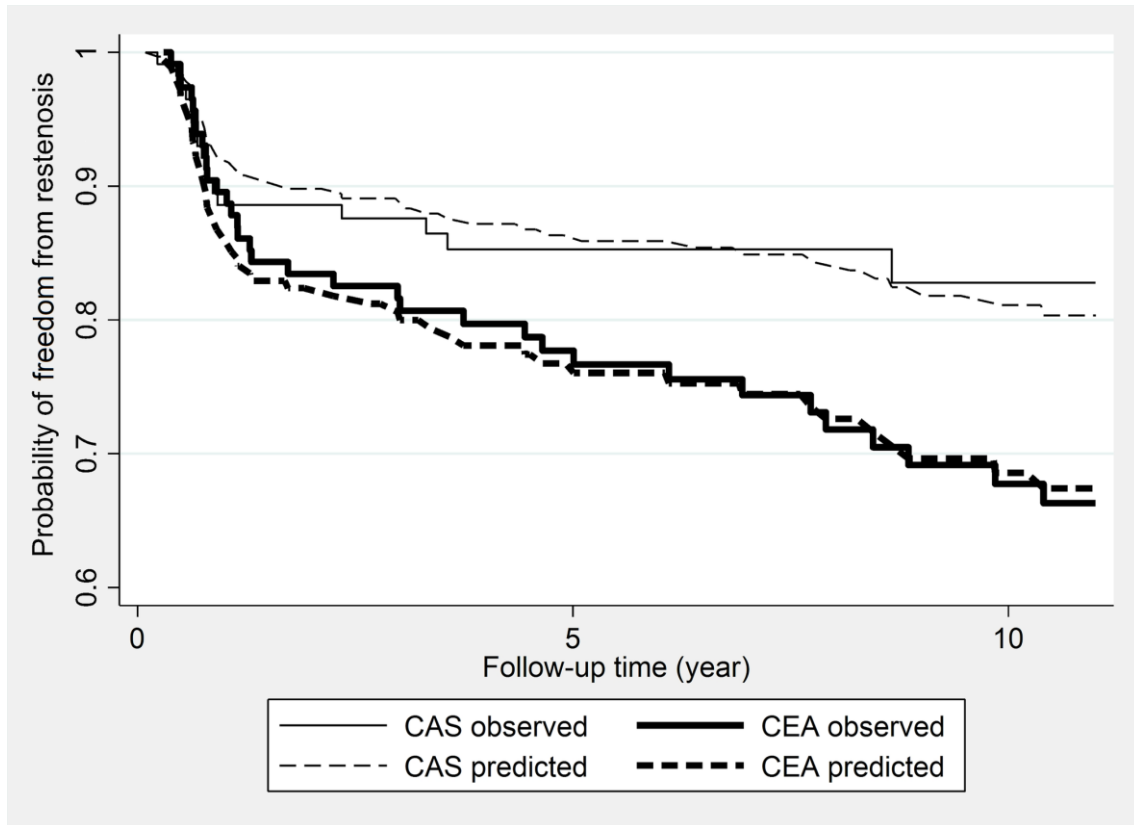
**Table 6. Probability of restenosis**

		1 year	2 years	3 years	5 years	11 years
<i>CEA</i>	%	10.4	16.6	18.4	22.3	33.7
	<i>No. at risk</i>	104	93	89	76	41
	95% <i>CI</i>	6.07– 17.64	10.90– 24.72	12.40– 26.81	15.64– 31.22	25.11– 44.24
<i>CAS</i>	%	11.4	11.4	12.4	14.7	17.2
	<i>No. at risk</i>	101	94	80	62	15
	95% <i>CI</i>	6.79– 18.84	6.79– 18.84	7.54– 20.07	15.64– 31.22	25.11– 44.24

*CAS*, Carotid artery stenting; *CEA*, carotid endarterectomy; *CI*, confidence interval.



**Figure 1. Risk of restenosis by the treatment group** (*CAS*, Carotid artery stenting; *CEA*, carotid endarterectomy.)



**Figure 2. Observed and model-predicted probabilities of freedom from restenosis after treatment** (CAS, Carotid artery stenting; CEA, carotid endarterectomy.)

4.2. Study II (Short- and mid-term outcomes of stenting in patients with isolated distal internal carotid artery stenosis or post-surgical restenosis)

#### 4.2.1. Patient data

The 66 patients (women, N=13; men, N=53) had a median age of 66 years (IQR, 61–73 years). Patients were divided into two etiological groups, atherosclerotic (AS, N=40 [60.6%]; median age, 67 years [IQR, 61–74 years]) and post-surgical restenotic (RES, N=26 [39.4%]; median age, 64.5 years [IQR, 60.5–71 years]). There was no significant difference ( $P=0.541$ ) in median age between the AS and RES groups. Carotid surgery was eversion endarterectomy in all patients. The median time between CEA and CAS was 80 months (IQR, 22–148 months). Nine patients were stented within 48 months of CEA. Patient-related parameters are shown in Table 7. Of the 66 patients, 15 patients (22.7%) had some neurological symptoms before CAS. There was no significant difference ( $P>0.999$ ) between the two groups in terms of pre-procedural neurological

events. In the RES group, there were significantly more women ( $P=0.003$ ) and significantly more patients with hypertension ( $P=0.010$ ), patients who underwent contralateral carotid invasive treatment ( $P=0.015$ ), and patients who had lower extremity arterial reconstruction ( $P=0.046$ ).

**Table 7. Pre-procedural neurological events, cardiovascular risk factors, comorbidities, and previous invasive vascular therapies**

Patient-related parameters	AS group (N=40)	RES group (N=26)	P-value
<b><i>Pre-procedural neurological events, N (%)</i></b>	9 (22.5)	6 (23.1)	>0.999
Amaurosis fugax, N (%)	3 (7.5)	0 (0)	0.273
TIA, N (%)	3 (7.5)	6 (23.1)	0.139
Minor stroke, N (%)	3 (7.5)	0 (0)	0.273
<b><i>Cardiovascular risk factors, comorbidities</i></b>			
Female sex, N (%)	3 (7.5)	10 (38.5)	<b>0.003</b>
Age $\geq 80$ years, N (%)	5 (12.5)	2 (7.7)	0.695
Hypertension, N (%)	28 (70)	25 (96.2)	<b>0.010</b>
DM, N (%)	8 (20)	8 (30.8)	0.384
Hyperlipidemia, N (%)	13 (32.5)	8 (30.8)	>0.999
CKD, N (%)	2 (5)	4 (15.4)	0.202
<b><i>Previous invasive vascular therapies</i></b>			
Coronary artery invasive treatment, N (%)	11 (27.5)	3 (11.5)	0.217
Contralateral ICA invasive treatment, N (%)	8 (20)	13 (50)	<b>0.015</b>
Subclavian artery invasive treatment, N (%)	0 (0)	1 (3.8)	0.394
Visceral artery invasive treatment, N (%)	1 (2.5)	2 (7.7)	0.557
Aortic invasive treatment, N (%)	0 (0)	1 (3.8)	0.394
Lower extremity arterial invasive treatment, N (%)	7 (17.5)	11 (42.3)	<b>0.046</b>

AS, Atherosclerotic; CKD, chronic kidney disease; DM, diabetes mellitus; ICA, internal carotid artery; RES, restenotic; TIA, transient ischemic attack.

## 4.2.2. Lesion characteristics

Lesion characteristics can be found in Table 8. The narrowest part of the ICA stenosis was at least 20 mm from the bifurcation in all patients. Among lesion-related parameters, only the length was significantly different between the two groups; AS lesions were significantly longer ( $P=0.002$ ) than RES lesions.

**Table 8. Lesion characteristics**

<b>Lesion-related parameters</b>	<b>AS group (N=40)</b>	<b>RES group (N=26)</b>	<b>P- value</b>
<i>Right side, N (%)</i>	15 (37.5)	14 (53.8)	0.214
<i>Distance from the bifurcation (mm), median (IQR)</i>	20.4 (20.1– 21.4)	21.5 (20.1– 24)	0.126
<i>Stenosis grade (%), median (IQR)</i>	90 (80–90)	90 (85–95)	0.099
<i>Stenosis length (mm), median (IQR)</i>	8.1 (6.1–12)	5.1 (4.1–7.5)	<b>0.002</b>
<i>Calcification, N (%)</i>	25 (62.5)	11 (42.3)	0.133
Mild, N (%)	14 (35)	8 (30.8)	0.794
Moderate, N (%)	8 (20)	1 (3.8)	0.077
Heavy, N (%)	3 (7.5)	2 (7.7)	>0.999

AS, Atherosclerotic; *IQR*, interquartile range; *RES*, restenotic.

## 4.2.3. Procedure data

In the AS group, the access site was femoral in 28 cases (70%) and radial in 12 cases (30%), while in the RES group, the access site was femoral in 13 cases (50%), radial in 10 cases (38.5%), and brachial in three cases (11.5%). In the AS group, embolic protection was distal type (FilterWire EZ) in 38 patients (95%) and proximal type (Mo.Ma) in two patients (5%). In the RES group, all patients had distal type embolic protection. Six cases (15%) in the AS group and one case (3.8%) in the RES group required predilation. Five different types of self-expanding stents were used. Twenty-eight (42.4%) of the stents were located only in the ICA and did not extend into the bifurcation and CCA. All stents were postdilated. Technical success was achieved in 100% of the cases. The types, diameters, and lengths of balloons and stents are listed in Table 9.

**Table 9. Parameters of balloons and stents**

<b>Balloons/stents</b>	<b>AS group (N=40)</b>	<b>RES group (N=26)</b>
<b><i>Balloons used for predilation</i></b>		
Maverick (Boston Scientific Corp., Marlborough, MA, USA), N (%)	4 (10)	0 (0)
Emerge (Boston Scientific Corp.), N (%)	1 (2.5)	0 (0)
Pantera Pro (Biotronik AG, Bülach, Switzerland), N (%)	1 (2.5)	0 (0)
Sprinter Legend Rx (Medtronic Inc., Minneapolis, MN, USA), N (%)	0 (0)	1 (3.8)
Diameter (mm), range	2.5–4	2.5
Length (mm), range	20–40	12
<b><i>Stents</i></b>		
Wallstent (Boston Scientific Corp.), N (%)	32 (80)	25 (96.2)
Exact (Abbott Vascular Inc., Santa Clara, CA, USA), N (%)	4 (10)	0 (0)
Roadsaver (Terumo Corp., Tokyo, Japan), N (%)	1 (2.5)	1 (3.8)
Precise Pro (Cordis Corp., Johnson & Johnson Co., Miami, FL, USA), N (%)	2 (5)	0 (0)
Exponent (Medtronic Inc.), N (%)	1 (2.5)	0 (0)
Diameter (mm), range	5–9	5–9
Length (mm), range	25–50	30–50
<b><i>Balloons used for postdilation</i></b>		
Sterling (Boston Scientific Corp.), N (%)	25 (62.5)	12 (46.2)
Maverick (Boston Scientific Corp.), N (%)	8 (20)	5 (19.2)
Viatrac 14 Plus (Abbott Vascular Inc.), N (%)	5 (12.5)	6 (23.1)
Ultra-Soft SV (Boston Scientific Corp.), N (%)	2 (5)	3 (11.5)
Diameter (mm), range	4–6	4–5
Length (mm), range	20–40	20–40

AS, Atherosclerotic; RES, restenotic.

4.2.4. Early ( $\leq 30$  days) post-procedural period

There were five intervention-related complications: one inguinal haematoma (1.5%) that did not require evacuation and four neurological events (6.1%; AS group, one TIA and one major stroke; RES group, two TIAs). Parameters of patients with post-procedural neurological complications can be seen in Table 10. Transient ischemic attacks presented as contralateral upper and/or lower limb paresis or dysarthria and lasted no longer than 15 minutes. None of the TIA patients had acute ischemic or hemorrhagic brain lesions on post-stenting CT or MR images. The time between CEA and CAS was 103 months in patient 3 and 178 months in patient 4. The patient with major stroke lost consciousness 2 hours after an uneventful stenting procedure. Emergency CT scan showed extensive bleeding in the ipsilateral frontal and parietal lobes. The patient died on day 37 after stenting.

**Table 10. Parameters of patients with post-procedural neurological complications**

Parameters	Patient 1 with TIA	Patient 2 with major stroke	Patient 3 with TIA	Patient 4 with TIA
Sex	Male	Male	Female	Female
Age	59 years	87 years	67 years	86 years
Etiological group	AS	AS	RES	RES
Pre-procedural symptom	No	TIA	Minor stroke	TIA
Contralateral ICA stenosis/occlusion	Occlusion	No	Stenosis	Stenosis
Ipsilateral pre-procedural stenosis grade and length	90%, 6.2 mm	95%, 16.8 mm	90%, 3.3 mm	95%, 4.5 mm
Calcification	Mild	Absent	Absent	Mild
Predilation	No	Yes	No	No
Stent type	Wallstent	Wallstent	Wallstent	Wallstent
Post-procedural US	Patent stent	Patent stent	Patent stent	Patent stent

AS, Atherosclerotic; RES, restenotic; TIA, transient ischemic attack; US, ultrasound.

#### 4.2.5. Follow-up

The median follow-up time was 34 months (IQR, 15–87 months) in the AS group and 41 months (IQR, 28–74 months) in the RES group. There was no significant difference ( $P=0.708$ ) in the follow-up time between the two groups. Two cases (5%) of ISR 50–69% and one case (2.5%) of ISR  $\geq 70\%$  were detected in the AS group. All ISRs were located within the stent and were of focal type. Patients with ISR were asymptomatic. The patient with  $\geq 70\%$  ISR underwent reintervention with a plain balloon (Trek Rx; Abbott Vascular Inc., Santa Clara, CA, USA; size, 4 mm  $\times$  20 mm). No one in the RES group had ISR.

The primary patency rate was 97.2% at 6 months, 94.4% at 12 and 24 months, and 89.7% at 36 and 48 months in the AS group, and 100% during the entire follow-up period in the RES group. The primary patency rates of the two groups were not significantly different ( $P=0.528$ ). (Figure 3 and Table 11) During follow-up, three patients (7.5%) in the AS group and seven patients (26.9%) in the RES group died. The cause of death was myocardial infarction in three patients, heart failure in two patients, malignancy in two patients, major stroke in one patient, chronic obstructive pulmonary disease in one patient, and gastrointestinal bleeding in one patient. The survival proportion was 97.4% at 6, 12, and 24 months and 84.1% at 36 and 48 months in the AS group and 100% at 6, 12, and 24 months, 83.8% at 36 months, and 61.5% at 48 months in the RES group. The survival proportions of the two groups were not significantly different ( $P=0.289$ ). (Figure 4 and Table 12)



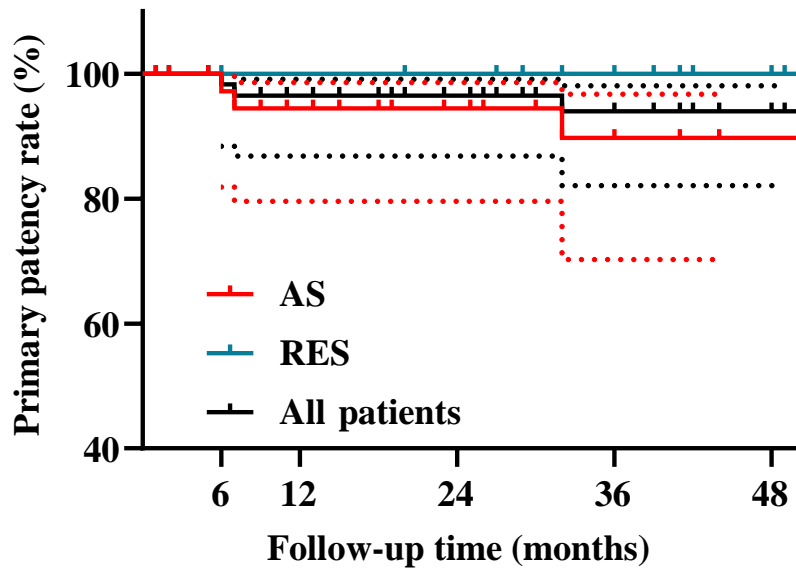
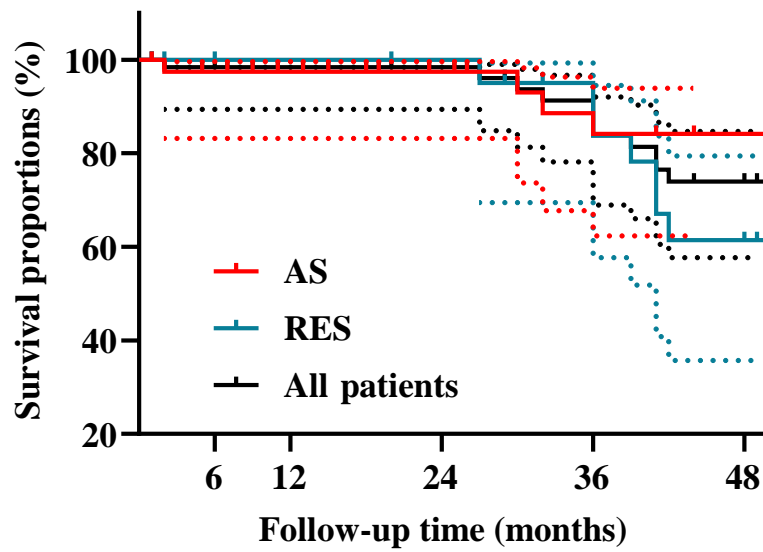


Figure 3. Primary patency (AS, Atherosclerotic; RES, restenotic.)

Table 11. Primary patency

		6 months	12 months	24 months	36 months	48 months
<i>All patients</i>	%	98.3	96.5	96.5	94	94
	<i>No. at risk</i>	58	52	45	35	26
	95% CI	88.42– 99.78	86.77– 99.12	86.77– 99.12	82.11– 98.06	82.11– 98.06
<i>AS group</i>	%	97.2	94.4	94.4	89.7	89.7
	<i>No. at risk</i>	36	31	25	18	16
	95% CI	81.87– 99.60	79.56– 98.58	79.56– 98.58	70.25– 96.72	70.25– 96.72
<i>RES group</i>	%	100	100	100	100	100
	<i>No. at risk</i>	22	22	21	17	11
	95% CI	-	-	-	-	-

AS, Atherosclerotic; CI, confidence interval; RES, restenotic.



**Figure 4. Survival proportions (AS, Atherosclerotic; RES, restenotic.)**

**Table 12. Survival proportions**

		6 months	12 months	24 months	36 months	48 months
<i>All patients</i>	%	98.4	98.4	98.4	83.9	73.9
	<i>No. at risk</i>	58	54	46	37	28
	95% CI	89.42– 99.78	89.42– 99.78	89.42– 99.78	68.92– 92.04	55.71– 84.72
<i>AS group</i>	%	97.4	97.4	97.4	84.1	84.1
	<i>No. at risk</i>	37	33	26	20	18
	95% CI	83.16– 99.64	83.16– 99.64	83.16– 99.64	62.37– 93.89	62.37– 93.89
<i>RES group</i>	%	100	100	100	83.8	61.5
	<i>No. at risk</i>	22	22	21	17	11
	95% CI	-	-	-	57.69– 94.49	35.68– 79.47

AS, Atherosclerotic; CI, confidence interval; RES, restenotic.

### 4.3. Study III (Mid-term results and predictors of restenosis in patients undergoing endovascular therapy for isolated popliteal artery steno-occlusive disease)

#### 4.3.1. Patient data

Twenty-six patients (42.6%) were in the PTA group, while 35 patients (57.4%) were in the stenting group. The median age in the PTA group was 65.1 years (IQR, 60.7–71.9 years). The indication for radiological intervention was severe claudication (Rutherford grade 3) in 12 cases (46.2%) and critical limb ischemia (Rutherford grade 4–6) in 14 cases (53.8%). Six patients (23.1%) were obese, 22 patients (84.6%) were smokers, 22 patients (84.6%) had hypertension, 13 patients (50%) had DM, 10 patients (38.5%) had hyperlipidemia, and three patients (11.5%) had CKD. (Table 13) Six patients (23.1%) had coronary artery bypass grafting and/or percutaneous coronary intervention, one patient (3.8%) had supra-aortic surgical and/or endovascular reconstruction, and three patients (11.5%) had contralateral lower extremity open and/or percutaneous revascularization.

The median age in the stenting group was 63.5 years (IQR, 56.9–71 years). The indication for radiological intervention was severe claudication in 21 cases (60%) and critical limb ischemia in 14 cases (40%). Eleven patients (31.4%) were obese, 30 patients (85.7%) were smokers, 30 patients (85.7%) had hypertension, 15 patients (42.9%) had DM, 20 patients (57.1%) had hyperlipidemia, and one patient (2.9%) had CKD. (Table 14) Six patients (17.1%) had coronary artery bypass grafting and/or percutaneous coronary intervention, three patients (8.6%) had supra-aortic surgical and/or endovascular reconstruction, and 14 patients (40%) had contralateral lower extremity open and/or percutaneous revascularization.

**Table 13. Treatment indication, atherosclerotic risk factors, and comorbidities in the percutaneous transluminal angioplasty group**

<b>Indication, atherosclerotic risk factors, comorbidities</b>	<b>RES subgroup (N=9)</b>	<b>Non-RES subgroup (N=17)</b>	<b>P-value</b>
<i>Critical limb ischemia, N (%)</i>	4 (44.4)	10 (58.8)	>0.999
<i>Female gender, N (%)</i>	5 (55.6)	11 (64.7)	0.692
<i>Age (year), median (IQR)</i>	70.3 (63–75.5)	63.5 (56.2–69.9)	0.124
<i>Obesity (BMI <math>\geq</math>30 kg/m<sup>2</sup>), N (%)</i>	2 (22.2)	4 (23.5)	>0.999
<i>Smoking, N (%)</i>	9 (100)	13 (76.5)	0.263
<i>Hypertension, N (%)</i>	9 (100)	13 (76.5)	0.263
<i>DM, N (%)</i>	4 (44.4)	9 (52.9)	>0.999
<i>Hyperlipidemia, N (%)</i>	3 (33.3)	7 (41.2)	0.206
<i>CKD, N (%)</i>	1 (11.1)	2 (11.8)	>0.999

*BMI*, Body mass index; *CKD*, chronic kidney disease; *DM*, diabetes mellitus; *IQR*, interquartile range; *PTA*, percutaneous transluminal angioplasty; *RES*, restenotic.

**Table 14. Treatment indication, atherosclerotic risk factors, and comorbidities in the stenting group**

Indication, atherosclerotic risk factors, comorbidities	RES subgroup (N=12)	Non-RES subgroup (N=23)	P-value
<i>Critical limb ischemia, N (%)</i>	6 (50)	8 (34.8)	0.477
<i>Female gender, N (%)</i>	3 (25)	9 (39.1)	0.477
<i>Age (year), median (IQR)</i>	63.3 (57.9–70.2)	63.5 (56.9–71.5)	0.794
<i>Obesity (BMI <math>\geq</math>30 kg/m<sup>2</sup>), N (%)</i>	2 (16.7)	9 (39.1)	>0.999
<i>Smoking, N (%)</i>	11 (91.7)	19 (82.6)	0.640
<i>Hypertension, N (%)</i>	10 (83.3)	20 (87)	>0.999
<i>DM, N (%)</i>	5 (41.7)	10 (43.5)	>0.999
<i>Hyperlipidemia, N (%)</i>	6 (50)	14 (60.9)	0.721
<i>CKD, N (%)</i>	0 (0)	1 (4.3)	>0.999

*BMI*, Body mass index; *CKD*, chronic kidney disease; *DM*, diabetes mellitus; *IQR*, interquartile range; *PTA*, percutaneous transluminal angioplasty; *RES*, restenotic.

#### 4.3.2. Lesion, balloon, and stent characteristics

The pathological background in all cases was atherosclerosis. The ipsilateral antegrade approach was chosen in 42 patients (68.9%), while the contralateral approach was used in 19 cases (31.1%). In the PTA group, lesions were left-sided in 12 patients (46.2%). The steno-occlusive disease affected the P1 segment in 13 cases (50%) and so did the P2 segment in eight cases (30.8%). Multi-segment disease within the PA was observed in five cases (19.2%). The median degree of stenosis was 95% (IQR, 90–100%), the median lesion length was 26.7 mm (IQR, 11.6–72.9 mm), and calcification was observed in 13 patients (50%). The median balloon diameter was 5 mm (IQR, 5–5 mm), and the median balloon length was 40 mm (IQR, 40–80 mm). (Table 15)

In the stenting group, lesions were left-sided in 15 patients (42.9%). The steno-occlusive disease affected the P1 segment in 14 cases (40%) and so did the P2 segment in 12 cases (34.3%). Multi-segment disease within the PA was present in nine cases (25.7%). The median degree of stenosis was 100% (IQR, 90–100%), the median lesion

length was 52.8 mm (IQR, 23.4–80.6 mm), and calcification was observed in 22 patients (62.9%). In all cases, a self-expanding Astron Pulsar stent (Biotronik AG, Bülach, Switzerland) was deployed. The median stent diameter was 6 mm (IQR, 6–7 mm) and the median stent length was 60 mm (IQR, 40–120 mm). (Table 16) Primary stenting was performed in 15 patients (42.9%) and selective stenting in 20 patients (57.1%).

**Table 15. Lesion and balloon parameters in the percutaneous transluminal angioplasty group**

Parameters	RES subgroup (N=9)	Non-RES subgroup (N=17)	P-value
<i>Lesion</i>			
Left-sided, N (%)	5 (55.6)	7 (41.2)	0.683
P1 segment, N (%)	6 (66.7)	7 (41.2)	0.411
P2 segment, N (%)	2 (22.2)	6 (35.3)	0.667
P3 segment, N (%)	0 (0)	0 (0)	NA
Multi-segment disease, N (%)	1 (11.1)	4 (23.5)	0.628
Stenosis grade (%), median (IQR)	100 (90–100)	90 (90–100)	0.293
Occlusion, N (%)	6 (66.7)	7 (41.2)	0.411
Length (mm), median (IQR)	49.6 (17.3–72.6)	24.9 (11.6–60.9)	0.666
Calcification, N (%)	4 (44.4)	9 (52.9)	>0.999
Heavy calcification, N (%)	1 (11.1)	1 (5.9)	>0.999
<i>Balloon</i>			
Diameter (mm), median (IQR)	5 (5–5)	5 (4–5)	0.686
Length (mm), median (IQR)	40 (40–80)	40 (40–80)	0.225

*IQR*, Interquartile range; *NA*, not applicable; *PI–3*, popliteal; *PTA*, percutaneous transluminal angioplasty; *RES*, restenotic.

**Table 16. Lesion and stent parameters in the stenting group**

Parameters	RES subgroup (N=12)	Non-RES subgroup (N=23)	P-value
<i>Lesion</i>			
Left-sided, N (%)	5 (41.7)	10 (43.5)	>0.999
P1 segment, N (%)	1 (8.3)	13 (56.5)	<b>0.010</b>
P2 segment, N (%)	6 (50)	6 (26.1)	0.261
P3 segment, N (%)	0 (0)	0 (0)	NA
Multi-segment disease, N (%)	5 (41.7)	4 (17.4)	0.220
Stenosis grade (%), median (IQR)	100 (100–100)	100 (90–100)	0.357
Occlusion, N (%)	10 (83.3)	15 (65.2)	0.434
Length (mm), median (IQR)	58.3 (30.6–82.7)	49.6 (17.3–72.6)	0.289
Calcification, N (%)	9 (75)	13 (56.5)	0.463
Heavy calcification, N (%)	2 (16.7)	4 (17.4)	>0.999
<i>Stent</i>			
Diameter (mm), median (IQR)	6 (6–7)	6 (6–7)	0.972
Length (mm), median (IQR)	60 (60–120)	60 (40–80)	0.476

*IQR*, Interquartile range; *NA*, not applicable; *PI*–3, popliteal; *RES*, restenotic.

#### 4.3.3. Early ( $\leq 30$ days) post-procedural period

Technical success was achieved in 100% of patients. In one stented patient, a retroperitoneal hematoma was observed, but no evacuation of the hematoma was necessary. The patient was discharged after 2 days of observation. None of the patients had distal embolization. The 30-day all-cause mortality rate was zero.

#### 4.3.4. Follow-up

At 6 weeks, the clinical success rate was 92% in the PTA group and 89% in the stenting group. The median resting ABI in the PTA group improved significantly ( $P < 0.001$ )

from 0.40 (IQR, 0.28–0.52) before the procedure to 0.90 (IQR, 0.84–1.02) at 6-week follow-up. For the stenting group, the ABI also improved significantly ( $P<0.001$ ) from 0.37 (IQR, 0.24–0.51) to 0.89 (IQR, 0.80–1.0).

The median follow-up time was 29 months (IQR, 16–47 months) in the PTA group and 26.5 months (IQR, 6–47 months) in the stenting group. Follow-up time was not significantly different ( $P=0.435$ ) between groups. Nine patients (34.6%) in the PTA group (stenosis,  $N=7$ ; occlusion,  $N=2$ ) and 12 patients (34.3%) in the stenting group developed restenosis (stenosis,  $N=5$ ; occlusion,  $N=7$ ). Nine cases (100%) in the PTA group (PTA with plain balloon,  $N=5$ ; stenting with Astron Pulsar stent,  $N=4$ ) and eight cases (66.7%) in the stenting group required reintervention (PTA with plain balloon,  $N=6$ ; stenting with Astron Pulsar stent,  $N=1$ ; femoropopliteal bypass grafting,  $N=1$ ).

The primary patency rate was 85.7% at 6 months, and 71.4% at 12 and 24 months in the PTA group, while in the stenting group it was 91.2% at 6 months, 88.2% at 12 months, and 68.9% at 24 months. There was no significant difference ( $P=0.629$ ) in primary patency rates between groups. The primary patency rate in the pooled patient group was 89.1% at 6 months, 81.8% at 12 months, and 70% at 24 months. (Figure 5 and Table 17)

Re-restenosis was observed in three patients (3/9; 33.3%) in the PTA group and in six patients (6/8; 75%) in the stenting group. In the PTA group, two out of three patients underwent invasive therapy (PTA with plain balloon,  $N=1$ ; femoropopliteal bypass grafting,  $N=1$ ), whereas in the stenting group, four out of six patients underwent repeated revascularization (PTA with plain balloon,  $N=2$ ; stenting with Astron Pulsar stent,  $N=1$ ; femorocrural bypass grafting,  $N=1$ ).

The secondary patency rate was 100% at 6 months, and 90% at 12 and 24 months in the PTA group, while in the stenting group it was 100% at 6 months, 97.1% at 12 months, and 90.6% at 24 months. There was no significant difference ( $P=0.603$ ) in secondary patency rates between groups. The secondary patency rate in the pooled patient group was 100% at 6 months, 96.3% at 12 months, and 90.4% at 24 months. (Figure 6 and Table 18) Restenosis and re-restenosis were treated invasively only in patients with Rutherford stages 3–6.



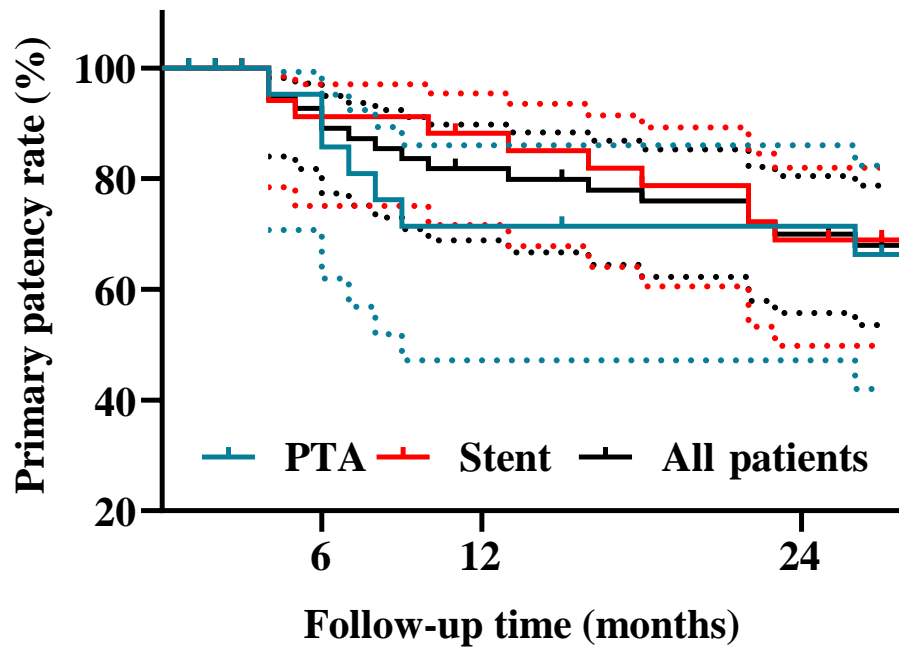
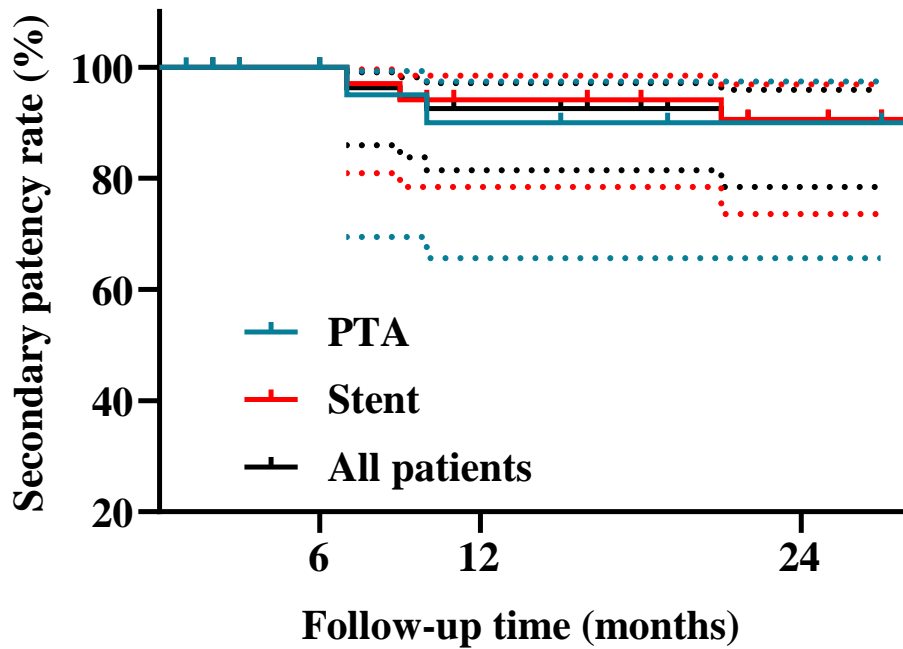


Figure 5. Primary patency rate of percutaneous transluminal angioplasty and stenting groups (*PTA*, Percutaneous transluminal angioplasty.)

Table 17. Primary patency rate of percutaneous transluminal angioplasty and stenting groups

		6 months	12 months	24 months
<i>All patients</i>	%	89.1	81.8	70
	<i>No. at risk</i>	51	44	36
	<i>95% CI</i>	77.32–4.95	68.84–89.78	55.73–80.47
<i>PTA group</i>	%	85.7	71.4	71.4
	<i>No. at risk</i>	20	16	15
	<i>95% CI</i>	85.7	71.4	71.4
<i>Stenting group</i>	%	91.2	88.2	68.9
	<i>No. at risk</i>	32	29	22
	<i>95% CI</i>	75.09–97.1	71.63–95.41	49.84–81.98

*CI*, Confidence interval; *PTA*, percutaneous transluminal angioplasty.



**Figure 6. Secondary patency rate of percutaneous transluminal angioplasty and stenting groups (PTA, Percutaneous transluminal angioplasty.)**

**Table 18. Secondary patency rate of percutaneous transluminal angioplasty and stenting groups**

		6 months	12 months	24 months
<i>All patients</i>	%	100	92.6	90.4
	<i>No. at risk</i>	55	49	42
	<i>95% CI</i>	-	81.46–97.15	78.49–95.52
<i>PTA group</i>	%	100	90	90
	<i>No. at risk</i>	21	19	17
	<i>95% CI</i>	-	65.60–97.40	65.60–97.40
<i>Stenting group</i>	%	100	94.1	90.6
	<i>No. at risk</i>	35	31	26
	<i>95% CI</i>	-	78.47–98.50	73.57–96.90

*CI*, Confidence interval; *PTA*, percutaneous transluminal angioplasty.

#### 4.3.5. Predictors of restenosis

In the PTA group, neither atherosclerotic risk factors nor lesion and balloon parameters were significantly different between the RES and non-RES subgroups. (Tables 13 and 15) In the stenting group, stents implanted in the P1 segment were significantly less likely ( $P=0.010$ ) to develop restenosis compared with P2 plus multi-segment stents. The primary patency rate was 100% at 6 and 12 months and 90.9% at 24 months for P1 segment stents compared with 85.7% at 6 months, 81% at 12 months, and 55.7% at 24 months for P2 plus multi-segment stents. Primary patency rates were significantly improved ( $P=0.018$ ) in patients with P1 stents compared with patients with P2 and multi-segment stents. (Figure 7 and Table 19)

The secondary patency rate at 6, 12, and 24 months was 100% in patients with a P1 segment lesion, while in patients with a P2 plus multi-segment lesion it was 100% at 6 months, 90.5% at 12 months, and 84.8% at 24 months. There was no significant difference ( $P=0.253$ ) in the secondary patency rate of the stented segments. (Figure 8 and Table 20)

Cox regression analysis identified lesion location as a predictor of ISR (HR, 2.54; 95% CI, 1.16–5.54;  $P=0.019$ ).

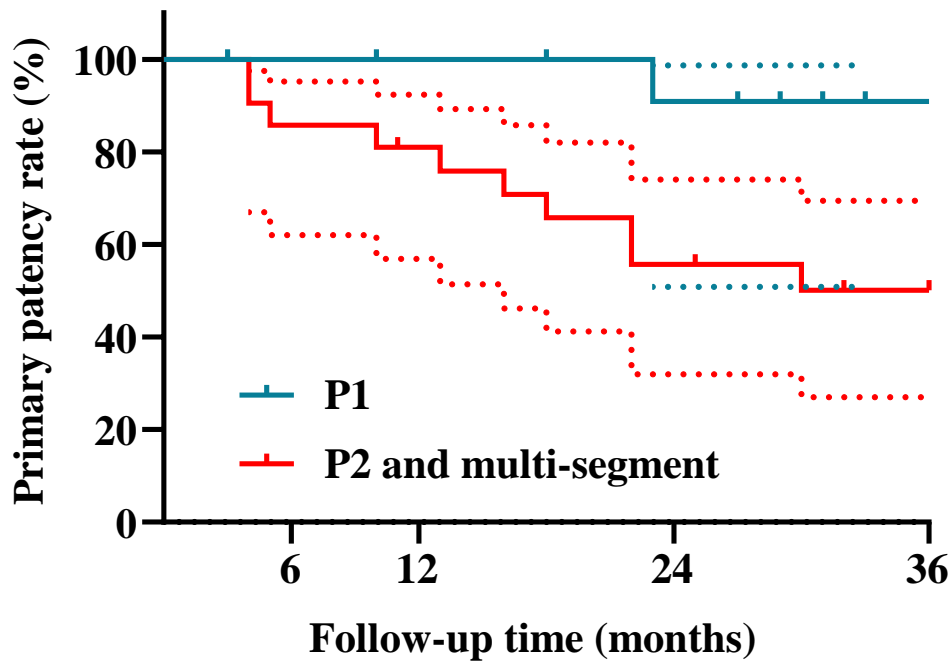


Figure 7. Primary patency rate of different popliteal artery segments (*P1-2*, Popliteal.)

Table 19. Primary patency rate of different popliteal artery segments

		6 months	12 months	24 months
<i>P1 segment</i>	%	100	100	90.9
	<i>No. at risk</i>	13	12	11
	<i>95% CI</i>	-	-	50.81–98.67
<i>P2 and multi-segment</i>	%	85.7	81	55.7
	<i>No. at risk</i>	19	17	13
	<i>95% CI</i>	61.97–95.16	56.89–92.39	31.97–74.00

*CI*, Confidence interval; *P1-2*, popliteal.

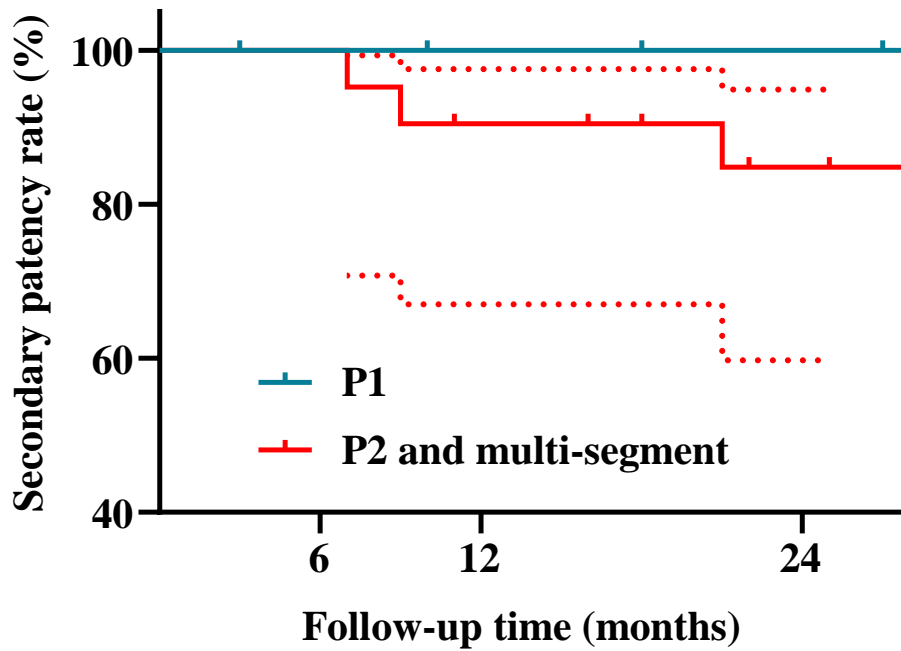


Figure 8. Secondary patency rate of different popliteal artery segments (*P1–2*, Popliteal.)

Table 20. Secondary patency rate of different popliteal artery segments

		6 months	12 months	24 months
<i>P1 segment</i>	%	100	100	100
	No. at risk	14	13	12
	95% CI	-	-	-
<i>P2 and multi-segment</i>	%	100	90.5	84.8
	No. at risk	21	20	15
	95% CI	-	67.00–97.53	59.75–94.87

CI, Confidence interval; *P1–2*, popliteal.

## 5. Discussion

### 5.1. Study I (Restenosis rates in patients with ipsilateral carotid endarterectomy and contralateral carotid artery stenting)

The outcome of CEA and CAS for ICA stenosis in the same patient was previously investigated in four retrospective studies. (82–85) De Borst et al. compared restenosis rates in 63 patients who first underwent CEA followed by CAS. The median follow-up time was  $54.4\pm 39.5$  months for CEA and  $28.7\pm 16.9$  months for CAS. The rate of  $\geq 50\%$  restenosis was not significantly different between CEA and CAS and was 10%, 19%, and 24% for CEA and 23%, 31%, and 34% for CAS at 1, 2, and 3 years, respectively. (83) Martelli et al. revealed  $\geq 50\%$  restenosis in 31% of CEAs (median follow-up,  $67.3\pm 51.6$  months) and 21% of CASs (median follow-up,  $24.6\pm 16.9$  months). In their study, the restenosis-free survival rate was 85% after CEA and 66% after CAS. Since the definition of restenosis-free survival rate is not found in the article by Martelli et al., and patient loss to follow-up was not reported, the survival rates mentioned by this group should be taken with a grain of salt. (82) Ciccone et al. evaluated 45 patients treated with CEA on one side and CAS on the contralateral side, and none of the patients had  $\geq 50\%$  restenosis on either side, but the carotid diameter stenosis was on average 10% higher at 6 months and 16% higher at 1 year with CEA than with CAS (P-value not shown in the article). (85) Xu et al. carried out CEA and CAS simultaneously in eight patients and detected no restenosis at 6-month follow-up. (84)

In our study, the risk of  $\geq 50\%$  restenosis was the same in the first year after both procedures, and then it was significantly higher throughout the follow-up in the CEA group. For CEA, we noted restenosis rates similar to those documented by de Borst et al., (83) but approximately 10% better 5-year restenosis rates than Martelli et al. (82) In the latter study, the majority of CEAs were performed with direct suturing, which is known to have a higher rate of restenosis than patching and eversion endarterectomy. (104) Regarding CAS, de Borst et al. published significantly worse ISR rates at 1, 2, and 3 years than our results, but nearly 20% of their CAS lesions were post-surgical restenosis, (83) previously identified as an independent risk factor for ISR. (82, 105) Moreover, de Borst et al. used the same US cut-off values to determine the grade of stenosis after stenting as before stenting. This is incorrect because an inserted stent

reduces the elasticity of that artery segment, resulting in higher flow velocities compared to native artery segments. Therefore, in our opinion, the incidence of ISR was overestimated in the study by de Borst et al. (83, 91)

A recently updated Cochrane meta-analysis of randomized clinical trials comparing restenosis rates between CAS and CEA in asymptomatic and symptomatic patients showed a significantly higher risk of  $\geq 50\%$  restenosis after CAS (OR, 2.00; 95% CI, 1.12–3.60;  $P=0.02$ ;  $I^2=44\%$ ), however, no significant difference was observed in the pooled data for severe ( $\geq 70\%$ ) restenosis (OR, 1.26; 95% CI, 0.79–2.00;  $P=0.33$ ;  $I^2=58\%$ ). (33) Four of the randomized clinical trials included in the Cochrane meta-analysis reported data on  $\geq 50\%$  restenosis. In three of four randomized clinical trials,  $\geq 50\%$  restenosis occurred more frequently after CAS than after CEA. (33) The Endarterectomy Versus Angioplasty in Patients with Symptomatic Severe Carotid Stenosis (EVA-3S) trial compared 242 patients treated with CAS and 265 patients treated with CEA. At 3 years, 12.5% of patients after CAS and 5% of patients after CEA developed a  $\geq 50\%$  restenosis (OR, 2.65; 95% CI, 1.31–5.35). (106) In the Regensburg 2008 trial, eight (25%) of 32 patients randomized to CAS and one (3.4%) of 29 patients randomized to CEA had  $\geq 50\%$  restenosis (OR, 9.33; 95% CI, 1.09–80.06). (107) In the International Carotid Stenting Study (ICSS),  $\geq 50\%$  restenosis was detected in 274 of 737 CASs and 217 of 793 CEAs; the 5-year cumulative risk of  $\geq 50\%$  restenosis was 40.7% after CAS and 29.6% after CEA (HR, 1.43; 95% CI, 1.21–1.72;  $P<0.001$ ). (108) In the Basel Carotid Artery Stenting Study (BACASS), 10 patients were enrolled to both groups. Only one restenosis occurred and it was not in the CAS group but in the CEA group. (109) Nine randomized clinical trials with a secondary endpoint of  $\geq 70\%$  restenosis were included in the meta-analysis. None of the nine randomized clinical trials found a significant difference in the rate of severe ( $\geq 70\%$ ) restenosis between the CAS and CEA groups. (33)

In our study, the majority of restenosis was 50–69% on the stented side and  $\geq 70\%$  on the operated side. Even after adjusting for differences between the two groups, an HR of 1.86 was estimated favoring CAS for restenosis. A possible explanation for the better patency of CAS could be that in most randomized clinical trials, patients had a similar baseline prognosis due to randomization, whereas our patients had different lesion characteristics on the two sides. Another explanation may be that the differences in

restenosis rates in our study were more accentuated at later stages of the follow-up, and none of the randomized clinical trials had as long a follow-up as our study.

Two main processes play a role in the pathomechanism of restenosis. One is neointimal hyperplasia, which appears in the early stages, and the other is “neoatherosclerosis”, which usually develops only 2–3 years after the intervention. (43) In our study, no significant difference in 1-year restenosis rates was noted between CEA and CAS, and almost half of the restenoses in the CEA group occurred after 2 years. In our opinion, this underlines the importance of the duration of atherosclerotic risk factors, since the average duration of hypertension, DM, and hyperlipidemia was significantly longer at the end of the follow-up on the side where CEA was performed.

One of the limitations of our study is its retrospective nature. Additional limitations are the inevitable selection bias, as guidelines recommend different interventional techniques for different types of lesions. Although the most important risk factors have been adjusted, the persistence of the residual confounding factors cannot be ruled out.

## 5.2. Study II (Short- and mid-term outcomes of stenting in patients with isolated distal internal carotid artery stenosis or post-surgical restenosis)

Most studies analyzed the short- and mid/long-term outcomes of CAS separately for atherosclerosis and post-surgical restenosis, (33, 110) but we found nine studies that did so comparatively. (111–119) The two main indicators of the short-term success of CAS are the rate of new or recurrent neurological events and mortality. The rate of stroke within 30 days after stenting is between 0% and 9.8%, while the rate of all-cause mortality within 30 days after stenting is between 0% and 1.3% for atherosclerotic ICA stenoses. (33) The same rates for post-surgical ICA restenosis stenting are 0–18% and 0–2%, respectively. (110) Peri- and post-procedural neurological complications were more frequent in patients stented for atherosclerotic ICA stenosis in five of the nine comparative studies. (111, 112, 114, 115, 117) AbuRahma et al. evaluated 68 patients undergoing ICA stenting for atherosclerosis and 121 patients undergoing ICA stenting for post-CEA restenosis; the median follow-up time was 19 months (range, 1–73 months) and 22.6 months (range, 1–78 months), respectively. Any type of stroke was significantly more common in the atherosclerotic group than in the post-surgical restenotic group (7.4% versus 3.3%,  $P=0.029$ ). Five of the six patients with peri-



procedural stroke had pre-procedural symptoms. All-cause mortality differed significantly between the two groups only when the composite endpoints of stroke and death were compared (7.4% versus 0.9%,  $P=0.029$ ). (111) White et al. examined three groups of stented patients with different etiologies, namely atherosclerotic, post-surgical restenotic, and radiation-induced ICA stenosis. In this study, a subgroup analysis of 871 atherosclerotic and 341 post-surgical restenotic patients showed significantly more TIAs in the atherosclerotic group than in the post-surgical restenotic group (2.8% versus 0.3%,  $P=0.005$ ), however, after regression analysis adjusted for confounding factors, the difference no longer remained significant. The 30-day all-cause mortality was 6% in the atherosclerotic group and 4.5% in the post-surgical restenotic group ( $P=0.230$ ). (112) Kahlberg et al. enrolled 158 matched patients in both the atherosclerotic and post-surgical restenotic groups. The rate of 30-day combined neurological events (TIA, amaurosis fugax, and all types of stroke) was significantly higher in the atherosclerotic group than in the post-surgical restenotic group (7.6% versus 1.9%,  $P=0.017$ ). None of the patients died within 30 days of the procedure. (114) Hynes et al. also performed a propensity-matched study with 1,756 patients per group. There was a significant difference between the two groups in the rate of in-hospital combined neurological events, which was higher in the atherosclerotic group (3.6% versus 2.2%,  $P<0.001$ ). The rate of stroke in the first 30 days after the intervention was similar in the two groups (3.2% versus 4.5%,  $P=0.077$ ). In-hospital mortality rates were also significantly higher in the atherosclerotic group (0.7% versus 0.3%,  $P=0.012$ ). (115) Arhuidese et al. compared three groups of patients: such as patients stented for primary ICA stenosis, patients stented for post-CEA restenosis, and patients re-stented for ICA ISR. A subgroup analysis including 8,519 patients stented for primary ICA stenosis and 2,645 patients stented for post-CEA restenosis was published. Both ipsilateral stroke (2.2% versus 1.6%,  $P=0.044$ ) and mortality (1.8% versus 0.9%,  $P=0.002$ ) were more frequent in the primary ICA stenosis group than in the post-CEA restenosis group in the first 30 days after stenting. (117)

Four studies showed no significant difference in neurological events within 30 days after stenting between the two etiological groups. (113, 116, 118, 119)

To the best of our knowledge, no study has specifically investigated the outcome of CAS in distal ICA lesions. In our AS group, the rate of neurological complications

within 30 days after stenting was 5%, as a result of one TIA and one hemorrhagic stroke; the hemorrhagic stroke patient died on the 37th day after the intervention. The underlying cause of the hemorrhagic stroke was presumably the hyperperfusion syndrome. After CAS, hyperperfusion syndrome occurs in 0–21.2% of cases, and consequent hemorrhagic stroke in 0.7–1.1% of cases. (120) There are two hypotheses as to how the hyperperfusion syndrome results in hemorrhagic stroke after CAS. (121) One hypothesis is that the sudden increase in blood flow and pressure due to impaired neurovascular autoregulation leads to rupture of vulnerable arterioles and capillaries in the chronically ischemic brain parenchyma. (121) According to another hypothesis, the background of the process is the malfunction of the baroreceptor reflex, which is caused by intense stimulation of the carotid body during the insertion of the stent and/or the inflation of the balloon. An ineffective baroreceptor reflex cannot respond to acute changes in the systemic blood pressure, which leads to a long-lasting increase in pressure in the neurovascular bed and then to the development of a hemorrhagic stroke. (121) In our RES group, compared to our AS group, neurological symptoms were seen in a non-significantly higher proportion, 7.7%, within 30 days after stenting, but no deaths were recorded in the early post-procedural period. Thus, the short-term success rate of stenting distal ICA (re)stenoses is not worse than stenting ICA (re)stenoses in general (without determining the location of the lesion).

The mid/long-term outcome of CAS is best characterized by ISR and the mortality rates. Some publications include both  $\geq 50\%$  ISR and  $\geq 70\%$  ISR, (107–109) while others only include  $\geq 70\%$  ISR. (122–126) Based on literature data, the prevalence of  $\geq 50\%$  ISR after stenting for atherosclerotic ICA lesions is between 0% and 37%, (107–109) while the prevalence of  $\geq 70\%$  ISR is between 0% and 9.8%. (122–126) For post-surgical ICA restenosis stenting, these incidences range from 0% to 15% (127, 128) and 0% to 9.5%, (129, 130) respectively. Only three of the nine comparative studies examined ISR. (111, 116, 119) AbuRahma et al. reported no significant difference in  $\geq 50\%$  ISR, which occurred in 10.6% of patients after CAS for atherosclerosis versus 8.2% of patients after CAS for post-surgical restenosis ( $P=0.761$ ). At 1, 2, 3, and 4 years, the freedom from  $\geq 50\%$  ISR was 94%, 83%, 83%, and 66% in the atherosclerotic group and 96%, 91%, 83%, and 72% in the post-surgical restenotic group ( $P=0.471$ ). Two patients (3%) in the atherosclerotic group and seven patients (6.3%) in the post-

surgical restenotic group had  $\geq 80\%$  ISR. At 1, 2, 3, and 4 years, the freedom from  $\geq 80\%$  ISR was 100%, 98%, 98%, and 78% in the atherosclerotic group and 99%, 96%, 92%, and 87% in the post-surgical restenotic group ( $P=0.701$ ). (111) Mousa et al. also investigated ISR as an endpoint in 196 patients undergoing CAS for atherosclerosis and 189 patients undergoing CAS for post-surgical restenosis, defining ISR as  $\geq 70\%$  stenosis by US. The rate of ISR was 9.6% in the atherosclerotic group and 15.3% in the post-surgical restenotic group ( $P=0.112$ ). The mean follow-up time was  $27.7 \pm 30.9$  months in the atherosclerotic group and  $41.8 \pm 33.3$  months in the post-surgical restenotic group. In this study, exact primary patency rates at specific follow-up times were not published, and Kaplan–Meier curves were compared in four subgroups of asymptomatic and symptomatic patients with atherosclerosis and post-surgical restenosis. (116) Tanaskovic et al. assessed 440 atherosclerotic and 342 post-surgical restenotic patients after CAS with a mean follow-up time of  $34.6 \pm 18$  months. The pooled rates of  $\geq 50\%$  ISR were 7.9% in all patients, 8.7% in patients with atherosclerosis, and 7.2% in patients with post-surgical restenosis ( $P=0.406$ ). The incidence of severe ( $\geq 70\%$ ) ISR was 5.6% in the entire study group and was also not significantly different between the two subgroups (atherosclerotic versus post-surgical restenotic subgroup, 6.4% versus 4.7%,  $P=0.351$ ). (119)

In our patient population, the incidence of ISR was not significantly higher in the AS group ( $\geq 50\%$  ISR, 7.5% and  $\geq 70\%$  ISR, 2.5%) than in the RES group ( $\geq 50\%$  ISR, 0% and  $\geq 70\%$  ISR, 0%). Thus, ISR rates for stenting of distal ICA (re)stenoses (e.g., short-term results) are not inferior to stenting of ICA (re)stenoses in general (without specifying the location of the lesion).

Only a few publications were found that included mid/long-term mortality rates for CAS. For CAS performed for atherosclerotic ICA stenoses, the mid/long-term mortality rate ranges from 12.1% to 35%, (108, 109, 130, 131) while for CAS performed for post-surgical ICA restenoses, the mid/long-term mortality rate ranges from 9.6% to 11.8%. (110, 129, 132) Of the nine comparative studies, only one study by AbuRahma et al. aimed to determine the mid-term (4-year) mortality rate. In this study, there was no significant difference in mid-term mortality (none related to stroke) between CAS for atherosclerosis (12.1%) and CAS for post-surgical restenosis (11.8%). Survival rates at 1, 2, 3, and 4 years were 91%, 86%, 80%, and 80% in the atherosclerotic group and

96%, 91%, 85% and 80% in the post-surgical restenotic group, respectively (P=0.510). (111)

The mid-term mortality rate of 7.5% in our AS group is low, while the mid-term mortality rate of 26.9% in our RES group is quite high in the light of the literature. However, it is important to note that none of the deaths in our RES group were directly related to CAS itself; deaths were due to other serious comorbidities of the patients.

Our study has two main limitations: its retrospective nature and the relatively small number of patients.

### 5.3. Study III (Mid-term results and predictors of restenosis in patients undergoing endovascular therapy for isolated popliteal artery steno-occlusive disease)

Several studies have investigated the results of endovascular treatment of atherosclerotic steno-occlusive disease of PA. (51, 75, 133–146) The majority of studies were heterogeneous not only in terms of treatment type, but also inflow and/or outflow involvement. Most studies included not only patients with isolated PA stenosis/occlusion, but also patients who underwent inflow and/or outflow repair in addition to PA intervention. (133–141, 143, 144, 146)

Only four studies reported the results of PTA and stenting in truly isolated *de novo* atherosclerotic PA stenosis/occlusion. (51, 75, 142, 145) Spiliopoulos et al. studied 46 patients treated with PTA or stenting in a retrospective multicenter trial, and the overall primary patency rate was 84.2% at 1 year and 59.1% at 2 years. Subgroup analysis showed no significant difference between primary patency after PTA and primary patency after stenting at 1 year (80% versus 84.6%; P=0.17). (51) A prospective multicenter trial was conducted by Rastan et al. Primary and selective stenting were compared with PTA in a subset of patients with PA occlusion (N=185). The primary patency rate at 2 years was 56.1% after PTA and 64.2% after stenting and the secondary patency rate was 78.4% after PTA and 77.8% after stenting, with no significant difference (P=0.45 and P>0.999, respectively). (142) Chang et al. assessed the short-term outcome of stenting in the P2 and P3 segments and found a relatively low primary patency rate of 44% at 6 months. (75) Troisi et al. evaluated six different types of treatment for isolated atherosclerotic stenosis/occlusion of the PA. These six intervention types were: PTA with plain balloon, PTA with drug-coated balloon,

stenting for dissection, stenting for residual stenosis or extensive calcification, atherectomy alone, and atherectomy combined with anti-restenotic endovascular therapy. At 5 years of follow-up, the primary patency rate of 50.7% in the PTA group was significantly lower than the primary patency rate of 56.6% in the stenting group and other groups, after adjusting for confounding factors. However, the secondary patency rates did not show a significant difference between the individual groups. (145)

In our study cohort, the mid-term (24 months) primary patency rates were similar to the primary patency rates reported in the aforementioned articles: primary patency rates were 70% in the entire patient group, 71.4% in the PTA group, and 68.9% in the stenting group. The secondary patency rate was 90.4% in the entire patient group, 90% in the PTA group, and 94.1% in the stenting group. Consistent with three of the four studies mentioned above, patency rates were not significantly different between the PTA and stenting groups (when selective stenting was not considered a loss of patency). Our slightly better primary patency rate may be due in part to the fact that all previous studies were heterogeneous in terms of the number of runoff arteries and included patients with zero or only one patent crural runoff. (136, 140) Because poor runoff has previously been identified as a predictor of restenosis, (147) our study included only patients with at least two patent crural runoff arteries.

In addition to poor runoff, other known predictors of restenosis in patients treated endosurgically for isolated PA stenosis/occlusion are: smoking, chronic limb-threatening ischemia, long lesion (>60 mm), baseline occlusion, multilevel disease, subintimal recanalization, and stent placement in the P3 segment. (51, 136, 137) In our study, restenosis occurred less frequently in patients with P1 segment stenting than in patients with P2 segment and multi-segment stenting. In the popliteal region, the vessels must adapt to the mechanical forces induced by movement (e.g., axial compression and bending). (73) Stent deployment disrupts the elastic capabilities of arteries and reduces axial compressibility, which may cause increased kinking at the marginal sections of the stents, leading to chronic vessel microtrauma, intimal injuries, hyperplasia, and restenosis. (74) Furthermore, stented PAs exhibit additional bending compared to bare arteries. During knee flexion, bare PAs are smooth C-shaped, while stented PAs are “three-shaped”, which generates increased stress both inside and at the marginal sections of the stents. (74) The mechanical forces induced by movement affect the

individual popliteal segments differently. Axial compression and bending are most pronounced behind the knee, suggesting that stents implanted in the P2 segment are exposed to greater mechanical forces than stents placed in the P1 segment. (148) Thus, patients with P1 segment stenting have a lower chance of restenosis than patients with P2 segment or multi-segment stenting.

The main limitation of our study is its retrospective nature. Additionally, SF (an important cause of restenosis) was not examined.

## 6. Conclusions

6.1. Study I (Restenosis rates in patients with ipsilateral carotid endarterectomy and contralateral carotid artery stenting)

The intra-patient comparison of CEA and CAS tilts the balance towards CAS with respect to restenosis (especially  $\geq 70\%$  restenosis).

6.2. Study II (Short- and mid-term outcomes of stenting in patients with isolated distal internal carotid artery stenosis or post-surgical restenosis)

Early complications and ISR rates of distal ICA stenting are acceptable and are not influenced by the etiology of the lesion. However, the mid-term mortality rate of the RES group is high. The lower survival is probably not due to the stenting procedure but to the more complex comorbidity profile of the RES population.

6.3. Study III (Mid-term results and predictors of restenosis in patients undergoing endovascular therapy for isolated popliteal artery steno-occlusive disease)

Mid-term patency of PA interventions is good. Stenting is not superior to PTA (if selective stenting is not considered a loss of patency). Lesions located in the P2 segment or in multiple segments are more prone to restenosis, therefore, patients undergoing stenting in these segments or undergoing PTA should be followed more closely.

## 7. Summary

The two main invasive therapeutic options for extracranial carotid artery stenosis are CEA and CAS, of which CEA remains the gold standard due to a lower rate of periprocedural neurological complications, but there is conflicting literature on long-term outcomes such as restenosis. Given the bilateral nature of ICA, it is possible to examine the rate of restenosis within the same patient (CEA on one side, CAS on the other). In our study, there was significantly more 70–90% restenosis after CEA than after CAS, especially in the later stages of follow-up; Cox regression analysis showed an HR of 1.80 in favor of CAS. The adjusted HR (1.85), which took into account smoking, hypertension, DM, calcification and echogenicity levels, lesion location, and treatment type, was barely different from the crude HR, supporting the importance of the duration of atherosclerotic risk factors.

There are many data on the short- and long-term success of CAS for extracranial ICA stenosis, but most studies have not analyzed lesions by location. We found a periprocedural neurological complication rate of 6.1% in patients who underwent CAS for isolated distal extracranial ICA stenosis. The primary patency rate was 97.2% at 6 months, 94.4% at 12 and 24 months, and 89.7% at 36 and 48 months in the atherosclerotic etiology group, and 100% during the entire follow-up period in the restenotic etiology group ( $P=0.528$ ). The mortality rate at 48 months was relatively high (61.5%) in the group with restenotic etiology, however, this is probably not related to the stenting procedure itself, but to the more complex comorbidity profile of the restenotic population.

Peripheral artery disease usually involves multiple segments, which makes it difficult to assess the short- and mid-term success of endovascular interventions in a given arterial segment because of the inflow and outflow pathologies that influence treatment outcome. We aimed to investigate the success of PTA and/or stent implantation in truly isolated PA steno-occlusive disease. Primary patency rates were not significantly different ( $P=0.629$ ) between the PTA and stenting groups. Restenosis was significantly less frequent ( $P=0.010$ ) in patients with P1 stents than in patients with P2 plus multi-segment stents. Cox regression analysis identified the lesion location as a predictor of ISR (HR, 2.54).



## 8. References

1. Menotti A, Puddu PE, Tolonen H, Kafatos A. (2023) Cardiovascular mortality in Northern and Southern European cohorts of the Seven Countries Study at 60-year follow-up. *J Cardiovasc Med (Hagerstown)*, 24: 96–104.
2. Naylor R, Rantner B, Ancetti S, de Borst GJ, De Carlo M, Halliday A, Kakkos SK, Markus HS, McCabe DJH, Sillesen H, van den Berg JC, Vega de Ceniga M, Venermo MA, Vermassen FEG, Esvs Guidelines Committee, Antoniou GA, Bastos Goncalves F, Bjorck M, Chakfe N, Coscas R, Dias NV, Dick F, Hinchliffe RJ, Kolh P, Koncar IB, Lindholt JS, Mees BME, Resch TA, Trimarchi S, Tulamo R, Twine CP, Wanhainen A, Document Reviewers, Bellmunt-Montoya S, Bulbulia R, Darling RC 3rd, Eckstein HH, Giannoukas A, Koelemay MJW, Lindström D, Schermerhorn M, Stone DH. (2023) Editor's Choice - European Society for Vascular Surgery (ESVS) 2023 Clinical Practice Guidelines on the Management of Atherosclerotic Carotid and Vertebral Artery Disease. *Eur J Vasc Endovasc Surg*, 65: 7–111.
3. Flaherty ML, Kissela B, Khoury JC, Alwell K, Moomaw CJ, Woo D, Khatri P, Ferioli S, Adeoye O, Broderick JP, Kleindorfer D. (2013) Carotid artery stenosis as a cause of stroke. *Neuroepidemiology*, 40: 36–41.
4. den Brok MG, Kuhrij LS, Roozenbeek B, van der Lugt A, Hilkens PH, Dippel DW, Nederkoorn PJ. (2020) Prevalence and risk factors of symptomatic carotid stenosis in patients with recent transient ischaemic attack or ischaemic stroke in the Netherlands. *Eur Stroke J*, 5: 271–277.
5. Piagkou M, Anagnostopoulou S, Kouladouros K, Piagkos G. (2009) Eagle's syndrome: a review of the literature. *Clin Anat*, 22: 545–558.
6. Nashnoush M, Lad M, Masood I, Singh A, Sazzad S, Bharmal S, Negussie M, Marwan M, Eskander S. (2023) Multiparametric analysis of carotid body tumours: a pictorial essay. *J Ultrasound*, 26: 553–561.

7. Bir SC, Kelley RE. (2022) Carotid atherosclerotic disease: A systematic review of pathogenesis and management. *Brain Circ*, 8: 127–136.
8. Milutinović A, Šuput D, Zorc-Pleskovič R. (2020) Pathogenesis of atherosclerosis in the tunica intima, media, and adventitia of coronary arteries: An updated review. *Bosn J Basic Med Sci*, 20: 21–30.
9. Jebari-Benslaiman S, Galicia-García U, Larrea-Sebal A, Olaetxea JR, Alloza I, Vandebroek K, Benito-Vicente A, Martín C. (2022) Pathophysiology of Atherosclerosis. *Int J Mol Sci*, 23: 3346.
10. Zhou M, Yu Y, Chen R, Liu X, Hu Y, Ma Z, Gao L, Jian W, Wang L. (2023) Wall shear stress and its role in atherosclerosis. *Front Cardiovasc Med*, 10: 1083547.
11. Tomaniak M, Katagiri Y, Modolo R, de Silva R, Khamis RY, Bourantas CV, Torii R, Wentzel JJ, Gijzen FJH, van Soest G, Stone PH, West NEJ, Maehara A, Lerman A, van der Steen AFW, Lüscher TF, Virmani R, Koenig W, Stone GW, Muller JE, Wijns W, Serruys PW, Onuma Y. (2020) Vulnerable plaques and patients: state-of-the-art. *Eur Heart J*, 41: 2997–3004.
12. Singh RB, Mengi SA, Xu YJ, Arneja AS, Dhalla NS. (2002) Pathogenesis of atherosclerosis: A multifactorial process. *Exp Clin Cardiol*, 7: 40–53.
13. Zain MA, Jamil RT, Siddiqui WJ. (2023) Neointimal Hyperplasia. In: *StatPearls [Internet]*. Treasure Island (FL): StatPearls Publishing, 2023 Jan–.
14. Otsuka F, Byrne RA, Yahagi K, Mori H, Ladich E, Fowler DR, Kutys R, Xhepa E, Kastrati A, Virmani R, Joner M. (2015) Neoatherosclerosis: overview of histopathologic findings and implications for intravascular imaging assessment. *Eur Heart J*, 36:2147–2159.

15. Yang EH, Marmagkiolis K, Balanescu DV, Hakeem A, Donisan T, Finch W, Virmani R, Herrman J, Cilingiroglu M, Grines CL, Toutouzas K, Iliescu C. (2021) Radiation-Induced Vascular Disease-A State-of-the-Art Review. *Front Cardiovasc Med*, 8: 652761.
16. Cardounell SZ, Gonzalez L. (2023) Carotid Artery Fibromuscular Dysplasia. In: *StatPearls [Internet]*. Treasure Island (FL): StatPearls Publishing, 2023 Jan–.
17. Gulati A, Bagga A. (2010) Large vessel vasculitis. *Pediatr Nephrol*, 25: 1037–1048.
18. Tsao CW, Vasan RS. (2015) Cohort Profile: The Framingham Heart Study (FHS): overview of milestones in cardiovascular epidemiology. *Int J Epidemiol*, 44: 1800–1813.
19. Ismail A, Ravipati S, Gonzalez-Hernandez D, Mahmood H, Imran A, Munoz EJ, Naeem S, Abdin ZU, Siddiqui HF. (2023) Carotid Artery Stenosis: A Look Into the Diagnostic and Management Strategies, and Related Complications. *Cureus*, 15: e38794.
20. McColgan P, Bentley P, McCarron M, Sharma P. (2012) Evaluation of the clinical utility of a carotid bruit. *QJM*, 105: 1171-1177.
21. Cassola N, Baptista-Silva JC, Nakano LC, Flumignan CD, Sesso R, Vasconcelos V, Carvas Junior N, Flumignan RL. (2022) Duplex ultrasound for diagnosing symptomatic carotid stenosis in the extracranial segments. *Cochrane Database Syst Rev*, 7: CD013172.
22. Saba L, Loewe C, Weikert T, Williams MC, Galea N, Budde RPJ, Vliegenthart R, Velthuis BK, Francone M, Bremerich J, Natale L, Nikolaou K, Dacher JN, Peebles C, Caobelli F, Redheuil A, Dewey M, Kreitner KF, Salgado R. (2023) State-of-the-art CT and MR imaging and assessment of atherosclerotic carotid artery disease: the reporting-

a consensus document by the European Society of Cardiovascular Radiology (ESCR). *Eur Radiol*, 33: 1088-1101.

23. Peret A, Romero-Sanchez G, Dabiri M, McNally JS, Johnson KM, Mossa-Basha M, Eisenmenger LB. (2023) MR Angiography of Extracranial Carotid Disease. *Magn Reson Imaging Clin N Am*, 31: 395–411.

24. Mizoshiri T, Yoshida M, Oda S, Tsumagari S, Nakaura T, Harada K, Ikeda O. (2021) Non-contrast mDixon MR angiography of the neck: Comparison with time-of-flight MR angiography in normal subjects. *Medicine (Baltimore)*, 100: e28351.

25. Navot B, Hecht EM, Lim RP, Edelman RR, Koktzoglou I. (2021) MR Angiography Series: Fundamentals of Non-Contrast-enhanced MR Angiography. *Radiographics*, 41: E157-E158.

26. Kim HW, Regenhardt RW, D'Amato SA, Nahhas MI, Dmytriw AA, Hirsch JA, Silverman SB, Martinez-Gutierrez JC. (2023) Asymptomatic carotid artery stenosis: a summary of current state of evidence for revascularization and emerging high-risk features. *J Neurointerv Surg*, 15: 717–722.

27. Easton JD. (2014) History of carotid endarterectomy then and now: personal perspective. *Stroke*, 45: e101-103.

28. DaCosta M, Tadi P, Surowiec SM. (2023) Carotid Endarterectomy. In: *StatPearls [Internet]*. Treasure Island (FL): StatPearls Publishing, 2023 Jan–.

29. Spacek M, Veselka J. (2015) Carotid Artery Stenting-Historical Context, Trends, and Innovations. *Int J Angiol*, 24: 205–209.

30. Calvet D, Mas JL, Algra A, Becquemin JP, Bonati LH, Dobson J, Fraedrich G, Jansen O, Mali WP, Ringleb PA, Chatellier G, Brown MM, Calvet D, Mas JL, Algra A, Becquemin JP, Bonati LH, Dobson J, Fraedrich G, Jansen O, Mali WP, Ringleb PA,

Chatellier G, Brown MM, Algra A, Becquemin JP, Chatellier G, Mas JL, Fraedrich G, Ringleb PA, Jansen O, Brown MM; Carotid Stenting Trialists' Collaboration. (2014) Carotid stenting: is there an operator effect? A pooled analysis from the carotid stenting trialists' collaboration. *Stroke*, 45: 527–532.

31. Halliday A, Bulbulia R, Bonati LH, Chester J, Craddock-Bamford A, Peto R, Pan H; ACST-2 Collaborative Group. (2021) Second asymptomatic carotid surgery trial (ACST-2): a randomised comparison of carotid artery stenting versus carotid endarterectomy. *Lancet*, 398: 1065–1073.

32. Payne DA, Twigg MW, Hayes PD, Naylor AR. (2010) Antiplatelet agents and risk factors for bleeding postcarotid endarterectomy. *Ann Vasc Surg*, 24: 900–907.

33. Müller MD, Lyrer P, Brown MM, Bonati LH. (2020) Carotid artery stenting versus endarterectomy for treatment of carotid artery stenosis. *Cochrane Database Syst Rev*, 2: CD000515.

34. Kakisis JD, Antonopoulos CN, Mantas G, Moulakakis KG, Sfyroeras G, Geroulakos G. (2017) Cranial Nerve Injury After Carotid Endarterectomy: Incidence, Risk Factors, and Time Trends. *Eur J Vasc Endovasc Surg*, 53: 320–335.

35. Lin YH, Liu HM. (2020) Update on cerebral hyperperfusion syndrome. *J Neurointerv Surg*, 12: 788–793.

36. Naylor AR, Evans J, Thompson MM, London NJ, Abbott RJ, Cherryman G, Bell PR. (2003) Seizures after carotid endarterectomy: hyperperfusion, dysautoregulation or hypertensive encephalopathy? *Eur J Vasc Endovasc Surg*, 26: 39–44.

37. Chiu TM, Chu SY. (2022) Hypersensitivity Reactions to Iodinated Contrast Media. *Biomedicines*, 10: 1036.

38. Sarkadi H, Csöre J, Veres DS, Szegedi N, Molnár L, Gellér L, Bérczi V, Dósa E. (2021) Incidence of and predisposing factors for pseudoaneurysm formation in a high-volume cardiovascular center. *PLoS One*, 16: e0256317.
39. Sajnani N, Bogart DB. (2013) Retroperitoneal hemorrhage as a complication of percutaneous intervention: report of 2 cases and review of the literature. *Open Cardiovasc Med J*, 7: 16–22.
40. Nazari P, Golnari P, Hurley MC, Shaibani A, Ansari SA, Potts MB, Jahromi BS. (2021) Carotid Stenting without Embolic Protection Increases Major Adverse Events: Analysis of the National Surgical Quality Improvement Program. *AJNR Am J Neuroradiol*, 42: 1264–1269.
41. Abou-Chebl A, Reginelli J, Bajzer CT, Yadav JS. (2007) Intensive treatment of hypertension decreases the risk of hyperperfusion and intracerebral hemorrhage following carotid artery stenting. *Catheter Cardiovasc Interv*, 69: 690–696.
42. Oszkinis G, Pukacki F, Juszkat R, Weigele JB, Gabriel M, Krasinski Z, Zieliński M, Krejza J. (2007) Restenosis after carotid endarterectomy: incidence and endovascular management. *Interv Neuroradiol*, 13: 345–352.
43. Clagett GP. (1989) Intimal hyperplasia and restenosis after carotid endarterectomy. *J Vasc Surg*, 10: 577–579.
44. Chen D, Ma L, Tham EL, Maresh S, Lechler RI, McVey JH, Dorling A. (2013) Fibrocytes mediate intimal hyperplasia post-vascular injury and are regulated by two tissue factor-dependent mechanisms. *J Thromb Haemost*, 11: 963–974.
45. Déglise S, Bechelli C, Allagnat F. (2023) Vascular smooth muscle cells in intimal hyperplasia, an update. *Front Physiol*, 13: 1081881.

46. Kumar R, Batchelder A, Saratzis A, AbuRahma AF, Ringleb P, Lal BK, Mas JL, Steinbauer M, Naylor AR. (2017) Restenosis after Carotid Interventions and Its Relationship with Recurrent Ipsilateral Stroke: A Systematic Review and Meta-analysis. *Eur J Vasc Endovasc Surg*, 53: 766–775.
47. Hirschberg K, Dosa E, Huttl K, Selmeçi L, Nemes B, Szabo A, Merkely B, Acsady G, Entz L. (2009) Early restenosis after eversion carotid endarterectomy versus carotid stenting: a single-centre retrospective study. *J Cardiovasc Surg (Torino)*, 50: 655–663.
48. Yan D, Tang X, Shi Z, Wang L, Lin C, Guo D, Fu W. (2019) Perioperative and Follow-up Results of Carotid Artery Stenting and Carotid Endarterectomy in Patients with Carotid Near-Occlusion. *Ann Vasc Surg*, 59: 21–27.
49. Rizwan M, Aridi HD, Dang T, Alshwaily W, Nejm B, Malas MB. (2019) Long-Term Outcomes of Carotid Endarterectomy and Carotid Artery Stenting When Performed by a Single Vascular Surgeon. *Vasc Endovascular Surg*, 53: 216–223.
50. Aboyans V, Ricco JB, Bartelink MEL, Bjorck M, Brodmann M, Cohnert T, Collet JP, Czerny M, De Carlo M, Debusa S, Espinola-Klein C, Kahan T, Kownator S, Mazzolai L, Naylor AR, Roffi M, Rotherb J, Sprynger M, Tendera M, Tepe G, Venermoa M, Vlachopoulos C, Desormais I. (2018) 2017 ESC Guidelines on the Diagnosis and Treatment of Peripheral Arterial Diseases, in collaboration with the European Society for Vascular Surgery (ESVS). *Rev Esp Cardiol (Engl Ed)*, 71: 111.
51. Spiliopoulos S, Kitrou P, Galanakis N, Papadimitos P, Katsanos K, Konstantos C, Palialexis K, Reppas L, Kehagias E, Karnabatidis D, Brountzos E, Tsetis D. (2018) Incidence and Endovascular Treatment of Isolated Atherosclerotic Popliteal Artery Disease: Outcomes from the IPAD Multicenter Study. *Cardiovasc Intervent Radiol*, 41: 1481–1487.
52. Wright LB, Matchett WJ, Cruz CP, James CA, Culp WC, Eidt JF, McCowan TC. (2004) Popliteal artery disease: diagnosis and treatment. *Radiographics*, 24: 467–479.

53. Okazaki J, Guntani A, Homma K, Kyuragi R, Kawakubo E, Maehara Y. (2011) Fibromuscular dysplasia of the lower extremities. *Ann Vasc Dis*, 4: 143–149.
54. McDermott MM, Guralnik JM, Ferrucci L, Tian L, Liu K, Liao Y, Green D, Sufit R, Hoff F, Nishida T, Sharma L, Pearce WH, Schneider JR, Criqui MH. (2008) Asymptomatic peripheral arterial disease is associated with more adverse lower extremity characteristics than intermittent claudication. *Circulation*, 117: 2484–2491.
55. Hardman RL, Jazaeri O, Yi J, Smith M, Gupta R. (2014) Overview of classification systems in peripheral artery disease. *Semin Intervent Radiol*, 31: 378–388.
56. Csöre J, Suhai FI, Gyánó M, Pataki AA, Juhász G, Vecsey-Nagy M, Pál D, Fontanini DM, Bérczi Á, Csobay-Novák C. (2022) Quiescent-Interval Single-Shot Magnetic Resonance Angiography May Outperform Carbon-Dioxide Digital Subtraction Angiography in Chronic Lower Extremity Peripheral Arterial Disease. *J Clin Med*, 11: 4485.
57. Csore J, Drake M, Roy TL. (2023) Peripheral arterial disease treatment planning using noninvasive and invasive imaging methods. *J Vasc Surg Cases Innov Tech*, 9: 101263.
58. Baram A, Taha AY, Muhamed RG. (2023) Outcomes of Popliteal Endarterectomy and Infrapopliteal Angioplasty for Short Atherosclerotic Popliteal Artery Occlusion: Single-Center Case Series. *Ann Vasc Surg*, 88: 145–153.
59. Hingorani AP, Ascher E, Marks NA, Jung D, Ignatiev I, Hingorani A. (2016) Interposition bypass of the popliteal artery using the popliteal vein in 1943. *J Vasc Surg*, 63: 1400–1403.
60. Good DW, Al Chalabi H, Hameed F, Egan B, Tierney S, Feeley TM. (2011) Popliteo-pedal bypass surgery for critical limb ischemia. *Ir J Med Sci*, 180: 829–835.



61. Alonso AG, Kobzeva-Herzog A, Siracuse JJ. (2023) Alternative access for peripheral vascular interventions. *J Vasc Surg Cases Innov Tech*, 9: 101232.
62. Sheeran D, Wilkins LR. (2018) Long Chronic Total Occlusions: Revascularization Strategies. *Semin Intervent Radiol*, 35: 469–476.
63. Bakker O, Bausback Y, Wittig T, Branzan D, Steiner S, Fischer A, Konert M, Düsing S, Banning-Eichenseer U, Scheinert D, Schmidt A. (2022) First Experience With The GoBack-Catheter For Successful Crossing of Complex Chronic Total Occlusions in Lower Limb Arteries. *J Endovasc Ther*, 29: 798–807.
64. Cao J, Lu HT, Wei LM, Zhao JG, Zhu YQ. (2016) Rendezvous technique for recanalization of long-segmental chronic total occlusion above the knee following unsuccessful standard angioplasty. *Vascular*, 24: 157–165.
65. Boc A, Eržen B, Perme RL, Boc V. (2022) Bailout stenting in femoropopliteal arterial segment. *Vasa*, 51: 13–18.
66. Kassimis G, Didagelos M, De Maria GL, Kontogiannis N, Karamasis GV, Katsikis A, Sularz A, Karvounis H, Kanonidis I, Krokidis M, Ziakas A, Banning AP. (2020) Shockwave Intravascular Lithotripsy for the Treatment of Severe Vascular Calcification. *Angiology*, 71: 677–688.
67. Giannopoulos S, Mustapha J, Gray WA, Ansel G, Adams G, Secemsky EA, Armstrong EJ. (2021) Three-Year Outcomes From the LIBERTY 360 Study of Endovascular Interventions for Peripheral Artery Disease Stratified by Rutherford Category. *J Endovasc Ther*, 28: 262–274.
68. Dake MD, Ansel GM, Bosiers M, Holden A, Iida O, Jaff MR, Lottes AE, O'Leary EE, Saunders AT, Schermerhorn M, Yokoi H, Zeller T. (2020) Paclitaxel-Coated Zilver PTX Drug-Eluting Stent Treatment Does Not Result in Increased Long-Term All-Cause Mortality Compared to Uncoated Devices. *Cardiovasc Intervent Radiol*, 43: 8–19.

69. Ochoa Char CI, Shebl F, Sumpio B, Dardik A, Indes J, Sarac T. (2017) Distal embolization during lower extremity endovascular interventions. *J Vasc Surg*, 66: 143–150.

70. Baerlocher MO, Kennedy SA, Rajebi MR, Baerlocher FJ, Misra S, Liu D, Nikolic B. (2015) Meta-analysis of drug-eluting balloon angioplasty and drug-eluting stent placement for infrainguinal peripheral arterial disease. *J Vasc Interv Radiol*, 26: 459–473.e4

71. Daher MA, Lopez GE, Duarte PV. (2020) Stents in the femoropopliteal territory: prevalence of fractures and their consequences. *Rev Col Bras Cir*, 47: e20202481.

72. Yoshioka N, Tokuda T, Koyama A, Yamada T, Nishikawa R, Shimamura K, Takagi K, Morita Y, Tanaka A, Ishii H, Morishima I, Murohara T; on the ASIGARU PAD investigators. (2022) Clinical outcomes and predictors of restenosis in patients with femoropopliteal artery disease treated using polymer-coated paclitaxel-eluting stents or drug-coated balloons. *Heart Vessels*, 37: 555–566.

73. Poulson W, Kamenskiy A, Seas A, Deegan P, Lomneth C, MacTaggart J. (2018) Limb flexion-induced axial compression and bending in human femoropopliteal artery segments. *J Vasc Surg*, 67: 607–613.

74. Smouse HB, Nikanorov A, LaFlash D. (2005) Biomechanical forces in the femoropopliteal arterial segment. *Endovasc Today*, 4: 60–66.

75. Chang IS, Chee HK, Park SW, Yun IJ, Hwang JJ, Lee SA, Kim JS, Chang SH, Jung HG. (2011) The primary patency and fracture rates of self-expandable nitinol stents placed in the popliteal arteries, especially in the P2 and P3 segments, in Korean patients. *Korean J Radiol*, 12: 203–209.

76. Fortier A, Gullapalli V, Mirshams RA. (2014) Review of biomechanical studies of arteries and their effect on stent performance. *IJC Heart & Vessels*, 4: 12–18.

77. Scheinert D, Scheinert S, Sax J, Piorkowski C, Bräunlich S, Ulrich M, Biamino G, Schmidt A. (2005) Prevalence and clinical impact of stent fractures after femoropopliteal stenting. *J Am Coll Cardiol*, 45: 312–315.
78. Davaine JM, Quérat J, Guyomarch B, Brennan MÁ, Costargent A, Chaillou P, Patra P, Gouëffic Y. (2013) Incidence and the clinical impact of stent fractures after primary stenting for TASC C and D femoropopliteal lesions at 1 year. *Eur J Vasc Endovasc Surg*, 46: 201–212.
79. Trabattoni D, Agrifoglio M, Cappai A, Bartorelli AL. (2010) Incidence of stent fractures and patency after femoropopliteal stenting with the nitinol self-expandable SMART stent: a single-center study. *J Cardiovasc Med (Hagerstown)*, 11: 678–682.
80. Sarkadi H, Bérczi V, Kollár A, Kiss D, Jakabfi P, Végh EM, Nemes B, Merkely B, Hüttl K, Dósa E. (2015) Safety, clinical outcome, and fracture rate of femoropopliteal stenting using a 4F compatible delivery system. *Eur J Vasc Endovasc Surg*, 49: 199–204.
81. Rocha-Singh KJ, Jaff MR, Crabtree TR, Bloch DA, Ansel G; VIVA Physicians, Inc. (2007) Performance goals and endpoint assessments for clinical trials of femoropopliteal bare nitinol stents in patients with symptomatic peripheral arterial disease. *Catheter Cardiovasc Interv*, 69: 910–919.
82. Martelli E, Pataconi D, DE Vivo G, Ippoliti A. (2016) Conventional carotid endarterectomy versus stenting: comparison of restenosis rates in arteries with identical predisposing factors. *J Cardiovasc Surg (Torino)*, 57: 503–509.
83. De Borst GJ, Hellings WE, Ackerstaff RG, Moll FL; Antonius Carotid Endarterectomy, Angioplasty and Stenting Study Group. (2006) Inpatient comparison of restenosis between carotid artery angioplasty with stenting and carotid endarterectomy. *J Cardiovasc Surg (Torino)*, 47: 49–54.

84. Xu RW, Liu P, Fan XQ, Wang Q, Zhang JB, Ye ZD. (2016) Feasibility and Safety of Simultaneous Carotid Endarterectomy and Carotid Stenting for Bilateral Carotid Stenosis: A Single-Center Experience using a Hybrid Procedure. *Ann Vasc Surg*, 33: 138–143.
85. Ciccone MM, Scicchitano P, Cortese F, Gesualdo M, Zito A, Carbonara R, Dentamaro I, Pulli R, Salerno C, Impedovo G, Marinazzo D, Angiletta D, Guido D, Regina G. (2017) Carotid stenting versus endarterectomy in the same patient: A "direct" comparison. *Vascular*, 25: 290–298.
86. Liapis CD, Bell PR, Mikhailidis D, Sivenius J, Nicolaides A, Fernandes e Fernandes J, Biasi G, Norgren L; ESVS Guidelines Collaborators. (2009) ESVS guidelines. Invasive treatment for carotid stenosis: indications, techniques. *Eur J Vasc Endovasc Surg*, 37: 1–19.
87. Moore WS, Barnett HJ, Beebe HG, Bernstein EF, Brener BJ, Brott T, Caplan LR, Day A, Goldstone J, Hobson RW 2nd. (1995) Guidelines for carotid endarterectomy. A multidisciplinary consensus statement from the ad hoc Committee, American Heart Association. *Stroke*, 26: 188–201.
88. Eckstein HH. (2018) European Society for Vascular Surgery Guidelines on the Management of Atherosclerotic Carotid and Vertebral Artery Disease. *Eur J Vasc Endovasc Surg*, 55: 1–2.
89. Timaran CH, McKinsey JF, Schneider PA, Littooy F. (2011) Reporting standards for carotid interventions from the Society for Vascular Surgery. *J Vasc Surg*, 53: 1679–1695.
90. Ouriel K, Yadav J, Green RM. (2004) Standards of practice: carotid angioplasty and stenting. *J Vasc Surg*, 39: 916–917.

91. AbuRahma AF, Stone P, Deem S, Dean LS, Keiffer T, Deem E. (2009) Proposed duplex velocity criteria for carotid restenosis following carotid endarterectomy with patch closure. *J Vasc Surg*, 50: 286-291, 291.e1-2; discussion 291.
92. Stanziale SF, Wholey MH, Boules TN, Selzer F, Makaroun MS. (2005) Determining in-stent stenosis of carotid arteries by duplex ultrasound criteria. *J Endovasc Ther*, 12: 346–353.
93. Vértes M, Nguyen DT, Székely G, Bérczi Á, Dósa E. (2020) Middle and Distal Common Carotid Artery Stenting: Long-Term Patency Rates and Risk Factors for In-Stent Restenosis. *Cardiovasc Intervent Radiol*, 43: 1134–1142.
94. Ferguson GG, Eliasziw M, Barr HW, Clagett GP, Barnes RW, Wallace MC, Taylor DW, Haynes RB, Finan JW, Hachinski VC, Barnett HJ. (1999) The North American Symptomatic Carotid Endarterectomy Trial : surgical results in 1415 patients. *Stroke*, 30: 1751–1758.
95. Bonati LH, Ederle J, Dobson J, Engelter S, Featherstone RL, Gaines PA, Beard JD, Venables GS, Markus HS, Clifton A, Sandercock P, Brown MM; CAVATAS Investigators. (2014) Length of carotid stenosis predicts peri-procedural stroke or death and restenosis in patients randomized to endovascular treatment or endarterectomy. *Int J Stroke*, 9: 297–305.
96. Woodcock RJ Jr, Goldstein JH, Kallmes DF, Cloft HJ, Phillips CD. (1999) Angiographic correlation of CT calcification in the carotid siphon. *AJNR Am J Neuroradiol*, 20: 495–499.
97. Ariyoshi K, Okuya S, Kunitsugu I, Matsunaga K, Nagao Y, Nomiyama R, Takeda K, Tanizawa Y. (2015) Ultrasound analysis of gray-scale median value of carotid plaques is a useful reference index for cerebro-cardiovascular events in patients with type 2 diabetes. *J Diabetes Investig*, 6: 91–97.

98. Lee JD, Ryu SJ, Chang YJ, Hsu KC, Chen YC, Huang YC, Lee M, Hsiao MC, Lee TH. (2007) Carotid ultrasound criteria for detecting intracranial carotid stenosis. *Eur Neurol*, 57: 156–160.
99. Dósa E, Hirschberg K, Apor A, Járányi Z, Entz L, Acsády G, Hüttl K. (2010) Echolucent or predominantly echolucent femoral plaques predict early restenosis after eversion carotid endarterectomy. *J Vasc Surg*, 51: 345–350.
100. Hüttl AB, Hüttl A, Vértes M, Nguyen DT, Bérczi Á, Hüttl K, Dósa E. (2019) The presence of long and heavily calcified lesions predisposes for fracture in patients undergoing stenting of the first part of the subclavian artery. *J Vasc Surg*, 70: 1146–1154.e1.
101. Stoner MC, Calligaro KD, Chaer RA, Dietzek AM, Farber A, Guzman RJ, Hamdan AD, Landry GJ, Yamaguchi DJ; Society for Vascular Surgery. (2016) Reporting standards of the Society for Vascular Surgery for endovascular treatment of chronic lower extremity peripheral artery disease. *J Vasc Surg*, 64: e1-e21.
102. Kruse RR, Doomernik DE, Maltha KV, Kooloos JGM, Kozicz TL, Reijnen MMPJ. (2017) Collateral artery pathways of the femoral and popliteal artery. *J Surg Res*, 211: 45–52.
103. Doris I, Dobranowski J, Franchetto AA, Jaeschke R. (1993) The relevance of detecting carotid artery calcification on plain radiograph. *Stroke*, 24: 1330–1334.
104. Markovic DM, Davidovic LB, Cvetkovic DD, Maksimovic ZV, Markovic DZ, Jadranin DB. (2008) Single-center prospective, randomized analysis of conventional and eversion carotid endarterectomy. *J Cardiovasc Surg (Torino)*, 49: 619–625.
105. de Borst GJ, Ackerstaff RG, de Vries JP, vd Pavoordt ED, Vos JA, Overtom TT, Moll FL. (2007) Carotid angioplasty and stenting for postendarterectomy stenosis: long-term follow-up. *J Vasc Surg*, 45: 118–1123.

106. Mas JL, Arquizan C, Calvet D, Viguiet A, Albucher JF, Piquet P, Garnier P, Viader F, Giroud M, Hosseini H, Hinzelin G, Favrole P, Hénon H, Neau JP, Ducrocq X, Padovani R, Milandre L, Rouanet F, Wolff V, Saudeau D, Mahagne MH, Sablot D, Amarenco P, Larrue V, Beyssen B, Leys D, Moulin T, Lièvre M, Chatellier G; EVA-3S Investigators. (2014) Long-term follow-up study of endarterectomy versus angioplasty in patients with symptomatic severe carotid stenosis trial. *Stroke*, 45: 2750–2756.

107. Steinbauer MG, Pfister K, Greindl M, Schlachetzki F, Borisch I, Schuirer G, Feuerbach S, Kasprzak PM. (2008) Alert for increased long-term follow-up after carotid artery stenting: results of a prospective, randomized, single-center trial of carotid artery stenting vs carotid endarterectomy. *J Vasc Surg*, 48: 93–98.

108. Bonati LH, Gregson J, Dobson J, McCabe DJH, Nederkoorn PJ, van der Worp HB, de Borst GJ, Richards T, Cleveland T, Müller MD, Wolff T, Engelter ST, Lyrer PA, Brown MM; International Carotid Stenting Study investigators. (2018) Restenosis and risk of stroke after stenting or endarterectomy for symptomatic carotid stenosis in the International Carotid Stenting Study (ICSS): secondary analysis of a randomised trial. *Lancet Neurol*, 17: 587–596.

109. Hoffmann A, Engelter S, Taschner C, Mendelowitsch A, Merlo A, Radue EW. (2008) Carotid artery stenting versus carotid endarterectomy – a prospective randomized controlled single-centre trial with long-term follow-up (BACASS). *Schweizer Arch für Neurol und Psychiatr*, 159: 84–89.

110. Texakalidis P, Giannopoulos S, Jonnalagadda AK, Kokkinidis DG, Machinis T, Reavey-Cantwell J, Armstrong EJ, Jabbour P. (2018) Carotid Artery Endarterectomy versus Carotid Artery Stenting for Restenosis After Carotid Artery Endarterectomy: A Systematic Review and Meta-Analysis. *World Neurosurg*, 115: 421–429.e1.

111. AbuRahma AF, Abu-Halimah S, Bensenhaver J, Nanjundappa A, Stone PA, Dean LS, Keiffer T, Emmett M, Tarakji M, AbuRahma Z. (2009) Primary carotid artery

stenting versus carotid artery stenting for postcarotid endarterectomy stenosis. *J Vasc Surg*, 50: 1031–1039.

112. White RA, Sicard GA, Zwolak RM, Sidawy AN, Schermerhorn ML, Shackelton RJ, Siami FS; SVS Outcomes Committee. (2010) Society of vascular surgery vascular registry comparison of carotid artery stenting outcomes for atherosclerotic vs nonatherosclerotic carotid artery disease. *J Vasc Surg*, 51: 1116–1123.

113. Cuadra S, Hobson RW, Lal BK, Goldstein J, Chakhtoura E, Jamil Z. (2009) Outcome of carotid artery stenting for primary versus restenotic lesions. *Ann Vasc Surg*, 23: 330–334.

114. Kahlberg A, Ardita V, Spertino A, Mascia D, Bertoglio L, Baccellieri D, Lembo R, Melissano G, Chiesa R. (2021) Propensity-Matched Comparison for Carotid Artery Stenting in Primary Stenosis Versus after Carotid Endarterectomy Restenosis. *Ann Vasc Surg*, 70: 332–340.

115. Hynes BG, Kennedy KF, Ruggiero NJ 2nd, Kiernan TJ, Margey RJ, Rosenfield K, Garasic JM. (2014) Carotid artery stenting for recurrent carotid artery restenosis after previous ipsilateral carotid artery endarterectomy or stenting: a report from the National Cardiovascular Data Registry. *JACC Cardiovasc Interv*, 7: 180–186.

116. Mousa AY, AbuRahma AF, Bozzay J, Broce M, Kali M, Yacoub M, Stone P, Bates MC. (2015) Long-term Comparative Outcomes of Carotid Artery Stenting Following Previous Carotid Endarterectomy vs De Novo Lesions. *J Endovasc Ther*, 22: 449–456.

117. Arhuidese IJ, Rizwan M, Nejjim B, Malas M. (2017) Outcomes of Primary and Secondary Carotid Artery Stenting. *Stroke*, 48: 3086–3092.

118. Fokkema M, de Borst GJ, Nolan BW, Lo RC, Cambria RA, Powell RJ, Moll FL, Schermerhorn ML; Vascular Study Group of New England. (2014) Carotid stenting



versus endarterectomy in patients undergoing reintervention after prior carotid endarterectomy. *J Vasc Surg*, 59: 8-15.e1-2.

119. Tanaskovic S, Sagic D, Radak D, Antonic Z, Kovacevic V, Vukovic M, Aleksic N, Radak S, Nenezic D, Cvetkovic S, Isenovic E, Vucurevic G, Lozuk B, Babic A, Babic S, Matic P, Gajin P, Unic-Stojanovic D, Ilijevski N. (2023) Carotid Restenosis Rate After Stenting for Primary Lesions Versus Restenosis After Endarterectomy With Creation of Risk Index. *J Endovasc Ther*, 30: 580–591.

120. Huibers AE, Westerink J, de Vries EE, Hoskam A, den Ruijter HM, Moll FL, de Borst GJ. (2018) Editor's Choice - Cerebral Hyperperfusion Syndrome After Carotid Artery Stenting: A Systematic Review and Meta-analysis. *Eur J Vasc Endovasc Surg*, 56: 322–333.

121. Farooq MU, Goshgarian C, Min J, Gorelick PB. (2016) Pathophysiology and management of reperfusion injury and hyperperfusion syndrome after carotid endarterectomy and carotid artery stenting. *Exp Transl Stroke Med*, 8: 7.

122. Liu CW, Liu B, Ye W, Wu WW, Li YJ, Zheng YH. (2009) [Carotid endarterectomy versus carotid stenting: a prospective randomized trial]. *Zhonghua Wai Ke Za Zhi*, 47: 267–270.

123. Eckstein HH, Ringleb P, Allenberg JR, Berger J, Fraedrich G, Hacke W, Hennerici M, Stingele R, Fiehler J, Zeumer H, Jansen O. (2008) Results of the Stent-Protected Angioplasty versus Carotid Endarterectomy (SPACE) study to treat symptomatic stenoses at 2 years: a multinational, prospective, randomised trial. *Lancet Neurol*, 7: 893–902.

124. Brott TG, Howard G, Roubin GS, Meschia JF, Mackey A, Brooks W, Moore WS, Hill MD, Mantese VA, Clark WM, Timaran CH, Heck D, Leimgruber PP, Sheffet AJ, Howard VJ, Chaturvedi S, Lal BK, Voeks JH, Hobson RW 2nd; CREST Investigators.

(2016) Long-Term Results of Stenting versus Endarterectomy for Carotid-Artery Stenosis. *N Engl J Med*, 374: 1021–1031.

125. Wang P, Liang C, Du J, Li J. (2013) Effects of carotid endarterectomy and carotid artery stenting on high-risk carotid stenosis patients. *Pak J Med Sci*, 29: 1315–1318.

126. Mannheim D, Karmeli R. (2017) A prospective randomized trial comparing endarterectomy to stenting in severe asymptomatic carotid stenosis. *J Cardiovasc Surg (Torino)*, 58: 814–817.

127. AbuRahma AF, Abu-Halimah S, Hass SM, Nanjundappa A, Stone PA, Mousa A, Lough E, Dean LS. (2010) Carotid artery stenting outcomes are equivalent to carotid endarterectomy outcomes for patients with post-carotid endarterectomy stenosis. *J Vasc Surg*, 52: 1180–1187.

128. Antonello M, Deriu GP, Frigatti P, Amistà P, Lepidi S, Stramanà R, Battocchio P, Dall'Antonia A, Grego F. (2008) Does the type of carotid artery closure influence the management of recurrent carotid artery stenosis? Results of a 6-year prospective comparative study. *Surgery*, 143: 51–57.

129. Dorigo W, Pulli R, Fargion A, Pratesi G, Angiletta D, Aletto I, Alessi Innocenti A, Pratesi C. (2013) Comparison of open and endovascular treatments of post-carotid endarterectomy restenosis. *Eur J Vasc Endovasc Surg*, 45: 437–442.

130. Marques de Marino P, Martinez Lopez I, Hernandez Mateo MM, Cernuda Artero I, Cabrero Fernandez M, Reina Gutierrez MT, Serrano Hernando FJ. (2016) Open Versus Endovascular Treatment for Patients with Post-Carotid Endarterectomy Restenosis: Early and Long-term Results. *Ann Vasc Surg*, 36: 159–165.

131. Rinaldo L, Bhargav AG, Arnold Fiebelkorn CE, Lanzino G. (2020) Long-Term Mortality After Carotid Stenting. *World Neurosurg*, 141: e589–e599.

132. Wen L, Wang S, Liu L, Chen L, Geng J, Kuang L, Qian G, Su J, Chen K, Zhou Z. (2018) The Long-Term Efficacy and Safety of Carotid Artery Stenting among the Elderly: A Single-Center Study in China. *Behav Neurol*, 2018: 4707104.
133. Stavroulakis K, Schwindt A, Torsello G, Stachmann A, Hericks C, Bosiers MJ, Beropoulos E, Stahlhoff S, Bisdas T. (2017) Directional Atherectomy With Antirestenotic Therapy vs Drug-Coated Balloon Angioplasty Alone for Isolated Popliteal Artery Lesions. *J Endovasc Ther*, 24: 181–188.
134. Elens M, Verhelst R, Mastrobuoni S, Bosiers MJ, Possoz J, Lacroix V, Astarci P. (2019) Balloon Angioplasty Versus Bailout Stenting for Isolated Chronic Total Occlusions in the Popliteal Artery. *Vasc Endovascular Surg*, 53: 126–131.
135. Scheinert D, Werner M, Scheinert S, Paetzold A, Banning-Eichenseer U, Piorkowski M, Ulrich M, Bausback Y, Bräunlich S, Schmidt A. (2013) Treatment of complex atherosclerotic popliteal artery disease with a new self-expanding interwoven nitinol stent: 12-month results of the Leipzig SUPERA popliteal artery stent registry. *JACC Cardiovasc Interv*, 6: 65–71.
136. Soga Y, Tomoi Y, Sato K, Iida O, Yokoi H. (2013) Clinical outcome after endovascular treatment for isolated common femoral and popliteal artery disease. *Cardiovasc Interv Ther*, 28: 250–257.
137. Cui C, Huang X, Liu X, Li W, Lu X, Lu M, Jiang M, Yin M. (2017) Endovascular treatment of atherosclerotic popliteal artery disease based on dynamic angiography findings. *J Vasc Surg*, 65: 82–90.
138. Siracuse JJ, Gill HL, Cassidy SP, Messina MD, Catz D, Egorova N, Parrack I, McKinsey JF. (2014) Endovascular treatment of lesions in the below-knee popliteal artery. *J Vasc Surg*, 60: 356–361.

139. Goltz JP, Ritter CO, Kellersmann R, Klein D, Hahn D, Kickuth R. (2012) Endovascular treatment of popliteal artery segments P1 and P2 in patients with critical limb ischemia: initial experience using a helical nitinol stent with increased radial force. *J Endovasc Ther*, 19: 450–456.
140. León LR Jr, Dieter RS, Gadd CL, Ranellone E, Mills JL Sr, Montero-Baker MF, Gruessner AC, Pacanowski JP Jr. (2013) Preliminary results of the initial United States experience with the Supera woven nitinol stent in the popliteal artery. *J Vasc Surg*, 57: 1014–1022.
141. Peidro J, Boufi M, Loundou Dieudonné A, Hartung O, Dona B, Vernet F, Alimi Y. (2015) Atheromatous occlusive lesions of the popliteal artery treated with stent grafts: predictive factors of midterm patency. *Ann Vasc Surg*, 29: 708–715.
142. Rastan A, McKinsey JF, Garcia LA, Rocha-Singh KJ, Jaff MR, Harlin S, Kamat S, Janzer S, Zeller T. (2018) One-Year Outcomes Following Directional Atherectomy of Popliteal Artery Lesions: Subgroup Analysis of the Prospective, Multicenter DEFINITIVE LE Trial. *J Endovasc Ther*, 25: 100–108.
143. Takács T, Mihalovits G, Váradi R, Palásthy Z. (2020) Kezdeti tapasztalataink öntáguló flexibilis sztenttel az arteria poplitea atheroscleroticus betegségeinek kezelésében [Early experience with self-expanding flexible stent for the treatment of atherosclerotic diseases in the popliteal artery]. *Orv Hetil*, 161: 588–593.
144. El-Mahallawy AM, Tawfik AMI, Alwageh MM, Kamhawy AH. (2023) Predictors of restenosis after popliteal angioplasty in patients with chronic limb threatening ischemia. *Int J Surg Sci*, 7: 16–19.
145. Troisi N, Saratzis A, Katsogridakis E, Stavroulakis K, Berchiolli R, Zayed H, Torsello G; EMO-POP Registry Collaborative Group. (2023) Different endovascular modalities of treatment for isolated atherosclerotic popliteal artery lesions (EMO-POP) registry. *J Vasc Surg*, 77: 231–240.e4.

146. San Norberto EM, Flota CM, Fidalgo-Domingos L, Taylor JH, Vaquero C. (2020) Real-World Results of Supera Stent Implantation for Popliteal Artery Atherosclerotic Lesions: 3-Year Outcome. *Ann Vasc Surg*, 62: 397–405.

147. Hiramori S, Soga Y, Tomoi Y, Tosaka A. (2014) Impact of runoff grade after endovascular therapy for femoropopliteal lesions. *J Vasc Surg*, 59: 720–727.

148. Klein AJ, Chen SJ, Messenger JC, Hansgen AR, Plomondon ME, Carroll JD, Casserly IP. (2009) Quantitative assessment of the conformational change in the femoropopliteal artery with leg movement. *Catheter Cardiovasc Interv*, 74: 787–798.

## 9. Bibliography of the candidate's publications

### 9.1. Peer-reviewed articles with relevance to the current work

1. **Nguyen DT**, Bérczi Á, Nyárady BB, Szőnyi Á, Philippovich M, Dósa E. (2022) Short- and Mid-Term Outcomes of Stenting in Patients with Isolated Distal Internal Carotid Artery Stenosis or Post-Surgical Restenosis. *J Clin Med*, 11: 5640. **IF: 3.9**
2. **Nguyen DT**, Vokó B, Nyáradi BB, Munkácsi T, Bérczi Á, Vokó Z, Dósa E. (2022) Restenosis rates in patients with ipsilateral carotid endarterectomy and contralateral carotid artery stenting. *PLoS One*, 17: e0262735. **IF: 3.7**
3. **Nguyen DT**, Bayerle P, Vértes M, Bérczi Á, Dósa E. (2021) Mid-term results and predictors of restenosis in patients undergoing endovascular therapy for isolated popliteal artery steno-occlusive disease. *IMAGING*, 13: 69–75. **IF: –**

### 9.2. Other peer-reviewed articles

1. Mihály Z, Booth S, **Nguyen DT**, Vecsey-Nagy M, Vértes M, Czinege Z, Péter C, Sótónyi P, Varga A. (2023) A Propensity-Matched Comparison of Ischemic Brain Lesions on Postprocedural MRI in Endovascular versus Open Carotid Artery Reconstruction. *J Cardiovasc Dev Dis*, 10: 257. **IF: 2.4**
2. Zhubi Bakija F, Bagyura Z, Fábián A, Ferencz A, Kiss L, Szenczi O, Vadas R, Dósa E, **Nguyen DT**, Csobay-Novák C, Jermendy ÁL, Szelid Z, Soós P, Kovács A, Merkely B. (2023) Long-term prognostic value of left atrial longitudinal strain in an elderly community-based cohort. *Geroscience*, 45: 613–625. **IF: 5.6**
3. Bérczi Á, **Nguyen DT**, Sarkadi H, Nyáradi BB, Beneda P, Szőnyi Á, Philippovich M, Szeberin Z, Dósa E. (2022) Amputation and mortality rates of patients undergoing upper or lower limb surgical embolectomy and their predictors. *PLoS One*, 17: e0279095. **IF: 3.7**

4. Pataki Á, **Nguyen DT**, Nagy Z, Nardai S, Nemes B. (2022) Stent-Graft Treatment of a Giant Asymptomatic Extracranial Vertebral Artery Aneurysm: Case Report and Literature Review. *Ann Vasc Surg*, 79: 442.e1–442.e6. **IF: 1.5**
5. Bagyura Z, Takács A, Kiss L, Dósa E, Vadas R, **Nguyen DT**, Dinya E, Soós P, Szelid Z, Láng O, Pállinger É, Kőhidai L, Merkely B. (2022) Level of advanced oxidation protein products is associated with subclinical atherosclerosis. *BMC Cardiovasc Disord*, 22: 5. **IF: 2.1**
6. Bérczi Á, Vértes M, **Nguyen DT**, Bérczi V, Nemes B, Hüttl K, Dósa E. (2021) Early and long-term results of the endovascular treatment of patients with isolated infrarenal aortic stenosis. *J Vasc Surg*, 73: 510–515.e2. **IF: 4.860**
7. Pomozi E, Lengyel B, Osztrogonác P, **Nguyen DT**, Szeberin Z. (2021) Az aortobiiliacalis occlusiv érbetegség miatt végzett aortobifemoralis bypass műtétek hosszú távú eredményeinek elemzése [Long-term analysis of the results of aorto-bifemoral bypass surgery for diffuse aorto-biiliac occlusive disease]. *Orv Hetil*, 162: 99–105. **IF:0.707**
8. Vértes M, **Nguyen DT**, Székely G, Bérczi Á, Dósa E. (2020) Middle and Distal Common Carotid Artery Stenting: Long-Term Patency Rates and Risk Factors for In-Stent Restenosis. *Cardiovasc Intervent Radiol*, 43: 1134–1142. **IF: 2.740**
9. Vértes M, **Nguyen DT**, Székely G, Bérczi Á, Dósa E. (2020) The incidence and risk factors of stent fracture in patients treated for proximal common carotid artery stenosis. *J Vasc Surg*, 71: 824–831.e1. **IF: 4.268**
10. Hüttl AB, Hüttl A, Vértes M, **Nguyen DT**, Bérczi Á, Hüttl K, Dósa E. (2019) The presence of long and heavily calcified lesions predisposes for fracture in patients undergoing stenting of the first part of the subclavian artery. *J Vasc Surg*, 70: 1146–1154.e1. **IF: 3.405**

11. Vértes M, Juhász IZ, **Nguyen DT**, Veres DS, Hüttl A, Nemes B, Hüttl K, Dósa E. (2018) Stent Protrusion >20 mm Into the Aorta: A New Predictor for Restenosis After Kissing Stent Reconstruction of the Aortoiliac Bifurcation. *J Endovasc Ther*, 25: 632–639. **IF: 2.986**

### 9.3. Published abstracts

1. **Nguyen DT**, Dósa E. (2022) Outcome of distal internal carotid artery stenting. CIRSE 2022 Book of Abstracts. *Cardiovasc Intervent Radiol*, 45 (Suppl 4), page: 320. **IF: –**

2. Nyárády B, Szőnyi Á, **Nguyen DT**, Philippovich M, Dósa E. (2022) Occurrence and characteristics of carotid filter debris – preliminary results. CIRSE 2022 Book of Abstracts. *Cardiovasc Intervent Radiol*, 45 (Suppl 4), page: 326. **IF: –**

3. **Nguyen DT**, Pataki Á, Nemes B. (2022) Stent-graft treatment of a giant asymptomatic extracranial vertebral artery aneurysm. CIRSE 2022 Book of Abstracts. *Cardiovasc Intervent Radiol*, 45 (Suppl 4), page: 463. **IF: –**

4. **Nguyen DT**, Philippovich M, Nemes B, Dósa E. (2022) A distalis a. carotis interna (ACI) stentelések rövid- és hosszútávú eredményessége. *Érbetegségek*, Suppl. 2, page: 73. **IF: –**

5. Philippovich M, **Nguyen DT**, Dósa E. (2022) A femoralis plaque-karakterisztika jelentősége a carotis stentelés utáni restenosis kialakulásában. *Érbetegségek*, Suppl. 2, page: 111. **IF: –**

6. **Nguyen DT**, Vértes M, Bayerle P, Bérczi Á, Dósa E. (2019) The long-term results of endovascular therapy in patients with popliteal artery steno-occlusive disease. CIRSE 2019 Book of Abstracts. *Cardiovasc Intervent Radiol*, 42 (Suppl 3), page: 702. **IF: –**



7. **Nguyen DT**, Vértes M, Bayerle P, Bérczi Á, Dósa E. (2019) Az arteria poplitea stenosisok/occlusiók endovascularis terápiájának eredményessége. *Érbetegségek, Suppl. 2*, page: 73. **IF:** –
8. Bérczi Á, Vértes M, **Nguyen DT**, Nemes B, Csobay-Novák Cs, Hüttl K, Dósa E. (2019) Az infrarenalis aorta stenosis miatt végzett interventiók hosszútávú kimenetele. *Érbetegségek, Suppl. 2*, page: 83. **IF:** –
9. Vértes M, Juhász I, **Nguyen DT**, Nemes B, Hüttl K, Dósa E. (2018) Az iliaca kissing in-stent restenosisok új, eddig nem ismert rizikófaktorai. *Magyar Radiológia*, 92: 156–157. **IF:** –
10. Juhász I, Vértes M, **Nguyen DT**, Nemes B, Hüttl K, Dósa E. (2017) Az iliaca kissing in-stent restenosisok (ISR-ek) lehetséges rizikófaktorai. *Érbetegségek, Suppl. 2*, page: 14. **IF:** –
11. **Nguyen DT**, Vértes M, Juhász I, Heltai K, Merkely B, Hüttl K, Dósa E. (2017) Az N-acetil-cisztein (NAC) parenterálisan, mellékhatás nélkül alkalmazható dózis maximumának meghatározása - fázis I. tanulmány. *Érbetegségek, Suppl. 2*, page: 38. **IF:** –

## 10. Acknowledgements

I would like to express my deep gratitude and appreciation to the following individuals whose unwavering support and contribution made this dissertation possible.

First and foremost, I would like to thank my supervisor, Dr. Edit Dósa, for her exceptional guidance, wisdom, and encouragement throughout the research. Her commitment to my academic and personal development is invaluable.

I owe sincere thanks to the Head of Semmelweis University, Dr. Béla Merkely, for creating an optimal research environment at our institution. His vision and leadership set a remarkable standard for the academic endeavors of Ph.D. students.

I am deeply grateful to Dr. Csaba Csobay-Novák, Head of the Department of Diagnostic Radiology, for his insights and expertise, which significantly enriched the quality of my work.

Special thanks go to Dr. Balázs Nemes, Head of the Department of Interventional Radiology, for his collaborative efforts, which greatly facilitated the preparation of this thesis.

I would also like to acknowledge my colleagues at the Heart and Vascular Center of Semmelweis University for their cooperation and useful advice. Their camaraderie often helped me through the low points while writing my dissertation.

I am indebted to my beloved wife and my cherished daughter, My and Vy, for their never-ending love, patience, and understanding that got me through the challenges of this academic journey. Their sacrifice and encouragement was my greatest motivation.

## RESEARCH ARTICLE

# Restenosis rates in patients with ipsilateral carotid endarterectomy and contralateral carotid artery stenting

Dat Tin Nguyen<sup>1,2</sup>, Boldizsár Vokó<sup>1</sup>, Balázs Bence Nyárádi<sup>1</sup>, Tamás Munkácsi<sup>1</sup>, Ákos Bérczi<sup>1,2</sup>, Zoltán Vokó<sup>3</sup>, Edit Dósa<sup>1,2\*</sup>

**1** Heart and Vascular Center, Semmelweis University, Budapest, Hungary, **2** Hungarian Vascular Radiology Research Group, Budapest, Hungary, **3** Center for Health Technology Assessment, Semmelweis University, Budapest, Hungary

\* [dosa.edit@med.semmelweis-univ.hu](mailto:dosa.edit@med.semmelweis-univ.hu)



## Abstract

### Purpose

We aimed to evaluate the long-term outcome of carotid endarterectomy (CEA) and carotid artery stenting (CAS) in patients who underwent both procedures on different sides.

### Methods

In this single-center retrospective study (2001–2019), 117 patients (men, N = 78; median age at CEA, 64.4 [interquartile range {IQR}, 57.8–72.2] years; median age at CAS, 68.8 [IQR, 61.0–76.0] years) with  $\geq 50\%$  internal carotid artery stenosis who had CEA on one side and CAS on the other side were included. The risk of restenosis was estimated by treatment adjusted for patient and lesion characteristics.

### Results

Neurological symptoms were significantly more common (41.9% vs 16.2%,  $P < 0.001$ ) and patients had a significantly shorter mean duration of smoking (30.2 [standard deviation {SD}, 22.2] years vs 31.8 [SD, 23.4] years,  $P < 0.001$ ), hypertension (10.1 [SD, 9.8] years vs 13.4 [SD, 9.1] years,  $P < 0.001$ ), hyperlipidemia (3.6 [SD, 6.6] years vs 5.0 [SD, 7.3] years,  $P = 0.001$ ), and diabetes mellitus (3.9 [SD, 6.9] years vs 5.7 [SD, 8.9] years,  $P < 0.001$ ) before CEA compared to those before CAS. While the prevalence of heavily calcified stenoses on the operated side (25.6% vs 6.8%,  $P < 0.001$ ), the incidence of predominantly echogenic/echogenic plaques (53.0% vs 70.1%,  $P = 0.011$ ) and supravalvular lesions (1.7% vs 22.2%,  $P < 0.001$ ) on the stented side was significantly higher. Restenosis rates were 10.4% at 1 year, 22.3% at 5 years, and 33.7% at the end of the follow-up (at 11 years) for CEA, while these were 11.4%, 14.7%, and 17.2%, respectively, for CAS. Cox regression analysis revealed a significantly higher risk of restenosis (hazard ratio [HR], 1.80; 95% confidence interval [CI], 1.05–3.10;  $P = 0.030$ ) for CEA compared to that for CAS. After adjusting for relevant confounding factors (smoking, hypertension, diabetes mellitus, calcification severity,

## OPEN ACCESS

**Citation:** Nguyen DT, Vokó B, Nyárádi BB, Munkácsi T, Bérczi Á, Vokó Z, et al. (2022)

Restenosis rates in patients with ipsilateral carotid endarterectomy and contralateral carotid artery stenting. PLoS ONE 17(2): e0262735. <https://doi.org/10.1371/journal.pone.0262735>

**Editor:** Rudolf Kirchmair, Medical University Innsbruck, AUSTRIA

**Received:** August 9, 2021

**Accepted:** January 4, 2022

**Published:** February 11, 2022

**Copyright:** © 2022 Nguyen et al. This is an open access article distributed under the terms of the [Creative Commons Attribution License](https://creativecommons.org/licenses/by/4.0/), which permits unrestricted use, distribution, and reproduction in any medium, provided the original author and source are credited.

**Data Availability Statement:** All relevant data are within the manuscript and its [Supporting Information](#) files.

**Funding:** This article was funded by the EFOP-3.6.3-VEKOP-16-2017-00009 project (Ákos Bérczi and Balázs Bence Nyárádi). Name of the funder: HRDOP (Human Resource Development Operational Programme) Website: [https://www.palyazat.gov.hu/human\\_resource\\_development\\_operational\\_programme](https://www.palyazat.gov.hu/human_resource_development_operational_programme).

**Competing interests:** The authors have declared that no competing interests exist.

plaque echogenicity, and lesion location), the estimate effect size materially did not change, although it did not remain statistically significant (HR, 1.85; 95% CI, 0.95–3.60;  $P = 0.070$ ).

## Conclusion

Intra-patient comparison of CEA and CAS in terms of restenosis tilts the balance toward CAS.

## Introduction

Among invasive interventions, those performed for carotid artery stenosis are one of the most common in the field of vascular medicine [1]. To date, carotid artery stenting (CAS) still occurs primarily when the patient is at “high” risk for open surgery [2]. Patients with high or low placed stenosis, non-atherosclerotic lesions, contralateral carotid artery occlusion, contralateral laryngeal nerve palsy, previous radical neck surgery, cervical radiation therapy, and/or severe cardiopulmonary comorbidities are considered to be at “high” risk for open surgery [2, 3]. In all other cases, carotid endarterectomy (CEA) is preferable, especially if the patient has crescendo symptoms, aortic arch anomaly, aortic arch atheroma, tortuous common carotid artery (CCA), angulated internal carotid artery (ICA) origin, angulated distal ICA, severely diseased CCA/external carotid artery, pinhole or long ICA stenosis, and if the ICA lesions are thrombotic, heavily calcified, or sequential [2, 4, 5]. Age requires special attention when choosing the type of invasive therapy; the outcome of older patients is better with CEA than with CAS [6, 7]. The dominance of CEA over CAS is mainly because the perioperative death and stroke rate of CEA is lower than that of CAS [2, 6–13]. A meta-analysis of data from four randomized clinical trials (RCTs) revealed a 30-day death/stroke rate of 1.6% after CEA versus 2.7% after CAS in asymptomatic patients at “average” risk for surgery [2, 8–11]. The Endarterectomy versus Stenting in Patients with Symptomatic Severe Carotid Stenosis (EVA-3S) study, the Stent-Protected Angioplasty versus Carotid Endarterectomy (SPACE) trial, the International Carotid Stenting Study (ICSS), and the Carotid Revascularization Endarterectomy Versus Stenting Trial (CREST) have reported even stronger trends in symptomatic patients [2, 6, 7, 12, 13].

According to the results of large RCTs, it can be clearly stated that, among the long-term outcomes, there is no significant difference between CEA and CAS in the incidence of ipsilateral stroke [2, 6, 7, 12, 13]. However, concerning restenosis, the literature data are rather contradictory; while RCTs have shown that CAS has a higher rate of restenosis [2, 14, 15], observational studies have noted that CEA has a higher rate of restenosis [16–18].

Because there are two ICAs, it is possible to evaluate the short- and long-term outcomes of CEA and CAS in the same patient (ipsilateral CEA versus contralateral CAS). As the number of such publications is few (we found four in total) with small sample sizes (63 subjects the most) [19–22], we considered it worthwhile to perform an intra-patient comparison of restenosis on a larger sample size.

## Patients and methods

### Study characteristics

In this single-center retrospective study, 117 patients who underwent CEA on one side and CAS on the other side between January 2001 and January 2019 were included. The study was approved by the institutional ethics committee (Approval No: 222/2017). Due to the

retrospective nature of the study, patient informed consent for analysis of data was not obtained. All data were fully anonymized before we accessed them.

### Procedure characteristics

The indications for CEA and CAS were based on international guidelines that were in force at the time of the intervention [23–25]. In general, asymptomatic patients in the presence of  $\geq 70\%$  ICA stenosis and symptomatic patients in the presence of  $\geq 50\%$  ICA stenosis were treated invasively. Following the guidelines, a team of vascular surgeons, interventional radiologists, and angiologists decided on the type of invasive therapy [23–25].

The type of open surgery was eversion endarterectomy (EEA) without routine shunt use, which was carried out under general anesthesia. The indication for the use of shunt was left to the discretion of the operating surgeon. The technical details of EEA can be found in the publication by Hirschberg et al. [16]. If the patient had not previously taken a platelet aggregation inhibitor drug regularly, antiplatelet therapy was initiated at least 7 days before the procedure and was continued indefinitely postsurgically. Technical success was defined as the absence of visible plaque remnants and successful restoration of blood flow at the completion of EEA [26].

CAS, which meant the deployment of a self-expanding stent, was executed in a standard manner via the common femoral, brachial, or radial artery. Embolic protection systems were routinely used and stent postdilation was inevitable. Puncture sites were manually compressed or sealed with a closure device. If they were not already administered, patients were pretreated with dual antiplatelet therapy for 5 days before the intervention and were administered post-procedurally for up to 3 months. If the patient did not have heart disease, monotherapy was sufficient thereafter. Technical success was achieved if no extravasation, dissection, or  $>30\%$  residual stenosis was seen on the final angiographic images [23–27].

### Control ultrasonography

The carotid ultrasonography was due 6 weeks, 6 months, and 12 months after the procedure, and then once a year. In the event of symptom/complaint or contralateral invasive treatment, these dates were changed. On the operated side, a restenosis was considered 50–69% when the peak systolic velocity (PSV) was 210–270 cm/s and  $\geq 70\%$  when the PSV was  $>270$  cm/s [28], while on the stented side, a restenosis was considered 50–69% when the PSV was 225–350 cm/s and  $\geq 70\%$  when the PSV was  $>350$  cm/s [29].

### Evaluated parameters and their definitions

Symptoms were categorized as amaurosis fugax, transient ischemic attack (TIA), minor stroke, major stroke, or no symptoms [26].

Information on the presence and duration of atherosclerotic risk factors and the type and duration of medications was obtained from the medical record archiving system (MedSol; T-Systems Hungary Ltd., Budapest, Hungary) or directly from the patients, who were called by phone. Definitions of atherosclerotic risk factors can be found in one of the articles by Vértés et al. [30].

Stenosis grade, lesion length, and the severity of plaque calcification were evaluated on the reformatted computed tomography (CT)/CT angiography images. The percentage of ICA stenosis was determined according to the North American Symptomatic Carotid Endarterectomy Trial (NASCET) criteria [31]. Lesion length was defined as the distance between the proximal and the distal point where the degree of stenosis decreased to 80% of its maximum [32]. In terms of calcification, the following groups were distinguished: absent, mild (thin, discontinuous), moderate (thin, continuous or thick, discontinuous), and severe (thick, continuous) [33].

Plaque echogenicity was assessed by computer-assisted quantification of the gray-scale median (GSM) values using Adobe Photoshop software (CS3; Adobe System, San Jose, CA, USA) [34]. According to the modified Geroulakos classification, depending on the percentage of pixels in the plaque area with GSM values  $>25$ , plaques were categorized as type 1: uniformly echolucent ( $<15\%$ ), type 2: predominantly echolucent ( $15\text{--}50\%$ ), type 3: predominantly echogenic ( $50\text{--}85\%$ ), type 4: uniformly echogenic ( $>85\%$ ), and type 5: indeterminable due to acoustic shadow [35].

### Statistical analysis

Statistical analysis was performed with the software Stata 16.0 (StataCorp. 2019. Stata Statistical Software: Release 16. College Station, TX: StataCorp LLC). Distributions of the continuous variables in the two treatment groups were compared with paired t-tests, while categorical data were compared with Fisher exact tests. The probability of being free from restenosis was estimated by the Kaplan-Meier method. Restenosis was considered as failure in the analysis, while death and end of observation were considered as censoring. As only one death occurred during the 11-year follow-up, a competing risk problem was not considered. The maximum follow-up time was set at 11 years on each side. The event-free survival curves were compared by the log-rank test.

The crude hazard ratio (HR) comparing the two procedures was estimated by Cox proportional-hazards model. Then, we adjusted for prognostic factors that could be related to the indication of the procedures in a stepwise manner. First, we considered age, symptoms, and lesion characteristics, which were significantly associated with the procedures at the level of  $P \leq 0.20$  in the univariate analysis. To improve the efficiency of the estimation, we eliminated the potential confounders of treatment effect in a stepwise manner from the initial model starting with the ones having the largest P-value in the Wald-test. The decision rule of elimination was that covariates non-significant at the level of  $P < 0.05$  were eliminated if the estimate of the coefficient of the treatment effect from the initial model did not change more than 10% by the elimination. After this process, lesion characteristics that were not previously included in the model were added back individually and were kept in the model if the adjustment for them changed the coefficient of treatment more than 10%. Finally, the length of history of smoking, hypertension, hyperlipidemia, and diabetes mellitus were added to the model, and the same elimination process was performed.

## Results

### Patient data

There were 39 women and 78 men in the study group (median age at CEA, 64.4 [interquartile range {IQR}, 57.8–72.2] years; median age at CAS, 68.8 [IQR, 61.0–76.0] years). Neurological symptoms were significantly more common ( $P < 0.001$ ) before CEA compared to those before CAS. Except for age  $\geq 80$  years ( $P = 0.033$ ), there was no significant difference in the presence of atherosclerotic risk factors/comorbidities at the time of CEA and CAS. The duration of smoking ( $P < 0.001$ ), hypertension ( $P < 0.001$ ), hyperlipidemia ( $P = 0.001$ ), and diabetes mellitus ( $P < 0.001$ ) was significantly shorter at the time of CEA compared to that at the time of CAS. (Table 1)

### Lesion characteristics

Except for one stented stenosis (0.9%), which was presumably caused by radiation therapy, all other lesions (99.1%) were of atherosclerotic origin. There was no difference in the grade and length of the stenosis, but the majority of the lesions (79.5%) were mildly or moderately

calcified in the CAS group compared to the balanced distribution of the lesions along the four categories of calcification in the CEA group. In terms of plaque echogenicity, most of the lesions were types 3 and 4 in both groups; however, significantly more lesions were types 3 and 4 in the CAS group compared to those in the CEA group. The majority of the lesions were in the bulb in both groups; supr bulbular lesions were mostly treated with stenting. (Table 2)

## Procedures

In 95 patients, CEA was the first invasive therapeutic method. The median time interval between the two procedures was 50.0 (IQR, 8.5–102.0) months if the first procedure was CEA and 2.5 (IQR, 1.0–12.8) months if the first procedure was CAS.

During CEA, the clamping time was  $22.7 \pm 8.0$  minutes. A shunt was inserted in four patients (3.4%).

In the case of CAS, access sites were femoral in 77 patients (65.8%), radial in 37 patients (31.6%), and brachial in three patients (2.6%). In two cases (1.7%), a proximal Mo.Ma (Medtronic Inc., Minneapolis, MN, USA) was used, while in the other patients (98.3%), a distal embolic protection device (FilterWire EZ; Boston Scientific Corp., Marlborough, MA, USA) was used. Predilation was carried out in six cases (5.1%). Balloon and stent parameters can be found in Table 3.

The technical success rate among the patients was 100%.

## Early ( $\leq 30$ days) postprocedural period

No one died during the early stages of the follow-up.

The following complications occurred after CEA: four wound hematomas (3.4%), with two requiring surgical evacuation; five cranial nerve injuries (4.3%); two cases of hemodynamic instability (1.7%; hypotension,  $N = 1$ ; hypertension,  $N = 1$ ); one myocardial infarction (0.9%); and five neurological ischemic events (4.3%; TIA,  $N = 1$ ; ipsilateral minor stroke,  $N = 1$ ; ipsilateral major stroke,  $N = 3$ ). Two of five neurological ischemic events were due to acute occlusion of the ICA that was operated on; both patients underwent reoperation.

The following complications were observed after CAS: one postpuncture pseudoaneurysm (0.9%), which was eliminated by thrombin injection; four cases of hemodynamic instability (3.4%; hypotension,  $N = 3$ ; hypertension,  $N = 1$ ); and six ocular or neurological ischemic events (5.1%; amaurosis fugax,  $N = 1$ ; TIA,  $N = 5$ ). One of six neurological ischemic events was due to acute stent occlusion; the patient underwent surgical stent removal.

There was no significant difference ( $P = 0.683$  and  $P = 1.000$ , respectively) between CEA and CAS neither for hemodynamic instability nor for early postprocedural neurological complications.

## Follow-up

The median follow-up time was 10.0 (IQR, 5.5–14.0) years after CEA and 6.0 (IQR, 3.0–10.0) years after CAS. One death occurred during the follow-up period. The cause of death was ventricular fibrillation.

Ocular or neurological ischemic events corresponding to the operated side were reported in five patients (4.3%; amaurosis fugax,  $N = 1$ ; TIA,  $N = 2$ ; minor stroke,  $N = 2$ ) and neurological symptoms corresponding to the stented side in one patient (0.9%; TIA,  $N = 1$ ); the difference between the two sides was statistically non-significant ( $P = 0.213$ ).

After CEA, 50–69% restenosis was detected in eight cases (6.8%; symptomatic restenosis,  $N = 0$ ), 70–99% restenosis in 30 cases (25.6%; symptomatic restenosis,  $N = 5$ ), and occlusion in two cases (1.7%; symptomatic occlusion,  $N = 0$ ). Twenty-four of 30 patients with 70–99%

restenosis underwent radiological intervention (Wallstent implantation [N = 24]; Boston Scientific Corp., Marlborough, MA, USA), while all the other patients remained on best medical treatment (BMT). Three patients (2.6%; symptomatic re-restenosis, N = 1) developed 70–99% re-restenosis; radiological reintervention (percutaneous transluminal angioplasty [PTA]) was performed in one of these three patients.

After CAS, 50–69% restenosis was detected in 12 cases (10.3%; symptomatic restenosis, N = 0), 70–99% restenosis in five cases (4.3%; symptomatic restenosis, N = 0), and occlusion in one case (0.9%; symptomatic occlusion, N = 1). Four of five patients with 70–99% restenosis underwent radiological reintervention (PTA), while all the others remained on BMT. No one had 70–99% re-restenosis.

Nine patients developed restenosis on both sides, with one patient having bilateral ICA occlusion.

Restenosis probabilities are displayed in Table 4. The risk of restenosis was the same in the first year after both procedures, followed by a lower risk in the CAS group throughout the follow-up. (Fig 1) There was a statistically significant difference between the two groups; the P-value from the log-rank test was 0.045. The crude incidence rate of restenosis was 2.5/100 person-years in the CAS group and 4.2/100 person-years in the CEA group; the crude HR estimated by Cox regression was 1.80 (95% CI, 1.05–3.10; P = 0.030). Fig 2 shows the observed and predicted probabilities of being free from restenosis by treatment. The adjusted HR hardly differed from the crude being 1.85 (95% CI, 0.95–3.60; P = 0.070). The final model, which contained all important covariates (either being significant in the model or their omission would have changed the effect size more than 10%), included smoking, hypertension, diabetes mellitus, level of calcification and echogenicity, and location of the lesions, besides the type of treatment.

All patients received an antiaggregant, 60 of whom were on long-term dual antiplatelet therapy. Cilostazol therapy was noted in 13 patients (11.1%). Ninety-three patients (79.5%) received statin therapy, 51 of whom were on high-intensity therapy. Other lipid-lowering medications (fibrates and ezetimibe) were prescribed to 14 patients (12.0%).

## Discussion

The outcomes of CEA and CAS performed for ICA stenosis on the same patient have been previously investigated in four retrospective studies [19–21]. De Borst et al. compared the restenosis rates of 63 patients who underwent CEA first, followed by CAS. The median follow-up time was 54.4±39.5 months for CEA and 28.7±16.9 months for CAS. The ≥50% restenosis rates were not significantly different between CEA and CAS and were 10%, 19%, and 24% for CEA and 23%, 31%, and 34% for CAS at 1, 2, and 3 years, respectively [19]. Martelli et al. revealed a ≥50% restenosis rate of 31% for CEA, with a median follow-up time of 67.3±51.6 months, and 21% for CAS, with a median follow-up time of 24.6±16.9 months. In their study, the restenosis-free survival rate was 85% after CEA and 66% after CAS. As the definition of restenosis-free survival rate cannot be found in the article by Martelli et al. and the loss to follow-up is not reported either, survival rates mentioned by this group should be taken with a grain of salt [20]. Ciccone et al. evaluated 45 patients treated with CEA on one side and CAS on the contralateral side and did not observe restenosis ≥50% on either side of the patients [21]. Xu et al. carried out simultaneous CEA and CAS on eight patients and did not detect restenosis during the 6-month follow-up [22].

In our study, the risk of ≥50% restenosis after both procedures were the same in the first year, then it was significantly higher in the CEA group throughout the follow-up. Regarding CEA, we noted similar restenosis rates to those documented by De Borst et al. [19] but



approximately a 10% better 5-year restenosis rate compared to that for Martelli et al. [20]. In the latter study, the majority of CEAs were performed with direct suturing, which is known to have higher restenosis rates compared to that in patching and EEA [36]. Regarding CAS, De Borst et al. published significantly worse restenosis rates at 1, 2, and 3 years compared to our results, but almost 20% of their CAS lesions were postsurgical restenoses [19], which has been previously identified as an independent risk factor for restenosis after CAS [20, 37].

According to a recently updated Cochrane meta-analysis, RCTs comparing restenosis rates of CEA and CAS showed a significantly higher risk for  $\geq 50\%$  restenosis after CAS (OR, 2.00; 95% CI, 1.12–3.60;  $P = 0.02$ ;  $I^2 = 44\%$ ); however, in terms of severe ( $\geq 70\%$ ) restenosis, no significant difference was observed in the pooled data (OR, 1.26; 95% CI, 0.79–2.00;  $P = 0.33$ ;  $I^2 = 58\%$ ) [38]. In the present study, most of the restenoses were 50–69% on the stented side and  $\geq 70\%$  on the operated side. Even after adjustment for differences in the two groups, a 1.86 HR was estimated favoring CAS with respect to restenosis. A possible explanation for our better patency rates for CAS could be that, in most of the RCTs, patients had a similar prognosis at baseline due to randomization, while our patients had different lesion characteristics on the two sides. Another explanation could be that differences in restenosis rates in our study were accentuated in the later stages of the follow-up, and none of the RCTs had as long a follow-up as our study.

Two main processes are playing roles in the pathomechanism of restenosis. One of them is neointimal hyperplasia, which occurs at the early stages, and the other one is neoatherosclerosis, which does not develop until 2 to 3 years after the intervention [39]. No significant difference was noted in terms of restenosis rate at 1 year between CEA and CAS, and almost half of the restenoses were found after 2 years in the CEA group. In our opinion, this underlies the importance of the duration of atherosclerotic risk factors, such as the average durations of hypertension, hyperlipidemia, and diabetes mellitus were significantly longer at the end of the follow-up on the side where CEA was performed.

One of the limitations is the retrospective nature of our study. Other limitations are the inevitable selection bias, as guidelines suggest different interventional techniques for different types of lesions. Although we adjusted the most important risk factors, residual confounding could not be excluded.

In conclusion, late restenosis is more frequent after CEA in patients undergoing both CEA and CAS on different sides for atherosclerotic bilateral carotid artery stenosis.

## Supporting information

**S1 Table. Evaluated parameters.**  
(XLS)

## Author Contributions

**Conceptualization:** Dat Tin Nguyen, Edit Dósa.

**Data curation:** Dat Tin Nguyen, Boldizsár Vokó, Balázs Bence Nyárádi, Tamás Munkácsi, Ákos Bérczi.

**Formal analysis:** Dat Tin Nguyen, Zoltán Vokó.

**Investigation:** Dat Tin Nguyen, Boldizsár Vokó, Balázs Bence Nyárádi, Tamás Munkácsi, Ákos Bérczi.

**Methodology:** Zoltán Vokó.

**Supervision:** Edit Dósa.

**Writing – original draft:** Dat Tin Nguyen, Zoltán Vokó.

**Writing – review & editing:** Ákos Bérczi, Zoltán Vokó, Edit Dósa.

## References

1. Stanley JC, Barnes RW, Ernst CB, Hertzner NR, Mannick JA, Moore WS. Vascular surgery in the United States: workforce issues. Report of the Society for Vascular Surgery and the International Society for Cardiovascular Surgery, North American Chapter, Committee on Workforce Issues. *J Vasc Surg.* 1996; 23(1):172–81. [https://doi.org/10.1016/s0741-5214\(05\)80050-3](https://doi.org/10.1016/s0741-5214(05)80050-3) PMID: 8558735
2. Naylor AR, Ricco JB, de Borst GJ, Debus S, de Haro J, Halliday A, et al. Editor's Choice—Management of Atherosclerotic Carotid and Vertebral Artery Disease: 2017 Clinical Practice Guidelines of the European Society for Vascular Surgery (ESVS). *Eur J Vasc Endovasc Surg.* 2018; 55(1):3–81. <https://doi.org/10.1016/j.ejvs.2017.06.021> PMID: 28851594
3. Yadav JS, Wholey MH, Kuntz RE, Fayad P, Katzen BT, Mishkel GJ, et al. Protected carotid-artery stenting versus endarterectomy in high-risk patients. *N Engl J Med.* 2004; 351(15):1493–501. <https://doi.org/10.1056/NEJMoa040127> PMID: 15470212
4. Macdonald S, Lee R, Williams R, Stansby G, Delphi Carotid Stenting Consensus Panel. Towards Safer Carotid Artery Stenting: A Scoring System for Anatomic Suitability. *Stroke.* 2009; 40(5):1698–703. <https://doi.org/10.1161/STROKEAHA.109.547117> PMID: 19299627
5. Moore WS, Popma JJ, Roubin GS, Voeks JH, Cutlip DE, Jones M, et al. Carotid Angiographic Characteristics in the CREST Trial Were Major Contributors to Periprocedural Stroke and Death Differences Between Carotid Artery Stenting and Carotid Endarterectomy. *J Vasc Surg.* 2016; 63(4):851–7, 858.e1. <https://doi.org/10.1016/j.jvs.2015.08.119> PMID: 26610643
6. Ederle J, Dobson J, Featherstone RL, Bonati LH, van der Worp HB, de Borst GJ, et al. Carotid Artery Stenting Compared With Endarterectomy in Patients With Symptomatic Carotid Stenosis (International Carotid Stenting Study): An Interim Analysis of a Randomised Controlled Trial. *Lancet.* 2010; 375(9719):985–97. [https://doi.org/10.1016/S0140-6736\(10\)60239-5](https://doi.org/10.1016/S0140-6736(10)60239-5) PMID: 20189239
7. Brott TG, Hobson RW 2nd, Howard G, Roubin GS, Clark WM, Brooks W, et al. Stenting Versus Endarterectomy for Treatment of Carotid-Artery Stenosis. *N Engl J Med.* 2010; 363(1):11–23. <https://doi.org/10.1056/NEJMoa0912321> PMID: 20505173
8. Silver FL, Mackey A, Clark WM, Brooks W, Timaran CH, Chiu D, et al. Safety of Stenting and Endarterectomy by Symptomatic Status in the Carotid Revascularization Endarterectomy Versus Stenting Trial (CREST). *Stroke.* 2011; 42(3):675–80. <https://doi.org/10.1161/STROKEAHA.110.610212> PMID: 21307169
9. Rosenfield K, Matsumura JS, Chaturvedi S, Riles T, Ansel GM, Metzger DC, et al. Randomized Trial of Stent Versus Surgery for Asymptomatic Carotid Stenosis. *N Engl J Med.* 2016; 374(11):1011–20. <https://doi.org/10.1056/NEJMoa1515706> PMID: 26886419
10. Eckstein HH, Reiff T, Ringleb P, Jansen O, Mansmann U, Hacke W. SPACE-2: A Missed Opportunity to Compare Carotid Endarterectomy, Carotid Stenting, and Best Medical Treatment in Patients With Asymptomatic Carotid Stenoses. *Eur J Vasc Endovasc Surg.* 2016; 51(6):761–5. <https://doi.org/10.1016/j.ejvs.2016.02.005> PMID: 27085660
11. Mannheim D, Karmeli R. A Prospective Randomized Trial Comparing Endarterectomy to Stenting in Severe Asymptomatic Carotid Stenosis. *J Cardiovasc Surg (Torino).* 2017; 58(6):814–817. <https://doi.org/10.23736/S0021-9509.16.09513-6> PMID: 27332677
12. Mas JL, Trinquart L, Leys D, Albuquer JF, Rousseau H, Viguier A, et al. Endarterectomy Versus Angioplasty in Patients With Symptomatic Severe Carotid Stenosis (EVA-3S) Trial: Results Up to 4 Years From a Randomised, Multicentre Trial. *Lancet Neurol.* 2008; 7(10):885–92. [https://doi.org/10.1016/S1474-4422\(08\)70195-9](https://doi.org/10.1016/S1474-4422(08)70195-9) PMID: 18774745
13. Eckstein HH, Ringleb P, Allenberg JR, Berger J, Fraedrich G, Hacke W, et al. Results of the Stent-Protected Angioplasty Versus Carotid Endarterectomy (SPACE) Study to Treat Symptomatic Stenoses at 2 Years: A Multinational, Prospective, Randomised Trial. *Lancet Neurol.* 2008; 7(10):893–902. [https://doi.org/10.1016/S1474-4422\(08\)70196-0](https://doi.org/10.1016/S1474-4422(08)70196-0) PMID: 18774746
14. Bonati LH, Lyrer P, Ederle J, Featherstone R, Brown MM. Percutaneous Transluminal Balloon Angioplasty and Stenting for Carotid Artery Stenosis. *Cochrane Database Syst Rev.* 2012;(9):CD000515. <https://doi.org/10.1002/14651858.CD000515.pub4> PMID: 22972047
15. Kumar R, Batchelder A, Saratzis A, AbuRahma AF, Ringleb P, Lal BK, et al. Restenosis After Carotid Interventions and Its Relationship With Recurrent Ipsilateral Stroke: A Systematic Review and Meta-

- analysis. *Eur J Vasc Endovasc Surg.* 2017; 53(6):766–775. <https://doi.org/10.1016/j.ejvs.2017.02.016> PMID: 28363431
16. Hirschberg K, Dosa E, Huttli K, Selmezi L, Nemes B, Szabo A, et al. Early restenosis after eversion carotid endarterectomy versus carotid stenting: a single-centre retrospective study. *J Cardiovasc Surg (Torino).* 2009; 50(5):655–63. PMID: 19339958
  17. Yan D, Tang X, Shi Z, Wang L, Lin C, Guo D, et al. Perioperative and Follow-up Results of Carotid Artery Stenting and Carotid Endarterectomy in Patients with Carotid Near-Occlusion. *Ann Vasc Surg.* 2019; 59:21–27. <https://doi.org/10.1016/j.avsg.2019.01.019> PMID: 31009714
  18. Rizwan M, Aridi HD, Dang T, Alshwaily W, Nejim B, Malas MB. Long-Term Outcomes of Carotid Endarterectomy and Carotid Artery Stenting When Performed by a Single Vascular Surgeon. *Vasc Endovascular Surg.* 2019; 53(3):216–223. <https://doi.org/10.1177/1538574418823379> PMID: 30614413
  19. De Borst GJ, Hellings WE, Ackerstaff RG, Moll FL. Inpatient comparison of restenosis between carotid artery angioplasty with stenting and carotid endarterectomy. *J Cardiovasc Surg (Torino).* 2006; 47(1):49–54. PMID: 16434945
  20. Martelli E, Pataconi D, DE Vivo G, Ippoliti A. Conventional carotid endarterectomy versus stenting: comparison of restenosis rates in arteries with identical predisposing factors. *J Cardiovasc Surg (Torino).* 2016; 57(4):503–9. PMID: 27366880
  21. Ciccone MM, Scicchitano P, Cortese F, Gesualdo M, Zito A, Carbonara R, et al. Carotid stenting versus endarterectomy in the same patient: A "direct" comparison. *Vascular.* 2017; 25(3):290–298. <https://doi.org/10.1177/1708538116674375> PMID: 27811331
  22. Xu RW, Liu P, Fan XQ, Wang Q, Zhang JB, Ye ZD. Feasibility and Safety of Simultaneous Carotid Endarterectomy and Carotid Stenting for Bilateral Carotid Stenosis: A Single-Center Experience using a Hybrid Procedure. *Ann Vasc Surg.* 2016; 33:138–43. <https://doi.org/10.1016/j.avsg.2015.11.017> PMID: 26902940
  23. Moore WS, Barnett HJ, Beebe HG, Bernstein EF, Brener BJ, Brott T, et al. Guidelines for carotid endarterectomy. A multidisciplinary consensus statement from the ad hoc Committee, American Heart Association. *Stroke.* 1995; 26(1):188–201. <https://doi.org/10.1161/01.str.26.1.188> PMID: 7839390
  24. Liapis CD, Bell PR, Mikhailidis D, Sivenius J, Nicolaides A, Fernandes e Fernandes J, et al. ESVS guidelines. Invasive treatment for carotid stenosis: indications, techniques. *Eur J Vasc Endovasc Surg.* 2009; 37(4 Suppl):1–19. <https://doi.org/10.1016/j.ejvs.2008.11.006> PMID: 19286127
  25. Eckstein HH. European Society for Vascular Surgery Guidelines on the Management of Atherosclerotic Carotid and Vertebral Artery Disease. *Eur J Vasc Endovasc Surg.* 2018; 55(1):1–2. <https://doi.org/10.1016/j.ejvs.2017.06.026> PMID: 28851595
  26. Timaran CH, McKinsey JF, Schneider PA, Littooy F. Reporting standards for carotid interventions from the Society for Vascular Surgery. *J Vasc Surg.* 2011; 53(6):1679–95. <https://doi.org/10.1016/j.jvs.2010.11.122> PMID: 21609800
  27. Ouriel K, Yadav J, Green RM. Standards of practice: carotid angioplasty and stenting. *J Vasc Surg.* 2004; 39(4):916–7. <https://doi.org/10.1016/j.jvs.2004.01.028> PMID: 15071467
  28. AbuRahma AF, Stone P, Deem S, Dean LS, Keiffer T, Deem E. Proposed duplex velocity criteria for carotid restenosis following carotid endarterectomy with patch closure. *J Vasc Surg.* 2009; 50(2):286–91, 291.e1-2; discussion 291. <https://doi.org/10.1016/j.jvs.2009.01.065> PMID: 19631861
  29. Stanziale SF, Wholey MH, Boules TN, Selzer F, Makaroun MS. Determining in-stent stenosis of carotid arteries by duplex ultrasound criteria. *J Endovasc Ther.* 2005; 12(3):346–53. <https://doi.org/10.1583/04-1527.1> PMID: 15943510
  30. Vértes M, Nguyen DT, Székely G, Bérczi Á, Dósa E. Middle and Distal Common Carotid Artery Stenting: Long-Term Patency Rates and Risk Factors for In-Stent Restenosis. *Cardiovasc Intervent Radiol.* 2020; 43(8):1134–1142. <https://doi.org/10.1007/s00270-020-02522-5> PMID: 32440962
  31. Barnett HJM, Taylor DW, Haynes RB, Sackett DL, Peerless SJ, Ferguson GG, et al. Beneficial effect of carotid endarterectomy in symptomatic patients with high-grade carotid stenosis. *N Engl J Med.* 1991; 325(7):445–53. <https://doi.org/10.1056/NEJM199108153250701> PMID: 1852179
  32. Bonati LH, Ederle J, Dobson J, Engelter S, Featherstone RL, Gaines PA, et al. Length of carotid stenosis predicts peri-procedural stroke or death and restenosis in patients randomized to endovascular treatment or endarterectomy. *Int J Stroke.* 2014; 9(3):297–305. <https://doi.org/10.1111/ijvs.12084> PMID: 23895672
  33. Woodcock RJ Jr, Goldstein JH, Kallmes DF, Cloft HJ, Phillips CD. Angiographic correlation of CT calcification in the carotid siphon. *AJNR Am J Neuroradiol.* 1999; 20(3):495–9 PMID: 10219418
  34. Ariyoshi K, Okuya S, Kunitsugu I, Matsunaga K, Nagao Y, Nomiyama R, et al. Ultrasound analysis of gray-scale median value of carotid plaques is a useful reference index for cerebro-cardiovascular

- events in patients with type 2 diabetes. *J Diabetes Investig.* 2015; 6(1):91–7. <https://doi.org/10.1111/jdi.12242> PMID: 25621138
35. Stenudd I, Sjödin E, Nyman E, Wester P, Johansson E, Grönlund C. Ultrasound risk marker variability in symptomatic carotid plaque: impact on risk reclassification and association with temporal variation pattern. *Int J Cardiovasc Imaging.* 2020; 36(6):1061–1068. <https://doi.org/10.1007/s10554-020-01801-z> PMID: 32144637
  36. Markovic DM, Davidovic LB, Cvetkovic DD, Maksimovic ZV, Markovic DZ, Jadranin DB. Single-center prospective, randomized analysis of conventional and eversion carotid endarterectomy. *J Cardiovasc Surg (Torino).* 2008; 49(5):619–25 PMID: 18670379
  37. De Borst GJ, Ackerstaff RG, de Vries JP, vd Pavoordt ED, Vos JA, Overtoom TT, Moll FL. Carotid angioplasty and stenting for postendarterectomy stenosis: long-term follow-up. *J Vasc Surg.* 2007; 45(1):118–23. <https://doi.org/10.1016/j.jvs.2006.09.013> PMID: 17210395
  38. Müller MD, Lyrer P, Brown MM, Bonati LH. Carotid artery stenting versus endarterectomy for treatment of carotid artery stenosis. *Cochrane Database Syst Rev.* 2020; 2(2):CD000515. <https://doi.org/10.1002/14651858.CD000515.pub5> PMID: 32096559
  39. Clagett PG. Intimal hyperplasia and restenosis after carotid endarterectomy. *J Vasc Surg.* 1989; 10(5):577–9. [https://doi.org/10.1016/0741-5214\(89\)90150-x](https://doi.org/10.1016/0741-5214(89)90150-x)

## Article

# Short- and Mid-Term Outcomes of Stenting in Patients with Isolated Distal Internal Carotid Artery Stenosis or Post-Surgical Restenosis

Dat Tin Nguyen<sup>1,2</sup>, Ákos Bérczi<sup>1,2</sup>, Balázs Bence Nyárady<sup>1,2</sup>, Ádám Szőnyi<sup>1,2</sup>, Márton Philippovich<sup>1,2</sup> and Edit Dósa<sup>1,2,\*</sup>

<sup>1</sup> Heart and Vascular Center, Semmelweis University, 1122 Budapest, Hungary

<sup>2</sup> Hungarian Vascular Radiology Research Group, 1122 Budapest, Hungary

\* Correspondence: [dosa.edit@med.semmelweis-univ.hu](mailto:dosa.edit@med.semmelweis-univ.hu)

**Abstract:** The aim was to evaluate the outcome of stenting in patients with isolated distal internal carotid artery (ICA) stenosis or post-surgical restenosis, as no data are currently available in the literature. Sixty-six patients (men, N = 53; median age: 66 [IQR, 61–73] years) with  $\geq 50\%$  distal ICA (re)stenosis were included in this single-center retrospective study. The narrowest part of the (re)stenosis was at least 20 mm from the bifurcation in all patients. Patients were divided into two etiological groups, atherosclerotic (AS, N = 40) and post-surgical restenotic (RES, N = 26). Postprocedural neurological events were observed in two patients (5%) in the AS group and in two patients (7.7%) in the RES group. The median follow-up time was 40 (IQR, 18–86) months. Three patients (7.5%) in the AS group had an in-stent restenosis (ISR)  $\geq 50\%$ , but none in the RES group. Three patients (7.5%) in the AS group and seven patients (26.9%) in the RES group died. None of the deaths in the RES group were directly related to stenting itself. The early neurological complication rate of stenting due to distal ICA (re)stenoses is acceptable. However, the mid-term mortality rate of stenting for distal ICA post-surgical restenoses is high, indicating the vulnerability of this subgroup.

**Keywords:** internal carotid artery; atherosclerosis; restenosis; stenting; outcome; stroke; in-stent restenosis; patency; mortality; survival



**Citation:** Nguyen, D.T.; Bérczi, Á.; Nyárady, B.B.; Szőnyi, Á.; Philippovich, M.; Dósa, E. Short- and Mid-Term Outcomes of Stenting in Patients with Isolated Distal Internal Carotid Artery Stenosis or Post-Surgical Restenosis. *J. Clin. Med.* **2022**, *11*, 5640. <https://doi.org/10.3390/jcm11195640>

Academic Editor:  
Anna Kablak-Ziembicka

Received: 12 July 2022  
Accepted: 21 September 2022  
Published: 24 September 2022

**Publisher's Note:** MDPI stays neutral with regard to jurisdictional claims in published maps and institutional affiliations.



**Copyright:** © 2022 by the authors. Licensee MDPI, Basel, Switzerland. This article is an open access article distributed under the terms and conditions of the Creative Commons Attribution (CC BY) license (<https://creativecommons.org/licenses/by/4.0/>).

## 1. Introduction

The most common sites of atherosclerotic lesions of the carotid arteries are the bifurcation, the 10–15 mm proximal segment of the internal carotid artery (ICA), and the origin/proximal third of the left common carotid artery (CCA). Atherosclerosis rarely affects the distal part of the ICA [1]. Invasive therapy for atherosclerotic carotid stenoses includes open surgery, stenting, or a combination of both [2,3]. Distal ICA lesions can only be approached with great difficulty by open surgery, either from the retromandibular fossa or by other means (e.g., the mobilization of the parotid gland, double mandibular osteotomy, or mandibular subluxation with styloidectomy) [4–7]. For this reason, stenting rather than open surgery is the invasive option for these patients, even for those who are symptomatic [2].

After open carotid surgery, restenosis occurs in 0.3–9% of cases [8]. Like atherosclerotic stenoses, restenoses can localize to the distal ICA [9]. Stenting is also the main invasive therapy for distal ICA restenoses [2].

Since there are no literature data on the short- and mid-term efficacy of stenting in atherosclerotic or post-surgical restenotic distal ICA stenoses, our aim was to provide information on this topic.

## 2. Materials and Methods

### 2.1. Study Design

This single-center retrospective study analyzed patients (N = 66) who underwent stenting for atherosclerotic or post-surgical restenotic isolated distal ICA stenosis between January 2001 and January 2020.

### 2.2. Stenting Process

For each patient, the vascular team at our center decided on the need for stenting based on the European Society for Vascular Surgery guidelines in force at the time. Patients were considered symptomatic if they had any ischemic neurological event (amaurosis fugax, transient ischemic attack [TIA], minor or major stroke) in the ipsilateral carotid territory within 6 months before the intervention [10].

Stenting was performed in the standard manner [11] by three interventional radiologists with more than 10 years of experience, with the implantation of self-expanding stents and embolic protection. If the patient was not on antiplatelet therapy or was on monotherapy only, 100–300 mg acetylsalicylic acid and/or 75 mg clopidogrel daily was started at least 72 h before the procedure. In urgent cases, a loading dose of 250–500 mg acetylsalicylic acid and/or 300–600 mg clopidogrel was given. In the absence of cardiological or other indications, dual antiplatelet therapy was continued for 1 month after the intervention, followed by monotherapy for an indefinite period [12].

Stenting was technically successful if no extravasation, dissection, or >30% residual stenosis was seen on final digital subtraction angiography (DSA) images [11].

### 2.3. Follow-Up Visits

Follow-up visits were scheduled for the 6th week after the intervention, the 6th and 12th month, and then once a year. However, due to complaints, contralateral invasive carotid procedure, or other reasons, these dates could be changed. Follow-up visits consisted of interviewing the patient and ultrasound examination of the cervical arteries. Restenosis was defined as 50–69% if the peak systolic velocity (PSV) inside the stent or at either end of the stent was 225–350 cm/s and  $\geq 70\%$  if PSV was  $>350$  cm/s [13]. If the distal part of the stent was not visible by ultrasound but indirect signs (ICA flow volume  $<159$  mL/min, ICA PSV  $<33$  cm/s, and/or CCA PSV  $<42$  cm/s) suggested a  $\geq 70\%$  in-stent restenosis (ISR) [14], the patient was submitted to computed tomography angiography (CTA).

### 2.4. Analyzed Parameters

Cardiovascular risk factors and comorbidities (female sex, age  $\geq 80$  years, hypertension, hyperlipidemia, diabetes mellitus, and chronic kidney disease), previous invasive vascular therapies, lesion- and intervention-related parameters, neurological events (amaurosis fugax, TIA, minor or major stroke) before and after the stenting, ISR characteristics and primary patency and mortality rates were assessed. For a definition of cardiovascular risk factors and comorbidities, see another publication by our research group [15]. The parameters of the lesions (localization, grade and length of stenosis, presence, and severity of calcification) were determined on preprocedural CTA scans. By localization, the affected side and the distance of the narrowest part of the ICA stenosis from the bifurcation was meant. The percentage of stenosis was calculated using the formula in the North American Symptomatic Carotid Endarterectomy Trial [16]. The length of the lesion was defined as the distance between the proximal and distal points where the grade of stenosis decreased to 80% of its maximum [17]. The severity of calcification was classified according to Woodcock and four types, such as absent, mild (thin, discontinuous), moderate (thin, continuous or thick, discontinuous), and severe (thick, continuous), were distinguished [18]. Among the intervention-related parameters, the puncture site, the type of embolic protection device, the manufacturer, diameter and length of the balloons and stents, and the complications were collected. Regarding the definition of neurological events, reference is made to a

guideline [19]. ISR characteristics included the ultrasonographic grade, localization (in-stent, persistent, or both), and pattern (focal or diffuse) of restenotic lesions. The ISR was considered focal if it was shorter than 10 mm. Primary patency was defined as freedom from  $\geq 50\%$  ISR or occlusion.

### 2.5. Statistical Analysis

Statistical analysis was performed using SPSS Statistics for Windows (Version 25.0.; IBM Corp., Armonk, NY, USA) and GraphPad Prism 7.01 (GraphPad Software Inc., La Jolla, CA, USA) software. Continuous data were presented as median and interquartile range (IQR) and compared using Mann–Whitney *U* test. Categorical data were expressed as numbers (percentages) and compared using Fisher's exact test. Kaplan–Meier analysis was performed to determine primary patency and mortality rates. Follow-up was maximized at 48 months. Survival curves were compared using a log-rank test. All statistical tests were two-tailed. The threshold for statistical significance was  $p \leq 0.05$ .

## 3. Results

### 3.1. Patient Data

The median age of the 66 patients (women,  $N = 13$ ; men,  $N = 53$ ) was 66 years (IQR, 61–73 years). Patients were divided into two etiological groups, atherosclerotic (AS,  $N = 40$  [60.6%]; median age: 67 years [IQR, 61–74 years]) and post-surgical restenotic (RES,  $N = 26$  [39.4%]; median age: 64.5 years [IQR, 60.5–71 years]). There was no significant difference ( $p = 0.541$ ) in median age between the AS and RES groups. The carotid surgery in all patients was an eversion endarterectomy. The median time between carotid surgery and stenting was 80 months (IQR, 22–148 months). Stenting was carried out in nine patients within 48 months after endarterectomy. Patient-related parameters are shown in Table 1. Of the 66 patients, 15 (22.7%) had some neurological symptoms before stenting. There was no significant difference ( $p > 0.999$ ) in preprocedural neurological events between the two groups. The RES group had significantly more women ( $p = 0.003$ ) and significantly more patients with hypertension ( $p = 0.010$ ), contralateral carotid invasive treatment ( $p = 0.015$ ), and lower extremity arterial reconstruction ( $p = 0.046$ ).

**Table 1.** Preprocedural neurological events, cardiovascular risk factors, comorbidities, and previous invasive vascular therapies.

Patient-Related Parameters	AS Group (N = 40)	RES Group (N = 26)	<i>p</i> -Value
Preprocedural neurological events, N (%)	9 (22.5)	6 (23.1)	>0.999
Amaurosis fugax, N (%)	3 (7.5)	0 (0)	0.273
TIA, N (%)	3 (7.5)	6 (23.1)	0.139
Minor stroke, N (%)	3 (7.5)	0 (0)	0.273
CV risk factors, comorbidities			
Female sex, N (%)	3 (7.5)	10 (38.5)	0.003
Age $\geq 80$ years, N (%)	5 (12.5)	2 (7.7)	0.695
Hypertension, N (%)	28 (70)	25 (96.2)	0.010
Hyperlipidemia, N (%)	13 (32.5)	8 (30.8)	>0.999
Diabetes mellitus, N (%)	8 (20)	8 (30.8)	0.384
Chronic kidney disease, N (%)	2 (5)	4 (15.4)	0.202
Previous invasive vascular therapies			
Coronary artery invasive treatment, N (%)	11 (27.5)	3 (11.5)	0.217
Contralateral carotid artery invasive treatment, N (%)	8 (20)	13 (50)	0.015
Subclavian artery invasive treatment, N (%)	0 (0)	1 (3.8)	0.394
Visceral artery invasive treatment, N (%)	1 (2.5)	2 (7.7)	0.557
Aortic invasive treatment, N (%)	0 (0)	1 (3.8)	0.394
Lower extremity arterial invasive treatment, N (%)	7 (17.5)	11 (42.3)	0.046

AS, Atherosclerotic; CV, cardiovascular; N, number; RES, restenotic; TIA, transient ischemic attack.

### 3.2. Lesion Data

Lesion characteristics can be found in Table 2. The narrowest part of the ICA stenosis was at least 20 mm from the bifurcation in all patients. Among lesion-related parameters, only length was significantly different between the two groups; AS lesions were significantly longer ( $p = 0.002$ ) than RES lesions.

**Table 2.** Lesion characteristics.

Lesion-Related Parameters	AS Group (N = 40)	RES Group (N = 26)	p-Value
Right side, N (%)	15 (37.5)	14 (53.8)	0.214
Distance from the bifurcation (mm), median (IQR)	20.4 (20.1–21.4)	21.5 (20.1–24)	0.126
Stenosis grade (%), median (IQR)	90 (80–90)	90 (85–95)	0.099
Stenosis length (mm), median (IQR)	8.1 (6.1–12)	5.1 (4.1–7.5)	0.002
Calcification, N (%)	25 (62.5)	11 (42.3)	0.133
Mild, N (%)	14 (35)	8 (30.8)	0.794
Moderate, N (%)	8 (20)	1 (3.8)	0.077
Heavy, N (%)	3 (7.5)	2 (7.7)	>0.999

AS, Atherosclerotic; IQR, interquartile range; N, number; RES, restenotic.

### 3.3. Procedure Data

In the AS group, the access site was femoral in 28 cases (70%) and radial in 12 cases (30%), while in the RES group, the access site was femoral in 13 cases (50%), radial in 10 cases (38.5%), and brachial in three cases (11.5%). In the AS group, embolic protection was distal type (FilterWire EZ; Boston Scientific Corp., Marlborough, MA, USA) in 38 patients (95%) and proximal type (Mo.Ma; Medtronic Inc., Minneapolis, MN, USA) in two patients (5%). In the RES group, all patients had distal type embolic protection. Six cases (15%) in the AS group and one case (3.8%) in the RES group required predilation. Five different types of self-expanding stents were used. Twenty-eight (42.4%) of the stents were located only in the ICA and did not extend into the bifurcation and CCA. All stents were postdilated. Technical success was achieved in 100% of cases. The types, diameters, and lengths of balloons and stents are listed in Table 3.

**Table 3.** Balloon and stent characteristics.

Balloon- and Stent-Related Parameters	AS Group (N = 40)	RES Group (N = 26)
Predilation balloons		
Maverick (Boston Scientific Corp., Marlborough, MA, USA), N (%)	4 (10)	0 (0)
Emerge (Boston Scientific Corp.), N (%)	1 (2.5)	0 (0)
Pantera Pro (Biotronik SE & Co. KG, Berlin, Germany), N (%)	1 (2.5)	0 (0)
Sprinter Legend Rx (Medtronic Inc., Minneapolis, MN, USA), N (%)	0 (0)	1 (3.8)
Diameter (mm), range	2.5–4	2.5
Length (mm), range	20–40	12
Postdilation balloons		
Sterling (Boston Scientific Corp.), N (%)	25 (62.5)	12 (46.2)
Maverick (Boston Scientific Corp.), N (%)	8 (20)	5 (19.2)
Viatrac 14 Plus (Abbott Vascular Inc., Santa Clara, CA, USA), N (%)	5 (12.5)	6 (23.1)
Ultra-Soft SV (Boston Scientific Corp.), N (%)	2 (5)	3 (11.5)
Diameter (mm), range	4–6	4–5
Length (mm), range	20–40	20–40
Stents		
Wallstent (Boston Scientific Corp.), N (%)	32 (80)	25 (96.2)
Xact (Abbott Vascular Inc.), N (%)	4 (10)	0 (0)
Roadsaver (Terumo Corp., Tokyo, Japan), N (%)	1 (2.5)	1 (3.8)
Precise Pro Rx (Cordis Corp., Johnson & Johnson Co., Miami, FL, USA), N (%)	2 (5)	0 (0)
Exponent (Medtronic Inc.), N (%)	1 (2.5)	0 (0)
Diameter (mm), range	5–9	5–9
Length (mm), range	25–50	30–50

AS, Atherosclerotic; N, number; RES, restenotic.



### 3.4. Early ( $\leq 30$ Days) Postprocedural Period

There were five intervention-related complications: one inguinal haematoma (1.5%) not requiring evacuation and four neurological events (6.1%; AS group, one TIA and one major stroke; RES group, two TIAs). The parameters of patients with postprocedural neurological complications can be seen in Table 4. TIAs presented as contralateral upper and/or lower limb paresis or dysarthria and lasted no longer than 15 min. None of the TIA patients had an acute ischemic or hemorrhagic brain lesion on post-stenting CT or magnetic resonance images. The time between carotid surgery and stenting was 103 months in Patient 3 and 178 months in Patient 4. The major stroke patient became unconscious 2 h after an uneventful stenting procedure. The emergency CT scan showed extensive bleeding in the ipsilateral frontal and parietal lobes. The patient died on day 37 after stenting.

**Table 4.** Parameters of patients with postprocedural neurological complications.

Parameters	Patient 1 with Postprocedural TIA	Patient 2 with Postprocedural Major Stroke	Patient 3 with Postprocedural TIA	Patient 4 with Postprocedural TIA
Sex	Male	Male	Female	Female
Age	59 years	87 years	67 years	86 years
Etiological group	AS	AS	RES	RES
Preprocedural symptom	No	TIA	Minor stroke	TIA
Contralateral ICA stenosis/occlusion	Occlusion	No	Stenosis	Stenosis
Ipsilateral preprocedural stenosis grade	90%	95%	90%	95%
Ipsilateral preprocedural stenosis length	6.2 mm	16.8 mm	3.3 mm	4.5 mm
Calcification	Mild	Absent	Absent	Mild
Predilatation	No	Yes	No	No
Stent type	Wallstent	Wallstent	Wallstent	Wallstent
Postprocedural ultrasound	Patent stent	Patent stent	Patent stent	Patent stent

AS, Atherosclerotic; RES, restenotic; TIA, transient ischemic attack.

### 3.5. Follow-Up Period

The median follow-up time was 34 months (IQR, 15–87 months) in the AS group and 41 months (IQR, 28–74 months) in the RES group. There was no significant difference ( $p = 0.708$ ) in follow-up time between the two groups. In the AS group, two cases (5%) of 50–69% ISR and one case (2.5%) of  $\geq 70\%$  ISR were detected. All ISRs were located within the stent and were of the focal type. Patients with ISR were asymptomatic. The patient with  $\geq 70\%$  ISR underwent reintervention with a plain balloon (Trek; Abbott Vascular Inc., Santa Clara, CA, USA; size, 4 mm  $\times$  20 mm). No one in the RES group had ISR. The primary patency rate was 97.2% at 6 months, 94.4% at 12 and 24 months, and 89.7% at 36 and 48 months in the AS group and 100% over the entire follow-up period in the RES group. The primary patency rates of the two groups were not significantly different ( $p = 0.528$ ) (Figure 1 and Table 5). During follow-up, three patients (7.5%) in the AS group and seven patients (26.9%) in the RES group died. The cause of death was myocardial infarction in three patients, heart failure in two patients, malignancy in two patients, major stroke in one patient, chronic obstructive pulmonary disease in one patient, and gastrointestinal bleeding in one patient. The survival proportion was 97.4% at 6, 12, and 24 months and 84.1% at 36 and 48 months in the AS group and 100% at 6, 12, and 24 months, 83.8% at 36 months, and 61.5% at 48 months in the RES group. The survival proportions of the two groups were not significantly different ( $p = 0.289$ ) (Figure 2 and Table 6).

**Table 5.** Primary patency.

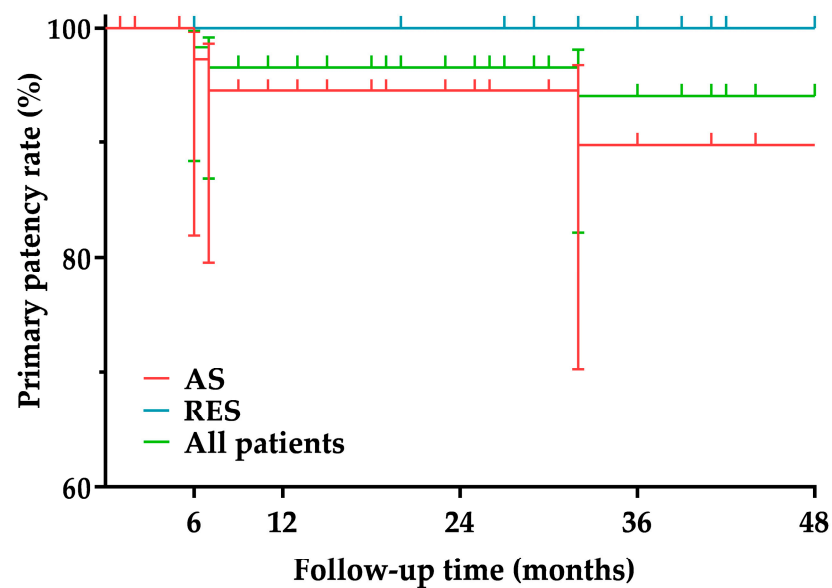
		6 Months	12 Months	24 Months	36 Months	48 Months
All patients	%	98.3	96.5	96.5	94	94
	95% CI	88.4–99.7	86.8–99.1	86.8–99.1	82.1–98.1	82.1–98.1
	Number at risk	58	52	45	35	26
AS group	%	97.2	94.4	94.4	89.7	89.7
	95% CI	81.9–99.6	79.5–98.5	79.5–98.5	70.2–96.7	70.2–96.7
	Number at risk	36	31	25	18	16
RES group	%	100	100	100	100	100
	95% CI	-	-	-	-	-
	Number at risk	22	22	21	17	11

AS, Atherosclerotic; CI, confidence interval; RES, restenotic.

**Table 6.** Survival proportions.

		6 Months	12 Months	24 Months	36 Months	48 Months
All patients	%	98.4	98.4	98.4	83.9	73.9
	95% CI	89.4–99.7	89.4–99.7	89.4–99.7	68.9–92.1	55.7–84.7
	Number at risk	58	54	46	37	28
AS group	%	97.4	97.4	97.4	84.1	84.1
	95% CI	83.1–99.6	83.1–99.6	83.1–99.6	62.3–93.8	62.3–93.8
	Number at risk	37	33	26	20	18
RES group	%	100	100	100	83.8	61.5
	95% CI	-	-	-	57.7–94.5	35.7–79.5
	Number at risk	22	22	21	17	11

AS, Atherosclerotic; CI, confidence interval; RES, restenotic.

**Figure 1.** Primary patency. AS, Atherosclerotic; RES, restenotic.

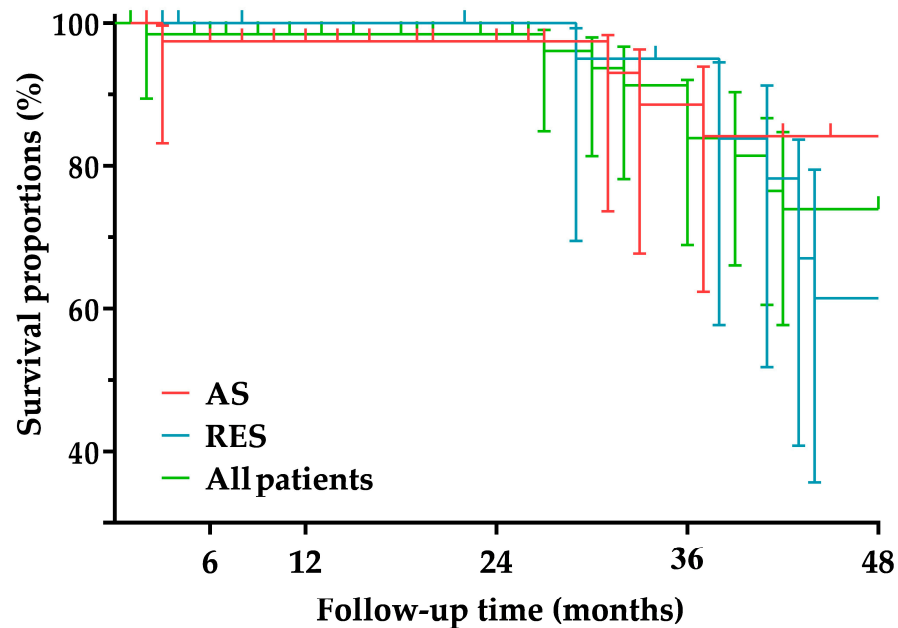


Figure 2. Survival proportions. AS, Atherosclerotic; RES, restenotic.

#### 4. Discussion

Most studies have separately analyzed the short- and mid-/long-term outcomes of carotid artery stenting (CAS) for atherosclerosis and post-surgical restenosis [19,20], but we found eight studies that did so comparatively [21–28]. The two main indicators of the short-term success of CAS are the rate of new or recurrent neurological events and mortality. The rate of stroke within 30 days after stenting ranges from 0% to 9.8%, while the rate of all-cause mortality within 30 days after stenting ranges from 0% to 1.3% for atherosclerotic ICA stenoses [19]. The same rates for post-surgical ICA restenosis stenting range from 0% to 18% and 0% to 2%, respectively [20]. In three of the eight comparative studies, peri- and postprocedural neurological complications were more frequent in patients undergoing stenting for atherosclerotic ICA stenoses [22–24]. The other five studies showed no significant difference in neurological events within 30 days after stenting between the two etiological groups [21,25–28]. The etiology of ICA lesions had no effect on CAS 30-day mortality in any of the comparative studies [21–28]. However, to the best of our knowledge, no study has specifically investigated the outcome of CAS in distal ICA lesions. In our AS group, the rate of neurological complications within 30 days after stenting was 5%, resulting from one TIA and one hemorrhagic stroke; the patient with hemorrhagic stroke died on day 37 after the intervention. The underlying cause of the hemorrhagic stroke was presumably hyperperfusion syndrome. After CAS, hyperperfusion syndrome occurs in 0–21.2% of cases and consequential hemorrhagic stroke in 0–100% of cases [29]. In our RES group, compared to our AS group, a non-significantly higher proportion of patients, 7.7%, developed neurological symptoms within 30 days after stenting, but no deaths were recorded in the early postprocedural period. Thus, the short-term success rates for stenting distal ICA (re)stenoses are not worse than the rates reported for stenting ICA (re)stenoses in general (without defining the lesion location).

The mid-/long-term outcome of CAS is best characterized by ISR and mortality rates. In some publications, both the  $\text{ISR} \geq 50\%$  rate and the  $\text{ISR} \geq 70\%$  rate are given [30–32], while in others, only the  $\text{ISR} \geq 70\%$  rate is mentioned [33–38]. Based on literature data, the prevalence of  $\text{ISR} \geq 50\%$  after stenting for atherosclerotic ICA lesions is between 0% and 37% [30–32], while the prevalence of  $\text{ISR} \geq 70\%$  is between 0% and 9.8% [33–38]. For post-surgical ICA restenosis stenting, these incidences range from 0% to 15% [39,40] and 0% to 9.5% [41,42], respectively. Of the eight comparative studies, only two examined ISR (one considered  $\text{ISR} \geq 50\%$  [21], the other considered  $\text{ISR} \geq 70\%$  as the endpoint [26]), and

none revealed a significant difference in the prevalence of ISR between the two etiological groups [21,26]. In our patient population, the incidence of ISR was non-significantly higher in the AS group (ISR  $\geq$  50%, 7.5% and ISR  $\geq$  70%, 2.5%) than in the RES group (ISR  $\geq$  50%, 0% and ISR  $\geq$  70%, 0%). Thus, the ISR rates for stenting distal ICA (re)stenoses (such as the short-term results) are not worse than the rates reported for stenting ICA (re)stenoses in general (without defining the lesion location).

Only a few publications were found that included mid-/long-term mortality rates for CAS. For CAS performed for atherosclerotic ICA stenoses, the mid-/long-term mortality rate ranges from 12.1% to 35% [18,20,30,32,42,43], while for CAS performed for post-surgical ICA restenoses, the mid-/long-term mortality rate ranges from 9.6% to 11.8% [20,41,44]. Of the eight comparative studies, only one study aimed to determine the mid-term (4-year) mortality rate [21]. In this study, there was no significant difference in the 4-year mortality rate between CAS for atherosclerosis (12.1%) and CAS for post-surgical restenosis (11.8%) [21]. The mid-term mortality rate of 7.5% in our AS group is low, while the mid-term mortality rate of 26.9% in our RES group is quite high in light of the literature. It is important to note, however, that none of the deaths in our RES group were directly related to CAS itself; the deaths were the result of other serious comorbidities in the patients.

Our study has two main limitations: its retrospective nature and the relatively small number of patients.

## 5. Conclusions

The early complication and ISR rates of distal ICA stenting are acceptable and are not influenced by the etiology of the lesion. However, the mid-term mortality rate of the RES group is high. The lower survival is probably not due to the stenting procedure but rather to the more complex comorbidity profile of the RES population.

**Author Contributions:** Conceptualization, D.T.N. and E.D.; methodology, D.T.N.; software, D.T.N.; validation, Á.B., B.B.N. and Á.S.; formal analysis, D.T.N.; investigation, D.T.N. and M.P.; resources, E.D.; data curation, B.B.N. and Á.S.; writing—original draft preparation, D.T.N.; writing—review and editing, E.D.; visualization, Á.B.; supervision, E.D.; project administration, M.P.; funding acquisition, Á.B. and B.B.N. All authors have read and agreed to the published version of the manuscript.

**Funding:** This research was funded by the EFOP-3.6.3-VEKOP-16-2017-00009 project (Á.B. and B.B.N.).

**Institutional Review Board Statement:** The study was conducted in accordance with the Declaration of Helsinki and approved by the Ethics Committee of the Semmelweis University (approval number 222/2017).

**Informed Consent Statement:** Due to the retrospective nature of the study, no informed consent for analysis of data was obtained from patients.

**Data Availability Statement:** The data presented in this study are available on request from the corresponding author. The data are not publicly available due to reasons pertaining to patient privacy.

**Conflicts of Interest:** The authors declare no conflict of interest.

## References

1. Bonati, L.H.; Brown, M.M. Carotid artery disease. In *Stroke: Pathophysiology, Diagnosis, and Management*; Grotta, J.C., Albers, G.W., Broderick, J.P., Kasner, S.E., Lo, E.H., Mendelow, A.D., Sacco, R.L., Wong, L.K.S., Eds.; Elsevier—Health Sciences Division: Amsterdam, The Netherlands, 2016; p. 326.
2. Naylor, A.R.; Ricco, J.B.; de Borst, G.J.; Debus, S.; de Haro, J.; Halliday, A.; Hamilton, G.; Kakisis, J.; Kakkos, S.; Lepidi, S.; et al. Editor's Choice—Management of Atherosclerotic Carotid and Vertebral Artery Disease: 2017 Clinical Practice Guidelines of the European Society for Vascular Surgery (ESVS). *Eur. J. Vasc. Endovasc. Surg.* **2018**, *55*, 3–81. [[CrossRef](#)] [[PubMed](#)]
3. Kwolek, C.J.; Jaff, M.R.; Leal, J.I.; Hopkins, L.N.; Shah, R.M.; Hanover, T.M.; Macdonald, S.; Cambria, R.P. Results of the ROADSTER multicenter trial of transcrotid stenting with dynamic flow reversal. *J. Vasc. Surg.* **2015**, *62*, 1227–1234. [[CrossRef](#)] [[PubMed](#)]
4. Buckley, M.; Carlson, E.; Heidel, E.; McNally, M.; Hodge, A.; Fahmy, M.; Arnold, J.; Grandas, O.; Freeman, M. Double Mandibular Osteotomy for Access to High-Carotid Pathology. *Ann. Vasc. Surg.* **2021**, *70*, 202–212. [[CrossRef](#)] [[PubMed](#)]

5. Mock, C.N.; Lilly, M.P.; McRae, R.G.; Carney, W.I., Jr. Selection of the approach to the distal internal carotid artery from the second cervical vertebra to the base of the skull. *J. Vasc. Surg.* **1991**, *13*, 846–853. [[CrossRef](#)]
6. Izci, Y.; Moftakhar, R.; Pyle, M.; Başkaya, M.K. Retromandibular fossa approach to the high cervical internal carotid artery: An anatomic study. *Neurosurgery* **2008**, *62*, ONS363–ONS370, discussion ONS369–ONS370. [[CrossRef](#)]
7. Naylor, A.R.; Moir, A. An aid to accessing the distal internal carotid artery. *J. Vasc. Surg.* **2009**, *49*, 1345–1347. [[CrossRef](#)]
8. Szabo, A.; Brazda, E.; Dosa, E.; Apor, A.; Szabolcs, Z.; Entz, L. Long-term restenosis rate of eversion endarterectomy on the internal carotid artery. *Eur. J. Vasc. Endovasc. Surg.* **2004**, *27*, 537–539. [[CrossRef](#)]
9. Gaudry, M.; Bartoli, J.M.; Bal, L.; Giorgi, R.; De Masi, M.; Magnan, P.E.; Piquet, P. Anatomical and Technical Factors Influence the Rate of In-Stent Restenosis following Carotid Artery Stenting for the Treatment of Post-Carotid Endarterectomy Stenosis. *PLoS ONE* **2016**, *11*, e0161716. [[CrossRef](#)]
10. Timaran, C.H.; McKinsey, J.F.; Schneider, P.A.; Littooy, F. Reporting standards for carotid interventions from the Society for Vascular Surgery. *J. Vasc. Surg.* **2011**, *53*, 1679–1695. [[CrossRef](#)]
11. Nguyen, D.T.; Vokó, B.; Nyáradi, B.B.; Munkácsi, T.; Bérczi, Á.; Vokó, Z.; Dósa, E. Restenosis rates in patients with ipsilateral carotid endarterectomy and contralateral carotid artery stenting. *PLoS ONE* **2022**, *17*, e0262735. [[CrossRef](#)]
12. Aboyans, V.; Ricco, J.B.; Bartelink, M.E.L.; Björck, M.; Brodmann, M.; Cohnert, T.; Collet, J.P.; Czerny, M.; De Carlo, M.; Debus, S.; et al. 2017 ESC Guidelines on the Diagnosis and Treatment of Peripheral Arterial Diseases, in collaboration with the European Society for Vascular Surgery (ESVS): Document covering atherosclerotic disease of extracranial carotid and vertebral, mesenteric, renal, upper and lower extremity arteries. Endorsed by: The European Stroke Organization (ESO), the Task Force for the Diagnosis and Treatment of Peripheral Arterial Diseases of the European Society of Cardiology (ESC) and of the European Society for Vascular Surgery (ESVS). *Eur. Heart J.* **2018**, *39*, 763–816. [[CrossRef](#)] [[PubMed](#)]
13. Stanziale, S.F.; Wholey, M.H.; Boules, T.N.; Selzer, F.; Makaroun, M.S. Determining in-stent stenosis of carotid arteries by duplex ultrasound criteria. *J. Endovasc. Ther.* **2005**, *12*, 346–353. [[CrossRef](#)] [[PubMed](#)]
14. Lee, J.D.; Ryu, S.J.; Chang, Y.J.; Hsu, K.C.; Chen, Y.C.; Huang, Y.C.; Lee, M.; Hsiao, M.C.; Lee, T.H. Carotid ultrasound criteria for detecting intracranial carotid stenosis. *Eur. Neurol.* **2007**, *57*, 156–160. [[CrossRef](#)]
15. Dósa, E.; Hirschberg, K.; Apor, A.; Járányi, Z.; Entz, L.; Acsády, G.; Hüttl, K. Echolucent or predominantly echolucent femoral plaques predict early restenosis after eversion carotid endarterectomy. *J. Vasc. Surg.* **2010**, *51*, 345–350. [[CrossRef](#)]
16. North American Symptomatic Carotid Endarterectomy Trial Collaborators; Barnett, H.J.M.; Taylor, D.W.; Haynes, R.B.; Sackett, D.L.; Peerless, S.J.; Ferguson, G.G.; Fox, A.J.; Rankin, R.N.; Hachinski, V.C.; et al. Beneficial effect of carotid endarterectomy in symptomatic patients with high-grade carotid stenosis. *N. Engl. J. Med.* **1991**, *325*, 445–453. [[CrossRef](#)] [[PubMed](#)]
17. Bonati, L.H.; Ederle, J.; Dobson, J.; Engelter, S.; Featherstone, R.L.; Gaines, P.A.; Beard, J.D.; Venables, G.S.; Markus, H.S.; Clifton, A.; et al. Length of carotid stenosis predicts peri-procedural stroke or death and restenosis in patients randomized to endovascular treatment or endarterectomy. *Int. J. Stroke* **2014**, *9*, 297–305. [[CrossRef](#)]
18. Woodcock, R.J., Jr.; Goldstein, J.H.; Kallmes, D.F.; Cloft, H.J.; Phillips, C.D. Angiographic correlation of CT calcification in the carotid siphon. *AJNR Am. J. Neuroradiol.* **1999**, *20*, 495–499. [[PubMed](#)]
19. Müller, M.D.; Lyrer, P.; Brown, M.M.; Bonati, L.H. Carotid artery stenting versus endarterectomy for treatment of carotid artery stenosis. *Cochrane Database Syst. Rev.* **2020**, *2*, CD000515. [[CrossRef](#)]
20. Texakalidis, P.; Giannopoulos, S.; Jonnalagadda, A.K.; Kokkinidis, D.G.; Machinis, T.; Reavey-Cantwell, J.; Armstrong, E.J.; Jabbour, P. Carotid Artery Endarterectomy versus Carotid Artery Stenting for Restenosis After Carotid Artery Endarterectomy: A Systematic Review and Meta-Analysis. *World Neurosurg.* **2018**, *115*, 421–429.e1. [[CrossRef](#)]
21. AbuRahma, A.F.; Abu-Halimah, S.; Bensenhaver, J.; Nanjundappa, A.; Stone, P.A.; Dean, L.S.; Keiffer, T.; Emmett, M.; Tarakji, M.; AbuRahma, Z. Primary carotid artery stenting versus carotid artery stenting for postcarotid endarterectomy stenosis. *J. Vasc. Surg.* **2009**, *50*, 1031–1039. [[CrossRef](#)]
22. White, R.A.; Sicard, G.A.; Zwolak, R.M.; Sidawy, A.N.; Schermerhorn, M.L.; Shackelton, R.J.; Siami, F.S.; SVS Outcomes Committee. Society of vascular surgery vascular registry comparison of carotid artery stenting outcomes for atherosclerotic vs nonatherosclerotic carotid artery disease. *J. Vasc. Surg.* **2010**, *51*, 1116–1123. [[CrossRef](#)] [[PubMed](#)]
23. Cuadra, S.; Hobson, R.W.; Lal, B.K.; Goldstein, J.; Chakhtoura, E.; Jamil, Z. Outcome of carotid artery stenting for primary versus restenotic lesions. *Ann. Vasc. Surg.* **2009**, *23*, 330–334. [[CrossRef](#)] [[PubMed](#)]
24. Kahlberg, A.; Ardita, V.; Spertino, A.; Mascia, D.; Bertoglio, L.; Baccellieri, D.; Lembo, R.; Melissano, G.; Chiesa, R. Propensity-Matched Comparison for Carotid Artery Stenting in Primary Stenosis versus after Carotid Endarterectomy Restenosis. *Ann. Vasc. Surg.* **2021**, *70*, 332–340. [[CrossRef](#)] [[PubMed](#)]
25. Hynes, B.G.; Kennedy, K.F.; Ruggiero, N.J., 2nd; Kiernan, T.J.; Margey, R.J.; Rosenfield, K.; Garasic, J.M. Carotid artery stenting for recurrent carotid artery restenosis after previous ipsilateral carotid artery endarterectomy or stenting: A report from the National Cardiovascular Data Registry. *JACC Cardiovasc. Interv.* **2014**, *7*, 180–186. [[CrossRef](#)]
26. Mousa, A.Y.; AbuRahma, A.F.; Bozzay, J.; Broce, M.; Kali, M.; Yacoub, M.; Stone, P.; Bates, M.C. Long-term Comparative Outcomes of Carotid Artery Stenting Following Previous Carotid Endarterectomy vs De Novo Lesions. *J. Endovasc. Ther.* **2015**, *22*, 449–456. [[CrossRef](#)]
27. Arhuidese, I.J.; Rizwan, M.; Nejm, B.; Malas, M. Outcomes of Primary and Secondary Carotid Artery Stenting. *Stroke* **2017**, *48*, 3086–3092. [[CrossRef](#)]

28. Fokkema, M.; de Borst, G.J.; Nolan, B.W.; Lo, R.C.; Cambria, R.A.; Powell, R.J.; Moll, F.L.; Schermerhorn, M.L.; Vascular Study Group of New England. Carotid stenting versus endarterectomy in patients undergoing reintervention after prior carotid endarterectomy. *J. Vasc. Surg.* **2014**, *59*, e1–e2. [[CrossRef](#)]
29. Huibers, A.E.; Westerink, J.; de Vries, E.E.; Hoskam, A.; den Ruijter, H.M.; Moll, F.L.; de Borst, G.J. Editor's Choice—Cerebral Hyperperfusion Syndrome After Carotid Artery Stenting: A Systematic Review and Meta-analysis. *Eur. J. Vasc. Endovasc. Surg.* **2018**, *56*, 322–333. [[CrossRef](#)]
30. Hoffmann, A.; Taschner, C.; Engelter, S.T.; Lyrer, P.A.; Rem, J.; Radue, E.W.; Kirsch, E.C. Carotid artery stenting versus carotid endarterectomy. A prospective, randomised trial with long term follow up (BACASS). *Schweiz. Arch. Neurol. Psychiatr.* **2006**, *157*, 191–192.
31. Steinbauer, M.G.; Pfister, K.; Greindl, M.; Schlachetzki, F.; Borisch, I.; Schuirer, G.; Feuerbach, S.; Kasprzak, P.M. Alert for increased long-term follow-up after carotid artery stenting: Results of a prospective, randomized, single-center trial of carotid artery stenting vs carotid endarterectomy. *J. Vasc. Surg.* **2008**, *48*, 93–98. [[CrossRef](#)]
32. Bonati, L.H.; Gregson, J.; Dobson, J.; McCabe, D.J.H.; Nederkoorn, P.J.; van der Worp, H.B.; de Borst, G.J.; Richards, T.; Cleveland, T.; Müller, M.D.; et al. Restenosis and risk of stroke after stenting or endarterectomy for symptomatic carotid stenosis in the International Carotid Stenting Study (ICSS): Secondary analysis of a randomised trial. *Lancet Neurol.* **2018**, *17*, 587–596. [[CrossRef](#)]
33. Mas, J.L.; Arquizan, C.; Calvet, D.; Viguier, A.; Albuquer, J.F.; Piquet, P.; Garnier, P.; Viader, F.; Giroud, M.; Hosseini, H.; et al. Long-term follow-up study of endarterectomy versus angioplasty in patients with symptomatic severe carotid stenosis trial. *Stroke* **2014**, *45*, 2750–2756. [[CrossRef](#)] [[PubMed](#)]
34. Liu, C.W.; Liu, B.; Ye, W.; Wu, W.W.; Li, Y.J.; Zheng, Y.H.; Wu, J.D.; Zeng, R.; Guan, H. [Carotid endarterectomy versus carotid stenting: A prospective randomized trial]. *Zhonghua Wai Ke Za Zhi* **2009**, *47*, 267–270.
35. Eckstein, H.H.; Ringleb, P.; Allenberg, J.R.; Berger, J.; Fraedrich, G.; Hacke, W.; Hennerici, M.; Stingele, R.; Fiehler, J.; Zeumer, H.; et al. Results of the Stent-Protected Angioplasty versus Carotid Endarterectomy (SPACE) study to treat symptomatic stenoses at 2 years: A multinational, prospective, randomised trial. *Lancet Neurol.* **2008**, *7*, 893–902. [[CrossRef](#)]
36. Brott, T.G.; Howard, G.; Roubin, G.S.; Meschia, J.F.; Mackey, A.; Brooks, W.; Moore, W.S.; Hill, M.D.; Mantese, V.A.; Clark, W.M.; et al. Long-Term Results of Stenting versus Endarterectomy for Carotid-Artery Stenosis. *N. Engl. J. Med.* **2016**, *374*, 1021–1031. [[CrossRef](#)] [[PubMed](#)]
37. Wang, P.; Liang, C.; Du, J.; Li, J. Effects of carotid endarterectomy and carotid artery stenting on high-risk carotid stenosis patients. *Pak. J. Med. Sci.* **2013**, *29*, 1315–1318. [[CrossRef](#)]
38. Mannheim, D.; Karmeli, R. A prospective randomized trial comparing endarterectomy to stenting in severe asymptomatic carotid stenosis. *J. Cardiovasc. Surg.* **2017**, *58*, 814–817. [[CrossRef](#)]
39. Antonello, M.; Deriu, G.P.; Frigatti, P.; Amistà, P.; Lepidi, S.; Stramanà, R.; Battocchio, P.; Dall'Antonia, A.; Grego, F. Does the type of carotid artery closure influence the management of recurrent carotid artery stenosis? Results of a 6-year prospective comparative study. *Surgery* **2008**, *143*, 51–57. [[CrossRef](#)]
40. AbuRahma, A.F.; Abu-Halimah, S.; Hass, S.M.; Nanjundappa, A.; Stone, P.A.; Mousa, A.; Lough, E.; Dean, L.S. Carotid artery stenting outcomes are equivalent to carotid endarterectomy outcomes for patients with post-carotid endarterectomy stenosis. *J. Vasc. Surg.* **2010**, *52*, 1180–1187. [[CrossRef](#)]
41. Dorigo, W.; Pulli, R.; Fargion, A.; Pratesi, G.; Angiletta, D.; Aletto, I.; Alessi Innocenti, A.; Pratesi, C. Comparison of open and endovascular treatments of post-carotid endarterectomy restenosis. *Eur. J. Vasc. Endovasc. Surg.* **2013**, *45*, 437–442. [[CrossRef](#)]
42. Marques de Marino, P.; Martinez Lopez, I.; Hernandez Mateo, M.M.; Cernuda Artero, I.; Cabrero Fernandez, M.; Reina Gutierrez, M.T.; Serrano Hernandez, F.J. Open Versus Endovascular Treatment for Patients with Post-Carotid Endarterectomy Restenosis: Early and Long-term Results. *Ann. Vasc. Surg.* **2016**, *36*, 159–165. [[CrossRef](#)] [[PubMed](#)]
43. Rinaldo, L.; Bhargav, A.G.; Arnold Fiebelkorn, C.E.; Lanzino, G. Long-Term Mortality After Carotid Stenting. *World Neurosurg.* **2020**, *141*, e589–e599. [[CrossRef](#)] [[PubMed](#)]
44. Wen, L.; Wang, S.; Liu, L.; Chen, L.; Geng, J.; Kuang, L.; Qian, G.; Su, J.; Chen, K.; Zhou, Z. The Long-Term Efficacy and Safety of Carotid Artery Stenting among the Elderly: A Single-Center Study in China. *Behav. Neurol.* **2018**, *2018*, 4707104. [[CrossRef](#)] [[PubMed](#)]

# Mid-term results and predictors of restenosis in patients undergoing endovascular therapy for isolated popliteal artery steno-occlusive disease

## IMAGING

DAT TIN NGUYEN, PATRIK BAYERLE, MIKLÓS VÉRTES, ÁKOS BÉRCZI and EDIT DÓSA\* 

Heart and Vascular Center, Semmelweis University, Budapest, Hungary

Received: July 23, 2020 • Revised manuscript received: September 20, 2020 • Accepted: November 24, 2020

## ORIGINAL RESEARCH PAPER



### ABSTRACT

**Background and aim:** There is only a limited number of major publications on the outcome of interventions for isolated popliteal artery stenosis. The purpose of this study was to report our results on mid-term patency and predictors of restenosis.

**Patients and methods:** This single-center retrospective study included 61 symptomatic patients (males,  $N = 33$ ; median age, 65.1 years [IQR, 60.7–71.9 years]; Rutherford grade 4–6,  $N = 14$ ) with at least two patent crural arteries, whose atherosclerotic stenoses/occlusions were treated with percutaneous transluminal angioplasty (PTA) or stenting (using self-expanding bare-metal Astron Pulsar stents) between 2011 and 2018.

**Results:** Twenty-six patients had PTA, while 35 underwent stenting. The median follow-up was 29 months (IQR, 10–47 months). The primary patency rates were not significantly different ( $P = 0.629$ ) between PTA and stenting groups. Restenosis developed in nine patients (34.6%) in the PTA group, and in 12 (34.3%) in the stenting group. Restenotic lesions required re-intervention in nine cases (100%) in the PTA group, and in eight (66.7%) in the stenting group. Restenosis developed significantly less frequently ( $P = 0.010$ ) in patients with a popliteal/P1 stent; the primary patency rates were also significantly better ( $P = 0.018$ ) in patients with a popliteal/P1 stent when compared to popliteal/P2 plus multi-segment stents. Cox regression analysis identified lesion location as a predictor of in-stent restenosis (HR, 2.5; 95% CI, 1.2–5.5;  $P = 0.019$ ).

**Conclusion:** Stenting was not superior when compared to PTA (if selective stenting was not considered as loss of patency). Follow-up should be more thorough in patients undergoing popliteal/P2 or multi-segment stenting.

### KEYWORDS

popliteal artery, endovascular therapy, PTA, stenting, restenosis, patency

## Introduction

Popliteal artery steno-occlusive disease could be truly isolated if no stenosis or occlusion were present elsewhere in the ipsilateral lower extremity. Atherosclerosis is usually a multilevel pathological process, therefore the probability of an isolated popliteal manifestation is minimal. In many cases, the cause of a truly isolated popliteal artery luminal narrowing is from external compression due to e.g. entrapment syndrome or cystic adventitial disease.

In the majority of studies, a presumed atherosclerotic popliteal artery stenosis is considered isolated if the patient has no ipsilateral femoral artery stenosis, requiring invasive therapy. However, publications are heterogeneous in terms of arterial runoff and the type of radiological intervention used [1–7]. Although percutaneous transluminal angioplasty (PTA) with a plain or drug-coated balloon plus or minus bare-metal stenting is the most commonly applied treatment method [1, 2, 4, 7–11], reports have outlined stentgraft implantation [12]

IMAGING 13 (2021) 1, 69–75  
DOI: 10.1556/1647.2020.00010

© 2020 The Author(s)

\*Corresponding author. Heart and Vascular Center, Semmelweis University, Városmajor Street 68, Budapest 1122, Hungary. Tel.: +36 20 825 8108; fax: +36 1 458 6746. E-mail: drdosaedit@gmail.com

and atherectomy [3, 4, 13]. However, studies also appear to be inconsistent in terms of the composition of deployed (mainly self-expanding) stents [1, 2, 5, 7–9, 11].

The mid- and long-term efficacy of endovascular procedures can be characterized by the restenosis rate. Depending on radiological intervention types, the restenosis rate of popliteal endovascular therapy is approximately 5–70% [1–6], which is slightly better than the restenosis rate of femoropopliteal interventions (40–70%; most likely because femoral lesions are almost always longer than popliteal lesions, and the longer the treated lesion, the greater the probability of restenosis) [14, 15].

Therefore, the goal of this study was to examine mid-term results of endovascular methods and identify predictors of restenosis in a single-center, homogeneous population in terms of crural runoff arteries and implanted stent type.

## Patients and methods

### Patient selection

Sixty-one patients from a single institution, who underwent an intervention for symptomatic isolated popliteal artery *de novo* steno-occlusive disease (no ipsilateral iliofemoral stenosis, two patent crural run-off arteries) between June 2011 and June 2018, were retrospectively analyzed. The study procedures were carried out in accordance with the Declaration of Helsinki. Institutional review board approval was granted (Approval No: 138/2013). Due to the retrospective nature of the study, no informed consent for analysis of data was obtained from patients.

### Pre-procedural data

The following clinical data were collected from our medical record archiving system (MedSol; T-Systems Hungary Ltd., Budapest, Hungary): age; gender; anthropometric parameters (e.g. weight, height); atherosclerotic risk factors and comorbidities (smoking, hypertension, hyperlipidemia, diabetes mellitus, chronic kidney disease); past medical history (coronary, supra-aortic, and/or lower extremity radiological interventions or surgical reconstructions); Rutherford grade [16]; ankle-brachial index (ABI); and medication regimen.

### Procedural information

Radiological interventions were executed through the common femoral artery. The choice of approach (antegrade versus retrograde) was left to the discretion of the interventional radiologist performing the procedure. Patients underwent either PTA or stenting (selective or primary). Selective stenting was defined as stent placement after PTA with suboptimal results (residual stenosis of  $\geq 30\%$ , flow-limiting dissection). Primary stenting was defined as stent placement after predilation of the lesion, regardless of the PTA outcome [17]. Generally, in patients with non-occlusive, short lesions, PTA was favored, while in the presence of heavily calcified, long lesions or total occlusions, primary

stenting was chosen. All procedures were performed by three experienced interventional radiologists with more than 10 years of experience in the treatment of peripheral arterial occlusive disease.

Technical success was defined as  $< 30\%$  residual stenosis without dissection or extravasation [16]. Punctured arteries were manually compressed. In uncomplicated cases, patients were discharged 1–2 days after the procedure. Patients were on dual antiplatelet therapy for 1 month, followed by a lifelong acetylsalicylic acid or clopidogrel monotherapy.

### Post-procedural data

According to international and in-house guidelines, patients were scheduled for a follow-up visit at 6 weeks, 6 months, and 12 months after the intervention, and yearly thereafter, or sooner if symptoms arose. The following follow-up data were collected: Rutherford grade [16], ABI, and duplex ultrasound (DUS) results. Significant restenosis was defined as peak systolic velocity of  $\geq 250$  cm/s as measured by DUS in the treated popliteal segment. Primary patency was defined as a patent popliteal artery, without further intervention. Secondary patency was defined as an open popliteal artery after endovascular re-intervention or surgical reconstruction due to restenosis. Clinical success was defined as subjective improvements as reported by the patient, and/or at least one stage improvement in Rutherford grade.

### Imaging data

Digital subtraction angiography data were extracted from picture archiving and communication systems (PACS; GE Healthcare Inc., Chicago, IL, USA). Lesion parameters consisted of localization (P1: from the intercondylar fossa to the proximal edge of the patella; P2: from the proximal edge of the patella to the center point of the knee joint; P3: from the center of the knee joint to the origin of the anterior tibial artery, and multi-segment disease: combinations of the above) [18], stenosis grade and length, calcification presence and grade, and residual stenosis grade.

Calcification was evaluated on the baseline fluoroscopic images. Lesions were mildly calcified if single or multiple punctate calcifications were present, moderately calcified if single or multiple linear areas of calcification were seen, and heavily calcified if continuous calcification with no visible breaks was observed [19].

### Analyzed parameters

Both PTA and stenting groups were divided into restenotic and non-restenotic subgroups, and were compared for pre-procedural, imaging, procedural, and post-procedural data.

### Statistical analysis

Statistical analyses were performed using StatSoft Statistica 13.4 (Moonsoft Oy, Espoo, Finland) and GraphPad Prism 7.01 (GraphPad Software Inc., La Jolla, CA, USA) software. Continuous data were expressed as medians and interquartile ranges (IQR, Q1–Q3); categorical data were





represented as counts (percentages). Significant differences in groups/subgroups for continuous and categorical data were evaluated using Mann-Whitney *U* and Fisher's exact tests, respectively. Patency was calculated using Kaplan-Meier analysis. Kaplan-Meier curves were compared using a log-rank test. Cox regression analysis was used to determine significant predictors of restenosis; the hazard ratio (HR) was presented together with its 95% confidence interval (CI). The threshold for statistical significance was  $P < 0.05$ .

## Results

### Patient data

Twenty-six patients (42.6%) were in the PTA group, while 35 patients (57.4%) were in the stenting group.

The median age was 65.1 years (IQR, 60.7–71.9 years) in the PTA group. Indications for radiological intervention were severe claudication (Rutherford grade 3) in 12 cases (46.2%), and critical limb ischemia (CLI; Rutherford grade 4–6) in 14 cases (53.8%). Twenty-two patients (84.6%) smoked, 22 (84.6%) had hypertension, 10 (38.5%) had hyperlipidemia, 13 (50%) had diabetes mellitus, six (23.1%) were obese, and three (11.5%) had chronic kidney disease (Table 1). Six patients (23.1%) had coronary artery bypass grafting and/or percutaneous coronary intervention, one

patient (3.8%) had supra-aortic surgical and/or endovascular reconstruction, and three patients (11.5%) had contralateral lower extremity open and/or percutaneous revascularization.

In the stenting group, the median age was 63.5 years (IQR, 56.9–71 years). Indications for radiological intervention were severe claudication in 21 cases (60%), and CLI in 14 cases (40%). Thirty patients (85.7%) smoked, 30 (85.7%) had hypertension, 20 (57.1%) had hyperlipidemia, 15 (42.9%) had diabetes mellitus, 11 (31.4%) were obese, and one (2.9%) had chronic kidney disease (Table 2). Six patients (17.1%) had coronary artery bypass grafting and/or percutaneous coronary intervention, three patients (8.6%) had supra-aortic surgical and/or endovascular reconstruction, and 14 patients (40%) had contralateral lower extremity open and/or percutaneous revascularization.

### Lesion, balloon, and stent characteristics

For all cases, the pathological background was atherosclerosis. The ipsilateral antegrade approach was chosen in 42 patients (68.9%), while the contralateral approach was used in 19 cases (31.1%).

In the PTA group, lesions were left-sided in 12 patients (46.2%). Steno-occlusive disease affected the P1 segment in 13 cases (50%), and the P2 in eight cases (30.8%). Multi-segment disease within the popliteal artery was observed in five cases (19.2%). The median degree of stenosis was 95%

Table 1. Indication for treatment, atherosclerotic risk factors, and comorbidities in the PTA group

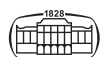
Indication, atherosclerotic risk factors, comorbidities	PTA group (N = 26)		P value
	RR subgroup (N = 9)	Non-RR subgroup (N = 17)	
CLI, N (%)	4 (44.4)	10 (58.8)	>0.999
Age (year), median (IQR)	70.3 (63–75.5)	63.5 (56.2–69.9)	0.124
Female gender, N (%)	5 (55.6)	11 (64.7)	0.692
Smoking, N (%)	9 (100)	13 (76.5)	0.263
Hypertension, N (%)	9 (100)	13 (76.5)	0.263
Hyperlipidemia, N (%)	3 (33.3)	7 (41.2)	0.206
Diabetes mellitus, N (%)	4 (44.4)	9 (52.9)	>0.999
Obesity (BMI ≥ 30 kg/m <sup>2</sup> ), N (%)	2 (22.2)	4 (23.5)	>0.999
Chronic kidney disease, N (%)	1 (11.1)	2 (11.8)	>0.999

BMI, Body mass index; CLI, critical limb ischemia; IQR, interquartile range; PTA, percutaneous transluminal angioplasty; RR, restenotic.

Table 2. Indication for treatment, atherosclerotic risk factors, and comorbidities in the stenting group

Indication, atherosclerotic risk factors, comorbidities	Stenting group (N = 35)		P value
	RR subgroup (N = 12)	Non-RR subgroup (N = 23)	
CLI, N (%)	6 (50)	8 (34.8)	0.477
Age (year), median (IQR)	63.3 (57.9–70.2)	63.5 (56.9–71.5)	0.794
Female gender, N (%)	3 (25)	9 (39.1)	0.477
Smoking, N (%)	11 (91.7)	19 (82.6)	0.640
Hypertension, N (%)	10 (83.3)	20 (87)	>0.999
Hyperlipidemia, N (%)	6 (50)	14 (60.9)	0.721
Diabetes mellitus, N (%)	5 (41.7)	10 (43.5)	>0.999
Obesity (BMI ≥ 30 kg/m <sup>2</sup> ), N (%)	2 (16.7)	9 (39.1)	>0.999
Chronic kidney disease, N (%)	0 (0)	1 (4.3)	>0.999

BMI, Body mass index; CLI, critical limb ischemia; IQR, interquartile range; RR, restenotic.



(IQR, 90–100%), the median lesion length was 26.7 mm (IQR, 11.6–72.9 mm), and calcification was observed in 13 patients (50%). The median balloon diameter and the median balloon length were 5 mm (IQR, 5–5 mm) and 40 mm (IQR, 40–80 mm), respectively (Table 3).

In the stenting group, lesions were left-sided in 15 patients (42.9%). Steno-occlusive disease affected the P1 segment in 14 cases (40%), and the P2 in 12 cases (34.3%). Multi-segment disease within the popliteal artery was present in nine cases (25.7%). The median degree of stenosis was 100% (IQR, 90–100%), the median lesion length was 52.8 mm (IQR, 23.4–80.6 mm), and calcification was observed in 22 patients (62.9%) (Table 4). In all cases, a self-expanding Astron Pulsar stent (Biotronik AG, Bülach, Switzerland) was deployed. The median stent diameter was 6 mm (IQR, 6–7 mm), while the median stent length was 60 mm (IQR, 40–120 mm). Primary stenting was performed in

15 patients (42.9%), while selective stenting was chosen for 20 cases (57.1%).

### Early post-procedural period (within 30 days)

Technical success was achieved in 100% of patients. In one of the stented patients, a retroperitoneal hematoma was observed, but did not require evacuation. After observation for 2 days, the patient was discharged. None of the patients had distal embolization. The 30-day all-cause mortality rate was zero.

### Follow-up period

At 6 weeks, the clinical success rate was 92% in the PTA group, while it was 89% in the stenting group. In the PTA group, the median resting ABI was significantly improved ( $P < 0.001$ ) from 0.40 (IQR, 0.28–0.52) before the procedure to

Table 3. Lesion and balloon parameters in the PTA group

Parameters	PTA group (N = 26)		P value
	RR subgroup (N = 9)	Non-RR subgroup (N = 17)	
<b>Lesion</b>			
Left-sided, N (%)	5 (55.6)	7 (41.2)	0.683
P1 segment, N (%)	6 (66.7)	7 (41.2)	0.411
P2 segment, N (%)	2 (22.2)	6 (35.3)	0.667
P3 segment, N (%)	0 (0)	0 (0)	NA
Multi-segment disease, N (%)	1 (11.1)	4 (23.5)	0.628
Stenosis grade (%), median (IQR)	100 (90–100)	90 (90–100)	0.293
Occlusion, N (%)	6 (66.7)	7 (41.2)	0.411
Length (mm), median (IQR)	49.6 (17.3–72.6)	24.9 (11.6–60.9)	0.666
Calcification, N (%)	4 (44.4)	9 (52.9)	>0.999
Heavy calcification, N (%)	1 (11.1)	1 (5.9)	>0.999
<b>Balloon</b>			
Diameter (mm), median (IQR)	5 (5–5)	5 (4–5)	0.686
Length (mm), median (IQR)	40 (40–80)	40 (40–80)	0.225

IQR, Interquartile range; NA, not applicable; P1–3, popliteal; PTA, percutaneous transluminal angioplasty; RR, restenotic.

Table 4. Lesion and stent parameters in the stenting group

Parameters	Stenting group (N = 35)		P value
	RR subgroup (N = 12)	Non-RR subgroup (N = 23)	
<b>Lesion</b>			
Left-sided, N (%)	5 (41.7)	10 (43.5)	>0.999
P1 segment, N (%)	1 (8.3)	13 (56.5)	0.010
P2 segment, N (%)	6 (50)	6 (26.1)	0.261
P3 segment, N (%)	0 (0)	0 (0)	NA
Multi-segment disease, N (%)	5 (41.7)	4 (17.4)	0.220
Stenosis grade (%), median (IQR)	100 (100–100)	100 (90–100)	0.357
Occlusion, N (%)	10 (83.3)	15 (65.2)	0.434
Length (mm), median (IQR)	58.3 (30.6–82.7)	49.6 (17.3–72.6)	0.289
Calcification, N (%)	9 (75)	13 (56.5)	0.463
Heavy calcification, N (%)	2 (16.7)	4 (17.4)	>0.999
<b>Stent</b>			
Diameter (mm), median (IQR)	6 (6–7)	6 (6–7)	0.972
Length (mm), median (IQR)	60 (60–120)	60 (40–80)	0.476

IQR, Interquartile range; NA, not applicable; P1–3, popliteal; RR, restenotic.



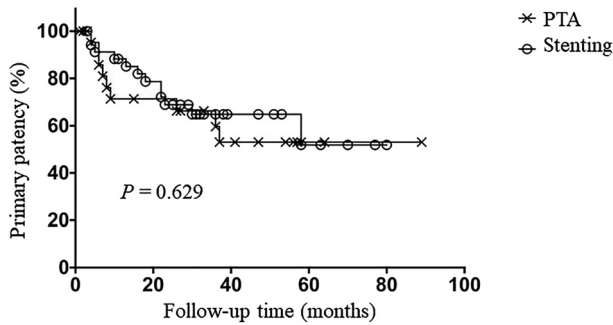
0.90 (IQR, 0.84–1.02) at the 6-week follow-up. For the stenting group, it significantly improved ( $P < 0.001$ ) from 0.37 (IQR, 0.24–0.51) to 0.89 (IQR, 0.80–1.0).

The median follow-up time was 29 months (IQR, 16–47 months) for the PTA group, and 26.5 months (IQR, 6–47 months) for the stenting group. Follow-up times did not significantly differ ( $P = 0.435$ ) between groups. Restenosis developed in nine patients (34.6%) in the PTA group (stenosis,  $N = 7$ ; occlusion,  $N = 2$ ), and in 12 patients (34.3%) in the stenting group (stenosis,  $N = 5$ ; occlusion,  $N = 7$ ). Restenotic lesions required re-intervention in nine cases (100%) in the PTA group (PTA with a plain balloon,  $N = 5$ ; stenting with an Astron Pulsar stent,  $N = 4$ ), and in eight cases (66.7%) in the stenting group (PTA with a plain balloon,  $N = 6$ ; stenting with an Astron Pulsar stent,  $N = 1$ ; femoropopliteal bypass grafting,  $N = 1$ ).

The primary patency rate was 86% at 6 months, and 71% at 12 and 24 months in the PTA group, while the rate was 91% at 6 months, 88% at 12 months, and 69% at 24 months in the stenting group. There were no significant differences ( $P = 0.629$ ) in the primary patency rates between groups (Fig. 1A). The primary patency rate in the pooled patient group was 89% at 6 months, 82% at 12 months, and 70% at 24 months.

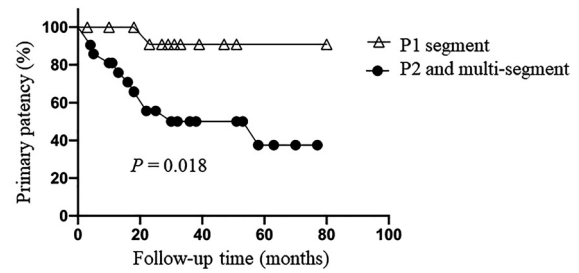
Recurrent restenosis was observed in three patients (3/9; 33.3%) in the PTA group, and in six patients (6/8; 75%) in the stenting group. Two of three patients received invasive therapy in the PTA group (PTA with a plain balloon,  $N = 1$ ; femoropopliteal bypass grafting,  $N = 1$ ), while four of six patients underwent repeat revascularization in the stenting group (PTA with a plain balloon,  $N = 2$ ; stenting with an Astron Pulsar stent,  $N = 1$ ; femorocrural bypass grafting,  $N = 1$ ).

The secondary patency rate was 100% at 6 months, and 90% at 12 and 24 months in the PTA group, while the rate was 100% at 6 months, 94% at 12 months, and 90% at 24



Primary patency rates		6 months	12 months	24 months
PTA	%	85.7	71.4	71.4
	No. at risk	20	16	15
	SE	7.6	9.9	9.9
Stenting	%	91.2	88.2	68.9
	No. at risk	32	29	22
	SE	4.9	5.5	8.2

Fig. 1A. Primary patency rates of PTA and stenting groups. No., Number; PTA, percutaneous transluminal angioplasty; SE, standard error



Primary patency rates		6 months	12 months	24 months
P1 segment	%	100	100	90.9
	No. at risk	13	12	11
	SE	0	0	8.7
P2 and multi-segment	%	85.7	80.9	55.6
	No. at risk	19	17	13
	SE	7.6	8.6	11.1

Fig. 1B. Primary patency rates of different popliteal artery segments. No., Number; P1–2, popliteal; SE, standard error

months in the stenting group. There were no significant differences ( $P = 0.603$ ) in the secondary patency rates between groups. The secondary patency rate in the pooled patient group was 100% at 6 months, 93% at 12 months, and 90% at 24 months.

Restenoses and recurrent restenoses were treated invasively only in patients with Rutherford stage 3–6.

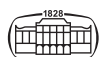### Predictors of restenosis

In the PTA group, neither atherosclerotic risk factors nor lesion and balloon parameters significantly differed between restenotic and non-restenotic subgroups (Tables 1 and 3).

In the stenting group, restenosis developed significantly less frequently ( $P = 0.010$ ) in stents implanted into the P1 segment when compared to P2 plus multi-segment stents. The primary patency rate was 100% at 6 and 12 months, and 91% at 24 months in patients with a P1 segment lesion location, while it was 86% at 6 months, 81% at 12 months, and 56% at 24 months in patients with P2 plus multi-segment lesion locations. The primary patency rates were significantly improved ( $P = 0.018$ ) in patients with a P1 stent when compared to P2 and multi-segment stents (Fig. 1B). The secondary patency rate was 100% at 6, 12, and 24 months in patients with a P1 segment lesion location, while it was 100% at 6 months, 91% at 12 months, and 65% at 24 months in patients with P2 plus multi-segment lesion locations. The secondary patency rates were significantly improved ( $P = 0.025$ ) in patients with a P1 stent when compared to P2 and multi-segment stents. Cox regression analysis identified lesion location as a predictor of in-stent restenosis (HR, 2.5; 95% CI, 1.2–5.5;  $P = 0.019$ ).

### Discussion

Among single-center studies, ours has the largest number of patients. The other studies included 18 to 46 patients [1, 3, 5,



6, 10, 11]. We have shown that the mid-term (24-month) primary patency of endovascular procedures performed on isolated popliteal artery stenosis was good (71% in the PTA group, 69% in the stenting group, 70% in the pooled group), and did not significantly differ between PTA and stenting groups (when selective stenting was not considered as loss of patency). In the stenting group, lesion location was identified as a predictor of restenosis.

As previously outlined, studies investigating patients with isolated popliteal artery steno-occlusive disease were heterogeneous in terms of patent crural runoff arteries. No studies were found where all crural arteries were patent. Our literature review revealed two studies where patients with no patent crural arteries were included [2, 10]. Other studies consisted of patients with at least one patent crural artery [1, 3–7, 13, 20]. To our knowledge, our study was the only investigation based on patients with at least two patent crural arteries.

The following treatment methods were used in these studies: (1) angioplasty with plain balloons, (2) PTA with drug-coated balloons, (3) stenting with bare-metal stents, (4) stent-graft implantation, (5) directional atherectomy, and (6) combinations of the above [1–7, 13]. For the majority of studies (similar to this study), PTA with plain balloons and stenting (either primary or selective) with bare-metal stents was the technique of choice [1, 2, 5–7, 10]. The type of stents implanted varies from study to study [1, 2, 5–11]. In the present patient population, only Astron Pulsar stents have been deployed, which has the advantage over other stents that in most cases the intervention can be executed through a 4F sheath.

In our study, the primary patency rate was 82% at 12 months, and 70% at 24 months in the pooled patient group. Other research studies have observed similar or worse patency rates [1, 2, 5, 7]. For example, in an article, published in 2020, similar rates (72%) [20], while in another article, published in 2018, worse 24-month primary patency rates (59%) [6] can be found when compared to our data. It should be noted that procedures performed with novel endovascular methods (atherectomy alone or combined with PTA with a drug-coated balloon) resulted in improved 12-month primary patency rates (atherectomy alone: 85%, atherectomy combined with PTA with a drug-coated balloon: 95%) [3, 4] when compared to plain balloon angioplasty with or without bare-metal stenting (PTA with bare-metal stenting: 68%, PTA without bare-metal stenting: 59%) [1]. In accordance with our findings, no studies evaluating the patency of PTA and stenting in patients with isolated popliteal artery stenosis showed any significant difference between the two radiological intervention types (when selective stenting was not considered as loss of patency) [1, 2, 5, 7].

Known predictors of restenosis in patients treated endovascularly for isolated popliteal artery stenosis include the following: body mass index (BMI), anemia, reference vessel diameter, long lesion (>60 mm), baseline occlusion, stent placement into the P3 segment, and high-grade residual stenosis [2, 5, 6]. In our study, restenosis occurred less frequently in patients with P1 segment stenting when compared to those with P2 segment and multi-segment

stenting. The popliteal region is critical in that vessels must adapt to movement-induced mechanical forces (e.g. axial compression and bending) [21–23]. Stent deployment disrupts artery elastic capabilities and results in reduced axial compressibility, which may cause extreme kinking at the marginal sections of the popliteal stents, leading to chronic vessel micro-trauma, intimal injuries, hyperplasia, and loss of patency [11, 21, 24]. Furthermore, stented popliteal arteries exhibit additional bending when compared to bare arteries. During knee flexion, bare popliteal arteries have a smooth C shape, while stented popliteal arteries adopt a ‘three-shape’ configuration, generating increased stress both inside and at marginal sections of the stents [23]. Movement-induced mechanical forces also affect each popliteal segment differently. Axial compression and bending are most pronounced behind the knee, suggesting that stents implanted into the P2 segment are exposed to greater mechanical forces than those placed into the P1 segment [21–23, 25]. Thus, patients with P1 segment stenting have reduced chances of restenosis when compared to those with P2 segment or multi-segment stenting.

The main limitation of the study was its retrospective nature. Additionally, stent fracture (an important cause of restenosis) was not examined.

In conclusion, mid-term patency of the popliteal artery interventions was good. Stenting exhibited no superiority when compared to PTA (if selective stenting was not considered as loss of patency). Lesions located in the P2 segment or at multi-segments were more prone to restenosis, therefore follow-up should be more thorough in patients undergoing stenting in these segments.

---

*Authors’ contribution:* All authors contributed to the study conception and design. Material preparation, data collection and analysis were performed by P.B., Á.B., M.V., and D.T.N. The first draft of the manuscript was written by D.T.N. and E.D., and all authors commented on previous versions of the manuscript. All authors read and approved the final version of the manuscript, and agreed to submit it to IMAGING for publication.

*Funding sources:* No financial support was received for this study.

*Conflicts of interest:* The authors declared no potential conflicts of interest with respect to the research, authorship, and publication of this article.

## REFERENCES

- [1] Elens M, Verhelst R, Mastrobuoni S, Bosiers MJ, Possoz J, Lacroix V, et al.: Balloon angioplasty versus bailout stenting for isolated chronic total occlusions in the popliteal artery. *Vasc Endovascular Surg* 2019; 53: 126–31.
- [2] Soga Y, Tomoi Y, Sato K, Iida O, Yokoi H: Clinical outcome after endovascular treatment for isolated common femoral and popliteal artery disease. *Cardiovasc Interv Ther* 2013; 28: 250–7.



- [3] Stavroulakis K, Bisdas T, Torsello G, Stachmann A, Schwindt A: Combined directional atherectomy and drug-eluting balloon angioplasty for isolated popliteal artery lesions in patients with peripheral artery disease. *J Endovasc Ther* 2015; 22: 847–52.
- [4] Stavroulakis K, Schwindt A, Torsello G, Stachmann A, Hericks C, Bosiers MJ, et al.: Directional atherectomy with antirestenotic therapy vs drug-coated balloon angioplasty alone for isolated popliteal artery lesions. *J Endovasc Ther* 2017; 24: 181–8.
- [5] Cui C, Huang X, Liu X, Li W, Lu X, Lu M, et al.: Endovascular treatment of atherosclerotic popliteal artery disease based on dynamic angiography findings. *J Vasc Surg* 2017; 65: 82–90.
- [6] Spiliopoulos S, Kitrou P, Galanakis N, Papadimatos P, Katsanos K, Konstantos C, et al.: Incidence and endovascular treatment of isolated atherosclerotic popliteal artery disease: outcomes from the IPAD multicenter study. *Cardiovasc Intervent Radiol* 2018; 41: 1481–7.
- [7] Rastan A, Krankenberg H, Baumgartner I, Blessing E, Müller-Hülsbeck S, Pilger E, et al.: Stent placement vs. balloon angioplasty for popliteal artery treatment: two-year results of a prospective, multicenter, randomized trial. *J Endovasc Ther* 2015; 22: 22–7.
- [8] Siracuse JJ, Gill HL, Cassidy SP, Messina MD, Catz D, Egorova N, et al.: Endovascular treatment of lesions in the below-knee popliteal artery. *J Vasc Surg* 2014; 60: 356–61.
- [9] Goltz JP, Ritter CO, Kellersmann R, Klein D, Hahn D, Kickuth R: Endovascular treatment of popliteal artery segments P1 and P2 in patients with critical limb ischemia: initial experience using a helical nitinol stent with increased radial force. *J Endovasc Ther* 2012; 19: 450–6.
- [10] León LR Jr, Dieter RS, Gadd CL, Ranellone E, Sr Mills JL, Montero-Baker MF, et al.: Preliminary results of the initial United States experience with the Supera woven nitinol stent in the popliteal artery. *J Vasc Surg* 2013; 57: 1014–22.
- [11] Chang IS, Chee HK, Park SW, Yun IJ, Hwang JJ, Lee SA, et al.: The primary patency and fracture rates of self-expandable nitinol stents placed in the popliteal arteries, especially in the P2 and P3 segments, in Korean patients. *Korean J Radiol* 2011; 12: 203–9.
- [12] Peidro J, Boufi M, Loundou Dieudonné A, Hartung O, Dona B, Vernet F, et al.: Atheromatous occlusive lesions of the popliteal artery treated with stent grafts: predictive factors of midterm patency. *Ann Vasc Surg* 2015; 29: 708–15.
- [13] Rastan A, McKinsey JF, Garcia LA, Rocha-Singh KJ, Jaff MR, Harlin S, et al.: One-year outcomes following directional atherectomy of popliteal artery lesions: subgroup analysis of the prospective, multicenter DEFINITIVE LE trial. *J Endovasc Ther* 2018; 25: 100–8.
- [14] Schillinger M, Sabeti S, Loewe C, Dick P, Amighi J, Mlekusch W, et al.: Balloon angioplasty versus implantation of nitinol stents in the superficial femoral artery. *N Engl J Med* 2006; 354: 1879–88.
- [15] Dick P, Wallner H, Sabeti S, Loewe C, Mlekusch W, Lammer J, et al.: Balloon angioplasty versus stenting with nitinol stents in intermediate length superficial femoral artery lesions. *Catheter Cardiovasc Interv* 2009; 74: 1090–5.
- [16] Stoner MC, Calligaro KD, Chaer RA, Dietzek AM, Farber A, Guzman RJ, et al.: Reporting standards of the Society for Vascular Surgery for endovascular treatment of chronic lower extremity peripheral artery disease. *J Vasc Surg* 2016; 64: e1–21.
- [17] Hüttl AB, Hüttl A, Vértes M, Nguyen DT, Bérczi Á, Hüttl K, et al.: The presence of long and heavily calcified lesions predisposes for fracture in patients undergoing stenting of the first part of the subclavian artery. *J Vasc Surg* 2019; 70: 1146–54.e1.
- [18] Kruse RR, Doomernik DE, Maltha KV, Kooloos JGM, Kozicz TL, Reijnen MMPJ: Collateral artery pathways of the femoral and popliteal artery. *J Surg Res* 2017; 211: 45–52.
- [19] Doris I, Dobranowski J, Franchetto AA, Jaeschke R: The relevance of detecting carotid artery calcification on plain radiograph. *Stroke* 1993; 24: 1330–4.
- [20] San Norberto EM, Flota CM, Fidalgo-Domingos L, Taylor JH, Vaquero C: Real-world results of Supera stent implantation for popliteal artery atherosclerotic lesions: 3-year outcome. *Ann Vasc Surg* 2020; 62: 397–405.
- [21] Smouse BH, Nikanorov A, LaFlash D: Biomechanical forces in the femoropopliteal arterial segment. *Endovascular Today* 2005; 60–6.
- [22] Poulson W, Kamenskiy A, Seas A, Deegan P, Lomneth C, MacTaggart J: Limb flexion-induced axial compression and bending in human femoropopliteal artery segments. *J Vasc Surg* 2018; 67: 607–13.
- [23] MacTaggart JN, Phillips NY, Lomneth CS, Pipinos II, Bowen R, Baxter BT, et al.: Three-dimensional bending, torsion and axial compression of the femoropopliteal artery during limb flexion. *J Biomech* 2014; 47: 2249–56.
- [24] Fortier A, Gullapallia V, Mirshams RA: Review of biomechanical studies of arteries and their effect on stent performance. *IJC Heart & Vessels* 2014; 4: 12–8.
- [25] Klein AJ, Chen SJ, Messenger JC, Hansgen AR, Plomondon ME, Carroll JD, et al.: Quantitative assessment of the conformational change in the femoropopliteal artery with leg movement. *Catheter Cardiovasc Interv* 2009; 74: 787–98.

