

SEMMELWEIS EGYETEM

DOKTORI ISKOLA

Ph.D. értekezések

3125.

FERENCZI ÖRS

Klinikai onkológia és sugárterápia

című program

Programvezető: Dr. Polgár Csaba, egyetemi tanár

Témavezető: Dr. Takácsi-Nagy Zoltán József, egyetemi docens

The application of high-dose-rate brachytherapy in the treatment of postoperative floor of the mouth tumours and dosimetric comparison with modern external beam radiotherapy modalities in localization of floor of the mouth and tongue tumours

PhD thesis

Örs Ferenczi, MD

Pathological and Oncological Division, Doctoral College, Semmelweis University



Supervisor: Zoltán Takácsi-Nagy, MD, PhD

Official reviewers: Szabolcs Bellyei, MD, Ph.D.

Sándor Bogdán, MD, Ph.D.

Head of the Complex Examination Committee: László Tamás, MD, DSc

Members of the Complex Examination Committee: Kornél Dános, MD, PhD

Róbert Farkas, MD, PhD

Budapest

2024

Table of Contents

1. Introduction	7
1.1. General introduction	7
2. Objectives	10
3. Historical overview.....	11
4. Material and methods	15
4.1. Postoperative brachytherapy in patients with squamous cell carcinoma of the floor of the mouth (Group A).....	17
4.2. Dosimetric comparison of postoperative brachytherapy for tongue and floor of mouth cancer with modern external radiation methods (Group B)	21
4.3. Radiation Planning and Dosimetry	22
4.3.1. The Group A.....	22
4.3.2. The Group B.....	22
4.3.2.1. Brachytherapy planning.....	22
4.3.2.2. VMAT planning.....	23
4.3.2.3. Cyberknife planning.....	25
4.3.2.4. Comparison of plans.....	24
4.4. Statistics.....	26
5. Results.....	27
5.1. The Group A.....	27
5.2. The Group B.....	29
6. Discussion.....	34
6.1. The Group A.....	34
6.2. The Group B.....	39
7. Conclusion.....	44
8. References	45
9. Bibliography of the candidate's publications	54

10. Acknowledgements 56

List of Abbreviations

BT: brachytherapy

CI: coverage index

CK: cyberknife

COIN: conformal index

CT: computer tomography

CTV: clinical target volume

DHI: dose homogeneity index

DNA: deoxyribonucleic acid

DNR: dose nonuniformity ratio

DSS: disease specific survival

EBRT: external beam radiotherapy

ESTRO: European Society for Radiotherapy and Oncology

ETT-TUKEB: Egészségügyi Tudományos Tanács - Tudományos és Kutatásetikai Bizottság (Medical Research Council - Committee on Scientific and Research Ethics)

EQD2: equivalent dose in 2-Gy fractions

GEC-ESTRO: Groupe Européen de Curiethérapie – European Society for Radiotherapy and Oncology

Gy: gray

HDR: high-dose-rate

HR: high-risk

IGRT: image-guided radiotherapy

IMRT intensity-modulated radiotherapy

IR: intermediate-risk

LC: local control

LDR: low-dose-rate

LINAC: linear accelerator

LR: low-risk

MDR: medium-dose-rate

MRI: magnetic resonance imaging

MLC: multileaf collimator

OAR: organ at risk

OS: overall survival

PD: prescribed dose

PDR: pulsed-dose-rate

PTV: planning target volume

RC: regional control

RT: radiotherapy

SRT: stereotactic radiotherapy

VMAT: volumetric-modulated arc therapy

1. Introduction

1.1. General introduction

Oral cavity (tongue, floor of mouth, buccal mucosa, gingiva, hard palate) squamous cell carcinomas rank as the sixth most common tumours globally. In 2020, there were 377,713 new cases reported worldwide, resulting in 177,755 deaths from this disease, placing it similarly at the 6th position among all malignancies. Men are affected 2-3 times more frequently than women. The 5-year overall survival rate is 60 % [1]. In Hungary, in 2020, 3,015 new cases were diagnosed, with 1,628 fatalities, ranking it as the 4th most common in incidence and the 6th highest in mortality globally [2]. Unfortunately, floor of mouth carcinomas represent approximately 28% of all oral cavity lesions, with the majority being diagnosed at advanced stages. In Hungary, 97 new cases with this diagnosis were confirmed in 2020 [3].

The occurrence of oral tumours is generally more prevalent in developing countries, with factors such as alcohol and tobacco use, poor oral hygiene, excessive sunlight exposure in lip malignancies, and immunosuppression following kidney and liver transplants playing significant roles in their development. Surgical intervention primarily drives their management, while smaller lesions can be effectively treated with laser resection, cryotherapy, or radiotherapy with comparable outcomes to surgery. In advanced cases, due to the increasing incidence of neck metastases, postoperative irradiation +/- chemotherapy following surgery is recommended, while for unresectable tumours, the combination of radiotherapy (RT) and anticancer drugs proves most effective [4-6].

Currently, the most advanced and routinely utilized radiation technique for oral cancer treatment is intensity-modulated radiation therapy (IMRT), enabling precise tracking of the three-dimensional shape of the target volume by the reference isodose surface using a multileaf collimator (MLC), significantly reducing exposure to critical organs [7,8]. An enhanced version of this approach is volumetric-modulated arc therapy (VMAT) or rotational IMRT, enhancing the precise irradiation of highly intricate target volumes like in head and neck tumour regions, further reducing exposure to critical organs [9, 10].

For smaller target volumes in external irradiation, a recent innovation is stereotactic radiotherapy (SRT), characterized by techniques such as the Cyberknife (CK) approach. This method aims to deliver the highest dose feasible to the tumour using multiple non-coplanar beams, minimizing exposure to surrounding healthy tissues [11, 12].

However, maximal external radiation dose delivery to the target volume (the tumour or its site post-surgery) generally leads to unnecessary radiation exposure of critical organs in the vicinity (salivary glands, jawbones, masticatory muscles, etc.), resulting in increased occurrence of side effects in normal tissues (xerostomia, osteoradionecrosis, fibrosis, trismus, etc.) [13]. Even though IMRT significantly reduces radiation-induced toxicity, brachytherapy (BT) remains an extremely advantageous method in managing malignant oral lesions due to its potential for dose escalation in this localization, minimizing radiation-related normal tissue damage during the short treatment period by placing radioactive sources directly in or near the tumour [14].

Until the end of the 20th century, low-dose-rate (LDR) BT served as the gold standard, backed by extensive literature based on years of experience [15]. Presently, LDR BT is being replaced by high-dose-rate (HDR) and pulse-dose-rate (PDR) BT in numerous institutions globally, allowing for optimal dose distribution by varying the dwell time of the remote-controlled radiation source as opposed to LDR. HDR BT proved to be comparable to LDR BT in terms of local tumour control and complications [16–18]. In the management of oral cancer, BT predominantly plays a vital role in the initial stages of lip, buccal mucosa, hard palate, floor of mouth, and tongue tumours. In advanced cases, it can also be used as an adjunct to external radiotherapy.

For this study, I utilized significant, statistically analyzed articles and studies from the past 30-40 years related to a larger cohort of patients in order to write the thesis. Employing the MEDLINE® database (via PubMed) and searching based on keywords such as "BT, HDR, VMAT, CK, and oral (floor of mouth) tumours," I conducted the literature search.

By focusing on the exclusive role of HDR BT in a retrospective study of postoperative radiotherapy for floor of mouth carcinomas, I aimed to investigate its effectiveness compared to surgery alone, exclusive radiotherapy, and LDR techniques.

Additionally, the dosimetric comparison of this therapeutic approach with modern external radiotherapy techniques in localizations of the tongue and floor of the mouth was of interest.

2. Objectives

To conduct a detailed discussion of the following topic groups related to the study of interstitial HDR brachytherapy applied postoperatively for tongue base tumours, and to draw conclusions:

1. Examination of the effectiveness of postoperative HDR brachytherapy in pT1-2N0 stage tongue base tumours.
2. Comparison of results - based on the literature - with postoperative LDR and PDR techniques, sole surgical treatment, and sole percutan postoperative radiotherapy.
3. Analysis of the local and locoregional tumour control, as well as prognostic factors influencing tumour-specific and overall survival, in tongue base cancer patients treated with postoperative brachytherapy.
4. Comparative dosimetric analysis of modern external beam radiotherapy modalities: VMAT and CK, as well as HDR brachytherapy technique, in terms of organs at risk for tongue and tongue base tumours operated upon.

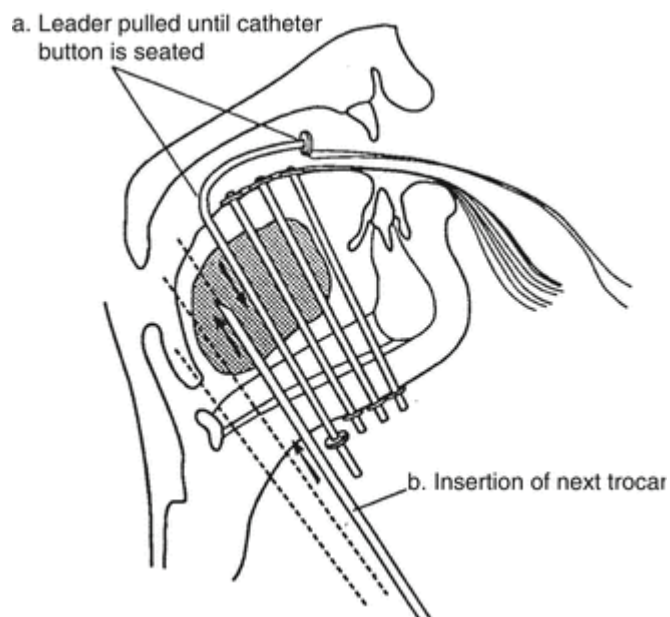
3. Historical overview

The history of interstitial irradiation of oral cavity, tongue, and floor of mouth tumours dates back to the early 20th century [19]. For decades in brachytherapy, radium needles represented the sole possibility [20]. Despite numerous advantages of the Ra-226 isotope (such as broad energy spectrum, long half-life, and consequent cost-effectiveness), it primarily posed a significant disadvantage from a radiation protection perspective (radon emanation). With the advent of modern, high-energy EBRT techniques, the role of classical brachytherapy diminished, yet additional factors may have also explained its limited application:

- Due to the lack of imaging procedures, it was challenging to assess the extent of tumour spread and the previous tumour location, which is especially important from a brachytherapy point of view, using traditional diagnostic methods (indirect mirroring, palpation).
- The implantation of isotopes and applicators under local or general anesthesia required good manual dexterity.
- Post-implantation perifocal edema could alter the geometrical position of implants, leading to underdosed areas and/or overdosed "hot spots."
- Edema could hinder the removal of radiation sources.
- The radiation exposure of the treatment team was significant in the era preceding remote-controlled brachytherapy [21, 22].

In the 1950s, Henschke [23, 24], and from the 1960s onwards, Pierquin and Chassagne [25-27], contributed to the widespread adoption of iridium Ir-192 isotope, which now dominates the field, offering numerous advantages (such as improved radiation protection, high specific activity, etc.). By the early 1970s, Ir-192 had effectively displaced radium. Initially, Ir-192 was used in the form of needle-shaped, then wire-shaped, and later as seeds threaded onto nylon strings (seed) [28, 29]. Henschke introduced the after-loading technique, which provided greater radiation protection, better dose distribution in the target volume, and improved plannability. The use of stainless steel rigid needles, as well as loop and non-loop techniques with straight tubes/strings, were also attributed to him [21]. Plastic applicators were inserted into the floor of

mouth/tongue area through a submental puncture channel created with a trocar. After pulling the tube/string (hereinafter referred to as catheter, tube, applicator, implant) through, the puncture needles were removed (Figure 1,2). Criticism was raised against the loop method, as the source often got stuck or broke during prolonged treatment. Several authors also experimented with isotopes possessing favorable dosimetric and radiation protection properties similar to Ir-192 (such as I-125 and Au-198 seeds) [30, 31, 32]. However, it can be concluded that currently, Ir-192 is considered the "gold standard" in brachytherapy for oral cavity and floor of mouth tumours [33-37, 55-58, 60, 65].



- a. Plastic applicators (secured with plastic button)
- b. Trocar insertion

Figure 1. Implantation of plastic tubes and insertion of trocars in tongue and floor of mouth tumours

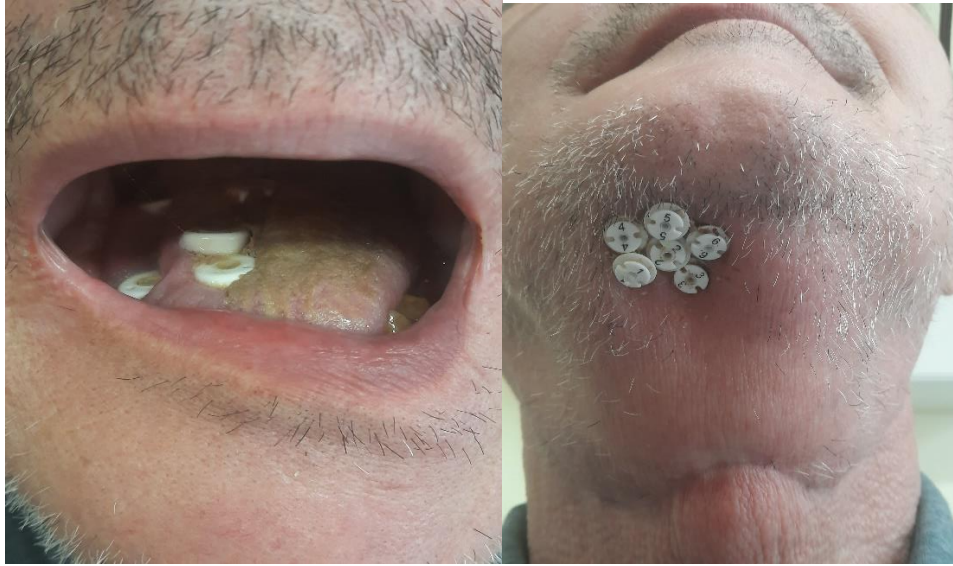

Figure 2. Plastic catheters with fixation buttons at the skin and tongue surface.

The dosimetric performance of brachytherapy can be classified into three categories: LDR (≤ 2 Gy/h), MDR (> 2 Gy/h, but ≤ 12 Gy/h), and HDR (> 12 Gy/h) treatments. Until the 1960s, the utilization of LDR radioactive isotopes characterized brachytherapy. The widespread application of LDR was driven by its advantageous radiobiological effects [71, 72]. The ability of low α/β -value ($\alpha/\beta = 0.5-6$ Gy), so-called late-responding normal tissues to repair sublethal radiation damage, surpasses that of high α/β -value ($\alpha/\beta = 7-20$ Gy) for early-responding tumours. Over a relatively prolonged treatment duration, radiologically resistant tumour cells are more likely to redistribute into the radiation-sensitive G2/M cell cycle phase, allowing for tumour cell reoxygenation, thereby enhancing radiosensitivity [72].

HDR brachytherapy presents numerous advantages over LDR, regardless of its less favorable radiobiological effects. With stepping, remote-controlled sources, maximum radiation protection for the treatment team is ensured. Through computerized control, dose distribution can be optimized, meaning it can be shaped within certain boundaries, as the dwell time in individual treatment positions can be freely chosen. The method is cost-effective because the short treatment duration allows for the treatment of multiple patients per day in the same shielded room. Concerns about implant

displacement are minimized. Extended bed rest is not required, thus avoiding potential thromboembolic complications [72].

Retaining the advantages of HDR brachytherapy, the negative radiobiological effects can be reduced through dose fractionation. With twice-daily treatments and a total dose not exceeding 6 Gy, drawbacks are nearly negligible. To determine the HDR fractionation schedule, the linear-quadratic model can be used based on the knowledge of the tumour and normal tissue α/β values [18].

PDR-BT is a method that combines the technical-physical advantages of HDR-BT (isodose optimization, design flexibility, radiation safety) with LDR-BT radiobiological benefits (repair advantages) [73].

4. Material and methods

Since 1992, high-dose-rate (HDR) brachytherapy has been employed at the National Institute of Oncology's radiotherapy department in the radiation treatment of malignancies of the oral cavity, mouth, and nasal cavity. This study retrospectively analyzes the therapeutic and survival data of 44 patients with floor of mouth cancer who were treated with postoperative brachytherapy between January 1998 and December 2017 [68], as well as compares the dosimetry of tongue (n=14) and floor of mouth (n=6) tumours treated with postoperative brachytherapy using EBRT techniques (VMAT, CK) between March 2013 and August 2022. The study was conducted in full compliance with the Helsinki Declaration and ethical norms related to human experimentation in Hungary. Both the retrospective and dosimetric analyses involved selecting participants based on the following criteria:

- tumours sized pT1-2(3) pN0-1 according to the UICC TNM system /7th edition/ (Table 1.), absence of distant metastasis and other malignant processes,
- histologically confirmed and surgically treated floor of mouth/tongue tumours,
- exclusive postoperative HDR interstitial brachytherapy as the type of radiotherapy,
- no prior therapeutic irradiation in the region,
- patients with regular follow-up, including necessary clinical and laboratory tests (complete blood count, sedimentation rate, liver function, kidney function), chest X-ray, abdominal ultrasound, diagnostic computer tomography (CT) and/or magnetic resonance imaging (MRI) of the oral cavity-neck region, possibly Positron Emission Tomography, and if needed, scintigraphy for clarifying bone pain causes.

In line with the study objectives, two research topics were distinguished:

Group A: Postoperative HDR brachytherapy of floor of mouth cancer patients (n=44)

Group B: Dosimetric comparison of postoperative brachytherapy of tongue and floor of mouth cancers within a model study framework using modern external irradiation methods (n=20)

The type of postoperative radiotherapy (brachytherapy or EBRT) was determined by the oncoteam and the treating physician team, but ultimately, after detailed information, the patient could decide on the type of postoperative radiation therapy.

Table 1. *The TNM system of oral cavity tumours (Union for International Cancer Control /UICC/ TNM atlas 7th edition, 2012)*

Parameters	Description
<i>Primary tumour (T)</i>	
Tx	Primary tumour cannot be assessed
T0	No evidence of primary tumour
Tis	Carcinoma in situ
T1	Tumour size less than 2 cm
T2	Tumour size between 2-4 cm
T3	Tumour size greater than 4 cm
T4	Tumour invades surrounding structures (bone, cartilage, deep or superficial muscles of the tongue, hard palate, etc.)
<i>Regional lymphnode metastasis (N)</i>	
Nx	Regional lymphnode cannot be assessed
N0	No lymphnode metastasis
N1	Single ipsilateral lymphnode less than 3 cm in size
N2a	Single ipsilateral lymphnode greater than 3 cm but less than 6 cm in size
N2b	Multiple ipsilateral lymphnodes smaller than 6 cm
N2c	Bilateral or contralateral neck lymphnodes smaller than 6 cm
N3	Lymphnode greater than 6 cm
<i>Distant metastasis (M)</i>	
Mx	Distant metastasis cannot be evaluated
M0	No distant metastasis
M1	Distant metastasis
<i>Stage</i>	
Stage I	T1, N0, M0
Stage II	T2, N0, M0
Stage III	T3, N0 or T1-3, N1, M0
Stage IV	T4, N0, N1, M0 Any T, N2, N3, M0 Any T, Any N, M1

4.1 Postoperative brachytherapy in patients with squamous cell carcinoma of the floor of the mouth (Group A)

Between January 1998 and December 2017, 44 patients with pT1-3pN0-1M0 squamous cell carcinoma located in the floor of the mouth were treated postoperatively exclusively with interstitial high-dose rate brachytherapy. The clinicopathological data are presented in Table 2.

Table 2. *Clinicopathological characteristics of the 44 patients with floor of mouth cancer who underwent postoperative brachytherapy (Ferenczi Ö.,2023)*

Parameters	Number of cases (%)
Histology	
squamous cell	44 (100)
Differentiation	
Grade I	13 (30)
Grade II	29 (66)
Grade III	2 (4)
Gender	
Female	15 (34)
Male	29 (66)
Tumour size	
pT1	24 (55)
pT2	15 (34)
pT3	5 (11)
Lymph node status	
pN0	40 (90)
pN1	4 (10)
Neck dissection	
Yes	32 (73)
No	12 (27)
Lymphovascular invasion	14 (32)
Perineural invasion	12 (27)
Tumour thickness	

≥5 mm	28 (64)
<5 mm	16 (36)
Surgical margin	
≥5 mm	9 (20)
<5; >2 mm	23 (52)
R1	6 (14)

During surgery, exclusive primary tumour excision was performed in 12 cases (27%). In these patients, elective neck dissection was not performed due to the low risk of cervical metastasis (tumour size < 3 cm; invasion depth < 5 mm; well-differentiated grade 1-2; absence of lymphatic and perineural invasion, clinically N0 status /n=11/), as well as due to frail physical condition, older age, and clinically negative neck status (n=1). Ipsilateral (n=30; 68%) or bilateral (n=2; 5%) neck dissection was performed in 32 cases. Levels I-IV dissection was carried out in T3 and/or N1 status, while levels I-III dissection was conducted in T1-2 N0 status. Among the patients with pT3 status (n=5), no regional metastasis was detected.

The average time between surgery and the first fraction of interstitial HDR brachytherapy was 42 days (range 35-71). Flexible plastic catheters were used in 30 cases (68%), while rigid metal needles were used in 14 cases (32%). The implantation was performed in the operating room under general anesthesia, through a submental approach. Trocars were used for inserting the plastic catheters, pulled through the lumen of these devices, and then the trocars were removed. The ends of the catheters were secured submentally with plastic buttons and on the surface of the tongue.

The determination of the target volume (tumour bed + 5 mm, planning target volume: PTV) was aided by the primary CT/MRI imaging, as well as palpation of the tumour bed. The Paris system rules were applied to the geometry of implant placement. The number of rigid metal needles/catheters and the distance between them (usually 1-2 cm) were determined considering the extent of the target volume.

The average dose of brachytherapy was 26 Gy (range 10-48 Gy), the average EQD2(10) was 36 Gy (16.7-56.3 Gy), and the average EQD2(3) was 46 Gy (range 26-72 Gy) (Table 3). Fourteen patients received a single fraction of 10-14 Gy with rigid needles (average number 2, range 2-4). After 2000, with one exception (1x14 Gy), we transitioned

to fractionated delivery of HDR brachytherapy using non-looped plastic catheters (average number 4, range 2-9). With this technique, an average dose of 36 Gy (range 14-48 Gy) was delivered in 1-15 fractions (average 10), 3-6 Gy per fraction (average 4 Gy), twice daily, with at least 6 hours apart (Table 4). Mouthguards were not used during treatment

Table 3. *Techniques and fractionation schemes of HDR brachytherapy (Ferenczi Ö., 2021)*

Technique		Number of cases (%)		
Plastic catheter		30 (68)		
Rigid needle		14 (32)		
Fractionation schemes				
Number of Fx	Dose/Fx	Cases (%)	EQD2(3) (Gy)	EQD2(10) (Gy)
1	10 Gy	6 (14)	26	16,7
1	12 Gy	5 (11)	36	22
1	14 Gy	4 (9)	47,6	28
5	4 Gy	1 (2)	28	23,3
5	5 Gy	2 (5)	40	31,3
5	6 Gy	2 (5)	54	40
6	4 Gy	1 (2)	33,6	28
6	5 Gy	1 (2)	48	37,5
7	4 Gy	3 (7)	39,2	32,7
7	5.2 Gy	2 (5)	59,7	46,1
7	5.4 Gy	2 (5)	63,5	48,5
8	4 Gy	1 (2)	44,8	37,3
9	4 Gy	1 (2)	50,4	42
9	5 Gy	1 (2)	72	56,3
12	4 Gy	1 (2)	67,2	56
15	3 Gy	11 (25)	54	48,8

Fx: fractions, EQD2(3): equivalent dose in 2-Gy fractions with α/β ratio=3 for late-responding tissues (normal tissue), EQD2(10): equivalent dose in 2-Gy fractions with α/β ratio=10 for early-responding tissues and tumours

Table 4. Therapeutical parameters of the 44 patients treated with postoperative BT

Pathological stage	Dissection (yes/no)	Number of catheters	Neck dissection (yes/no)	Dose
T1N0	yes	2	no	1x10 Gy
T1N0	no	2	no	1x10 Gy
T1N0	yes	2	no	1x12 Gy
T1N0	yes	2	no	1x12 Gy
T1N0	yes	2	no	1x12 Gy
T1N0	no	2	yes	5x4 Gy
T1N0	no	2	yes	6x4 Gy
T1N0	yes	2	yes	7x4 Gy
T1N0	yes	2	yes	7x4 Gy
T1N0	no	2	yes	7x5.2 Gy
T1N0	no	2	yes	7x5.4 Gy
T1N0	no	3	yes	7x5.4 Gy
T1N0	no	3	yes	9x4 Gy
T1N0	yes	3	yes	9x5 Gy
T1N0	yes	4	yes	15x3 Gy
T1N0	no	4	yes	15x3 Gy
T1N0	no	2	yes	15x3 Gy
T1N0	yes	5	yes	15x3 Gy
T1N0	no	6	yes	15x3 Gy
T1N0	yes	6	yes	15x3 Gy
T1N0	no	9	yes	15x3 Gy
T1N0	yes	6	yes	15x3 Gy
T1N0	yes	6	yes	15x3 Gy
T1N0	yes	6	yes	15x3 Gy
T2N0	yes	2	no	1x10 Gy
T2N0	yes	2	no	1x10 Gy
T2N0	yes	3	no	1x10 Gy
T2N0	yes	4	no	1x10 Gy
T2N0	yes	2	no	1x12 Gy
T2N0	yes	3	no	1x12 Gy
T2N0	no	2	no	1x14 Gy
T2N0	yes	3	no	1x14 Gy
T2N0	yes	4	yes	1x14 Gy
T2N0	yes	6	yes	5x5 Gy
T2N0	yes	5	yes	6x5 Gy
T2N0	yes	5	yes	7x4 Gy
T2N0	yes	5	yes	7x5.2 Gy
T2N1	yes	5	yes	5x5 Gy
T2N1	yes	5	yes	12x4 Gy
T3N0	yes	6	yes	5x6 Gy

T3N0	yes	6	yes	8x4 Gy
T3N0	yes	6	yes	15x3 Gy
T3N1	yes	4	yes	5x6 Gy
T3N1	yes	3	no	1x14 Gy

Our institutional protocol mandated the initial surveillance evaluation at 8-10 weeks following brachytherapy application in the form of CT or MRI, supplemented by a physical examination. Subsequently, we conducted physical examinations every 3 months and repeated the CT or MRI every 6 months during the first two years. Chest X-rays and laboratory tests were performed annually. The survival time was calculated from the last fraction of HDR brachytherapy. Acute and late side effects were classified according to the recommendations of the Radiation Therapy Oncology Group (RTOG) / European Organisation for Research and Treatment of Cancer (EORTC) [44].

4.2 Dosimetric comparison of postoperative brachytherapy for tongue and floor of mouth cancer with modern external radiation methods (group B)

At our institution, a model study included 20 patients treated between January 2016 and December 2021 with T1-3N0 stage disease who underwent postoperative brachytherapy and received the same total dose and fractionation, either for tongue or floor of mouth cancer. All of them underwent tumour resection and either unilateral (85%, 17/20) or bilateral (15%, 3/20) selective neck dissection following negative neck staging. No metastatic lymph nodes were confirmed on pathology. To justify local postoperative brachytherapy, one of the following criteria had to be met: pT3 tumour, surgical margin ≤ 2 mm, lymphatic vessel infiltration, or perineural invasion. Based on histopathological analysis, 20% of the lesions were pT3 in size (TNM 8) [45], 85% had surgical margins of ≤ 2 mm, and 40% exhibited perineural spread. Treatments were delivered using HDR afterloader with Iridium-192 isotope (Flexitron, Elekta Brachytherapy, Veenendaal, The Netherlands) after placement of flexible catheters (median 6, range 6-8) into the tumour bed. Insertion was performed submentally using trocars in the operating room under general anesthesia. The average time between interstitial brachytherapy implantation and

surgery was 54 days (range: 42-81 days). The total dose of brachytherapy was 45 Gy, delivered in 3 Gy fractions twice daily with a 6-hour interval (15x3 Gy).

4.3. Radiation Planning and Dosimetry

4.3.1. The Group A

Out of the 44 patients with floor of mouth cancer, treatment planning based on X-ray images obtained at opposing angles was performed for 18 patients (41%) (Figure 3). On X-ray images the active lengths of the needles/catheters were marked, and then the points of the needles/catheters were digitized into the Plato 3-dimensional (3D) planning system (Nucletron, Veenendaal, Netherlands). Instead of utilizing the traditional Paris system for dose prescription, we placed the reference dose points 0.5-1.2 cm outward from the axis of the needles/catheters, and optimized the dose distribution to these points, followed by dose prescription to mean doses. Subsequently, the dose at these points was prescribed based on the average dose. Since 2000, CT-based planning has been conducted for 26 patients (59%). The Planning Target Volume (PTV) was delineated on the CT slices, and the positions of the radiation sources were activated within the target volume. The reference dose points were placed on the surface of the PTV. Following dose optimization, the dose was prescribed to the 100% isodose surface (Figure 4). Prior to 1996, radiation was delivered using the Gammamed-II unit (Sauerwein GmbH, Haan, Germany) and since then, the Nucletron-Microselectron HDR (Ir-192) afterloader unit has been utilized, employing iridium-192 isotopes with an initial activity of 370 GBq (10 Ci). With the latter, Oncentra Brachy planning system (Elekta, Veenendaal, The Netherlands) was used for treatment planning.

4.3.2. The Group B

4.3.2.1. Brachytherapy planning

Following catheter placement, a 3 mm slice thickness CT imaging was performed for all patients, covering the entire head including the tumour bed, parotid glands, and submandibular salivary gland. Brachytherapy planning was carried out for each case using Oncentra Brachy v4.5.3 (Elekta Brachytherapy, Veenendaal, Netherlands). Imaging of the primary tumour (CT, MRI) and palpation of the surgical area aided in

determining the target volume (clinical target volume /CTV/: tumour bed + 0.5 cm safety margin). There was no safety margin around the CTV, making the Planning Target Volume (PTV) same as the CTV. The ipsilateral (il.) and contralateral (cl.) parotid glands, the cl. submandibular salivary gland, the skin, and the mandible were contoured as organs at risk. The skin was defined as a 0.5 cm layer beneath the external body surface. The source dwell positions and the reference dose points were individually determined for each implant. Geometrical and graphical dose optimization was performed. The prescribing isodose line was selected to achieve 90% dose coverage of the PTV (V100=90%). The brachytherapy planning was conducted in accordance with the recommendations of the GEC-ESTRO (Groupe Européen de Curiethérapie and the European Society for Radiotherapy and Oncology) Head and Neck Working Group [46].

4.3.2.2. VMAT planning

Planning for the external beam RT, the patients' CT scans were exported to an external planning system (Eclipse v11, Varian, Palo Alto, CA, USA) in compliance with the Digital Imaging and Communications in Medicine (DICOM) RT protocol, along with the structure set defined in the brachytherapy plans. Subsequently, volumetric-modulated arc therapy (VMAT) plans were created using two partial arcs. This method ensured precise match of the target volume and organs at risk between the two planning systems, thereby eliminating inaccuracies arising from contouring.

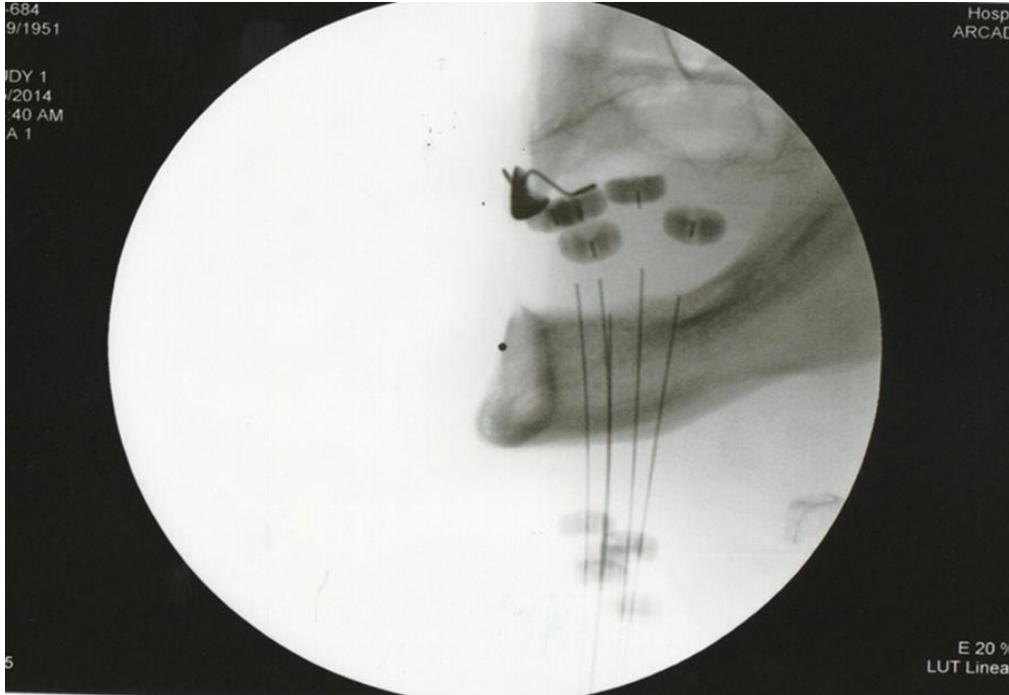


Figure 3. Lateral X-ray of 5 implanted flexible plastic catheters with markers and fixation plastic buttons (Ferenczi Ö, 2020 [53])

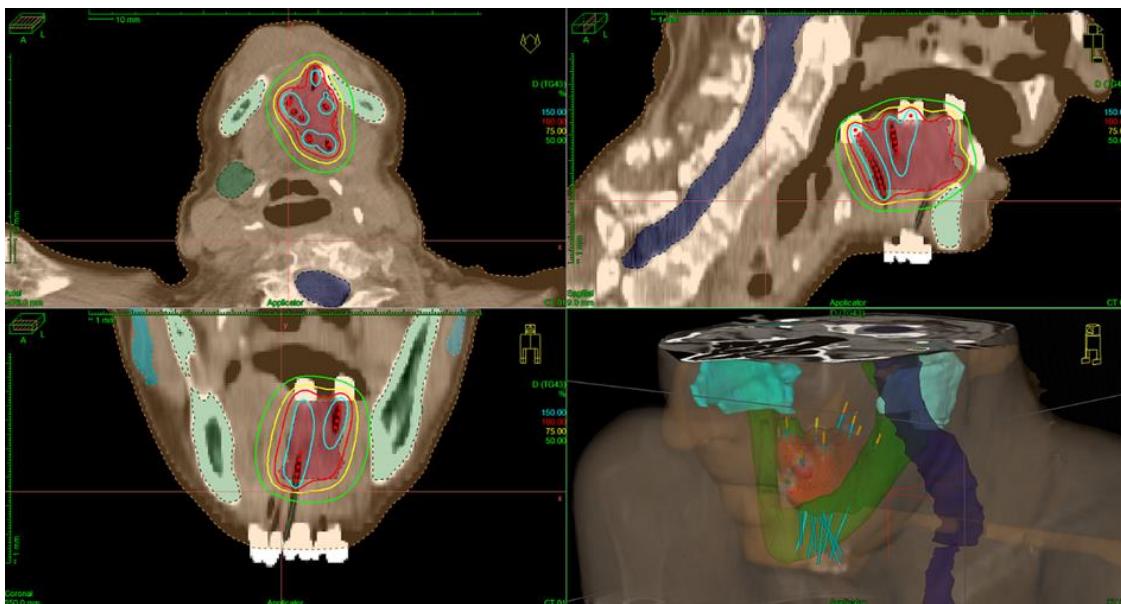


Figure 4. 3D-CT reconstruction of the implanted catheters (blue lines) and the calculated dose distribution in relation to PTV (red volume) in axial, coronal and sagittal views (Ferenczi Ö, 2020 [53])

This implies that the differences obtained during comparison can solely be attributed to the differences between the two radiation techniques, unaffected by other factors. In the case of VMAT plans, the CTV was expanded by 3 mm in all directions to create the PTV. In VMAT plans 6 MV photon energy was used. The VMAT plans were optimized using the Varian RapidArc progressive resolution optimization (PRO) algorithm and the doses were calculated using the analytical anisotropic algorithm (AAA). Following dose normalization, the coverage of PTV with the prescribed dose (V100) was 90%.

4.3.2.3. Cyberknife planning

For the creation of stereotaxic plans, the CT images and Radiotherapy Structure Set from the Eclipse system were transferred to the planning system of Precision version 3.1.0.0 (Accuray, Sunnyvale, CA, USA). The PTV used in the stereotaxic plans was generated by symmetrically extending the CTV of brachytherapy by 2 mm. The Cyberknife plans were developed using a multileaf collimator system, 6MV FFF photon energy, the VOLO optimizer for dose optimization, and the Finite Size Pencil Beam (FSPB) algorithm for dose calculation. The dose was selected to achieve V100=90% for the PTV.

4.3.2.4. Comparison of plans

The same dose and fractionation (15 x 3 Gy) were applied in all three techniques. Parameters calculated from the dose-volume histogram were used for plan comparison. The volume irradiated with the prescribed dose for the PTV (V100) was used to describe the target volume. Objective comparison was based on the same target volume coverage (V100=90%) for all three techniques. Thus, differences found among the plans were due solely to the characteristics of the irradiation techniques. A small volume of high-dose radiation was applied to characterize unintentional irradiation of OARs. The D_xcm³ represents the dose to the most exposed x cm³ portion of an organ (mandible, parotid gland). D₂cm³ and D_{0.1}cm³ values were calculated and compared for all OARs. The conformity of dose distributions was quantified using the conformal index (COIN), which takes into account both the target coverage and the unnecessary irradiation of normal tissues [36]. Its maximum value is 1, and the higher the value, the more conformal the

dose distribution. Dose homogeneity was characterized with the dose nonuniformity ratio (DNR) in BT plans, and homogeneity index (HI) in the VMAT and CK plans. DNR is the ratio of volume irradiated by 1.5 times the PD to volume irradiated by the PD. The HI was calculated according to recommendation of ICRU (International Commission on Radiation Units and Measurements) Report 83.21 By definition, $HI = (D2\% - D98\%) / D50\%$.

4.4. Statistics

In Group "A," statistical analysis was performed using the Solo software package (Department of Biometrics, University of California, Los Angeles, USA). Survival probability was calculated using the Kaplan-Meier method [47]. Survival differences were compared using the log-rank test. Cox regression analysis was conducted to explore possible risk factors for local and regional tumour control (LC, RC), overall survival (OS), and disease-specific survival (DSS) [46, 48].

In Group "B," Friedman ANOVA and Fisher-LSD post-hoc tests were utilized (Statistica 12.5, StatSoft, Tulsa, OK, USA) for comparing dose-volume parameters of VMAT, CK, and HDR BT techniques. Significance was considered at the $p \leq 0.05$ level.

5. RESULTS

5.1. The Group A

The median follow-up time for surviving patients was 122 months (range: 14-236 months). No patient was lost during this period. Local recurrence occurred in 4 patients (9%), regional metastasis in 12 patients (27%), and distant (lung) metastasis in 1 patient (2%). The salvage treatments were as follows: surgery in six cases (14%), external beam radiation therapy in eight cases (18%), surgery and external beam radiation therapy (EBRT) in two cases (5%), and palliative chemotherapy in four cases (9%). Among patients who experienced regional recurrence (n=12), as part of salvage care, surgery was performed in four cases, EBRT in four cases, surgery and external RT in two cases, and chemotherapy in two cases as well. Unfortunately, all 16 patients who received salvage treatment later died due to locoregional recurrence. Among other causes of death, second primary tumours (larynx, thyroid, esophagus, and rectum) were found in 4 patients (9%), while concomitant illness was listed in 10 patients (23%). The 5-year and 10-year probabilities of LC, RC, OS, and DSS were 89% and 89% (T1 95%, T2 82%, T3 80%), 73% and 67% (T1 68%, T2 63%, T3 80%), 52% and 32% (T1 40%, T2 27%, T3 0%), and 66% and 54% (T1 59%, T2 53%, T3 0%) (Figure 5).

The univariate analysis of prognostic factors confirmed the significant effect of lymphovascular invasion on 10-year RC (80% vs. 40%, $p=0.0062$) (Figure 6), DSS (66% vs. 31%, $p=0.0056$), and OS (41% vs. 14%, $p=0.0325$). In cases of neck recurrence (n = 12), the primary tumour histopathology revealed lymphatic invasion in 8 patients. Among the 12 patients treated without elective neck dissection, regional recurrence occurred in three cases (25%). Only one patient showed lymphovascular invasion in histopathology, but due to initial negative neck staging, advanced age (82 years), and poor general condition, elective neck surgery or neck EBRT was not carried out on them.

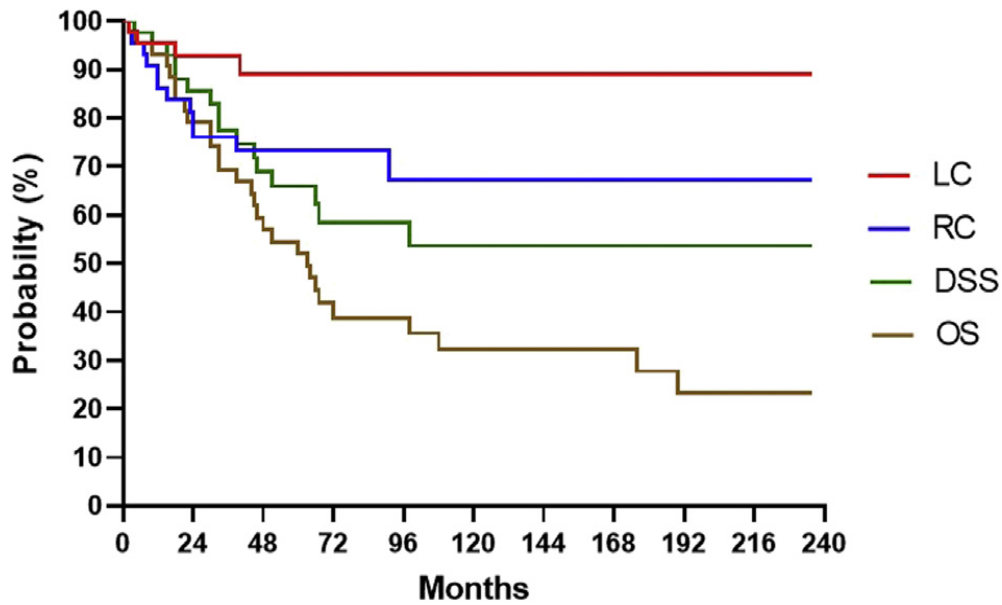


Figure 5. Local tumour control (LC), regional tumour control (RC), disease specific survival (DSS), and overall survival (OS). (Ferenczi Ö, 2020 [53])

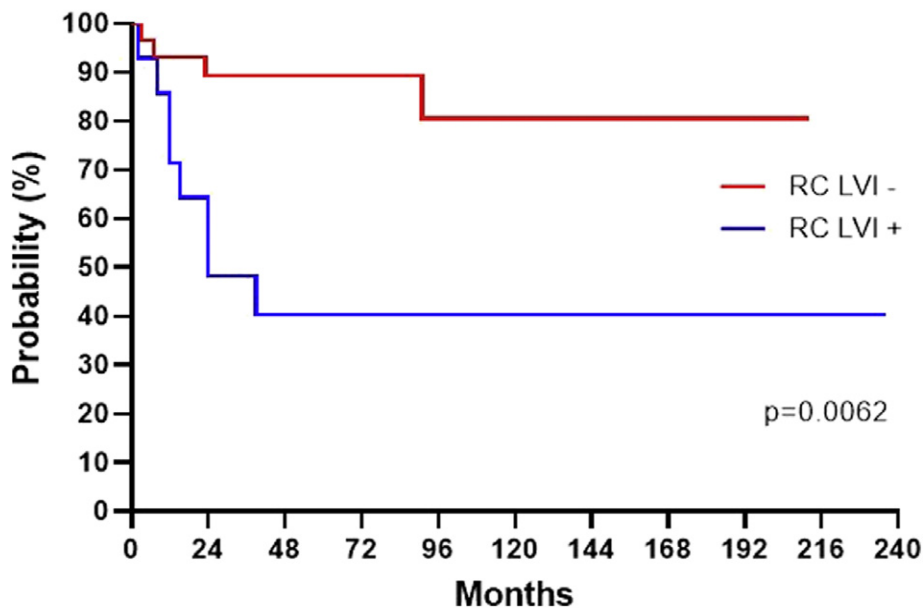


Figure 6. Regional tumour control (RC) in accordance with lymphovascular invasion (LVI -/+). (Ferenczi Ö, 2020 [53])

The recurrence in the neck had a significantly negative impact on the 10-year DSS (81% vs. 0%, $p < 0.0001$) and OS (46% vs. 0%, $p < 0.0001$). In the multivariable analysis, the neck recurrence remained an independent prognostic factor for both DSS ($p < 0.0001$)

and OS ($p=0.0001$). Factors such as age (threshold 50 years), gender, perineural invasion, grade, total EQD2 biologically effective dose (with cutoffs at 35 Gy and 45 Gy), number of fractions (single vs. multiple), surgical margin (positive, ≤ 2 mm, > 2 mm), tumour thickness ($<$, ≥ 5 mm), time between surgery and HDR brachytherapy did not influence the survival parameters.

Brachytherapy induced local mucositis of grade 1, 2, and 3 in 11 (25%), 28 (64%), and 5 (11%) cases, respectively. Bacterial infection occurred in 8 patients (18%), while fungal infection was seen in 9 patients (20%), all of whom responded to antibiotic and/or antifungal treatment. Severe (grade 4) side effects, such as soft tissue necrosis, occurred in four cases (9%) at 4 to 8 months (average 6 months) post-brachytherapy, but conservative management led to patient recovery. In these cases, the EQD2(3) was 59.7 Gy (7×5.2 Gy/n = 1, 7×5.4 Gy/n = 2, 9×5 Gy/n = 1) (Table 5). The average time to healing of the necrosis was 4 months (range 3-5 months). Only one patient required percutaneous endoscopic gastrostomy for nutrition. Osteoradionecrosis (ORN) did not occur in any case. The average D2cm3(%) for the mandible was 57.7% (range 39.9-73.1%), and the D2cm3(Gy) was 2 Gy (range 1.6-2.2 Gy). Long-term toxicities such as xerostomia, swallowing difficulties, and neck fibrosis did not occur (except in the surgically treated neck).

5.2 The Group B

The dose coverage of the target volume was 90.0% in all modalities due to the identical dose prescription ($V_{100}=90\%$). Figure 7. illustrates the representative dose distributions of the three examined techniques. It is evident that the target volume was adequately irradiated in all cases, but significant differences can be observed in the volumes irradiated with doses corresponding to the middle and lower isodose values ($<70\%$). In the brachytherapy plan, these volumes were the smallest, particularly in regions close to the target volume. Table 5. presents the dosimetric data related to the planning target volume (PTV). Due to the safety margins employed in the volumetric modulated arc therapy (VMAT) and CyberKnife (CK) plans, the largest volume was observed in VMAT, whereas the smallest was in the brachytherapy plan.

The plans of EBRT were more conformal compared to brachytherapy. The most conformal plans were found in the CK cases, likely due to the presence of many non-

coplanar beams. However, the VMAT plans were more homogeneous than the CK plans (homogeneity index: 0.09 vs. 0.20). It is evident that the homogeneity is much poorer with brachytherapy, and comparison with EBRT is not relevant. Table 6. displays the quantitative dosimetric parameters of the organs at risk (OARs). The dose to the jaw was the lowest with brachytherapy application (average D2cm3: 47.4%, $p < 0.001$) compared to the other modalities: VMAT (92.2%) and CK (68.4%).

Regarding the salivary glands, the CK technique resulted in the lowest dose on both ipsilateral and contralateral sides (i.e., parotid gland, contralateral parotid gland, and contralateral submandibular gland - CK average D2cm3: 2.3% ($p < 0.001$), 1.5% ($p < 0.001$), 3.6% ($p < 0.001$) vs. BT: 4.8%, 3.5%, 7.3% vs. VMAT: 7.3%, 6.8%, 9.0%) (Table 5). Similar results were obtained when comparing the D0.1cm3 values. The data in Table 5 unequivocally show that among the three techniques, VMAT resulted in the highest dose to the protected organs. Figures 8. and 9. graphically compare the D2cm3 values for the jaw and parotid gland.

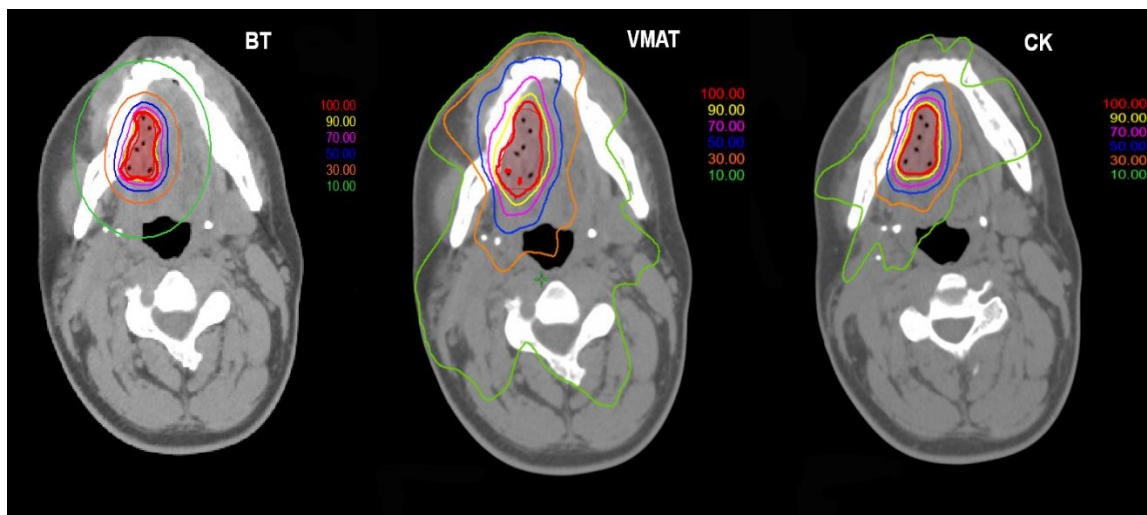
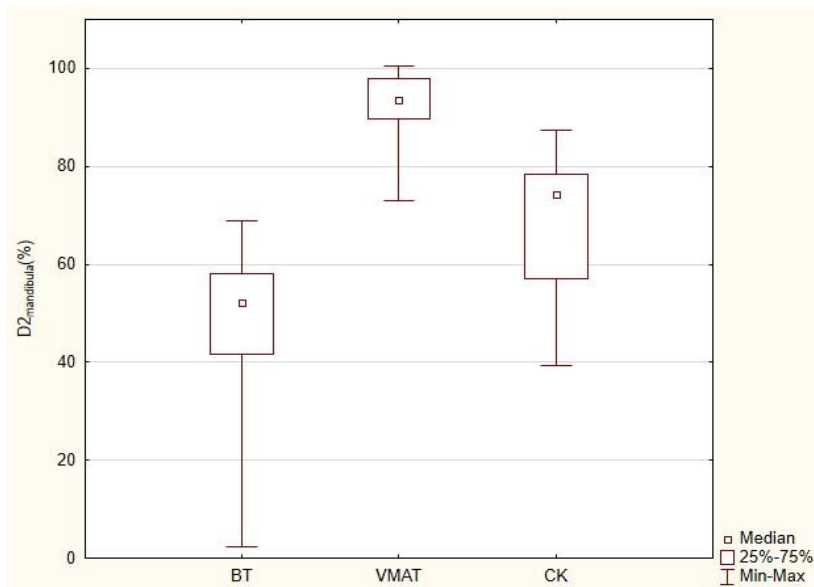


Figure 7. Representative dose distributions in a brachytherapy (BT), a volumetric modulated arc therapy (VMAT) and a Cyberknife (CK) plan. (Ferenczi Ö, 2023 [68])

Table 5. Mean dosimetric parameters of PTV with ranges (Ferenczi Ö., 2023)

	BT	VMAT	CK	p-value*	BT vs. VMAT**	BT vs. CK**	VMAT vs. CK**
V_{PTV} (cm ³)	12.5 (2.6-21.5)	26.5 (7.7-42.6)	17.5 (5.6-33.6)	<0.001	<0.001	0.5553	0.0043
COIN	0.62 (0.48-0.80)	0.84 (0.78-0.87)	0.86 (0.79-0.93)	<0.001	<0.001	<0.001	0.5480
HI	DNR=0.38 (0.30-0.50)	0.09 (0.05 - 0.10)	0.20 (0.17-0.20)	na.	na.	na.	<0.001

Abbreviations: PTV, planning target volume; BT, brachytherapy; VMAT, volumetric modulated arc therapy; CK, Cyberknife; DNR, dose non-uniformity ratio, COIN, conformal index; HI, homogeneity index, V_{PTV} = volume of the PTV

**Figure 8.** Mean dose in % to the most exposed 2 cm³ volume of the mandible

Abbreviations: BT = brachytherapy; VMAT = volumetric modulated arc therapy; CK = Cyberknife; (Ferenczi Ö, 2023 [68])

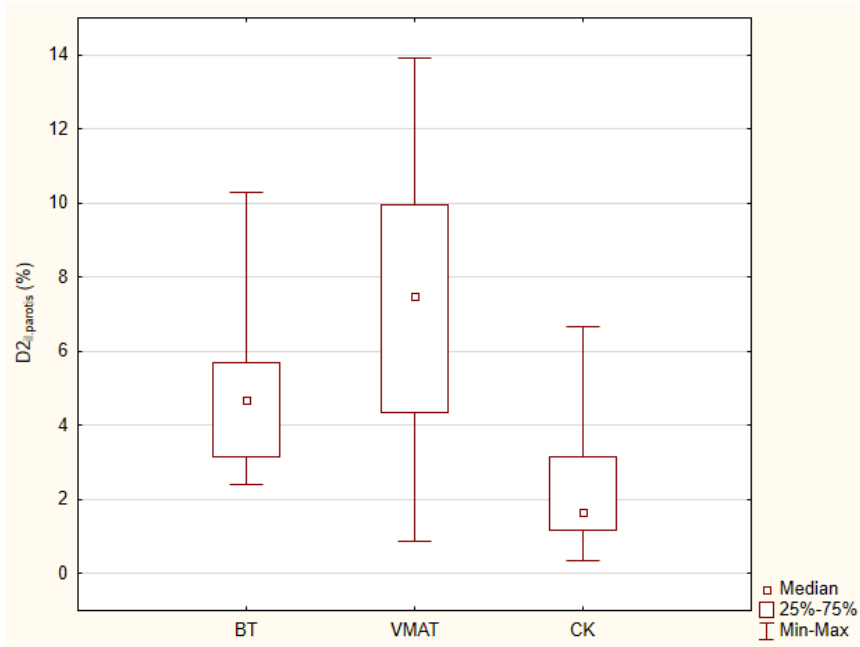


Figure 9. Mean dose to the most exposed 2 cm³ volume of the ipsilateral parotid
Abbreviations: BT = brachytherapy; VMAT = volumetric modulated arc therapy; CK = Cyberknife; (Ferenczi Ö, 2023 [68])

Table 6. Mean dosimetric parameters of OARs with ranges (*Friedman ANOVA **LSD post hoc test NS: non-significant) (Ferenczi Ö., 2023)

		BT	VMAT	CK	p-value*	BT vs. VMAT**	BT vs. CK**	VMAT vs. CK**
mandible	D2 (%)	47.4 (29.2-73.4)	92.2 (73.1-100.4)	68.4 (39.3-87.3)	<0.001	<0.001	<0.001	<0.001
	D0.1 (%)	73.9 (1.7-93.9)	101.8 (97.1-103.9)	92.3 (72.7-100.7)	<0.001	<0.001	<0.001	NS
Il. parotid	D2 (%)	4.8 (2.5-11.9)	7.3 (0.9-13.9)	2.3 (0.3-6.7)	<0.001	0.0011	NS	<0.001
	D0.1 (%)	6.7 (3.5-19.0)	13.8 (3.7-25.0)	5.1 (0.3-12.3)	<0.001	<0.001	NS	<0.001
Cl. parotid	D2 (%)	3.5 (0.0-7.6)	6.8 (0.6-15.8)	1.5 (0.0-4.7)	<0.001	0.0018	NS	<0.001
	D0.1 (%)	4.9 (0.0-11.9)	10.9 (0.9-20.2)	3.3 (0.3-14.0)	<0.001	0.0105	NS	0.0020
Cl. submand	D2 (%)	7.3 (3.9-16.3)	9.0 (0.8-17.7)	3.6 (2.0-6.0)	0.0098	NS	0.0198	0.0016
	D0.1 (%)	9.4 (6.2-21.4)	14.3 (2.1-23.1)	5.6 (3.0-11.3)	0.0098	NS	0.0146	<0.001

Abbreviations: BT = brachytherapy; VMAT = volumetric modulated arc therapy; CK = Cyberknife; PTV = planning target volume; il. parotid = ipsilateral parotid gland; cl. parotid = contralateral parotid gland; cl. submand = contralateral submandibular gland; DX = dose to the most exposed X cm³ volume

6. Discussion

6.1. The Group A

The early stage (T1-2) oral cavity and floor of mouth tumours can be managed with surgery or radiotherapy, yielding similar survival and functional outcomes. Table 7. shows - with a review of publications on the subject - the results achieved by sole surgical management, exclusive brachytherapy, or a combination of external radiotherapy and brachytherapy for early-stage floor of mouth tumours. The former report 84-89% and 86-95% of local tumour control rates and disease-specific survival rates, respectively, depending on tumour size, while the latter report 64-97% and 45-95% local tumour control rates and disease-specific survival rates [33, 49-57, 74-76]. Studies involving brachytherapy commonly employ the LDR method in the management of floor of mouth tumours [55-60].

Table 7. Survival outcomes of floor of mouth tumours treated with surgery alone or with external beam radiotherapy or brachytherapy (LDR)

	Author	n	LC (T1)	LC (T2)	DSS (T1)	DSS (T2)
Surgery	Hicks ⁷⁴	63	84%	86%	95%	86%
	Fu K ⁵¹	22	85%	89%	ND	ND
BT	Mazon ⁵⁵	59	92%	91%	94%	45%
	Marsiglia ⁵⁷	160	93%	88%	ND	ND
	Matsumoto ⁵²	90	89%	66%	95%	67%
	Pernot ⁵⁶	184	97%	72%	88%	47%
EBRT(+/- BT)	Session DG ⁴⁹	28	ND	ND	46%	67%
	Turner SL ⁵⁰	142	87%	67%	ND	ND
	Fukano ⁶¹	51	83%	64%	ND	ND

Abbreviations: n: number of patients; EBRT: external beam radiotherapy, BT: brachytherapy, LDR: low-dose-rate, ND: no data

Table 7. shows that in early stage oral cavity, therefore, tongue base formations, using brachytherapy alone achieves similar locoregional control as surgery. Definitive interstitial radiotherapy is generally considered for neoplasms up to 3 cm in size with negative neck lymph nodes. Brachytherapy is contraindicated in these cases due to the risk of osteoradionecrosis caused by gingival and bone involvement. Interestingly,

comparing brachytherapy alone to external beam radiotherapy plus brachytherapy, brachytherapy yields better outcomes due to its radiobiological characteristics, resulting in more tumour cell destruction, as suggested by Pernot et al.'s comparison of 184 patients [56]. This is particularly evident in T2 tumour size, where brachytherapy alone achieved 92% and 76% locoregional control and disease-specific survival, while external beam radiotherapy plus brachytherapy resulted in 67% and 35% LC and DSS, respectively.

Data from Table 7. also indicate that there are fewer publications related to patients treated solely with surgery. This is understandable, because a significant portion of patients undergo postoperative radiotherapy based on histopathology. Literature data supports the postoperative irradiation of head and neck squamous cell carcinomas in the case of T1-2 tumours, particularly when there are positive or close (<5 mm) surgical margins, lymphovascular invasion, and perineural invasion. The role of adjuvant radiotherapy for T1-2N1 oral cavity tumours was also confirmed by Schrimme et al. [79] in their retrospective analysis of 1539 patients. Post-surgery irradiation increased the 5-year overall survival by 12.8% (54.2% vs. 41.4%, $p < 0.001$) compared to the non-irradiated group, with the greatest benefit observed in T2 primary tumours. Notably, the effect was most pronounced in sublingual tumours among oral cavity locations.

In the study by Hicks et al. [74], for T1-2 tumours, the neck control rate was 81% with surgery alone, increasing to 90% at negative surgical margins but dropping to 62% with margins ≤ 5 mm. The incidence of occult cervical metastases was 21% for T1 and 62% for T2, emphasizing the importance of neck management. Mazon et al. [55] treated 117 patients with T1-2N1-3 tumours, achieving 94% and 75% LC, 94% and 85% regional tumour control, and 94% and 62% disease-specific survival for T1 and T2 tumours, respectively, with 65-70 Gy (LDR brachytherapy) delivered. In the analysis conducted by Marsiglia et al. [57] on 160 patients (T1-2N0-1) treated with brachytherapy alone, the 5-year local control was 76%, with soft tissue and bone necrosis rates of 14% vs. 16%.

Regarding postoperative brachytherapy for oral cavity tumours, especially for tongue base tumours, Lapeyre et al.'s analysis validates the usefulness of brachytherapy after surgery compared to external beam radiotherapy. They found a higher locoregional tumour control rate and lower severe side effect rate with brachytherapy in cases of positive or close surgical margins.

Our results are in line with the aforementioned publications on postoperative HDR brachytherapy for tongue base tumours. In our retrospective study involving 44 patients, we achieved 5 and 10-year locoregional tumour control, regional tumour control, overall survival, and disease-specific survival rates of 89% vs. 89%, 73% vs. 67%, 52% vs. 32%, and 66% vs. 54%, respectively, with a 9% soft tissue necrosis rate and no osteoradionecrosis.

Data from Tables 7. and 8. suggest that the locoregional control achieved with the combination of surgery and exclusive postoperative HDR brachytherapy is significantly comparable to that of sole surgical or radiation treatments. However, the literature emphasizes the advantage of postoperative radiation therapy, especially in cases of positive or close (<5 mm) surgical margins, indicating the superiority of brachytherapy over external beam radiotherapy in this context.

Table 8. Results of sole postoperative brachytherapy in floor of mouth cancer

Author	n	T status	Dose rate	Dose (Gy)	LC (5-year) %	RC (5-year) %	DSS (5-year) %	OS (5-year) %	Toxicity (grade 4) %
Mendenhall et al. (58)	6	T1-2	LDR	60	100	NR	100	66	57
Ange et al. (59)	6	T1-2	LDR	50-60	100	83	NR	NR	17
Lapeyre et al. (60)	17	T1-2	LDR	60	83	NR	NR	NR	6
Ferenczi Ö et al. (53)	44	T1-3	HDR	26* (10-48)	89	73	66	52	9

Abbreviations: n: number of patients, T: tumour, LC: local control, RC: regional control, DSS: disease-specific survival, OS: overall survival, LDR: low-dose-rate, HDR: high-dose-rate, NR: not reported, *: mean dose (*Ferenczi Ö., 2021*)

Elective neck dissection was not performed in 12 patients (27%) due to low-risk tumour characteristics (tumour size not exceeding 3 cm, grade 1-2 differentiation, absence of lymphovascular invasion - except for 1 patient as indicated below - and lack of perineural invasion, with no depth of invasion exceeding 5 mm), as well as confirmed negative regional status through imaging. In three N0 status patients who did not undergo operative elective neck treatment, regional recurrence occurred. In one of these patients - despite lymphovascular invasion - elective lymph node treatment was not planned due to their advanced age and overall health status (83 years old).

The necessity of elective treatment in the neck region (surgically or through irradiation) largely depends on tumour thickness. Fukano et al. [61] found subclinical neck metastasis in 5.9% of cases with tumour thickness smaller than 5 mm, compared to 64.7% in cases with deeper invasion. Some authors recommend elective neck dissection for negative neck status starting from T2 stage [62]. A longer interval between surgery and postoperative radiation exceeding 6 weeks showed a higher rate of local recurrence by 25.8% (31.4% vs. 5.6%, $p < 0.01$) [63]. On the other hand, another publication identified an interval of ≥ 85 days until completion of radiotherapy as a negative factor affecting survival and locoregional control ($p < 0.05$) [64]. In our study, age (≥ 50 years), gender, perineural invasion, grading, dose size (≥ 30 Gy), fraction number (one or more), surgical margin (≥ 2 mm), tumour thickness (< 5 mm, \geq), and the time elapsed between surgery and brachytherapy did not influence survival parameters, however, a significant association was found between lymphovascular invasion and RC, DSS, and OS ($p = 0.0062$, $p = 0.0056$, $p = 0.0325$), as well as between neck recurrence and DSS ($p < 0.0001$) and OS ($p < 0.0001$). In multivariate analysis, neck recurrence remained an independent prognostic factor for both DSS ($p < 0.0001$) and OS ($p = 0.0001$). Analyzing prognostic factors, Lapeyre et al. [65] found no association between tumour size, resection margin, radiation dose, and LC, while Fives et al. [60] characterized invasion depth greater than 10 mm ($p = 0.009$), lymphovascular invasion ($p < 0.001$), perineural spread ($p = 0.003$), and lymph node metastasis ($p = 0.02$) as significant predictors of OS. In the latter study, lymphovascular invasion remained a significant factor in multivariate analysis ($p = 0.009$) [66]. Mattei et al. found a negative impact of positive surgical margins on disease-free survival ($p = 0.007$), with a clear trend towards significance in margins smaller than 3 mm and lymphovascular invasion ($p = 0.058$ and $p = 0.055$, respectively). In another analysis, invasion to the gingiva and/or lesions larger than 3 cm resulted in a 50% lower 5-year LC rate (94% for T1 and 75% for T2). The latter and lymph node positivity proved to be independent negative prognostic factors [55].

In connection with the necessity of postoperative radiotherapy for T1-2N0-1 oral cavity tumours, nowadays there are numerous questions that arise. Ivaldi et al. [77], in their comprehensive review article focusing on the analysis of prognostic factors - after reviewing 5958 articles and selecting 15 studies suitable for analysis, concluded that among the unfavorable tumour characteristics, perineural invasion alone is sufficient

indication for irradiation of the tumour bed or at least the presence of at least two negative factors (lymphovascular invasion, low differentiation, depth of invasion >4 , close margin <5 mm) is necessary to recommend postoperative local irradiation. The neck irradiation therapy is not considered after adequate dissection.

It is worth mentioning that the first study on postoperative stereotactic radiotherapy for early stage head and neck tumours (STEREO POSTOP GORTEC 2017-03 phase II trial) has recently been published [67], in which the toxicity of SBRT was evaluated for pT1-T2/N0 oropharyngeal and oral cavity tumours. Out of the 10 included patients, 2 had surgically resected floor of mouth tumours. The indication for treatment was positive or a margin closer than 5 mm. The total dose administered in 6 fractions was 36 Gy. No necrosis was reported. The most common acute toxicity was grade ≥ 2 mucositis [67].

Although in our retrospective analysis, the fractionation schedules and doses applied were quite heterogeneous - largely due to the discomfort caused by the previously used rigid needles, the limited possibilities of implantation resulting from this, and the lack of experience with HDR brachytherapy - the results did not demonstrate the survival-affecting effect of this. Since 2014, in line with international recommendations, we have been using 15x3 Gy in exclusive postoperative brachytherapy [14,16]. Our results are comparable and similar to the known LDR data in literature, and highlight the enhancing effect of postoperative HDR brachytherapy on local control, possibly counterbalancing the negative influence of positive or close resection margins. The risk of severe complications with HDR approach is low.

Our analysis also highlighted that neck irradiation may be a necessary choice in cases of lymphovascular invasion even after elective neck dissection to reduce neck recurrences, or perhaps exclusive postoperative brachytherapy is not the optimal treatment in these cases. Further studies are needed to find the best therapeutic option in these scenarios.

Regarding the side effects caused by brachytherapy, we observed soft tissue necrosis at an EQD2(3) value of ≥ 59.7 Gy in our own dataset. This result underscores the importance of being cautious with a total dose EQD2(3) of ≥ 60 Gy and higher dose per fraction (>4 Gy). The recommendation from GEC-ESTRO (European Group of

Curietherapy/GEC/ and European Society for Radiotherapy and Oncology/ESTRO/) for HDR head and neck brachytherapy does not advise doses per fraction >4 Gy to reduce tissue damage [14].

A weakness of our retrospective analysis is the heterogeneity in the fractionation schedules and doses applied, partly due to the discomfort caused by the initially available and hence used rigid needles in the early study period, which limited the implementation of fractionated treatment, and partly due to the lack of experience with HDR brachytherapy not only on our part but globally as well. However, the results did not confirm the negative impact of the aforementioned factors on survival parameters. Since 2014, we have been using 15x3 Gy in exclusive postoperative HDR brachytherapy in accordance with international recommendations, and the treatments are well tolerated by the patients [14,16].

6.2 The Group B

Comparison of the new radiotherapeutic technologies in the head and neck region has become an increasingly intriguing area of research in recent times. In our scientific work, we conducted a dosimetric analysis of 20 cases of oral cavity that required exclusive postoperative irradiation of the tumour bed. The analysis allowed us to compare our brachytherapy planning with VMAT and CK techniques for the same target volume, with particular attention to the doses of the organs at risk. This study, so far, is the first investigation in the literature that compared these 3 therapeutic modalities for head and neck tumours [53]. A recent review study already compared brachytherapy dosimetrically with modern EBRT techniques for various types of tumours [38]. Although some authors used different fractionation schemes for postoperative brachytherapy for oral cavity tumours at similar fraction doses (18x3 Gy), since 2014, we have been following international guidelines by applying a fractionation of 15x3 Gy in exclusive postoperative brachytherapy, and based on our experience, patients tolerate this well without Grade 4 toxicity [39, 40, 43, 68].

Our study demonstrated that dosimetrically, brachytherapy competes with even the most advanced EBRT techniques, in terms of delivering higher doses within the target volume and sparing adjacent organs at risk. However, there are only a few publications

in the literature that compare the dose-volume parameters of critical organs between brachytherapy and other radiation therapy modalities.

Ange et al. [59] compared image-guided HDR-BT and IMRT plans for tongue cancer, achieving excellent dose conformity results with image-guided BT (IGBT). Similar results were confirmed with IMRT, but the dose to organs at risk was consistently lower with BT. Ram CA et al. [70] demonstrated the advantages of interstitial HDR BT over IMRT in the comparison for early stage tongue and oral cavity cancer patients. The average doses to critical organs with IMRT were 10.40 Gy to the brain, 19.20 Gy to the spinal cord, 62.99 Gy to the jaw, and 6.03 Gy and 5.70 Gy to the il. and cl. parotid glands, while with BT, these doses were 1.30 Gy, 1.40 Gy, 36.50 Gy, and 1.60 Gy and 1.00 Gy. The conformity index (CI) for IMRT and BT plans was 0.86 and 0.71, respectively. With comparable CI values, doses to critical organs favored BT plans over IMRT, which was statistically significant. Yoshida et al. [41] were the first to report on the dose-volume histogram analysis of HDR BT in tongue cancer in 2014. Using image-based planning, the average V100 (CTV), average D0.1cm³ (mandible), and D2cm³ (mandible) were 98.1%, 80.1%, and 55.7%, respectively. Akiyama et al. [42] corroborated Yoshida's results in their 2018 publication, which is considered the largest study in this area. Their study compared dosimetry of IGBT and VMAT for head and neck cancer cases in terms of PTV and OAR dose distribution. Thirty-eight consecutive patients with T1-4 tongue, oral cavity, and the base of tongue cancer were selected for IGBT treatment. VMAT treatment plans were also prepared for each patient using the same CT data. The V100 value was higher with IGBT (89.0% vs. 76.7%, $p < 0.05$). The IGBT technique resulted in significantly lower mean doses to organs at risk compared to VMAT (mandible: D0.1cm³ 77.0% vs. 85.4%, D2cm³ 48.4% vs. 68.4%, $p < 0.05$; il. parotis: D0.1cm³ 9.1% vs. 13.8%, D2cm³ 7.0% vs. 10.5%, $p < 0.05$; cl. parotis: D0.1cm³ 8.9% vs. 15.3%, D2cm³ 4.9% vs. 9.1%, $p < 0.05$; cl. submandibular glands: D0.1cm³ 13.4% vs. 29.7%, D2cm³ 8.1% vs. 18.3%, $p < 0.05$). The results clearly support the advantage of IGBT in protecting organs at risk.

Similar results were also achieved by us in presenting dosimetric comparative study in favor of the IGBT technique [54]. Akiyama and colleagues used the same PTV for BT and VMAT, whereas in our present comparative analysis, we used the commonly applied extension for the PTV in external irradiation (CTV + 3 mm), thus the average

PTV volume was smaller in the case of BT (VPTV 12.5 cm³ vs. 26.6 cm³, $p < 0.001$), which also serves as an advantage of this technique, as it is more suitable for protecting surrounding healthy tissues. Among the three techniques, the most conformal dose distribution is achievable with CK (COIN = 0.86), whereas homogeneity was better with VMAT (HI = 0.09). In the case of BT, the conformity was poorer compared to EBRT, but its advantage lied in the lower doses reaching the jawbone. ORN is one of the most dreaded complications in radiation therapy of head and neck tumours. Its incidence has decreased in recent times, from around 20% a few decades ago to 4-8% now (in the modern era). This trend can be attributed to the advancements in RT techniques, such as the currently used IMRT technique. Peterson and colleagues [69] ranked, based on 43 articles between 1990 and 2008, the proportion of bone necrosis caused by each therapy in terms of frequency. The weighted prevalence of ORN was 7.4%, 5.1%, 6.8%, and 5.3% for conventional RT, IMRT, chemoradiotherapy, and BT, respectively. Our results also confirm that the jawbone can be better protected with BT than with VMAT technique. CyberKnife stereotactic radiotherapy presents an attractive therapeutic option, as it entails lower fraction numbers (compared to BT), steep dose gradients, lower dose exposure to organs at risk, and the short treatment duration. It offers an effective treatment option for previously irradiated, recurrent head and neck tumours, especially in non-resectable tumours, and in elderly or patients not amenable to other therapies. However, in negative lymph node status (oral cavity) tumours where definitive local RT is recommended, or in postoperative care where neck RT is not needed, it has been considered as a therapeutic option, though currently only in the form of clinical trials. The STEREO POSTOP GORTEC 2017-03 trial is a non-randomized phase II trial, the first prospective study evaluating the benefits of postoperative stereotactic radiotherapy (SBRT) in early-stage oral and oropharyngeal cancer patients at high risk of positive surgical margins. In SBRT, a total dose of 36 Gy was delivered in 6 fractions over 2 weeks. The primary endpoint is severe late toxicity, with secondary endpoints including acute toxicity, local and locoregional control, disease-free and overall survival, and quality of life, with a planned completion date of January 2024. A recent publication has emerged on the preliminary results of the 10 patients enrolled in the study [54]. In each case, two treatment plans were created and compared, with one using only 2 coplanar arcs (VMATc), while the other using 1 coplanar arc and 3 non-coplanar arcs (VMATc+nc). The average Dmean for the

oral cavity, lips, and ipsilateral parotid gland were 16.8 Gy, 11.1 Gy, and 10.4 Gy in the former, compared to 14.8 Gy ($p = 0.005$), 8.1 Gy ($p = 0.001$), and 6.5 Gy ($p = 0.04$) in the latter technique. According to the study protocol, CTV was defined as the initial tumour bed, including positive or close margins, with a 5-10 mm expansion. A 2 mm setup margin was introduced around the CTV to create the PTV. If necessary, a 2 mm margin was applied around the OARs to create planning OAR volumes.

The stereotactic contouring protocols are highly heterogeneous, but generally involve a 1-5 mm extension from GTV to CTV and a 2-3 mm extension from CTV to PTV in the case of head and neck tumours. In our comparative study, we utilized a 2 mm extension from CTV to PTV.

Zhang Y. et al. [78] investigated the feasibility of laryngeal SBRT therapy on a conventional gantry-based linac system. They compared the plan quality with CK-based planning on an anthropomorphic head and neck phantom. The study confirmed that a gantry-based linear accelerator using non-coplanar VMAT arcs can provide similar dosimetric endpoints as CyberKnife.

According to the current study, the dose received on the lower jaw was most favorable with BT in terms of Dx ($p < 0.001$), while for the salivary glands (parotid and submandibular glands), CK technique resulted in the lowest dose, surpassing BT for the submandibular gland (average D_{2cm³}: $p = 0.0198$, average D_{0.1cm³}: $p = 0.0146$). The highest dose to critical organs was observed with the VMAT technique. These findings confirm that despite being an invasive technique, BT has clear beneficial effects in terms of dosimetry for the treatment of oral cavity tumours, and is a modality worth considering in radiation therapy applications, not only as definitive treatment but also postoperatively. The use of CK in the head and neck region requires further investigation.

While the parotid glands are important for saliva production, providing 70% of saliva, their relatively greater distance from the target volume results in negligible radiation exposure, which otherwise leads to xerostomia.

A limitation of our study is that while VMAT and BT techniques are routinely used in our department for the treatment of oral cavity tumours, we lack experience with CK therapy in treating this region. Another limitation is that this is a dosimetric comparison without discussion of the clinical consequences. In the future, it would be

interesting to study the side effects and survival parameters when these different radiotherapy methods are used in conjunction for postoperative management of oral cavity tumours.

7. Conclusion

This study presents data on high dose rate (HDR) brachytherapy about solitary postoperative BT for floor of mouth cancers for the first time. Based on the analysis, solitary HDR BT is a suitable method for postoperative radiation treatment of malignant T1-2N0-1 stage floor of mouth tumours, in conjunction with appropriate surgical treatment of the neck. The results are comparable and similar to those of solitary surgical and radiation treatments reported in the literature. However, it is important to highlight that in cases of close (<5 mm) or positive surgical margins, the advantages of postoperative radiation therapy are always observed, demonstrating the superiority of BT over external beam radiation therapy (EBRT). Data from limited and small-scale postoperative low dose rate (LDR) studies are comparable and draw attention to the enhancing effect of postoperative BT on local tumour control, which can counterbalance the negative impact of positive or close resection margins, as opposed to exclusive surgical treatment. The risk of severe complications is low with the HDR method.

Univariate analysis of prognostic factors confirmed the significant negative prognostic impact of lymphovascular invasion on recurrence-free survival, disease-specific survival, and overall survival, as well as on neck recurrence and distant metastases. Therefore, neck radiation following elective neck dissection should still be considered in cases of lymphovascular invasion, alongside solitary postoperative BT, to reduce neck recurrences.

This is the first study in the literature to perform dosimetric comparisons of volumetric modulated arc therapy (VMAT), CyberKnife (CK), and HDR BT techniques with respect to critical organs in head and neck cancers, specifically in operated tongue and floor of mouth tumours. It was observed that the dose received by the jaw was most favorable with BT, while CK resulted in the lowest dose to the salivary glands (parotid and submandibular glands). The highest dose to critical organs was observed with VMAT. These findings reinforce that despite being an invasive technique, BT has clear dosimetric benefits in the treatment of oral cavity tumours and is worth considering in radiation therapy, not only as definitive treatment but also postoperatively. The application of CK in the head and neck region requires further investigation.

References

- [1] National Library of Medicine. Oral Cancer Prevalence, Mortality, and Costs in Medicaid and Commercial Insurance Claims Data. [Internet]. 2020. Available from: <https://www.ncbi.nlm.nih.gov/pmc/articles/PMC9437560/>
- [2] World Cancer Research Fund International. Mouth and oral cancer statistics. [Internet]. 2020. Available from: <https://www.wcrf.org/cancer-trends/mouth-and-oral-cancer-statistics>
- [3] Chen AY, Myers JN (2001) Cancer of the oral cavity. *Dis Mon*; 47(7): 275–361.
- [4] Remenár É, Éles K, Németh Zs. (2018) Lip and oral cavity tumours. In: Kásler M. (ed.): *Basics of oncology. [Ajak- és szájüregi daganatok. In: Kásler M. (szerk.) Az onkológia alapjai.]* Medicina Könyvkiadó, Budapest, pp. 379–400.
- [5] Takácsi-Nagy Z, Martínez-Mongue R, Mazon JJ, Cristopher JA, Louis BH. (2017) American Brachytherapy Society Task Group report: combined external beam irradiation and interstitial brachytherapy for base of tongue s and other head and neck sites in the era of new technologies. *Brachytherapy*, 16: 44–58.
- [6] Chinn SB, Myers JN. (2015) Oral cavity carcinoma: current management, controversies, and future directions. *J Clin Oncol*, 33: 3269–3276.
- [7] Sternick ES, editor. (1997) *The theory and practice of intensity modulated radiation therapy*. Madison WI: Advanced Medical Publishing 1st edition: 1997. 54-74 p.
- [8] Grégoire V, De Neve W, Eisbruch A, Nancy L, Danielle VW, Dirk VG. (2007) Intensity-Modulated Radiation Therapy for Head and Neck Carcinoma. *The Oncologist*, 12: 555-564.
- [9] Yu CX, Li XA, Ma L, Dongjun C, Shahid N, David S, Mehrdad S, Timothy WH, Mohan S, Carl MM. (2002) Clinical implementation of intensity-modulated arc therapy. *Int J Radiat Oncol Biol Phys*, 53: 453-63.

- [10] Osborn J. (2017) Is VMAT beneficial for patients undergoing radiotherapy to the head and neck? *Radiography*; 23: 73-76.
- [11] Adler JR, Cox RS. (1996) Preliminary experience with CyberKnife - Radiosurgery. Basel: S.Karger; 112-138.
- [12] Kurup G. (2010) CyberKnife: A new paradigm in radiotherapy. *J Med Phys*, 35: 63-64.
- [13] Németh Zs., Somogyi A., Takácsi-Nagy Z, Barabás J, Németh G, Szabó G. (2000) Possibilities of preventing osteoradionecrosis during complex therapy of tumors of the oral cavity. *Pathol Oncol Res*, 6: 53-58.
- [14] Kovács G. (2015) Modern head and neck brachytherapy: from radium towards intensity modulated interventional brachytherapy. *J Contemp Brachytherapy*, 6: 404–416.
- [15] Mazon JJ, Ardiet JM, Haie-Méder C, György K, Peter L, Didier P, Alfredo P, Angels R, Vratislav S. (2009) GEC-ESTRO recommendations for brachytherapy for head and neck squamous cell carcinomas. *Radiother Oncol*, 91: 150–156.
- [16] Ghadjar P, Bojaxhiu B, Simcock M, Terribilini D, Isaak B, Gut P, Wolfensberger P, Brömme JO, Geretschlager A, Behrensmeier F, Pica A, Aebbersold D. (2012) High dose-rate versus low dose-rate brachytherapy for lip cancer. *Int J Radiat Oncol Biol Phys*, 83: 1205–1212.
- [17] Nag S, Cano ER, Demanes DJ, Puthawala AA, Vikram B. (2001) The American Brachytherapy Society recommendations for high-dose-rate brachytherapy for head-and-neck carcinoma. *Int J Radiat Oncol Biol Phys*, 50: 1190–1198.
- [18] Visser AG, van den Aardweg GJ, Levendag PC. (1996) Pulsed dose rate and fractionated high dose rate brachytherapy: choice of brachytherapy schedules to replace low dose rate treatments. *Int J Radiat Oncol Biol Phys*, 34: 497–505.
- [19] Pernot M, Luporsi E, Hoffstetter S, Pfeiffert D, Aletti P, Marchal C, Kozminski P, Noel A, Bey P. (1997) Complications following definitive irradiation for cancers of the oral cavity and the oropharynx (In a series of 1134 patients). *Int J Radiat Oncol Biol Phys*, 37: 577-585.

- [20] Fayos J.V. (1980) The role of radium implants in cancer of the oral cavity and oral pharynx. *Int J Radiat Oncol Biol Phys*, 6: 423-429.
- [21] Vándor F., Selymes Z. (1952) Vallecule praeepiglottica carcinomájának rádium tüzdelése. *Magy Rad*, 4: 32-38.
- [22] Vikram B., Hilaris B.S. (1981) A non-looping after-loading technique for interstitial implants of the base of the tongue. *Int J Radiat Oncol Biol Phys*, 7: 419-422.
- [23] Henschke U.K., Hilaris B.S., Mahan G.D. (1963) Afterloading in interstitial and intracavitary radiation therapy. *Am J Roentgenol*, 90: 386-395.
- [24] Henschke U.K., Hilaris B.S., Mahan G.D. (1963) Afterloading applicator for treatment of cancer of the uterus. *NY State J Med*, 64: 624-628.
- [25] Pierquin B., Chassagne D.J., Cox J.D. (1971) Toward consistent local control of certain malignant tumors. *Ther Radiology*, 99: 661-667.
- [26] Pierquin B., Dutreix A., Paine CH, Chassagne D, Marinello G, Ash D. (1978) The Paris System in interstitial radiation therapy. *Acta Radiol Oncol*, 17: 33-48.
- [27] Pierquin B., Wilson J.F., Chassagne D. (1987) *Modern Brachytherapy*. Book Medical Publishers, New York, 216-240 p.
- [28] Levin W., Wasserman, H.J. (1978) An improved technique for interstitial radiotherapy of the tongue. *Brit J Radiol*, 51: 213-217.
- [29] Vikram B., Strong E., Shah J, Spiro R, Gerold F, Session R, Hilaris B. (1985) A non-looping after-loading technique for base of tongue implants: results in the first 20 patients. *Int J Radiat Oncol Biol Phys*, 11: 1853-1855.
- [30] Clarke D.H., Edmundson G.K., Martinez A, Richard CM, Cathy W. (1988) The utilization of I-125 seeds as a substitute for Ir-192 seeds in temporary interstitial implants: An overview and a description of the William Beaumont Hospital technique. *Int J Radiat Oncol Biol Phys*, 15: 1027-1033.

- [31] Stannard C., Maree G., Tovey S, Hunter A, Wetter J. (2014) Iodine-125 brachytherapy in the management of squamous cell carcinoma of the oral cavity and oropharynx. *Brachytherapy*, 13:405-412.
- [32] Konishi M., Takeuchi Y., Imano N, Kubo K, Nishibuchi I, Murakami Y, Shimabukuro K, Wongratwanich P, Kakimoto N, Nagata Y. (2022) Brachytherapy with ¹⁹⁸Au grains for cancer of the floor of the mouth: relationships between radiation dose and complications. *Oral Radiol*, 38:105-113.
- [33] Bachaud JM, Delannes M, Allouache N, Benchalal M, Alzieu C, David JM, Serrano E, Daly-Schveitzer NJ. (1994) Radiotherapy of stage I and II carcinomas of the mobile tongue and/or floor of mouth. *Radiother Oncol*, 31:199-206.
- [34] Goineau A, Piot B, Malard O, Ferron C, Lisbona A, Cassagnau E, Delamazure AS, Campion L, Bardet E. (2014) Postoperative interstitial brachytherapy for resectable squamous cell carcinoma of the tongue. *Brachytherapy*, 14:71–76.
- [35] Cheng HS, Liu SA, Lin JC. (2020) Survival outcome and prognostic factor analyses in early tongue cancer patients treated with surgery alone. *Ther Radiol Oncol*, 4:7.
- [36] Baltas D, Kolotas C, Geramani K, Mould RF, Ioannidis G, Kekchidi M, Zamboglou N. (1998) A conformal index (COIN) to evaluate implant quality and dose specification in brachytherapy. *Int J Radiat Oncol Biol Phys*, 40: 515-524.
- [37] ICRU Report 83, Prescribing, Recording, and Reporting Photon-Beam Intensity-Modulated Radiation Therapy (IMRT) (2012) *Strahlenther Onkol*, 188(1): 97-9.
- [38] Major T, Fröhlich G, Ágoston P, Polgár Cs, Takácsi-Nagy Z. (2022) The value of brachytherapy in the age of advanced external beam radiotherapy: a review of the literature in terms of dosimetry. *Strahlenther Onkol*, 198: 93-109.
- [39] Petera J, Sirák I, Laco J, Kasaova L, Tucek L, Dolezalova H. (2015) High-dose-rate brachytherapy in early oral cancer with close or positive margins. *Brachytherapy*, 14(1): 77-83.

- [40] NCCN Clinical Practice Guidelines in Oncology. Version 2.2023, Head and Neck Cancers. [Internet]. 2023. Available from: <http://www.nccn.org/guidelines/guidelines-detail?category=1&id=1437>
- [41] Yoshida K, Takenaka T, Akiyama H, Yamazaki H, Yoshida M, Masui K, Kotsuma T, Baek S, Uesugi Y, Shimbo T, Yoshikawa N, Arika T, Koretsune Y, Yoshioka Y, Narumi Y. (2014) Three-dimensional image-based high-dose-rate interstitial brachytherapy for mobile tongue cancer. *J Radiat Res*, 55: 154-161.
- [42] Akiyama H, Pesznyák C, Béla D, Ferenczi Ö, Major T, Polgár Cs, Takácsi-Nagy Z. (2018) Image guided high-dose-rate brachytherapy versus volumetric modulated arc therapy for head and neck cancer: A comparative analysis of dosimetry for target volume and organs at risk. *Radiol Oncol*, 52: 461-467.
- [43] Takácsi-Nagy Z, Ferenczi Ö, Major T, Akiyama H, Fröhlich G, Oberna F, Révész M, Poósz M, Polgár Cs. (2022) Results of sole postoperative interstitial, high-dose-rate brachytherapy of T1-2 tongue tumours. *Strahlenther Onkol*, 198: 812-819.
- [44] Cox JD, Stez J, Pajak TF. (1995) Toxicity criteria of the Radiation Therapy Oncology Group (RTOG) and the European Organization for Research and Treatment of Cancer (EORTC). *Int J Radiat Oncol Biol Phys*, 31: 1341-1346.
- [45] Yamazaki H, Yoshida K, Yoshioka Y, Shimizutani K, Furukawa S, Koizumi M, Ogawa K. (2013) High dose rate brachytherapy for oral cancer. *J Radiat Res*, 54: 1-17.
- [46] Kovács G, Martinez-Monge R, Budrukkar A, Guinot JL, Johansson B, Strnad V, Skowronek J, Roviroso A, Siebert FA. (2017) GEC-ESTRO ACROP recommendations for head & neck brachytherapy in squamous cell carcinomas: 1st update – Improvement by cross sectional imaging based treatment planning and stepping source technology. *Radiother Oncol*, 122: 248-254.
- [47] Kaplan EL, Meier P. (1958) Nonparametric estimation from incomplete observations. *J Am Stat Assoc*, 53: 457-481.
- [48] Cox DR. (1972) Regression models and life tables. *J R Stat Soc*, 34: 187-220.

- [49] Sessions DG, Spector GJ, Lenox J, Parriott S, Haughey B, Chao C, Marks J, Perez C. (2000) Analysis of treatment results for floor-of-mouth cancer. *Laryngoscope*, 110 (10 Pt 1): 1764-72.
- [50] Turner SL, Slevin NJ, Gupta NK, Swindell R. (1996) Radical external beam radiotherapy for 333 squamous carcinomas of the oral cavity evaluation of late morbidity and a watch policy for the clinically negative neck. *Radiother Oncol*, 41; 21-29.
- [51] Fu KK, Lichter A, Galante M. (1976) Carcinoma of the floor of mouth: An analysis of treatment results and the sites and causes of failures. *Int. J. Radiat. Oncol. Biol. Phys*, 1: 829-837.
- [52] Matsumoto S, Takeda M, Shibuy H, Suzuki S. (1996) T1 and T2 squamous cell carcinomas of the floor of the mouth: results of brachytherapy mainly using ^{198}Au grains. *Int. J. Radiat. Oncol. Biol. Phys*, 34: 833-841.
- [53] Ferenczi Ö, Major T, Akiyama H, Fröchlich G, Oberna F, Révész M, Polgár Cs, Takácsi-Nagy Z. (2021) Results of postoperative interstitial brachytherapy of resectable floor of mouth tumors. *Brachytherapy Journal*, 57(4): 516-523.
- [54] Biau J, Lopez L, Thivat E, Casile M, Millardet C, Saroul N, Pham-Dang N, Molnar I, Bourhis J, Lapeyre M. (2023) Postoperative SBRT in the treatment of early-stage oropharyngeal and oral cavity cancers with high-risk margins: A dosimetric comparison of volumetric modulated arc therapy with or without non-coplanar arcs and acute toxicity outcomes from the STEREOPOSTOP GORTEC 2017–03 phase 2 trial. *Clinical and Translational Radiation Oncology*, 38: 169-174.
- [55] Mazon JJ, Grimard L, Raynal M, Haddad E, Martin M, Marinello G, Nair RC, Bourgeois JL, Pierquin B. (1990) Iridium-192 curietherapy for T1 and T2 epidermoid carcinomas of the floor of mouth. *Int J Radiat Oncol Biol Phys*, 18: 1299-1306.
- [56] Pernot M, Hoffstetter S, Peiffert D, Luporsi E, Marchal C, Kozmiski P, Dartois D, Bey P. (1995) Epidermoid carcinomas of the floor of mouth treated by exclusive irradiation: Statistical study of a series of 207 cases. *Radiother Oncol*, 35: 1737-185.

- [57] Marsiglia H, Haie-Meder C, Sasso G, Mamelle G, Gerbaulet A. (2002) Brachytherapy for T1-T2 floor-of-the-mouth cancers: The Gustave-Roussy Institute experience. *Int J Radiat Oncol Biol Phys*, 52: 1257–1263.
- [58] Mendenhall WM, Parsons JT, Stringer SP, Cassisi NJ, Million RR. (1989) Radiotherapy after excisional biopsy of carcinoma of the oral tongue/floor of mouth. *Head Neck*, 11: 129-131.
- [59] Ange DW, Lindberg RD, Guillaumondegui OM. (1975) Management of squamous cell carcinoma of the oral tongue and floor of mouth after excisional biopsy. *Radiology*, 116: 143-146.
- [60] Lapeyre M., Hoffstetter S, Peiffert D, Guérif S, Maire F, Dolivet G, Toussaint B, Mundt A, Chassagne JF, Simon C, Bey P. (2000) Postoperative brachytherapy alone for T1-2N0 squamous cell carcinomas of the oral tongue and floor of mouth with close or positive margins. *Int J Radiat Oncol Biol Phys*, 48: 37–42.
- [61] H Fukano , H Matsuura, Y Hasegawa, Nakamura S. (1997) Depth of invasion as a predictive factor for cervical lymph node metastasis in tongue carcinoma. *Head Neck*, 19(3): 205-10.
- [62] Zupi A, Califano L, Mangone GM, Longo F, Piombino P. (1998) Surgical management of the neck in squamous cell carcinoma of the floor of the mouth. *Oral Oncol*, 34: 472-475.
- [63] Vikram B. (1979) Importance of the time interval between surgery and postoperative radiation therapy in the combined management of head and neck cancer. *Int J Radiat Oncol Biol Phys*, 5: 1837–1840.
- [64] Rosenthal DI, Mohamed ASR, Garden AS, William HM, Adel KEN, Mona K, Randal SW, Clifton DF, Lester JP. (2017) Final Report of a Prospective Randomized Trial to Evaluate the Dose-Response Relationship for Postoperative Radiation Therapy and Pathologic Risk Groups in Patients with Head and Neck Cancer. *Int J Radiat Oncol Biol Phys*, 98: 1002-1011.

[65] M Lapeyre , D Peiffert, S Hoffstetter, Pernot M, Dolivet G, Simon C, Chassagne JF, Bey P. (1997) Postoperative brachytherapy: A prognostic factor for local control in epidermoid carcinomas of the mouth floor. *Eur J Surg Oncol*, 23: 243-246.

[66] Fives C, Feeley L, O'Leary G, Sheahan P. (2016) Importance of lymphovascular invasion and invasive front on survival in floor of mouth cancer. *Head Neck.*, 38 (Suppl 1): E1528-34.

[67] Julian Biau , Emilie Thivat , Corinne Millardet, Saroul N, Pham-Dang N, Molnar I, Pereira B, Durando X, Bourhis J, Lapeyre M. (2020) A multicenter prospective phase II study of postoperative hypofractionated stereotactic body radiotherapy (SBRT) in the treatment of early-stage oropharyngeal and oral cavity cancers with high risk margins: the STEREO POSTOP GORTEC 2017-03 trial, *BMC Cancer*, 20(1): 730.

[68] Ferenczi Ö, Major T, Fröhlich G, Béla D, Tódor SZ, Polgár CS, Akiyama H, Bukovszky B, Takácsi-Nagy Z. (2023) Dosimetric comparison of postoperative interstitial high-dose-rate brachytherapy and modern external beam radiotherapy modalities in tongue and floor of the mouth tumours in terms of doses to critical organs, *Radiol Oncol*, 57(4):516-523.

[69] Peterson DE, Doerr W, Hovan A, Pinto A, Saunders D, Elting LS, Spijkervet FKL, Brennan MT. (2010) Osteoradionecrosis in cancer patients: the evidence base for treatment-dependent frequency, current management strategies, and future studies. *Support Care Cancer*, 18:1089-1098.

[70] Ram Charith Alva, A. S. Kirthi Koushik, B. Sweta, Janaki MG, Arul Ponni TR, Kumar M, Yuvaraj B, Revath T. (2020) Brachytherapy for Oral Cavity Cancers in the Era of Intensity-Modulated Radiotherapy: Save it or Shelve it. *Indian J Surg Oncol*. 11(3): 406–411.

[71] Orton C.G., Ezzel G.A. (1998) Physics and dosimetry of high-dose-rate brachytherapy. In: Perez C.A., Brady L.W., szerk., *Principles and Practice of Radiation Oncology*. 3rd ed., Lippincott-Raven Publishers, Philadelphia, 469-486 p.

[72] Steel G.G. (1993) The dose-rate effect: brachytherapy. In: Steel G.G. szerk., Basic Clinical Radiobiology. 1st ed., Edward Arnold Publishers, London, 120-129 p.

[73] Skowronek J. (2010) Pulsed dose rate brachytherapy - is it the right way? J Contemp Brachytherapy, 2:107-113.

[74] Hicks WL, Loree TR, Garcia RI, Maamoun S, Marshall D, Ornen JB, Bakamjian VY, Shedd DP. (1997) Squamous cell carcinoma of the floor of mouth: a 20-year review. Head Neck, 19:400-405.

[75] Hintz B, Charyulu K, Chandler JR, Sudarsanam A, Garciga C. (1979) Randomized study of local control and survival following radical surgery or radiation therapy in oral and laryngeal carcinomas. J Surg Oncol, 12:61-74.

[76] Rodgers LW, Stringer SP, Mendenhall WM, Parsons JT, Cassis NJ, Million RR. (1993) Management of squamous cell carcinoma of the floor of mouth. Head Neck, 15:16-19.

[77] Ivaldi E, Di Mario D, Paderno A, Piazza C, Bossi P, Iacovelli NA, Incandela F, Locati L, Fallai C, Orlandi E. (2019) Postoperative radiotherapy (PORT) for early oral cavity cancer (pT1–2, N0–1): a review. Crit Rev Oncol Hematol, 143:67–75.

[78] Zhang Y, Chiu T, Dubas J, Zhen T, Pam L, Xuejun G, Yulong Y, David S, Robert T, Bo Z. (2019) Benchmarking techniques for stereotactic body radiotherapy for early-stage glottic laryngeal cancer: LINAC-based non-coplanar VMAT vs. Cyberknife planning. Radiat Oncol, 14:193.

[79] Shrime MG, Gullane PJ, Dawson L, Kim J, Gilbert RW, Irish JC, Brown DH, Goldstein DP. (2010) The impact of adjuvant radiotherapy on survival in T1-2 N1 squamous cell carcinoma of the oral cavity. Arch Otolaryngol Head Neck Surg. 136:225-228.

9. Bibliography of the candidate's publications

List of publications on the topic of the dissertation:

English-language peer-reviewed publications:

Ferenczi Ö, Major T, Akiyama H. (2020) Results of postoperative interstitial brachytherapy of resectable floor of mouth tumors. Brachytherapy Journal, 20(2):376-382

IF: 1.9

Ferenczi Ö, Major T, Fröhlich G. (2023) Dosimetric comparison of postoperative interstitial high-dose-rate brachytherapy and modern external beam radiotherapy modalities in tongue and floor of the mouth tumours in terms of doses to critical organs, Radiol Oncol. 57(4):516-523

IF: 2.4

Hungarian-language peer-reviewed publications:

Ferenczi Ö, Major, T, Takácsi-Nagy Z. (2021) A brachytherapia szerepe az ajak-szájüregi daganatok kuratív ellátásában = The role of brachytherapy in the curative treatment of oral cavity tumors, Orv Hetil. 12:162(37):1471-1479

IF: 0.7

The cumulative impact factor of publications on the topic of the dissertation: 5.0

Peer-reviewed publications closely related to the topic of the dissertation:

Takácsi-Nagy Z, Ferenczi Ö, Major T. (2022) Results of sole postoperative interstitial, high-dose-rate brachytherapy of T1-2 tongue tumours. Strahlenther Onkol, 198: 812-819

IF: 3.1

Akiyama H, Pesznyák C, Béla D, Ferenczi Ö. (2018) Image guided high-dose-rate brachytherapy versus volumetric modulated arc therapy for head and neck cancer: A comparative analysis of dosimetry for target volume and organs at risk. *Radiol Oncol*, 52: 461-467

IF: 2.4

Other publications on the treatment of head and neck cancer:

Mónika Révész, Ferenc Oberna, András Slezák, Erika Tóth, Örs Ferenczi (2024). EZH2 Expression in Head-and-Neck Squamous Cell Cancer in Young Patients. *Int. J. Mol. Sci.* 25(10), 5250

IF: 4.9

Mónika Révész, Ferenc Oberna, András Slezák, Örs Ferenczi (2023). The characteristics of head and neck squamous cell cancer in young adults: A retrospective single-center study. *Pathol Oncol Res.* 24:29:1611123.

IF: 2.3

Total cumulative impact factor of the author of the dissertation: 17.7

10. Acknowledgements

I would like to take this opportunity to thank all those who have helped me in my work.

I am especially grateful to my supervisor Dr. med. habil. Zoltán Takácsi-Nagy, from whom I received the help I needed for all my professional and scientific advancement, and from whom I learned the importance of persistent and thorough scientific work. His encouragement has given me the strength to devote time to writing scientific papers in addition to my clinical work.

I am grateful to Professor Tibor Major, Head of the Physics Department, who has improved the quality of my research with his valuable advices helping my clinical and scientific work.

I would like to thank my former boss, currently the Director of the Institute, Prof. Dr. Csaba Polgár, for his continuous support.

I would also like to express my special thanks to the head of the head and neck surgery department, Dr. Ferenc Oberna, and to all my colleagues, without whom I would not have been able to carry out the implants.

I am grateful to Georgina Fröhlich Ph.D., Szabolcs Tódor ph.D. and Dalma Béla, for their help in processing dosimetric data and with statistical analysis.

I would also like to express my gratitude to my colleagues in the Brachytherapy Department and to the nursing staff working in the department.

Many thanks to Professor András Matolcsy, the head of the Doctoral School of Pathological Sciences, who allowed me to write this dissertation.

Also, many thanks to all my colleagues who supported my work.

Last but not least, I would like to thank my family and my wife Veronika (also my kids Lotti and Zente) for providing a peaceful background for me during my scientific work.

