DOI:10.14753/SE.2015.2110

Pituitary gland dysfunction: Clinical and experimental studies

Ph.D. thesis

Dr. Judit Dénes

Semmelweis University

Doctoral School of Clinical Medicine

Supervisor: Dr. Miklós Góth, Ph.D., D.Sc.
Consultant: Dr. Márta Korbonits, Ph.D., D.Sc.

Official reviewers: Dr. Attila Patócs, Ph.D.
Dr. Miklós Bodor, Ph.D.

Head of the Final Examination Committee: Dr. László Gerő, Ph.D., D.Sc.
Members of the Final Examination Committee: Dr. Ágnes Sallai, Ph.D.
Dr. Gábor Speer, Ph.D.

Budapest

2015

DOI:10.14753/SE.2015.2110

1. Table of contents

1. Table of contents 2

2. List of abbreviations ..... **Error! Bookmark not defined.**

3. Introduction 9

3.1. Pituitary tumors 9

3.2. Pituitary tumorigenesis 10

3.2.1. Cell cycle dysregulation 15

3.2.2. Growth factors 16

3.2.3. Transcriptional regulators 16

3.3. Pituitary adenomas and microRNAs (study I) 17

3.3.1. MicroRNAs – Definition, biosynthesis and binding to target mRNAs 17

3.3.2. MicroRNAs and pituitary adenomas 19

3.4. Pituitary adenomas and pheochromocytomas/paragangliomas (study II) 22

3.4.1. Pheochromocytoma secreting hypothalamic or pituitary hormones causing acromegaly or Cushing syndrome 25

3.4.2. Pituitary adenoma causing genes and pheochromocytoma/paraganglioma 26

3.4.2.1. Multiple endocrine neoplasia type 1 26

3.4.2.2. Multiple endocrine neoplasia type 4 29

3.4.2.3. Familial isolated pituitary adenoma 30

3.4.2.4. Carney complex 30

3.4.3. Pheochromocytoma/paraganglioma causing genes and pituitary adenoma 31

3.4.3.1. Multiple endocrine neoplasia type 2 31

3.4.3.2. Von Hippel-Lindau disease 37

3.4.3.3. Neurofibromatosis type 1 37

3.4.3.4. Familial paraganglioma syndrome 37

4. Objectives 39

5. Methods 40

5.1. Patients 40

5.2. Postsurgical evaluation (study I) 41

5.3. Nucleic acid extraction and quantification 41

5.3.1. DNA extraction 42

5.3.2. RNA extraction 42

5.3.3. Determination of nucleic acid concentration and purity 42

5.4. Genetic screening 43

5.4.1. *AIP* mutation analysis in somatotropinomas (study I) 43

5.4.2. Mutation testing for pheochromocytoma/paraganglioma or pituitary adenoma causing genes in study II 43

5.4.3. Loss of heterozygosity analysis (study II) 44

5.5. Immunohistochemistry 44

5.5.1. Cytokeratin pattern analysis (study I) 44

5.5.2. AIP protein expression analysis in somatotropinomas (study I) 45

5.5.3. Immunohistochemistry of pheochromocytomas/paragangliomas and pituitary adenomas in study II 45

5.6. Electron microscopy (study II) 46

5.7. Reverse Transcription and Real-Time PCR (RT-qPCR) 46

5.7.1. AIP mRNA expression analysis in somatotropinomas (study I) 48

5.7.2. Quantification of miRNAs identified by *in silico* target prediction (study I) 49

5.7.3. Endogenous miR-34a expression in different cell lines and tissues 50

5.7.4. Endogenous AIP mRNA expression after miR-34a overexpression and inhibition 50

5.8. Identification of miRNAs targeting *AIP* 3'-untranslated region (3'-UTR) in somatotropinomas (study I) 51

5.9. Cell culture (study I) 51

5.9.1. Transient transfection of cells 52

5.9.2. miRNA overexpression and inhibition 52

5.10. Luciferase gene reporter assay 52

5.11. Construction of 3'-Untranslated Region Reporter Plasmid 53

5.11.1. Generation of mutant *AIP*-3'-UTR Reporter Plasmids 53

5.11.2. Transformation of competent bacterial cells with plasmid DNA 54

5.11.3. Small-scale plasmid DNA purification (miniprep) 54

5.11.4. Large-scale plasmid DNA purification (maxiprep) 55

5.12. Protein extraction and quantification 55

5.12.1. Western Blot (study I) 55

5.13. Cell proliferation assay (study I) 56

5.14. Wound healing assay (Study I) 57

5.15. Colony formation assay (study I) 57

5.16. Statistical analysis 57

6. Results 59

6.1. Study I 59

6.1.1. Analysis of *AIP* mutations 59

6.1.2. Demographic, radiological, biochemical and pathological data of the patients with acromegaly 59

6.1.3. AIP protein levels and correlation with *AIP* mRNA levels 61

6.1.4. miRNA expression levels in patients with low or high AIP protein expression 62

6.1.5. Correlation of AIP expression, miR-22 and miR-34a levels with tumor invasiveness, granulation pattern and response to somatostatin analogues 63

6.1.6. miR-34a and miR-22 predicted binding sites in the human *AIP*-3'UTR . 64

6.1.7. miR-34a effect on regulation of AIP expression *in vitro* 65

6.1.8. Confirmation of predicted miR-34a binding sites 67

6.1.9. Regulation of endogenous AIP expression by miR-34a *in vitro* 68

6.1.10. The effect of miR-34a on cell proliferation and colony formation 70

6.2. Study II 72

6.2.1. Clinical data 72

6.2.2. Genetic screening 79

6.2.2.1. *SDHX* mutation 80

6.2.2.2. *VHL* mutation 84

6.2.2.3. *MEN1* mutation 85

6.2.2.4. Control patients 86

6.2.3. Pathological features 88

7. Discussion 90

7.1. Study I 90

7.2. Study II 93

8. Conclusion 98

8.1. Study I 98

8.2. Study II 98

9. Summary 99

10. Összefoglalás 100

11. Bibliography 101

12. Bibliography of the candidate's publications 127

13. Acknowledgements 129

2. List of abbreviations

3'-UTR: 3' untranslated region

5'-UTR: 5' untranslated region

ACTH: adrenocorticotropin

AIP: aryl hydrocarbon receptor-interacting protein

BMI1: polycomb ring finger oncogene 1

BSA: bovine serum albumin

cAMP: cyclic adenosine monophosphate

CCNA2: cyclin A2

CDK: cyclin dependent kinase

CDKI: cyclin dependent kinase inhibitor

cDNA: complementary DNA

CNC: Carney complex

CRH: corticotropin releasing hormone

Ct: cycle threshold

DA: dopamine agonist

DMEM: Dulbecco's modified Eagle's medium

DNA: deoxyribonucleic acid

DPAS: diastase-resistant periodic acid of Schiff

E2F1: E2 transcription factor 1

ER: endoplasmic reticulum

FMTC: familial medullary thyroid carcinoma

FGF: fibroblast growth factor

FGFR: fibroblast growth factor receptor

FH: fumarate hydratase

FIPA: familial isolated pituitary adenoma

FSH: follicle-stimulating hormone

GAPDH: glyceraldehydes-3-phosphate dehydrogenase

gDNA: genomic DNA

GH: growth hormone

GHRH: growth hormone releasing hormone

GUSB: glucuronidase β

HIF: hypoxia inducible factor

HMGA: high-mobility group A

HNPGL: head and neck paraganglioma

HPT: hyperparathyroidism

IGF: insulin-like growth factor

LH: luteinizing hormone

LOH: loss of heterozigosity

MAX: MYC-associated factor X

mpx: multiplex

MTC: medullary thyroid carcinoma

MTS:3-(4,5-dimethylthiazol-2-yl)-5-(3-carboxymethoxyphenyl)-2-(4-sulfophenyl)-2H-tetrazolium

MEN1: multiple endocrine neoplasia type 1

MEN2: multiple endocrine neoplasia type 2

MEN4: multiple endocrine neoplasia type 4

miRNA: microRNA

MLPA: multiplex ligation-dependent probe amplification

mRNA: messenger RNA

NF1: neurofibromatosis type 1

NFPA: non-functioning pituitary adenoma

NP: normal pituitary

nt: nucleotide

OCT-LAR: long-acting octreotide

OGTT: oral glucose tolerance test

PaCS: particle-rich cytoplasmic structures

PAS: periodic acid of Schiff

PCR: polymerase chain reaction

PGK1: phosphoglycerate kinase 1

PGL: paraganglioma

PHD: prolyl hydroxylase

pheo: pheochromocytoma

PKA: protein kinase A

ptd-FGFR4: pituitary tumor-derived FGFR4

PPNAD: primary pigmented nodular adrenocortical disease

pri-miRNA: primary microRNA

PRKAR1A: protein kinase type 1A regulatory subunit

PRL: prolactin

PTEN: phosphatase and tensing homology

PTTG: pituitary tumor transforming gene

RARS: arginyl-tRNA synthetase

RB1: retinoblastoma

RET: 'rearranged during transfection' tyrosine kinase receptor gene

RISC: RNA induced silencing complex

RNA: ribonucleic acid

SDH: succinate dehydrogenase

SDHA: succinate dehydrogenase subunit A

SDHAF2: succinate dehydrogenase complex assembly factor 2

SDHB: succinate dehydrogenase subunit B

SDHC: succinate dehydrogenase subunit C

SDHD: succinate dehydrogenase subunit D

SSAs: somatostatin analogues

TBP: TATA box binding protein

TGF: transforming growth factor

TMEM127: transmembrane protein 127

TSH: thyrotropin-stimulating hormone

uORF: upstream open reading frame

VHL: von Hippel-Lindau

WT: wild type

X-LAG: X-linked acrogigantism

3. Introduction

3.1. Pituitary tumors

Pituitary adenomas are common intracranial neoplasms, which arise from the adenohypophysial cells. Their overall estimated prevalence is 16.7% (14.4% in autopsy studies and 22.5% in radiologic studies) (1). According to recent population based studies their prevalence ranges between 1:1064 and 1:1470 (2-4), much higher than previously thought. Although they are benign tumors, they can lead to increased mortality because of the hormone overproduction and compression or local invasion of surrounding structures.

Pituitary adenomas can be classified according to their size as micro- (<10 mm) or macroadenomas (>10 mm). Microadenomas are usually located in the sella turcica, and do not have significant compressive effects. Macroadenomas can cause compression on the optic chiasm and the pituitary stalk, as well as invading surrounding tissues, such as the cavernous sinus, the sphenoid sinus or the suprasellar area (5).

According to the functional classification various functioning adenomas and the clinically non-functioning pituitary adenomas (NFPA) can be distinguished. Prolactin (PRL)-producing adenomas are the most common type, associated with hyperprolactinemia. One-third are not associated with hypersecretory syndromes; however, many of these produce but do not secrete follicle-stimulating hormone (FSH) and/or luteinizing hormone (LH). Growth hormone (GH)-producing adenomas are 10-15% of pituitary adenomas, associated with acromegaly or gigantism. Adrenocorticotropin (ACTH)-producing adenomas account for 10 to 15%, and they can be associated with Cushing disease. Thyrotropin-stimulating hormone (TSH)-secreting adenomas, associated with thyroid dysfunction, are rare, accounting for less than 1% of all pituitary adenomas (6).

Pituitary tumors very rarely progress to carcinomas, of which criteria is the distant metastasis (6).

3.2. Pituitary tumorigenesis

Several etiologic factors, such as genetic events, epigenetic changes, hormonal stimulation, growth factors and environmental factors have been reported to initiate transformation and promote pituitary tumor cell proliferation (5, 6) (Figure 1).

The key mechanisms in pituitary tumorigenesis have been suggested to be the activation of oncogenes and inactivation of tumor suppressor genes. The common mutations in major carcinoma related genes, such as *p53, Rb, Ras* are usually absent in pituitary adenomas (7). The majority of pituitary adenomas occur sporadically, but familial cases are now increasingly recognised. For the genetic background of hereditary pituitary tumors see Section 3.4.2.

In the pathogenesis of sporadic pituitary adenomas numerous genes have been suggested to be involved (5, 8) (see Table 1). One of the most important genes is *GNAS*, which is coding the alpha subunit of G protein. Its mutation can be present in up to 40% of GH-secreting pituitary adenomas and might cause continuous activation of adenyl cyclase, resulting in increased cyclic adenosine monophosphate (cAMP) levels and protein kinase A (PKA) activation, and thus sustained GH hypersecretion and cell proliferation (5, 9).

Mosaic *GNAS* mutations lead to McCune-Albright syndrome, a disease causing endocrine hyperfunction and tumors in several organs, including the pituitary.

The oncogenic pituitary tumor transforming gene (*PTTG*) overexpression has been detected in many forms of pituitary adenomas, and its expression correlates positively with tumor invasiveness (10, 11).

Promoter methylation is an epigenetic mechanism that occurs in pituitary tumorigenesis. The genes *CDKN2A*, *MEG3A*, *Rb*, *FGFR2* and *GADD45γ* have been shown to be downregulated due to promoter hypermethylation (6, 12).

Several other alterations have been suggested to be involved in pituitary tumorigenesis, such as abnormal microRNA (miRNA) expression (see section 3.3.).

DOI:10.14753/SE.2015.2110

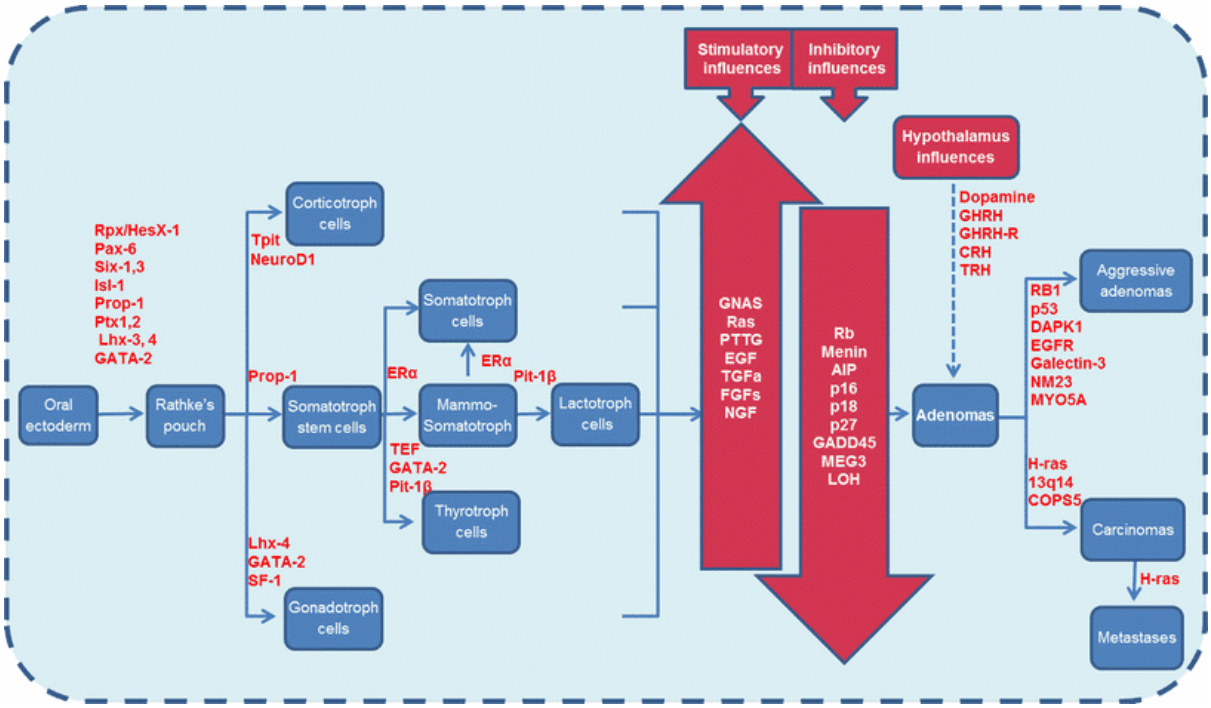

Figure 1. An overview of pituitary development and intracellular tumor cell signalling associated with cell proliferation and tumor development. Adapted from Aflorei et al. 2014 (5).

Table 1. Selected genes that may be involved in molecular pathogenesis of pituitary adenomas. Adapted from Aflorei et al. 2014 (5).

Gene	Mechanism of normal function	Result of altered function	Oncogene/ TSG
Somatotroph adenoma			
CCND1	Involved in progression through the G1-S phase of the cell cycle	Increased expression, can stimulate both cell proliferation and apoptosis in GH_3 cells	Oncogene
CREB	Phosphorylation-dependent transcriptional activator of cAMP response elements (CREs)	Constitutive activation by phosphorylation	Oncogene
GHR	Transmembrane receptor that mediates GH action	Loss-of-function somatic mutation	-
GHRH	Stimulates growth hormone secretion	Increased expression	-

Table 1. Selected genes that may be involved in molecular pathogenesis of pituitary adenomas. Adapted from Aflorei et al. 2014 (5) - cont.

Gene	Mechanism of normal function	Result of altered function	Oncogene/ TSG
GHRH-R	Transmembrane receptor that mediates GHRH action	Truncated alternatively spliced nonfunctioning receptor	-
GNAS1	Alpha subunit of the stimulatory G protein that activates adenylate cyclase	Predominant maternal origin of GNAS1 transcripts; 40% of GH-secreting pituitary adenomas have somatic mutations	Oncogene
SSTR2	Specific high-affinity G-coupled receptor for somatostatin	Decreased expression	-
Lactotroph adenoma			
BMP4	Involved in the control of the differentiation and proliferation of the different cell types in the anterior pituitary	Overexpressed in prolactinomas	TSG
DRD2	G protein-coupled receptor for dopamine	Decreased expression	-
FGF4	Membrane-anchored receptor for fibroblast growth factor	Increased expression of a N-terminally truncated cytoplasmic isoform (ptd-FGFR4) by alternative transcription initiation	Oncogene
TGF-alfa	Competes with EGF for binding to the EGF receptor and stimulates its phosphorylation in order to produce a mitogenic response	Overexpressed under the prolactin promoter influence	Oncogene
Corticotroph adenoma			
CCNE1	Promotes progression through the G1-S phase of the cell cycle	Increased expression	Oncogene
HDAC2	Enzyme that deacetylates lysine residues on the N-terminal region of the core histones	Decreased expression	Oncogene
NR3C1	Nuclear receptor for glucocorticoids	Loss-of-function somatic mutation	-

Table 1. Selected genes that may be involved in molecular pathogenesis of pituitary adenomas. Adapted from Aflorei et al. 2014 (5) - cont.

Gene	Mechanism of normal function	Result of altered function	Oncogene/ TSG
SmarcA4	Member of the SWI/SNF protein family with helicase and ATPase activities. Regulates gene transcription by altering chromatin structure	Decreased expression, altered subcellular localization	TSG
Nonfunctioning adenoma			
DKC1	Pseudouridine synthase that modifies rRNA and regulates telomerase activity	Loss-of-function somatic mutation	TSG
MEG3	Induces apoptosis and inhibits proliferation of tumour cells	Decreased expression	TSG
PITX2	Member of the bicoid-like homeobox transcription factor family, which is involved in the Wnt/Dvl/β-catenin pathway	Increased expression	-
PLAG-l1	Zinc finger transcription factor that plays a role in pituitary development, differentiation, maturation and tumorigenesis	Decreased expression	TSG
PRKCA	Kinase that participates in growth factor- and hormone-mediated transmembrane signaling and cell proliferation	Increased expression, gain-of-function mutation	Oncogene
Most or all pituitary tumour types			
AKT1	Regulates many processes including metabolism, proliferation, cell survival, growth and angiogenesis	Increased expression, especially in NFPAs	Oncogene
AKT2	Regulates many processes including metabolism, proliferation, cell survival, growth and angiogenesis	Increased expression, especially in NFPAs	Oncogene
BAG1	Inhibits the chaperone activity of HSP70/HSC70 and the pro-apoptotic function of PPP1R15A	Increased expression	-
CCNA1, B1, B2	Involved in the control of the G2/M phases of the cell cycle	Increased expression	Oncogene

Table 1. Selected genes that may be involved in molecular pathogenesis of pituitary adenomas. Adapted from Aflorei et al. 2014 (5) - cont.

Gene	Mechanism of normal function	Result of altered function	Oncogene/ TSG
CDKN1A – p21	Regulator of cell cycle progression at G1	Decreased expression in NFPAs, Increased expression in hormone producing adenomas	TSG
CDKN2A	Induces cell cycle arrest in G1 and G2 phases	Decreased expression	TSG
PIT1	Member of the POU transcription factor family; plays a key role in the specification, expansion and survival of somatothrops, lactotrophs and thyrotropes during development	Overexpressed in GH, PRL and TSH pituitary adenomas	Oncogene
POUF1	Transcription factor with a key role in specification, expansion and survival of different pituitary cell types during anterior pituitary development	Increased expression	-
PTTG	Cell cycle regulation and cell senescence	Increased expression, especially in corticotrophinomas	Oncogene
Invasive adenoma			
DAPK1	Positive mediator of programmed cell death induced by gamma-interferon	Decreased expression either by promoter methylation or by homozygous deletion of the promoter CpG island	TSG
EGFR	Transmembrane glycoprotein required for normal cellular proliferation, adhesion, migration and differentiation	Increased expression	Oncogene
Galectin-3	Extracellular Gal-3 mediates cell migration, cell adhesion, and cell-to-cell interactions; intracellular Gal-3 inhibits apoptosis	Up-regulated during neoplastic progression	Oncogene

Table 1. Selected genes that may be involved in molecular pathogenesis of pituitary adenomas. Adapted from Aflorei et al. 2014 (5) - cont.

Gene	Mechanism of normal function	Result of altered function	Oncogene/ TSG
MYO5A	Actin-dependent molecular motor, with roles in tumour cell migration, invasion, and metastasis	Increased expression	-
NM23	N-terminal kinase domain could phosphorylate and downregulate cyclin B and could prevent the progression of cell from G2 to M phase of the cell cycle	Allelic loss results in reduced NM23 expression	TSG
RB1	Key regulator of entry into cell division	Decreased expression partly by promoter methylation	TSG
Pituitary carcinoma			
COPS5	Probable protease subunit of the COP9 signalosome complex, which is involved in various cellular and developmental processes	Increased expression	-
HRAS	GDP/GTP binding protein that regulates cell division in response to growth factor stimulation	Gain-of-function somatic mutations	Oncogene

3.2.1. Cell cycle dysregulation

Cyclin dependent kinases (CDKs) control the progression of cells through the different phases of the cell cycle. CDK activity is modulated by their activators (cyclins) or inhibitors (CDKIs). A higher *CCDN1* expression, which encodes cyclin D1, was found in NFPAs and invasive adenomas, including prolactinomas, while cyclin E expression is higher in macroprolactinomas compared to microprolactinomas (5, 7).

CDKIs are divided in two families, the INK4 family ($p16^{INK4a}$, $p15^{INK4b}$, $p18^{INK4c}$ and $p19^{INK4d}$) and the Cip/Kip family ($p21^{Cip1}$, $p27^{Kip1}$ and $p57^{Kip2}$). p16 plays a crucial role in cell cycle control, and its lost or diminished expression by promoter methylation is suggested to play a role in pituitary tumorigenesis. In $p18^{INK4c}$ -null mice pituitary intermediate lobe hyperplasia develops, which then progress to adenoma (13). Regarding p27 see section 3.4.2.2.

3.2.2. Growth factors

Growth factors and their receptors have an important role in pituitary cell growth and hormone production. Fibroblast growth factors (FGF) and their receptors (FGFR) are involved in pituitary development and growth. Pituitary adenomas have altered FGFR subtype expression (14). FGFR2-IIIb is downregulated in pituitary tumors by promoter methylation (6). Expression of the transmembrane and kinase domains of FGFR4 was found uniquely in pituitary tumors (14). In human pituitary tumors, a novel N-terminally truncated isoform of FGFR4, the pituitary tumor-derived FGFR (ptd-FGFR4) has been described. This isoform might have a role in pituitary adenoma formation, as shown *in vitro* and in animal models (15).

It has been suggested that a single nucleotide germline polymorphism (SNP) G388R in the FGFR4 transmembrane domain can alter pituitary cell growth and hormone production.

In acromegalic patients the pituitary tumor size correlated with hormone excess in the presence of the FGFR4-R388 allele (16). In *AIP*-related pituitary adenomas the FGFR4 G388R variant does not influence the penetrance or clinical features (17).

Transforming growth factor-alpha (TGFα) overexpression stimulates the growth of lactotroph cells. It has been suggested that TGFα might play a role in the development of prolactinomas (18).

3.2.3. Transcriptional regulators

Transcription factors have an important role in pituitary cell differentiation, and their altered expression has been shown in pituitary tumors.

Although Pit1 was found to be overexpressed in PRL- and GH-secreting tumors, the cell type distribution, size and sequence of *Pit1* transcripts appeared intact (5, 19). The high mobility group A (HMGA) protein family members also seem to have a role in pituitary tumorigenesis. Overexpression of HMGA2 has been detected in pituitary adenomas and HMGA1B and HMGA2 overexpression in mice induces the development of GH- and PRL-secreting pituitary adenomas. Moreover HMGA1B and HMGA2 directly interact with Pit1 and its gene promoter *in vivo*, and they positively

regulate *Pit1* promoter activity. It seems that Pit1 upregulation by HMGA proteins might have a role in pituitary tumors (20).

Pituitary transcription factor Ptx-1 (pituitary homebox 1) expression level has been found reduced in corticotroph adenomas (21).

3.3. Pituitary adenomas and microRNAs (study I)

3.3.1. MicroRNAs – Definition, biosynthesis and binding to target mRNAs

miRNAs are small [approximately 19-25 nucleotides (nt)] non-coding RNA molecules involved in the post-transcriptional regulation of gene expression. They constitute a major class of molecular regulators, regulating about 60% of human genes (22-24). They were first described in the nematode *Caenorhabditis elegans* in 1993 (25), with let-7 being the first miRNA described in the human species in 2000 (26). miRNAs are found in the genome of animals, plants and protozoa (27). Since the first report, more than 1500 human miRNAs have been described (28). miRNA sequences are dispersed throughout the genome and are classified as intergenic (between genes) or intronic (embedded within a gene) (29). Intergenic miRNAs are expressed via their own promoter, while intronic miRNAs can be expressed either via the host gene promoter transcribed by the RNA Polymerase II enzyme or via their own promoter transcribed by RNA Polymerase III (29).

The first step in miRNAs biosynthesis is transcription of the miRNA sequence by RNA polymerase II or III to produce a long miRNA precursor called primary miRNA (pri-miRNA) (Figure 2). The pri-miRNA may contain either a single or a cluster of distinct miRNAs and may be from approximately 200 nt to several thousand nt in length. pri-miRNA has a characteristic stem-loop structure (Figure 2). The stem-loop structure is recognized and cleaved by a heterodimer consisting of the cellular RNase III enzyme Drosha and a cofactor called double-stranded RNA binding protein Pasha (also known as DGCR8), which is essential for Drosha activity. This cleavage liberates an approximately 60 nt hairpin looped-structured RNA, called pre-miRNA. All these described steps occur in the nucleus. The next step is nuclear export of the pre-miRNA by exportin 5 (30). After reaching the cytoplasm, the pre-miRNA binds to a second

cellular RNase III enzyme called Dicer. Dicer binds the overhang at the base of the pre-miRNA hairpin and removes the terminal loop, generating a 19-25 nt duplex miRNA intermediate (miRNA – miRNA duplex). This duplex miRNA is incorporated into a complex called RNA-induced silencing complex (RISC). The RISC composition is not completely known, but a key component is an argonaute protein. Then, one strand is retained and becomes the mature miRNA, while and the other strand, called miRNA*, is discarded (23).

Usually, the miRNA binds to a region located in the 3' untranslated region (3'UTR) of the target messenger RNA (mRNA). When a miRNA binds to perfectly complementary base pairs in the mRNA strand, degradation of the mRNA by RISC occurs (23). However, more commonly, a miRNA binds to a partially complementary mRNA sequence and this induces translational repression of the target mRNA or the recently discovered miRNA-mediated mRNA deadenylation (Figure 2) (23, 31). In a few cases, an interaction between a miRNA and its target mRNA has been shown in the open reading frame of the mRNA (32, 33).

Generally, miRNA:mRNA duplexes consist of a 5' end "seed" region, a central loop region, and a 3' end tail region. The major determinant of the interaction between a miRNA and its mRNA targets corresponds to the "seed" region of the miRNA (from 6 to 8 nt at position 1-8 at its 5' end), which pairs with mRNA complementary sequences (34). The binding at the "seed" region can be canonical, when there is 7-8 nt match, or non-canonical when matching is less perfect (34). The central loop has also been shown to be another important factor in miRNA functioning (35), and supplementary base pairing involving the 3' portion of the miRNA can enhance binding specificity and affinity (34). Moreover, the secondary structure, as well as the whole 3'UTR sequence, may contribute to miRNA function (36-38). In addition, the presence of RNA-binding proteins in the 3'UTR could physically prevent the interaction of miRNAs with nearby target site (39).

DOI:10.14753/SE.2015.2110

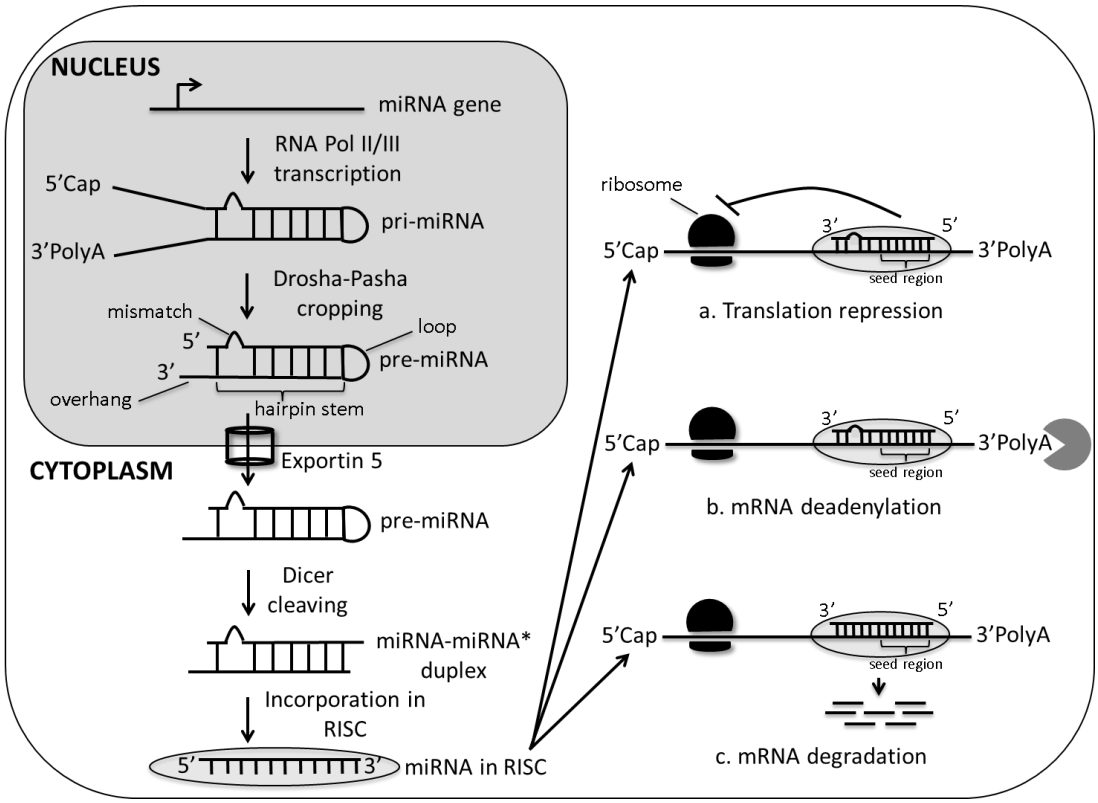

Figure 2. The summary of the steps of miRNAs biogenesis. Adapted from Gadelha et al. 2013 (40).

3.3.2. MicroRNAs and pituitary adenomas

miRNAs have been implicated in many cellular processes, including cell proliferation, apoptosis, cell adhesion and metabolism, and have a role in many developmental processes, including stem cell and germline maintenance, development and differentiation (28). Thus, alterations in miRNA expression can potentially be involved in the development of human neoplasias. miRNAs can act either as activators or inhibitors of carcinogenesis, and are called oncomiRs or tumor suppressor miRNAs accordingly (26). As in other human neoplasias, there is an increasing interest in the study of miRNAs in pituitary adenomas and carcinomas. miRNAs have been described to be associated with tumor type, characteristics (size, invasion) and response to therapy (Table 2) (41-46). They have also been involved in the regulation of several genes suggested to be associated with the pathogenesis of pituitary adenomas (Table 3).

Table 2. Studies correlating microRNAs expression in pituitary adenomas with clinical and therapeutic characteristics. Updated from Gadelha et al. 2013 (40).

Study	**Tumor type**	**Aberrant microRNAs expression**	**Clinical correlation**
Bottoni et al. 2005 (42)	10 GH- and 10 PRL-secreting	Underexpression of miR-15a and miR-16-1 in adenomas vs NP	Inverse correlation with tumor size
Bottoni et al. 2007 (43)	17 NFPA, 5 PRL-, 4 ACTH- and 6 GH-secreting	30 miRNAs differently expressed between adenomas and NP. 29 miRNAs predict tumor type	6 miRNAs correlated with tumor size in NFPA. 3 miRNAs up- and 3 down-regulated in NFPA treated with DA in comparison with non-treated ones
Amaral et al. 2009 (45)	14 ACTH-secreting	Underexpression of miR-145, miR-21, miR-141, miR-150, miR-15a, miR-16, miR-143 and let-7a in adenomas vs NP	miR-141 levels directly correlated with chance of disease recurrence
Mao et al. 2010 (44)	21 GH-secreting	23 over- and 29 under-expressed in GH-secreting vs NP	9 miRNAs differently expressed in micro vs macroadenomas 13 differently expressed in lanreotide treated vs surgery alone 7 differently expressed in lanreotide responders vs non responders
Butz et al. 2011 (46)	8 NFPA	70 over- and 92 under-expressed in NFPA vs NP	18 miRNAs inversely correlated with tumor size
Cheunsuchon et al. 2011 (47)	25 NFPA	2 over- and 13 under-expressed in NFPA vs NP	miR-134 directly correlates with age at diagnosis and miR-337 directly correlates with Ki-67 labeling index
Wang et al. 2012 (41)	6 PRL-secreting	-	80 over- and 71 under-expressed in PRL-secreting treated with bromocriptine compared to untreated PRL-secreting
Chen et al. 2012 (48)	PRL-secreting	6 over- and 4 under-expressed in PRL-secreting vs NP	miR-493(*) and miR-432 had positive correlation with the serum level of prolactin, miR-342-3p correlates with the invasiveness

Table 3. Studies addressing genes regulated by microRNAs in pituitary adenomas. Updated from Gadelha et al. 2013 (40).

Study	**Tumor type**	**Aberrant microRNAs expression**	**Affected gene(s)**
Bottoni et al. 2005(42)	10 GH- and 10 PRL-secreting	Underexpression of miR-15a and miR-16-1 in adenomas vs NP	*RARS*
Qian et al. 2009 (49)	98 adenomas of all types	Let-7 overexpression in adenomas with low HMGA2 expression	*HMGA2*
Butz et al. 2010* (50)	27 NFPA and 15 GH-secreting	miR-20a, miR-128a and miR-516-3p overexpressed in NFPA. miR-93 and miR-155 overexpressed in GH and NFPA vs NP	*Wee1*
Trivellin et al. 2012* (51)	14 GH-, 4 GH&PRL-secreting and 21 NFPA	miR-107 overexpressed in adenomas vs NP	*AIP*
Palmieri et al. 2012*(20)	14 PRL-, 9 GH-secreting and 18 NFPA	miR-15, miR-16, miR26a, miR-196a2 and Let-7a underexpressed in adenomas vs NP	*HMGA1* and *HMGA2*
Butz et al. 2011(46)	NFPA	miR-140-5p overexpressed	*Smad3(52)*
D'Ángelo et al. 2012* (53)	18 GH-secreting	miR34b, miR-326, miR-374b, miR-432, miR-548c-3p, miR-570, miR-603 and miR-633 under-expressed and miR-320 over-expressed in adenomas vs NP	*HMGA1* ,*HMGA2* and *E2F1*
Palumbo et al. 2012*(54)	12 GH-secreting	5 over- and 12 under-expressed in GH vs NP	*PTEN* and *BMI1*
Gentilin et al. 2013(55)	ACTH and mouse ACTH-secreting cell line	miR-212 in ACTH vs normal tissue. miR-24 and miR-189 downregulated and miR-26a as overexpressed in both human and mouse pituitary adenomas vs normal tissue	*PRKCD*
Leone et al., 2014* (56)	15 GH-secreting, 21 NFPA	miR-23b and miR-130b underexpressed in GH and NFPA vs NP	*HMGA2, CCNA2*

* studies were functional validation was done

3.4. Pituitary adenomas and pheochromocytomas/paragangliomas (study II)

Although both pituitary adenomas and pheochromocytomas/paragangliomas (pheo/PGL) are relatively rare diseases, they can sometimes occur in the same patient or in the same family. Coexistence of the two diseases could be due to pure coincidence, but it is possible that in some cases the two conditions share a common pathogenic mechanism. Since the first description of a patient with acromegaly and pheochromocytoma in 1952 (57), 70 cases have been published with this rare disease combination (Table 4). The simultaneous occurrence of these two tumor types might be explained by: (i) a pheo/PGL-related gene mutation which, in addition to the pheo/PGL, also causes pituitary adenoma – as suggested for *SDHX* mutation being involved in pituitary adenoma formation (58-60); (ii) a mutation in a familial pituitary adenoma gene which also causes pheo/PGL; (iii) a digenic disease i.e. two gene abnormalities are present in the same patient or family causing the two diseases; (iv) a single, possibly novel, gene causing both diseases; (v) ectopic hypothalamic hormone-secreting adrenal tumors causing pituitary enlargement mimicking pituitary adenoma, or (vi) the development of a pituitary adenoma and a pheo/PGL in the same patient or same family due to pure coincidence (Table 5).

Table 4. Summary of pheochromocytoma/paraganglioma and pituitary adenoma cases in the literature

Subgroups of pituitary adenoma + pheo/PGL cases	**Number of the cases**
GHRH secreting pheochromocytoma	4
CRH secreting pheochromocytoma	4
Pituitary adenoma + pheo/PGL	44

Table 4. Summary of pheochromocytoma/paraganglioma and pituitary adenoma cases in the literature – cont.

Subgroups of pituitary adenoma + pheo/PGL cases	**Number of the cases**
Pheo/PGL + pituitary adenoma in the family (not in the same individual)	4
Hereditary pheo syndrome (without pheo/PGL) + pituitary adenoma	9
Hereditary pituitary syndrome (without pituitary disease in patient) + pheo/PGL	4
Digenic (?)	1
TOGETHER	70

Table 5. Pheochromocytoma/paraganglioma and pituitary adenoma – other cases

Article	**Case**
Iversen K., Acta Med Scand, 1952 (57)	Acromegaly+pheo
Kahn MT et al., JAMA, 1964 (61)	Acromegaly+pheo
German WJ et al., Clin Neurosurg, 1964 (62, 63)	Acromegaly+pheo
O'Higgins NJ et al., Ir Med J, 1967 (64)	Acromegaly+pheo
Miller GL et al., Arch Intern Med, 1971 (65)	Acromegaly+pheo+toxic goiter

Table 5. Pheochromocytoma/paraganglioma and pituitary adenoma – other cases – cont.

Article	**Case**
Kadowaki S et al., Saishin-Igaku, 1976 (63)	Acromegaly+pheo
Melicow MM et al., Cancer, 1977 (66)	Pituitary adenoma (chromophobe) +pheo+papillary thyroid carcinoma
Janson KL et al., J Urol, 1978 (67, 68)	Pituitary adenoma+pheo
Anderson RJ et al., Clin Endocrinol, 1981 (69)	Acromegaly+pheo
Meyers DH et al., Med J Aust, 1982 (70)	PRLoma+pheo
Blumenkopf B et al., J Neurosurg, 1982 (71)	NFPA+PGL
Baughan J et al., Am J Surg, 2001 (72)	Acromegaly+pheo+liver hemangioma, parotid adenoma, skin lipomas
Dunser MW et al., Acta Anaesthesiol Scand, 2002 (73)	Pituitary adenoma+pheo
Breckenridge SM et al., Pituitary, 2003 (63)	Pituitary adenoma (LH,FSH,ACTH pos)+pheo
Yaylali GF et al., Clin Invest Med, 2008 (74)	Pituitary adenoma+ pheo+ adrenal cortical hyperplasia
Sisson JC et al., Thyroid, 2012 (75)	Acromegaly+pheo (bilateral) + papillary thyroid carcinoma
Filipponi S. et al., IWMEN (MEN workshop) 2012, P48 (76)	PRLoma+pheo
Parghane RV et al., Clin Nucl Med, 2014 (77)	PRLoma+mpx PGL

3.4.1. Pheochromocytoma secreting hypothalamic or pituitary hormones causing acromegaly or Cushing syndrome

The main cause of acromegaly is a GH-producing pituitary tumor, but rarely it can be caused by an eutopic or ectopic growth hormone releasing hormone (GHRH)- secreting tumor or very rarely by an ectopic GH-secreting tumor (78). Ectopic GHRH-secreting tumors are usually neuroendocrine tumors, such as pancreatic islet cell carcinoids, pheochromocytoma or small cell lung carcinoma (79-82).

In the latter cases the pituitary gland usually shows somatotrop hyperplasia, but adenoma-like transformation has also been described (83). The diagnosis of acromegaly caused by an ectopic GHRH source is suggested, when the plasma GHRH level is elevated, when GH and insulin-like growth factor (IGF)-I levels normalize after the resection of the GHRH-secreting tumor, and the tumor tissue is stained positively for GHRH (80).

A case report by Roth et al. of a patient with acromegaly and pheochromocytoma describes elevated GHRH levels and GHRH-positive immunostaining of the pheochromocytoma post mortem (84). Sano et al. examined immunohistochemically the GHRH production of 13 pheochromocytomas and measured the plasma GHRH levels. Two of the 13 cases showed GHRH-immunoreactivity, but the plasma GH levels of these patients were within the normal range suggesting that the plasma GHRH levels were under the threshold level to have biological effect on the pituitary gland (85). Recently in a case report by Vieira Neto et al. reported an acromegalic patient with an incidentally found pheochromocytoma, which stained positively for GHRH, and the acromegaly was cured after the removal of the adrenal tumor (80).

There are two cases with pheo/PGL and acromegaly, when acromegaly was clearly diagnosed concurrently with the pheo/PGL (64, 86). As these cases have been published before 1980, when the GHRH has been identified (87), the role of GHRH cannot be clearly proved.

Pheochromocytomas are known to be able to secrete other pituitary or hypothalamic hormones such as ACTH and corticotropin releasing hormone (CRH) and therefore causing ectopic Cushing syndrome. There are 9 cases in the literature about ACTH-producing pheochromocytomas (88-92), and 4 cases where the pheochromocytoma produces CRH, thus causing pituitary hyperfunction (91, 93-95) (Table 6).

Table 6. Growth hormone releasing hormone (GHRH) or corticotropin releasing hormone (CRH) secreted from the pheochromocytoma/paraganglioma causing acromegaly or Cushing syndrome in the literature

Article	**Case**
Sano T et al., NEJM, 1984 (96)	2/13 GHRH secreting phaeo, GH norm., no acromegaly
Roth KA et al., JCEM, 1986 (84)	GHRH secreting pheo, acromegaly
Vieira Neto L et al., Endocr Pathol, 2007 (80)	GHRH secreting pheo, acromegaly
O'Brien et al., Clin Endocrinol, 1992 (91)	ACTH+CRH secreting pheo
Eng PH et al., Endocr Pract, 1999 (95)	CRH secreting pheo
Bayraktar F et al., Exp Clin Endocrinol Diabetes, 2006 (94)	CRH secreting pheo
Ruggeri RM et al., Eur J Histochem, 2009 (93)	CRH secreting pheo

3.4.2. Pituitary adenoma causing genes and pheochromocytoma/paraganglioma

Pituitary tumors can occur in a familial setting within the multiple endocrine neoplasia type 1 (MEN1), multiple endocrine neoplasia type 4 (MEN4), familial isolated pituitary adenoma (FIPA) syndrome, and in Carney complex.

3.4.2.1. Multiple endocrine neoplasia type 1

MEN1 is an autosomal dominantly inherited disease, characterized by tumors of the parathyroids, pancreatic islet cells and anterior pituitary (97). Mutations of the *MEN1* tumor supressor gene are detected in 90-95% of MEN1 patients (98). Adrenal tumors

can also occur in MEN1 syndrome. In one study by Langer et al. in 2002 (99) 26.8% of MEN1 patients with confirmed genetic diagnosis had adrenal lesions. These lesions included nonfunctional bilateral nodular hyperplasia, adrenal Cushing syndrome, adrenocortical carcinoma and rarely (0-3%) pheochromocytoma (100-103).

In the literature, several cases have been published as „overlap" syndrome between MEN1 and MEN2, when the patient developed tumors which are associated with both MEN1 and MEN2. These cases represented pituitary adenomas and pheochromocytomas, pancreatic islet cell tumors and pheochromocytomas or carcinoid tumors with pheochromocytomas, as well as pancreatic islet cell tumor with medullary thyroid carcinoma (104-108).

Nine cases have been published with at least two of the main features of MEN1 syndrome and pheo/PGL (66, 68, 69, 86, 102, 103, 109-111), and 4 more cases with MEN1 phenotype, confirmed MEN1 mutation and a pheo/PGL (99, 112) (Table 7).

Table 7. Pheochromocytoma/paraganglioma and pituitary adenoma and pituitary adenoma-associated genes and related syndromes in the literature

Article	**Case**	**Family history**	**Mutation**
Langer P et al., World J Surg, 2002 (99)	pheo+PRLoma, insulinoma, HPT		*MEN1* (p.Lys119Ter)
Dackiw AP et al., Surgery, 1999 (112)	pheo+pituitary adenoma+pancreatic islet cell tumor+HPT+adrenal cortical adenoma	HPT, pancreatic islet cell tu	*MEN1* (c.320del2)
Dackiw AP et al., Surgery, 1999 (112)	pheo+HPT+pancreatic islet cell tumor+adrenal cortical hyperplasia	pancreatic islet cell tumor+rectal leiomyoma	*MEN1* (c.1325insA)
Jamilloux et al., Eur J Hum Genet, 2014 (113)	PGL+HPT+adrenocortical adenoma+pancreatic endocrine tumor	HPT+ pancreatic endocrine tumor	*MEN1* (p.Arg275Lys)

Table 7. Pheochromocytoma/paraganglioma and pituitary adenoma and pituitary adenoma-associated genes and related syndromes in the literature – cont.

Carty SE et al., Surgery, 1998 (102)	PRLoma+HPT+malignant pheo		
Marx S et al., Ann Intern Med, 1998 (111)	MEN1+ pheo		
Trump D et al., QJM, 1996 (103)	pheo+HPT+gastrinoma+nonfunctioning adrenal tumor		
Alberts WM et al., JAMA, 1980 (68)	pheo+HPT+gastrinoma+PRLoma+cortical adenoma		
Farhi F et al., Arch Pathol Lab Med, 1976 (86)	Acromegaly+mpx PGL+parathyroid hyperplasia		
Manger WM et al., New York:Springer-Velag, 1977 (109)	Acromegaly+pheo +HPT		
Myers JH et al., Arch Intern Med, 1981 (110)	Acromegaly+pheo +parathyroid adenoma		
Anderson RJ et al., Clin Endocrinol, 1981 (69)	Acromegaly+pheo (malignant) +parathyroid hyperplasia		
Melicow MM et al., Cancer, 1977 (66)	pituitary adenoma+ pheo +parathyroid hyperplasia +thyroid hyperplasia		

3.4.2.2. Multiple endocrine neoplasia type 4

Loss-of-function germline changes in *CDKN1B* gene coding for the cyclin-dependent kinase inhibitor $p27^{Kip1}$has been found in patients with an MEN1-like phenotype, now named MEN4 (114).

Recently novel mechanisms of *CDKN1B* loss-of-function were also discovered: a 4 bp deletion in the upstream open reading frame (uORF) within the CDKN1B 5'-UTR led to decreased translation reinitiation and decreased $p27^{Kip1}$ levels (115) and a novel heterozygous deletion was described in CDKN1B 5'-UTR region in an acromegalic patient (116).

Originally identified as MENX (MEN-like syndrome) in rats includes tumors which are typical for both human MEN1 and MEN2, such as bilateral pheochromocytomas, paragangliomas, parathyroid adenomas, multifocal thyroid C cell hyperplasia, endocrine pancreas hyperplasia, and multifocal pituitary adenomas (114). Interestingly this animal model develops both pheo/PGL and pituitary adenoma. No patient with MEN4 has been descibed with pheo/PGL and pituitary adenoma to date.

A study on homozygous p27 mutant MENX rats showed that they develope multiple, bilateral pituitary adenomas (of the pars distalis) at 4 month of age, with 100% penetrance (117). Although the tumors are mitotically active, and the Ki67 index reaches an avarage of 8% at 8 month of age, no invasion of the skull base or metastases from the pituitary tumors were observed. MENX adenomas are similar to human gonadotroph adenomas, but the cells rising to adenomas seem to be immature and not fully differentiated towards the gonadotroph lineage (117).

p27-knockout mice also develop pituitary tumors with 100% penetrance, but these adenomas arise from the melanotrophic cells of the pituitary intermediate lobe (118).

Adrenal medullary hyperplasia develops at 3 months of age and progresses to pheochromocytoma at 6 to 8 months to age in MENX rats. Studying the gene expression profile of p27 mutant and wild type (WT) rat adrenomedullary lesions revealed that the overexpression of certain genes may be specific for p27 loss of function. The overexpressed genes in the adrenal tumors did not show overexpression in the paragangliomas, suggesting that although both tumor types arise from the chromaffin cells, they are the result of distinct molecular alterations in the MENX animal model (119).

3.4.2.3. Familial isolated pituitary adenoma

FIPA occurs if two or more members of a family develop pituitary adenoma with no features of MEN1 or the Carney complex. Germline mutations in the aryl hydrocarbon receptor-interacting protein (AIP) gene have been identified in 20-25% of FIPA families (120), while the causative gene(s) in the rest of the families remain unknown. AIP is widely expressed in the body, but its mutation causes only pituitary tumors. Mutation screening in colorectal cancers, breast cancers, adrenal cancer and prostate tumors suggested that *AIP* mutation does not play a role in their development (121). Among the cases published in the literature with pituitary adenoma and pheo/PGL we could not find any *AIP* positive patient, which would have suggested that *AIP* mutation might be associated with that type of tumor.

The most recently identified genetic pituitary adenoma syndrome is X-linked acrogigantism (X-LAG) (122). It is caused by micro duplications at chromosome Xq26.3 described first in 13 patients with gigantism (4 members of two unrelated kindreds and 9 sporadic cases). These micro duplications span an area of 500 Kb containing 4 genes. Among these genes, only one, *GPR101*, coding for a G-protein-coupled-receptor, has been found to be significantly overexpressed in the pituitary tissue of these patients with infant or young childhood-onset acromegaly.

3.4.2.4. Carney complex

Carney complex (CNC) is a rare, autosomal dominant disease, characterized by cardiac myxomas, pigmentary anomalies, and several endocrine and nonendocrine tumors. The syndrome involves primary pigmented nodular adrenocortical disease (PPNAD), pituitary adenoma (PRL- and GH-producing), testicular tumor, thyroid adenoma or carcinoma, ovarian cysts, schwannomas, breast ductal adenoma and osteochondromyxoma (123). The *CNC1* gene encodes the protein kinase A regulatory subunit 1-α (PRKAR1A), and the majority of CNC cases are caused by inactivating germline mutations in this gene. The *CNC2* gene, located at 2p16, is still unknown. Cytogenetic changes of the 2p16 chromosomal region that harbours the CNC2 locus are frequently observed in tumors from CNC patients (124). Recently gain of function

of catalytic subunit beta of PRKA (PRKACB) was described in a patient with CNC phenotype (125).

To date known adrenal involvement in CNC affects the adrenal cortex (126) and no pheochromocytoma has been described.

3.4.3. Pheochromocytoma/paraganglioma causing genes and pituitary adenoma

Pheochromocytomas are chromaffin-derived tumors that develop in the adrenal medulla. In about 15% of cases tumors arise from the extra-adrenal chromaffin tissue, these tumors are commonly known as paragangliomas (127, 128). Paragangliomas can arise from parasymphatetic-associated tissues (along the cranial nerves and vagus, such as glomus tumors, carotid body tumor) and from symphatetic-associated chromaffin tissues (also so called extra-adrenal pheochromocytomas) (128). The prevalence of clinically-diagnosed pheo/PGL is 1:2500-6667 (129, 130).

Pheo/PGLs can occur sporadically or as a part of different hereditary tumor syndromes, such as MEN type 2, von Hippel-Lindau (VHL) disease, neurofibromatosis type 1 (NF1), familial paraganglioma syndrome and Carney-Stratakis syndrome. Around one third of pheo/PGL patients (most familial cases and 10-20% of the sporadic cases) carry a germline mutation in *RET, VHL, NF1, SDHA, SDHB, SDHC, SDHD, SDHAF2, MAX* or *TMEM127* genes (131, 132). Recently germline mutations in the fumarate hydratase (*FH*) gene have been described in predominantly malignant or multipe pheo/PGL (133) and germline mutation in the prolyl hydroxylase 1 and 2 (*PHD1, PHD2*) genes in pheo/PGL and polycythemia (134). Somatic mutations in *RET, VHL, MAX, NF1, SDHB* and *SDHD* genes have been reported in sporadic pheo/PGL cases (135-137). Somatic mutation in *H-RAS* (138) and *HIF2α* (139) has been also described in association with pheo/PGL.

3.4.3.1. Multiple endocrine neoplasia type 2

MEN2 is characterized by medullary thyroid carcinoma (MTC) (in 100% of the cases), pheochromocytoma (in 50% of the cases), and some additional tumors or features, namely in MEN2A parathyroid neoplasia (in 10-20% of the cases) and in MEN2B

multiple mucosal neuromas and marfanoid habitus. Familial medullary thyroid carcinoma (FMTC) syndrome is a variant of MEN2A, where the patients have only MTC. MEN2 is caused by germline activating mutation of the *RET* protooncogene, which encodes a tyrosine kinase receptor (130, 140).

Pheochromocytoma develop in around 50% of the gene carriers, and derive in most of the cases from the adrenal medulla (130, 140). Although pituitary adenoma is not part of the syndrome, there are some cases reported in the literature with MEN2 and pituitary adenoma. There are 3 cases with MEN2 phenotype and pituitary adenoma (141-143), but the cases have been reported before *RET* mutations have been identified first in 1993 (144). There are 5 cases in the literature with a confirmed *RET* mutation and pituitary adenoma (145-148) (Table 8).

RET was recently found to be an interaction partner with AIP in the pituitary gland (149), and RET was shown to have a role in regulating apoptosis in somatotroph cells (150). These findings lead to hypothesis, that RET might play a role in pituitary tumorigenesis. Neither sporadic GH-secreting pituitary adenomas (149), nor *AIP* mutation negative FIPA families testing (151) showed any relevant change in *RET* gene, which would indicate the pathogenic role of *RET* mutation in pituitary tumorigenesis.

Table 8. Pheochromocytoma/paraganglioma and pituitary adenoma and pheochromocytoma/paraganglioma-associated genes in the literature

Article	**Case**	**Family history**	**Mutation**
Dwight T et al., JCEM, 2013 (60)	PGL	Clinically NFPA with prolactin staining (son)	*SDHA* (c.1873CT, p.His625Tyr)
Majumdar S et al., Pediatr Blood Cancer, 2010 (152)	PGL (metastatic)	Pituitary adenoma (maternal grandmother)	*SDHB* (c.418G>T, p.Val140Phe+ c.200+7A>G)

Table 8. Pheochromocytoma/paraganglioma and pituitary adenoma and pheochromocytoma/paraganglioma-associated genes in the literature – cont.

Article	**Case**	**Family history**	**Mutation**
Benn DE et al., JCEM, 2006 (153)	Pituitary adenoma	pheo	*SDHB* (c.761 insC p.254fsX255)
Xekouki P et al., JCEM, 2012 (154)	Acromegaly PGL (mpx) Pheo (bilateral)	PGL (paternal uncle)	*SDHD* (c.298_301delACTC p.T100fsX133) LOH in the pituitary adenoma
Varsavsky M et al., Endocrinol Nutr, 2013 (155)	Macroprolactinoma PGL (mpx)	PGL (paternal uncle, brother) (paternal aunt-cervical tumor)	*SDHD* (c.242C>T p.Pro81Leu)
Dematti et al., ENSAT Meeting, P29, 2013 (156)	GH-secreting macroadenoma PGL-1 syndrome		*SDHD* (c.341A>G p.Tyr114Cys)
Dematti S et al., ENSAT Meeting, P29, 2013 (156)	NFPA (microadenoma) PGL-1 syndrome		*SDHD* (c.341A>G p.Tyr114Cys)
Dematti S et al., ENSAT Meeting, P29, 2013 (156)	NFPA (microadenoma) PGL-1 syndrome		*SDHD* (c.341A>G p.Tyr114Cys)
Dematti S et al., ENSAT Meeting, P29, 2013 (156)	NFPA (microadenoma) PGL-1 syndrome		*SDHD* (c.341A>G p.Tyr114Cys)
Papathomas T et al., Eur J Endocrinol, 2014 (157)	Macroprolactinoma HNPGL (mpx) Pheo	HNPGL	*SDHD* (c.274G>T p.Asp92Tyr) LOH in the PA
Papathomas T et al., Eur J Endocrinol, 2014 (157)	GH-secreting macroadenoma HNPGL (mpx)	HNPGL (father, two sisters) GIST (sister)	*SDHD* (c.274G>T p.Asp92Tyr)

Table 8. Pheochromocytoma/paraganglioma and pituitary adenoma and pheochromocytoma/paraganglioma-associated genes in the literature – cont.

Article	**Case**	**Family history**	**Mutation**
López-Jiménez E et al., Clin Endocrinol, 2008 (158)	Macroprolactinoma HNPGL		*SDHC* (c.256-257insTTT) p.Phe85dup
Gill AJ et al., Am J Surg Pathol, 2014 (159)	Clinically NFPA, but strong prolactin staining in adenoma		*SDHA* (not germline, double-hit inactivation confirmed in tumor) (c.725_736del) (c.989_990insTA)
Larraza-Hernandez O et al., Am J Clin Pathol, 1982 (160)	NFPA + PGL + papillary thyroid carcinoma+ parathyroid hyperplasia+ gastric leiomyoma+amyloidosis	PGL+pituitary tumor (daughter, granddaughter)	
Teh BT et al., Br J Surg, 1996 (161)	Acromegaly+pheo (bilateral, recurrent)+PGL		
Sleilati GG et al., Endocr Pract, 2002 (162)	Acromegaly+mpx PGL		
Zhang C et al., J Cancer Res Clin Oncol, 2011 (163)	Acromegaly+mpx PGL +pheo	Father: PGL Sister: adrenal mass	
Efstathiadou et al., Head Neck, 2014 (164)	Microprolactinoma+HNPGL +papillary thyroid carcinoma+components of Cowden syndrome (mammary gland fibroadenoma, uterine leiomyofibroma)		No *PTEN*, *SDHB*, *SDHC* and *SDHD* mutation

Table 8. Pheochromocytoma/paraganglioma and pituitary adenoma and pheochromocytoma/paraganglioma-associated genes in the literature – cont.

Article	**Case**	**Family history**	**Mutation**
Osamura Y et al., 9th Meeting on the Functioning Tumors, Tokyo, 1977 (63, 104)	Acromegaly+pheo+ adrenal cortical adenoma+renal cell carcinoma		
Brauer VF et al., Endocr Practice, 2004 (145)	Acromegaly+HPT		*RET* (codon 791 TAT/TTT, p.Tyr791Phe)
Saito T et al., Am J Med Sci, 2010 (146)	Acromegaly MTC	Pheo (bilat) MTC (mother)	*RET* (codon 634 TGC/TTC, p.Cys634Phe)
Heinlen JE et al., ISRN Oncology, 2011 (147)	NFPA Pheo MTC		*RET* (p.Cys618Ser)
Lugli F et al., IWMEN (MEN workshop), P43, 2012 (148)	PRLoma MTC	MTC (sister)	*RET* (c.2711C>T, p.Ser904Phe)
Lugli F et al., IWMEN (MEN workshop), P43, 2012 (148)	Microprolactinoma MTC	MTC , pancreatic lesion (gastrinoma?)(sister) MTC? (brother) (mild hypercalcitoninemia waiting for thyroidectomy)	*RET* (c.2410G>A p.Val804Met)
Steiner AL et al., Medicine, 1968 (59, 141)	MTC + HPT+ pheo + Cushing disease	Positive for MEN for VI generations	

Table 8. Pheochromocytoma/paraganglioma and pituitary adenoma and pheochromocytoma/paraganglioma-associated genes in the literature – cont.

Article	**Case**	**Family history**	**Mutation**
Wolf LM, Ann Endocrinol, 1972 (104, 142)	MTC + HPT+ pheo + NFPA		
Bertrand JH et al., Clin Endocrinol, 1987 (143)	MTC (bilateral)+ parathyroid adenoma+ pheo + Macroprolactinoma	MTC	
Boudin G et al., Presse Medicale, 1970 (165)	NF1+ pituitary adenoma (chromophobe)		
Barberis M et al., Pathologica, 1979 (166)	NF1+ pituitary adenoma		
Pinnamaneni K et al., Arch Intern Med, 1980 (167)	NF1+PRLoma	Neurofibromatosis (paternal grandfather, father, 2 children)	
Nakajima M et al., Nihon Geka Hokan, 1990 (168)	NF1+PRLoma	Neurofibromatosis (brother)	
Kurozumi K et al., No Shinkei Geka, 2002 (169)	NF1+pituitary adenoma (clinically silent corticotroph adenoma)	Neurofibromatosis (father, sister, daughter)	
Gatta-Cherifi B et al., EJE, 2012 (170)	acromegaly, pheo-bilateral, HPT, pancreatic endocrine tumor, +features of NF1	familial cases of MEN1	

3.4.3.2. Von Hippel-Lindau disease

VHL disease is an autosomal dominantly inherited tumor syndrome, characterized most commonly by retinal or cerebellar hemangioblastomas and clear cell renal carcinoma. Kidneys, pancreas and epididymis can be frequently affected by cystic disease as part of the syndrome. Pheo/PGLs can occur in the tumor syndrome is 10-20% (171). VHL results from mutations in the *VHL* tumor supressor gene. The identification of the *VHL* gene in 1993 enabled an earlier diagnosis of the disease and revealed genotype-phenotype association. The presence of pheochromocytoma in VHL disease has been linked to missense *VHL* mutations. Mutations, which result in substitution of a surface amino acid are associated with higher pheochromocytoma risk (172).
Pituitary adenoma is not part of the tumor syndrome, to date only 1 case has been published with VHL disease and a pituitary tumor (173).

3.4.3.3. Neurofibromatosis type 1

NF1 is characterized by dermal neurofibromas, café au lait spots, axillary or inguinal freckling, and hamartomas of the iris (131). Pheochromocytoma occurs in around 1% of the paients with NF1 (174). Usually the diagnosis of NF1 is based on the clinical findings, therefore the 5 cases with NF1 and pituitary adenoma in the literature had no genetic diagnosis (165-169). In addition to these cases 1 case has been published of a patient with acromegaly and pheochromocytoma, clinical features of NF1 and familial cases of MEN1, which might be an example for a digenic case (170) (Table 8).

3.4.3.4. Familial paraganglioma syndrome

Inherited PGL syndromes are casued by mutations in any of the succinate dehydrogenase (SDHx) genes and assembly factor (SDHAF2). The familial paraganglioma syndrome PGL1 is caused by mutation in the *SDHD* gene. PGL2 is caused by mutation in *SDHAF2* (175, 176). Both for *SDHD* and *SDHAF2*-related tumors paternal transmission is characteristic, suggesting genomic imprinting (177). The PGL3 syndrome is caused by the rarely occuring mutations in *SDHC* gene. Mutations in *SDHB* gene cause the PGL4 syndrome, and *SDHA*-related tumors are rare.

SDHB-related tumors have a high malignant potential, and are mainly abdominal, while *SDHD*- and *SDHC*-related tumors are mostly benign head and neck PGLs (175, 176). Four cases with pheo/PGL and pituitary adenoma has been published, which fit in the SDH phenotype (160-163) and 13 more cases with a confirmed mutation in *SDHA*, *SDHB*, *SDHC* or *SDHD* genes (60, 152-155, 158). In two cases loss of heterozigosity (LOH) at the *SDHD* locus was found in the pituitary adenoma (154, 157) (Table 8).

DOI:10.14753/SE.2015.2110

4. Objectives

The overall aim of the study was to investigate the genetic backround of pituitary tumor formation.

Study I: Patients with germline *AIP* mutations or low AIP protein expression have large, invasive somatotroph adenomas and poor response to somatostatin analogues (SSA). Therefore, low AIP expression seems to be important in determining the pathological characteristics of somatotropinomas. Our objective was to investigate the miRNA regulation of AIP protein expression, which could be responsible for the low AIP levels found in approximately half of the sporadic somatotropinomas (178, 179).

Study II: Pituitary adenoma and pheo/PGL can occur in the same patient or in the same family, and classically they are not part of any multiple endocrine tumor syndrome together. Coexistence of the two diseases could be due to either a common pathogenic mechanism or a coincidence. Our aim was to study the possible role of mutations in the genes known to cause pheo/PGL in pituitary adenoma formation. The genetic screening of the samples was done in special genetic laboratories in the United Kingdom.

DOI:10.14753/SE.2015.2110

5. Methods

5.1. Patients

Study I

Thirty-four consecutive patients with acromegaly who had previously had pituitary surgery and had tissue available (paraffin block and fresh frozen tumor sample) were included in the study. This study was approved by the Ethics Committees of the Clementino Fraga Filho University Hospital/Medical School, Federal University of Rio de Janeiro and the Clinics Hospital, Ribeirão Preto Medical School, São Paulo University. All subjects gave informed consent before study entry. Patients underwent pituitary surgery between 2006 and 2011. Biochemical diagnosis of acromegaly was based on international criteria at the time of the study (180). Exclusion criteria included previous known *AIP* mutations, a family history of pituitary adenoma, presence of features or family history of Carney complex or multiple endocrine neoplasia type 1 or 4 and preoperative therapy with SSA [as treatment may increase AIP expression (181)]. Tumor invasiveness was determined according to Knosp-Steiner criteria (182). GH-secreting pituitary tumor samples were obtained during transsphenoidal surgery: part of the sample was processed for routine histopathological and immunohistochemical studies (including anterior pituitary hormones), and part was snap-frozen and stored at -70°C for molecular biology studies. All samples were micro-dissected by an experienced pathologist in order to separate any non-tumoral tissue and homogenized using a Polytron™ homogenizer. In addition, five normal human pituitaries were obtained within 10 hours from the time of death at autopsies of subjects who had died from natural causes without previous evidence of any endocrine disease or pituitary abnormality.

Study II

We collected clinical data, genomic DNA, and tumor tissue, where available, from 39 patients (from 27 kindreds) with pheo/PGL and PA in a sporadic (n=19) or familial

(n=20) setting. Probands from 23 FIPA families served as controls. Patients have been referred from the following countries: Australia, Brasil, Bulgaria, France, Hungary, India, Ireland, Romania, Russia, Spain, United Kingdom, United States. Neurofibromatosis was ruled out based on clinical criteria according published guidelines (183). The study was approved by the local Ethics Committee and all subjects gave written informed consent.

5.2. Postsurgical evaluation (study I)

Biochemical assessment was performed 12 weeks after surgery by evaluation of oral glucose tolerance test (OGTT) and serum IGF-I levels in all subjects. Pituitary MRI was performed 3 months after the surgical procedure. Patients were considered as non-cured on the basis of the clinical picture, nadir GH levels after OGTT higher than 0.4 ng/mL, and plasma IGF-I levels higher than age-matched normal subjects. Medical therapy with long-acting octreotide (OCT-LAR) was started at a dose of 20 mg every 4 weeks, and the dose was increased to 30 mg every 4 weeks in uncontrolled patients after 3 months of therapy. Efficacy of medical therapy was evaluated at the last patient visit, and patients were considered uncontrolled if they had a basal GH value higher than 1.0 ng/mL and/or a plasma IGF-I level higher than age-matched normal subjects with at least 6 months of treatment with OCT-LAR at a dosage of 30 mg. Postsurgical follow-up ranged from 12 to 60 months (median 32 months).

Tumor volume was not considered as an endpoint in this series because the study included only postsurgical patients, which could lead to mistakes in the volume measurements due to confounding variables such as postsurgical changes. (This part of the work was done by Leandro Kasuki in Brazil).

5.3. Nucleic acid extraction and quantification

5.3.1. DNA extraction

Study I: Deoxyribonucleic acid (DNA) was extracted using the QIAamp DNA Mini Kit (Qiagen, Valencia, CA, USA) from the pituitary adenoma tissue according to the manufacturer's protocol.

Study II: Genomic DNA (gDNA) was extracted from peripheral blood using BACC2 DNA extraction kit (RPN-8502, GE Healthcare) according to the manufacturer's protocol. DNA extraction from formalin-fixed paraffin embedded pituitary or pheo/PGL tissue was performed using QIAamp DNA FFPE Tissue Kit (Qiagen, Crawley, UK) with some modifications (heating 5 min, adding 150 µl buffer ATL instead of 180 µl, incubation at 56 ^{o}C overnight, incubation at 90 ^{o}C for 1h, adding 500 µl buffer AW1 instead of 700 µl, drying the spin column membrane for 3 min instead of 5 min). Representative tumor tissue was marked by a pathologist to avoid areas showing suboptimal preservation and contamination with normal tissue.

5.3.2. RNA extraction

Study I: Tumoral ribonucleic acid (RNA) from somatotropinomas was extracted using the RNeasy Mini kit (Qiagen) according to the manufacturer's protocol. (Performed by Leandro Kasuki in Brazil).

After miR-34a overexpression and inhibition cells were harvested and RNA extracted using RNeasy Mini Kit (Qiagen) according to the manufacturer's protocol.

Study II: RNA was extracted from a peripherial blood sample using PAXgene Blood RNA Kit (QIAGEN Gmbh for PreAnalytiX, Hombrechtikon, Switzerland).

5.3.3. Determination of nucleic acid concentration and purity

The concentration and purity of the isolated DNA and RNA were determined spectrophotometrically in a Nanodrop Spectrophotometer ND 1000 (Thermo Scientific, USA). This spectrophotometer measures 1 ul samples with high accuracy and reproducibility (http://www.nanodrop.com/library/nd-1000-v3.7-users-manual-

8.5x11.pdf). The purity of the nucleic acids is determined by the A_{260}/A_{280} ratio. A ratio of 1.8-2.0 indicates little or no protein contamination.

5.4. Genetic screening

5.4.1. *AIP* mutation analysis in somatotropinomas (study I)

The entire coding sequence of *AIP* (NM_003977.2), the conserved splice sites (from the conserved A of the upstream branch site to +10 downstream of each exon) and 1200 base pairs of the promoter region were direct sequenced, as previously published (184). For those tumors whose DNA was not available, the complementary DNA (cDNA) was sequenced with previously published primers (184). Sequencing was performed with ABI 3130 Genetic Analyzer (ABI PRISM/PE Biosystems, Foster City, CA, USA).

5.4.2. Mutation testing for pheochromocytoma/paraganglioma or pituitary adenoma causing genes in study II

Sequence analysis of the aryl hydrocarbon receptor interacting protein gene (*AIP*, NM_003977.2), multiple endocrine neoplasia type 1 gene (*MEN1*, NM_130799.2), cyclin-dependent kinase inhibitor 1B gene (*CDKN1B*, coding region NM_004064.3, upstream open reading frame NM_004064.2) was performed using Sanger sequencing and multiplex ligation-dependent probe amplification (MLPA), as previously described (115, 185, 186). Genes implicated in pheo/PGL (MYC-associated factor X (*MAX*, NM_002382.3),'rearranged during transfection' tyrosine kinase receptor gene (*RET*, NM_020975.4), succinate dehydrogenase subunit A (*SDHA* NM_004168.2), succinate dehydrogenase complex assembly factor 2 (*SDHAF2*, NM_017841.2), succinate dehydrogenase subunit B (*SDHB*, NM_003000.2), succinate dehydrogenase subunit C (*SDHC*, NM_003001.3), succinate dehydrogenase subunit D (*SDHD*, NM_003002.2), transmembrane protein 127 (*TMEM 127*, NM_017849.3) and von Hippel–Lindau gene (*VHL*, NM_000551.3)) were analyzed using a combination of next generation sequencing, Sanger sequencing and MLPA, as previously described (187, 188). In addition, fumarate hydratase (*FH*, NM_000143) was studied in a subset of patients.

Tissue DNA analysis with polymerase chain reaction (PCR) and sequencing was carried out according to standard protocols (Applied Biosystems, Warrington, UK). The sequences were analyzed using Mutation Surveyor (version 4.0.6, Softgenetics, State College, PA, USA). RNA was converted to cDNA which was amplified using several exonic primers sets flanking the mutation found in gDNA, followed by sequence analysis of the PCR product. *In silico* analysis of variants was performed using the Polyphen2 (http//:genetics.bwh.harvard.edu) and ALAMUT 2.2.0 (http://www.interactive-biosoftware.com/) softwares.

5.4.3. Loss of heterozygosity analysis (study II)

Microsatellites D1S170 and D1S3669 for the *SDHB* locus were identified on the National Center for Biotechnology Information (NCBI) website (http://www.ncbi.nlm.nih.gov) and the UCSC Genome Browser website (http://genome.ucsc.edu/). Details of the microsatellites at the 11q13 locus (for *MEN1*) were previously described (189). Simple repeats were identified using the UCSC website and designed accordingly for the specific region (189). The NCBI36/hg18 assembly of the human Genome was used for localisation of the markers. Fragment analysis was carried out using standard protocols on an ABI 3730 (Applied Biosystems, Warrington, UK) and analysed using GeneMarker (version 2.20; SoftGenetics, State College, PA).

5.5. Immunohistochemistry

5.5.1. Cytokeratin pattern analysis (study I)

The cytokeratin expression pattern was analyzed as previously published with a mouse monoclonal antibody CAM 5.2 (1:100, BD Biosciences, San Jose, CA, USA, cat. number 349205) (190). Tumors were classified according to the cytokeratin expression as densely granulated, sparsely granulated or mixed forms according to a previously reported classification (191). Mixed tumors were considered as densely granulated for analysis, as previously suggested (191).

5.5.2. AIP protein expression analysis in somatotropinomas (study I)

AIP expression was analyzed by immunohistochemistry, using a monoclonal antibody (1:500, NB100-127, Novus, Littleton, CO, USA) in paraffin-embedded tissue sections as previously described (178, 192). For semi-quantitative estimate of cytoplasmic AIP immunostaining, slides were scored for pattern [diffuse (score 2) or patchy (score 1)] and for intensity [strong (score 3), moderate (score 2) and weak (score 1)], and the final score was calculated by multiplying the two scores (pattern and intensity), as previously described (178, 192). Final scores of 0 (no expression), 1 and 2 were considered as low AIP expression, while scores 3, 4, or 6 were considered as high expression. The adenoma scoring was performed by a single independent observer (Leandro Kasuki) blinded for the clinical data of the patients.

5.5.3. Immunohistochemistry of pheochromocytomas/paragangliomas and pituitary adenomas in study II

Immunostaining for GHRH was performed using GHRH antibody 451-7 (Lyon, France), 1:2000 dilution, as previously described (193, 194). Pheochromocytomas of patients with *MEN1* mutation were stained for menin using a rabbit polyclonal anti-menin antibody (AbCam, ab2605, dilution 1: 500), as previously described (195). Mouse pancreas showing islets and pheochromocytomas of patients without any known germline mutation were used as a positive control. SDHA and SDHB immunostaining was performed using a mouse monoclonal anti-SDHA antibody (2E3GC12FB2AE2, AbCam, ab147159, dilution 1:200) and a rabbit polyclonal anti-SDHB antibody (HPA002867, Sigma Aldrich, dilution 1:200), as previously described (196). Further immunostaining was performed using the anti-mitochondrial antibody 113-1 recognizing a 60-65 kDa nonglycosylated membrane protein (Merck Millipore, dilution 1:150) and an antibody directed against the endoplasmic reticulum lectin 1 (ERLEC1, Novus Biological, dilution 1:100). Immunoreactions were performed using the automated Leica Bond III system. For antigen unmasking EDTA at pH 8 was used for anti-113-1 and sodium citrate buffer (10mM Sodium Citrate, 0.05% Tween 20, at pH 6) for anti-ERLEC1. The primary antibody binding was visualized with the SuperSentitive

IHC detection system from BioGenex (Fremon, CA, USA). Sections were counterstained with Mayer's Hemalum before being dehydrated and coverslipped.

5.6. Electron microscopy (study II)

As the pituitary adenomas of patients affected by *SDHX* alterations have unique histological feature (intracytoplasmic vacuoles), to study the nature of the vacuoles ultrastructural examination was performed in a pituitary adenoma with an *SDHB* mutation from a formalin-fixed paraffin-embedded tissue fragment. Tissue was post-fixed in 1% osmium tetroxide, dehydrated in ethanol, processed through propylene oxide, and embedded in Spurr's resin. Ultrathin sections were stained with uranyl acetate and lead citrate and were examined with a Hitachi H-7650 transmission electron microscope.

5.7. Reverse Transcription and Real-Time PCR (RT-qPCR)

Total RNA (500-1000 ng) was reverse transcribed (RT) into cDNA according to the following conditions:

1. 500-1000 ng RNA + water to have a final volume of 16.95 µl, incubated in the thermocycler (G-Storm GT-12061) for 10 min 65 ^{o}C, than 1 min on ice.
2. Adding the following master mix to have a final volume of 25 µl.

Mix:	**volume for a single sample (µl)**
M-MLV RT 5x buffer M531A	5
0,1M DTT 500 µl (Invitrogen)	1
dNTPs 20mM	1.25
Random primers 250ng/µl (Promega C118A)	0.25
M-MLV 200 U/µl (Invitrogen)	0.5
Rnase OUT 40 U/µl (Invitrogen)	0.05
Total	**8.05**

3. Incubation in the thermocycler with the following conditions: 10 min 26 ^{o}C, 60 min 37 ^{o}C, 10 min 92 ^{o}C, ∞4 ^{o}C.

A RT-PCR reaction mix without the reverse transcriptase enzyme was included in each experiment as a control for gDNA contamination and one reaction mix without RNA was included as negative control. The exclusion of gDNA contamination from each sample was usually verified by PCR for the glyceraldehydes-3-phosphate dehydrogenase (GAPDH) gene. The cDNA samples were stored at -20°C.

The gene expression assays were performed using the TaqMan® RT-qPCR system (Applied Biosystems). The assays consist in the quantification of a gene of interest using a mix of unlabeled PCR primers and a TaqMan probe. TaqMan reactions were performed as duplex reactions including the gene of interest and an endogenous control (reference gene). In each reaction, each sample was assayed in duplicate or triplicate.

Reactions were prepared according to the following conditions:

Mix:	**volume for a single sample (µl)**
2X TaqMan Universal PCR Master Mix	5
20X Assay Mix gene of interest (AIP) (FAM)	0.5
20X Assay Mix reference gene (GAPDH) (VIC)	0.5
ddH2O	2
cDNA (5 ng/µl)	2
Total	**10**

The cDNA was amplified in 384-well plates on a 7900HT Real-Time PCR System (Applied Biosystems). Data were analysed using the SDS v2.3 software (Applied Biosystems). All data were normalised to the expression levels of the reference gene. The normalisation to an endogenous control was done to correct for sample to sample variations in RT-qPCR efficiency and errors in sample quantification.

5.7.1. AIP mRNA expression analysis in somatotropinomas (study I)

The AIP mRNA expression was analyzed by real-time qPCR in somatotropinomas and normal pituitaries. Approximately 1 µg of total RNA was used in a reverse transcription reaction of 10 µL using 2.5 µM Oligo D(T), 5.5 mM $MgCl_2$, 2.0 mM dNTPs, 20 U/µL RNase Inhibitor, 50 U/µL MultiScribe TaqMan and 10x RT Buffer, in a first strand cDNA synthesis kit (Taq-Man RT reagents, Applied Biosystems, Branchburg, New Jersey, USA). The reverse transcription cycle sequence was 25ºC for 10 min, 48ºC for 30 min and 95ºC for 5 min The cDNA of *AIP* and of *glucuronidase β* (*GUSB*), *TATA box binding protein* (*TBP*) and *phosphoglycerate kinase 1* (*PGK1*) genes, used as endogenous controls, were separately amplified in duplicates, in a total volume of 12 µl, in real-time qPCR assays, using the Applied Biosystems 7500 Real-Time PCR System (Foster City, CA, USA). Reactions were incubated in a 96-well optical plate at 95ºC for 10 min, followed by 40 cycles of 95ºC for 15 sec and 60ºC for 1 min The TaqMan® assays for *AIP* and the endogenous controls are shown in Table 9. The cycle threshold (Ct) was defined as the cycle number at which the fluorescence surpasses the fixed threshold. The Ct data were performed using default threshold settings. Expression analysis was performed with the QPCR software (197). Efficiency of each reaction was calculated by linear regression with the LingRegPCR software. The normalization of each sample results was performed by subtracting the Ct (geometric mean) for the target gene (*AIP*) by the endogenous control Ct (*TBP*, *PGK1* and *GUS*), generating the ΔCt [Ct_{sample} (target gene) - Ct_{sample} (endogenous control)]. The normalized results (ΔCt) were then subjected to calibration step. We used five normal pituitary tissue samples as calibrator, obtaining the ΔΔCt (ΔCt_{sample}- $\Delta Ct_{normal\ pituitary}$). The relative expression of each gene was given by the formula $(1 + efficiency)^{-\Delta\Delta Ct}$. The efficiency value was calculated for each reaction. The median values obtained from $(1 + efficiency)^{-\Delta\Delta Ct}$ of tumor samples was compared with the median value of $(1 + efficiency)^{-\Delta\Delta Ct}$ normal pituitary tissue samples, obtaining the fold change. Adequacy of endogenous controls was calculated with the GeNorm 3.3 visual basic application for Microsoft Excel. (Performed by Leandro Kasuki)

Table 9. TaqMan assays used in real-time qPCR quantification in Study I

Genes and miRNAs	Assays (TaqMan® Applied Biosystems)
human AIP	Hs_00610222_m1
rat Aip	Rn_00597273-m1
hsa-let-7a	000377
hsa-let-7b	002619
hsa-miR-202	002363
hsa-miR-22	000398
hsa-miR-34a	000426
hsa-miR-34c	000428
hsa-miR-324	002161
hsa-miR-449	001030
hsa-miR-510	002241
hsa-miR-612	001579
hsa-miR-639	001583
hsa-miR-671	002322
Endogenous controls	
RNU38B	001004
RNU49	001005
RNU6B	4373381
Beta-actin	4352340E
TBP	Hs_00427621_m1
GUS Beta	Hs_00939627_m1
PGK1	Hs_99999906_m1
GAPDH	Hs_99999905_m1

5.7.2. Quantification of miRNAs identified by *in silico* target prediction (study I)

The selected miRNA expressions were analyzed by real-time qPCR in somatotropinomas and in normal pituitaries. The reverse transcription cycle for

miRNAs was 16°C for 30 min, 42°C for 30 min and 85°C for 5 min The cDNA of the selected miRNAs and of *RNU38B* and *RNU49*, used as endogenous controls, were amplified in duplicates in three different reactions in a total volume of 12 µl, in real-time qPCR assays, using the Applied Biosystems 7500 Real-Time PCR System. Reactions were incubated in a 96-well optical plate with 40 cycles of 95ºC for 15 sec and 60ºC for 1 min The TaqMan® assays for miRNAs and for the endogenous controls are shown in Table 9. The analysis of the results was performed with the same methodology previously described for *AIP*. (Performed by Leandro Kasuki)

5.7.3. Endogenous miR-34a expression in different cell lines and tissues

In order to estimate the level of expression of miR-34a in the GH3 and HEK293 cells we extracted RNA from these cells. We also included in the analysis RNA from human tissues (AM6000, Ambion) previously described to express miR-34a at high (ovary, prostate and testes) or low (adipose, heart and liver) levels (http://mirnamap.mbc.nctu.edu.tw). Real-time qPCR amplifications were run using the hsa-miR-34a TaqMan® MicroRNA Assay, (4427975, Life Technologies). RNU6B was used as an endogenous control for human samples and beta-actin was chosen as a control for the rat sample. Data were analysed using the ΔΔCt method and normalized to the data of the liver.

5.7.4. Endogenous AIP mRNA expression after miR-34a overexpression and inhibition

After miR-34a overexpression and inhibition RT-qPCR was performed with the TaqMan system using ready made AIP-probe primer kits (Hs_00610222_m1, Rn_00597273-m1, Life Technologies). Reactions were performed in triplicate using *GAPDH* as endogenous control. Data were analysed using the ΔΔCt method.

5.8. Identification of miRNAs targeting *AIP* 3'-untranslated region (3'-UTR) in somatotropinomas (study I)

Target site prediction

To identify AIP mRNA-miRNA interaction we initially used algorithms described in the miRNAmap prediction program (198). This bioinformatics tool uses data from TargetScan 6.0 (http://www.targetscan.org), MiRanda (http://www.microrna.org/microrna/home.do) and RNAhybrid (http://bibiserv.techfak.uni-bielefeld.de/rnahybrid/). The mRNA-miRNA interaction was evaluated by three different criteria: (i) target site predicted by at least two prediction programs, (ii) the target gene contains multiple target sites for the miRNA and (iii) the target sites are located in accessible regions of the RNA as determined by a pre-specified algorithm. In addition, miRNAmap used miRNA and target mRNA expression profiles from a repository to calculate the Pearson correlation coefficients for each miRNA and the target gene (198, 199). We selected to evaluate by qPCR miRNAs that reach all three miRNAmap criteria or at least two miRNAmap criteria and a negative Pearson coefficient at least -0.30. Moreover, in order to confirm and to complete our search for miRNAs interacting with *AIP* and to determine the exact miRNA target binding sites in both human and rat *AIP* we utilized TargetScan version 6.2 (http://www.targetscan.org), MicroCosm (http://www.ebi.ac.uk/enright-srv/microcosm/cgi-bin/targets/v5), FindTar version 3 (http://bio.sz.tsinghua.edu.cn/content/list/), miRanda (http://www.microrna.org/microrna/home.do) and PicTar (www.pictar.bio.nyu.edu).

5.9. Cell culture (study I)

The rat GH- and prolactin-secreting pituitary adenoma cell line GH3, the human embryonic kidney cell line HEK293 and the human primary pancreatic adenocarcinoma BXPC3 cell line were grown in Dulbecco's modified Eagle's medium (DMEM, Sigma-Aldrich, Poole, Dorset, UK) supplemented with 10% fetal bovine serum (Biosera,

Ringmer, UK), penicillin (100 IU/mL) and streptomycin (100 mg/mL, Sigma Aldrich) in a humidified atmosphere at 37°C with 5% CO_2.

5.9.1. Transient transfection of cells

GH3, HEK293 and BXPC3 cells were transiently transfected with plasmid DNA using the Lipofectamine 2000 transfection reagent (Invitrogen). Transfections were carried out following the manufacturer's protocol. Briefly, cells were plated in normal culture medium without antibiotics. DNA and Lipofectamine 2000 were diluted in Opti-MEM I reduced serum medium (Invitrogen) and incubated at room temperature for 5 min. Then, the diluted DNA was mixed with the diluted Lipofectamine and incubated at room temperature for 30 min, to allow complex formation. The complexes were then added to the wells without removing the media. The plates were incubated for 24, 48 or 72h depending on the experiment.

5.9.2. miRNA overexpression and inhibition

HEK293 and GH3 cells were seeded in 24-well plates at a density of $0.6x10^5$ cells/well and $1x10^5$ cells/well, respectively. After 1-24 h cells were transfected with the pre-miR-34a precursor (PM11030, Life Technologies), the anti-miR-34a inhibitor (AM11030, Life Technologies), scrambled-miR (AM17111, Life Technologies) or scrambled-anti-miR (AM17010, Life Technologies) at a final concentration of 50 nM. miRNA precursors and Lipofectamine 2000 were diluted in Opti-MEM I reduced serum medium (Invitrogen) and incubated at room temperature for 5 min. Then, the diluted miRNA precursor was mixed with the diluted Lipofectamine and incubated at room temperature for 30 min, to allow complex formation. The complexes were then added to the wells without removing the media. The plates were incubated for 24, 48 or 72h depending on the experiment.

5.10. Luciferase gene reporter assay

To study the interaction between selected miRNAs and the wild type (WT) and mutant *AIP*-3'UTR constructs, the Dual-Luciferase Reporter Assay System (Promega) was used. This assay combines two luciferase reporter systems: the *Firefly* (*Photinus*

pyralis) and the *Renilla* (*Renilla reniformis*). The protocol was followed according to the manufacturer's instructions. GH3 cells were seeded in the inner wells of 24-well plates (200) at a density of $1x10^5$ cells/well. After 24 h, cells were cotransfected with Lipofectamine 2000 using 0.5 µg of the pGL3-vector and 25 ng of the Renilla vector [pRL-cytomegalovirus (CMV)]. For each plate, the pre-miR-34a or pre-miR-22 precursor or the scrambled miR was cotransfected at a final concentration of 50 nM. 24h post-transfection, transfected cells were lysed with 100 µl of 1X passive lysis buffer (PLB) for 10 min at 4°C. 25 µl of cell lysates were transferred to a 96-well luminometer plate and placed into the Omega luminometer (BMG Labtech). Previous to sample measurement, the injector system was primed with the Luciferase Assay Reagent II (LAR II, containing the substrate for *Firefly*) and the Stop & Glo reagent (containing the substrate for *Renilla*). *Firefly* and *Renilla* luciferase activities were then measured consecutively. Ratios of *Firefly* vs. *Renilla* luminescence signals served as a measure for reporter activity normalized for transfection efficiency.

5.11. Construction of 3'-Untranslated Region Reporter Plasmid

Reporter plasmids were used to study the interaction between selected miRNAs and the 3'UTR of *AIP*.

5.11.1. Generation of mutant *AIP*-3'-UTR Reporter Plasmids

A pGL3-vector containing the human *AIP*-3'-UTR was used to perform the experiments (201). A 931-bp segment of human *AIP*-3'-UTR is located immediately downstream from the coding sequence of the *Firefly* luciferase reporter gene. To examine whether the effect on the luciferase activity of the studied miRNAs was specifically due to binding to the predicted binding sites in the *AIP*-3'-UTR fragment, we disrupted these sites by site-directed mutagenesis. For interrupting the perfect "seed" pairing, four nucleotides (miR-34a site A and B) or three nucleotides (site C-which is overlapping with the only predicted binding site of miR-22) of the miR-34a seed sequences were deleted using the QuikChange XL-site-directed mutagenesis kit (Agilent Technologies, Santa Clara, CA, USA) and the following primers: site A: forward 5'-

ggccctgccttaccaagcccactgct-3' and reverse 5'-agcagtgggcttggtaaggcagggcc-3', site B: forward 5'-cctgccaagcccctgcagctgcca-3' and reverse 5'-tggcagctgcaggggcttggcagg-3', site C: forward 5'-gcccactgctgcccagcccccctg-3' and reverse 5'-caggggggctgggcagcagtgggc-3'. Mutagenic primers were designed using the QuickChange Primer Design program. Three mutant plasmids were generated with deletions at site A (MUT_A), B (MUT_B) and C (MUT_C), and a further mutant was generated with both site A and C mutations. All mutant inserts were confirmed by direct sequencing. The QuickChange XL site-directed mutagenesis kit was used in three steps according to the manufacturer's instructions: synthesis of the mutant strand, digestion of the parental methylated strand that did not contain the mutation with DpnI, transformation of competent cells with plasmid DNA (see next session).

5.11.2. Transformation of competent bacterial cells with plasmid DNA

The high-efficiency JM109 competent cells were transformed with plasmid DNA. The purpose of this technique is to introduce a foreign plasmid into bacteria and to use those bacteria to amplify the plasmid in order to make large quantities of it. Briefly, 50 µl of cells were mixed with 2 µl of each ligation reaction and then heat-shocked for 30 sec at 42°C. 950 µl of SOC medium (Invitrogen) were then added to the ligation reaction transformations and shaked for 1h at 37°C. After incubation, 50 µl of each transformation culture were plated onto LB/agar/ampicillin plates. Plates were incubated overnight at 37°C. Transformation was successful if the next day colonies were formed because of vector conferring resistance to ampicillin.

5.11.3. Small-scale plasmid DNA purification (miniprep)

A single colony from a plate was inoculated in 5 ml of LB medium containing 5 µl of 100 mg/ml ampicilin and shaked overnight at 37°C. The next day plasmid DNA was purified using the QIAprep Spin MiniPrep Kit (Qiagen) following the manufacturer's instructions. With this method bacterial cultures are lysed and the lysates are cleared by centrifugation. The cleared lysates are then applied to the QIAprep module where plasmid DNA adsorbs to the silica membrane. Impurities are washed away and pure DNA is eluted in a small volume of elution buffer or water. The concentration of each sample was determined using Nanodrop Spectrophotometer ND 1000 (Thermo

Scientific, USA). The plasmids were confirmed to contain the desired mutations by sequencing.

5.11.4. Large-scale plasmid DNA purification (maxiprep)

After confirming the constructs were correct, higher concentrations of plasmid DNA were obtained using the GenElute HP Plasmid Maxiprep Kit (Sigma-Aldrich) following the manufacturer's instructions. Previous to purification, 100 µl of each plasmid were added to 150 ml of LB medium and 150 µl of ampicillin. Bacterial cultures were shaked overnight at 37°C. According to the maxiprep protocol an overnight recombinant E. coli culture is harvested by centrifugation and subjected to a modified alkaline-SDS lysis procedure followed by adsorption of the DNA onto a silica membrane in the presence of high salts. Contaminants are removed by two wash steps. Finally, the bound DNA is eluted in Elution Solution (Tris-HCl) or water.

5.12. Protein extraction and quantification

Cell lysis buffer [PhosphoSafe Extraction Buffer (Merck Millipore, Darmstadt, Germany)] was added to the cells. After an incubation of 20 min, each well was scraped thoroughly and the cell lysates were transferred to 1.5 ml tubes. After a centrifugation step, the supernatants were stored at -80°C. The Bradford assay (Bio-Rad, UK) was carried out to ensure the protein concentration of the lysates used for Western Blot was normalised. A set of bovine serum albumin (BSA) dilutions was prepared for the calibration curve. 5 µl of protein samples and standards were transferred into a 96-well plate and then 195 µl of Bradford reagent were added to each well. After an incubation of 5 min, the plate was inserted on the reader (Wallac 1420, PerkinElmer, Massachusetts, USA) and the absorbance was read at 595 nm. The samples for the standard curve were measured in triplicates, while the samples were measured in duplicates.

5.12.1. Western Blot (study I)

The variation of protein expression after transfection of cells with the selected miRNAs was determined by Western Blot. Twenty to 80 µg of cell culture lysates were separated

by electrophoresis on NuPage 4-12% Bis-Tris Protein gels (NP0321BOX, Life Technologies) and transferred onto nitrocellulose membranes. Kaleidoscope Prestained Standards were used as molecular weight marker (Bio-Rad, 161-0324). After a 60 min incubation with blocking buffer, membranes were incubated overnight at 4°C with mouse monoclonal AIP antibody (Novus NB100-127) at 1:1000 dilution and GAPDH rabbit antibody (sc-25778 Santa Cruz Biotechnology, Dallas, USA) at 1:1000 dilution was used as loading control. Infrared fluorescent-labeled anti-rabbit or anti-mouse secondary antibodies (IRDye 680 and 800, Li-Cor Biosciences, Cambridge, UK) were used at a 1:8000 dilution. Immunoblot detection and density measurements were performed on the Odyssey infrared-imaging system (Li-Cor).

5.13. Cell proliferation assay (study I)

The CellTiter 96 AQueous Non-Radioactive Cell Proliferation Assay (Promega, G5421) was used to measure cell proliferation. Briefly, this is a colorimetric method for determining the number of viable cells in proliferation assays. The assay is composed of solutions of a novel tetrazolium compound [3-(4,5-dimethylthiazol-2-yl)-5-(3-carboxymethoxyphenyl)-2-(4-sulfophenyl)-2H-tetrazolium, inner salt; MTS] and an electron coupling reagent (phenazine methosulfate; PMS). MTS is bioreduced by cells into a formazan product that is soluble in tissue culture medium, and its absorbance at 490 nm can be measured directly from 96-well assay plates. The conversion of MTS into aqueous, soluble formazan is accomplished by dehydrogenase enzymes found in metabolically active cells. The quantity of formazan product as measured by the amount of 490 nm absorbance is directly proportional to the number of living cells in culture.

BXPC3 cells were seeded in 96-well plates at 5000 cells/well in 200µl of serum-free media and 150µl of serum-free media without cells served as control. Cells were immediately transfected with the pre-miR-34a precursor (PM11030, Life Technologies) or scrambled-miR (AM17111, Life Technologies) at a final concentration of 50 nM. Twenty-four, 48h or 72h after transfection MTS reagent was added to the media in each well, and the plates were incubated for a further 3h at 37°C. The optical density was measured in the reader (Wallac 1420, PerkinElmer, Massachusetts, USA).

5.14. Wound healing assay (Study I)

The wound-healing assay was used to study cell migration *in vitro* (202).

BXPC3 cells were seeded in 12-well plates at 2 x 10^5 cells/well in 1000µl culture medium without antibiotics. When confluent layer was formed pictures were taken of each well, and cells were transfected with the pre-miR-34a precursor (PM11030, Life Technologies) or scrambled-miR (AM17111, Life Technologies) at a final concentration of 50 nM. A wound in the shape of a cross in the centre of each well was formed. Pictures were taken 24h, 48h and 72h after. Cells were incubated at 37°C in the meantime. Data were analyzed using Tscratch Program (www.cse-lab.ethz.ch/software.html.).

5.15. Colony formation assay (study I)

Colony formation assay was used to determine the clonogenic ability of transiently transfected GH3 cells. The clonogenic ability is defined as the % of cells in a population that possess the ability to form individual clones when plated alone in culture. A colony is defined as a group of four or more contiguous cells that are judged by their appearance to have arisen from a single cell.

GH3 cells were seeded in 12-well plates at 2 x 10^5 cells/well in 1000µl culture medium and after 24 h cells were transfected with the pre-miR-34a precursor (PM11030, Life Technologies) or scrambled-miR (AM17111, Life Technologies) at a final concentration of 50 nM. Twenty-four hours after transfection, cells were trypsinized and seeded in 6-well culture plates at a density of 1500 cells/well in 2 ml culture medium to form colonies. Cells were cultured at 37°C for 10-14 days. Pictures were taken of each well under microscope and the number of colonies was calculated.

5.16. Statistical analysis

The statistical analysis was performed using SPSS version 16.0 for Windows (SPSS, Inc., Chicago, IL, USA) or StatsDirect software (Addison-Wesley-Longman, Cambridge, UK). The results were reported as median values (minimum – maximum) or mean ± SEM of two to ten independent experiments, each performed in triplicate. The normal distribution of the quantitative variables was verified using the Shapiro-

Wilk test. The Student t-test or the Mann-Whitney test was used as appropriate to compare numerical variables. The chi-squared test was used to compare categorical variables. P values < 0.05 were considered statistically significant.

6. Results

6.1. Study I

6.1.1. Analysis of *AIP* mutations

A total of 34 tumors from acromegalic patients were selected for the study. Tumor gDNA from 28 patients and tumor cDNA from six patients were sequenced for *AIP* mutations. Two patients were identified with truncating *AIP* mutations (p.Y268*, and p.R304*) and one patient with a variant with controversial significance (p.R16H) (203-205). Leukocyte-derived DNA from these patients confirmed heterozygous germline mutations and these three patients were excluded from the study; therefore only data from 31 adenomas were included in following experiments.

6.1.2. Demographic, radiological, biochemical and pathological data of the patients with acromegaly

The demographic, biochemical and pathological data of the 31 patients included in the study are summarized in Table 10. The median age at diagnosis was 43 years (range 23-63), 15 patients (48%) were male. The median GH at diagnosis was 23.0 ng/mL (range 1.6-392.5) and the median IGF-I was 408% of the upper limit of normal range (range 165–1139). Twenty-seven tumors (87%) were macroadenomas and 15 (48%) co-expressed GH and prolactin upon immunostaining.

Table 10. Demographic, radiological, biochemical and pathological characteristics of the patients in Study I with acromegaly

Patient	Age at diagnosis (years)	Sex	Tumor Size (cm)	Invasive*	Baseline GH (ng/mL)	Baseline IGF-I (%ULNR)	Control with OCT-LAR	AIP protein expression (score)	miR-34a#	Granulation pattern	PRL
1	52	M	3.8 x 3.5	Y	251.0	331	N	L (2)	1.50	Sparsely	Y
2	31	F	2.1 x 1.9	N	53.9	302	N	H (3)	1.37	Sparsely	N
3	55	M	4.0 x 3.7	Y	9.2	380	Y	L (1)	0.66	N/A	N
4	46	M	3.0 x 2.1	Y	51.5	417	N	H (3)	1.30	Densely	Y
5	37	M	3.3 x 3.0	Y	34.2	401	NT	L (2)	0.73	Sparsely	Y
6	63	F	3.0 x 2.5	Y	133.0	225	N	H (4)	0.50	Densely	N

Table 10. Demographic, radiological, biochemical and pathological characteristics of the patients in Study I with acromegaly – cont.

Patient	Age at diagnosis (years)	Sex	Tumor Size (cm)	Invasive*	Baseline GH (ng/mL)	Baseline IGF-I (%ULNR)	Control with OCT-LAR	AIP protein expression (score)	miR-34a#	Granulation pattern	PRL
7	40	F	3.0 x 2.8	Y	4.3	372	N	L (2)	1.40	Densely	N
8	46	M	2.6 x 2.6	Y	15.6	208	Y	H (6)	0.13	Densely	Y
9	23	F	2.0 x 1.5	Y	110.0	165	N	H (4)	0.65	N/A	N
10	63	M	1.0 x 0.8	N	3.6	386	NT	H (4)	2.50	N/A	N
11	46	F	3.4 x 2.3	Y	53.5	415	N	L (2)	2.27	Sparsely	N
12	42	M	1.1 x 0.7	N	9.5	488	N	H (4)	0.79	Densely	Y
13	43	F	1.0 x 0.8	N	15.5	238	Y	H (4)	0.13	N/A	Y
14	42	M	1.5 x 1.3	Y	23.0	1139	NT	L (2)	0.57	Sparsely	Y
15	59	F	1.0 x 0.9	N	1.7	805	Y	H (4)	0.11	Densely	Y
16	34	M	1.2 x 1.0	N	7.1	199	Y	H (4)	0.08	Densely	Y
17	50	F	1.2 x 1.0	N	39.2	NA	Y	H (6)	0.15	Densely	N
18	30	F	1.3 x 2.0	N	13.7	642	Y	H (3)	0.16	Densely	N
19	37	F	3.0 x 2.5	N	185.0	531	Y	H (4)	4.96	Densely	N
20	36	M	1.5 x 1.0	N	70.0	NA	N	H (4)	1.11	Densely	N
21	57	M	2.0 X 1.4	Y	47.8	963	N	L (2)	0.28	Sparsely	N
22	52	F	3.3 x 3.4	Y	23.0	517	N	L (2)	2.64	Sparsely	Y
23	32	M	3.8 x 2.6	Y	10.8	NA	N	H (6)	1.69	Sparsely	Y
24	54	F	2.3 x 1.7	Y	32.5	490	N	L (2)	2.42	Sparsely	N
25	56	F	1.8 x 1.3	Y	1.6	587	N	L (2)	1.81	Densely	N
26	53	F	2.5 x 1.8	N	20.9	NA	N	H (3)	0.32	Sparsely	N
27	43	M	0.9 x 0.7	N	4.9	789	NT	L (2)	1.82	N/A	N
28	37	F	2.9 x 1.9	Y	10.0	265	NT	L (1)	3.37	Sparsely	Y
29	42	M	1.8 x 1.5	N	110.0	NA	Y	H (6)	0.61	Densely	Y
30	31	F	1.3 x 1.1	N	119.0	NA	N	L (2)	0.32	Densely	Y
31	24	M	5.8 x 5.0	Y	392.5	NA	Y	H (4)	0.12	N/A	Y

F, female; M, male; Y, yes; N, no; NA, not available; ULNR, upper limit of normal range; L, low; H, high; OCT-LAR, octreotide LAR; NT, not treated; *, tumor invasiveness was determined according to Knosp-Steiner criteria; #, expression level (fold change); NT, not treated with somatostatin analogues, PRL, immunostaining for prolactin.

6.1.3. AIP protein levels and correlation with *AIP* mRNA levels

All tumors expressed AIP, with low expression levels (score 1-2) observed in 13 cases (42%) (Figure 3). Interestingly, there was no difference in the *AIP* mRNA expression between tumors with low or high AIP protein levels: in the low AIP protein group the median *AIP* mRNA expression was 0.91 (range 0.48-1.95) and in the high AIP protein group was 1.14 (0.45-2.34, low vs. high protein group P=0.123). These data lead us to the hypothesis that post-transcriptional regulation, such as that exerted by miRNAs, may be the cause of the low AIP protein expression.

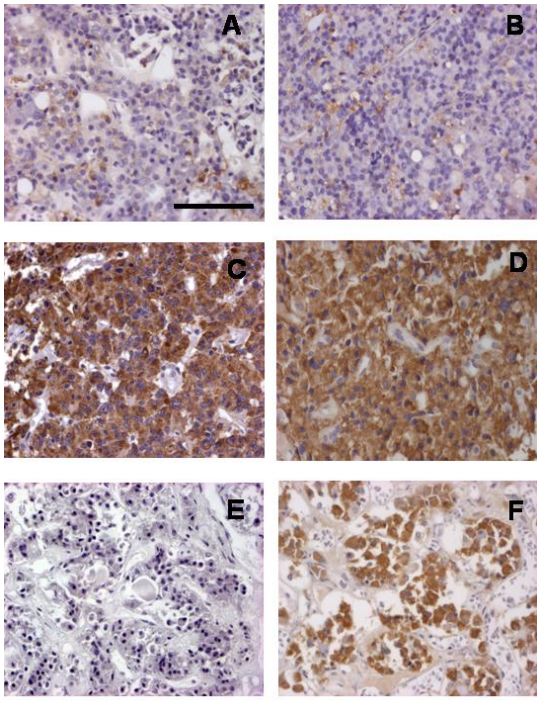

Figure 3. Aryl hydrocarbon receptor interacting protein (AIP) immunostaining. A and B – Examples of low AIP expression; C and D: Examples of high AIP expression; E - Normal human pituitary (negative control); F – Normal human pituitary (positive control); Scale bar = 1000 μm.

6.1.4. miRNA expression levels in patients with low or high AIP protein expression

Based on *in silico* predictions, we selected 11 miRNAs for analysis by real-time qPCR: let-7a, let-7b, miR-202, miR-22, miR-34a, miR-34c, miR-449b, miR-510, miR-612, miR-639 and miR-671 (Table 11). Two miRNAs showed higher expression in tumors with low AIP protein levels compared to tumors with high AIP protein levels (Figure 4): miR-22 [fold change compared to normal pituitary, low AIP protein 1.97 (range 0.25-6.89) vs. high AIP protein 0.78 (range 0.13-9.78), P=0.046] and miR-34a [low AIP protein 1.50 (range 0.28-3.37) vs. high AIP protein 0.55 (range 0.08-4.96), P=0.022]. Nine out of 13 tumors (69%) with low AIP expression exhibited high miR-34a levels [i.e. higher than median (0.72) of the whole group]. There was no difference in the expression of the other miRNAs between tumors with low or high AIP protein levels (Figure 4).

Table 11. The 11 miRNAs selected to analyse the expression level in patients with low or high AIP protein expression and the criteria for selection

miRNA	Criteria for selection
Let-7a	Reachs all three miRNAmap criteria
Let-7b	Reachs all three miRNAmap criteria
miR-202	Two miRNAmap criteria and Pearson coefficient of -0.32
miR-22	Two miRNAmap criteria and Pearson coefficient of -0.33
miR-34a	Two miRNAmap criteria and Pearson coefficient of -0.31
miR-34c	Two miRNAmap criteria and Pearson coefficient of -0.43
miR-449b	Reachs all three miRNAmap criteria
miR-510	Two miRNAmap criteria and Pearson coefficient of -0.50
miR-612	Reachs all three miRNAmap criteria
miR-639	Reachs all three miRNAmap criteria
miR-671	Reachs all three miRNAmap criteria

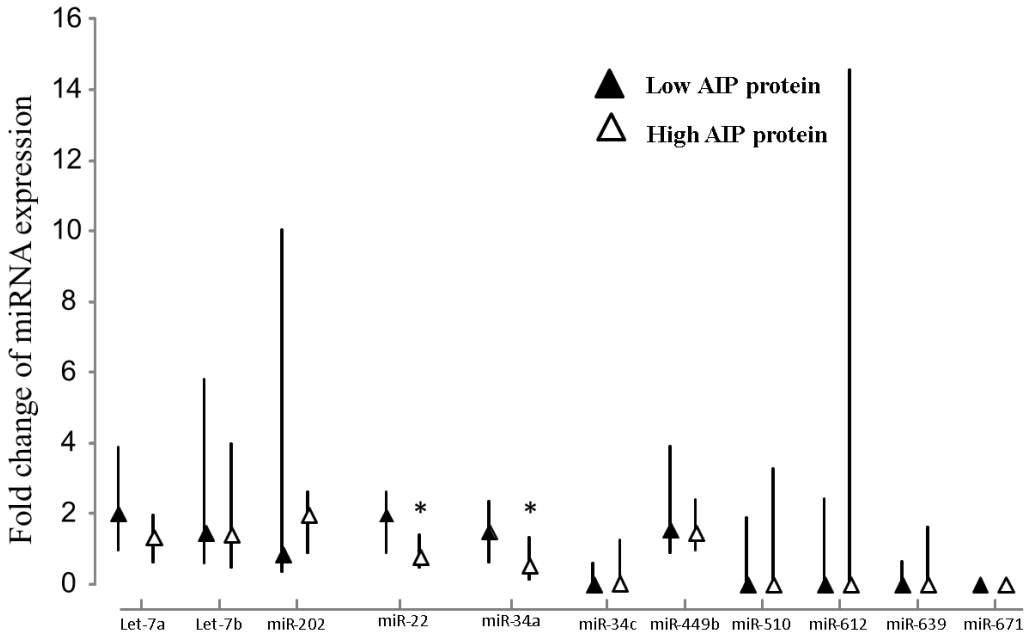

Figure 4. Expression levels of miRNAs predicted to bind *AIP* as determined by quantitative RT-PCR in human somatotroph adenomas with low (black triangles) and high (white triangles) AIP protein levels. Results are expressed as fold change compared to normal pituitary samples and are shown as median with upper and lower quartile; *, $P<0.05$.

6.1.5. Correlation of AIP expression, miR-22 and miR-34a levels with tumor invasiveness, granulation pattern and response to somatostatin analogues

Eleven out of 13 (85%) somatotropinomas with low AIP protein expression were invasive while 6 out of 18 (33%) somatotropinomas with high AIP expression were invasive ($P=0.006$) [Table 10]. The miR-34a levels did not differ significantly in

invasive (1.30, range 0.12 – 3.37) and in non-invasive somatotropinomas (0.47, range 0.08 – 4.96) (*P*=0.19).

Cytokeratin pattern was analyzed in 25 tumors. Eleven out of 25 somatotropinomas (44%) were classified as sparsely granulated. Nine (82%) sparsely granulated adenomas were invasive while only five (36%) densely granulated adenomas were considered invasive (*P*=0.027). Eight out of 11 (73%) tumors with low AIP expression are sparsely granulated adenomas while only three out of 14 (21%) adenomas that presented a high AIP expression are sparsely granulated (*P*=0.015). The miR-34a levels were 1.50 (range, 0.28 – 3.37) in sparsely granulated adenomas and 0.55 (0.08 – 4.96) in densely granulated adenomas, with a tendency to reach statistical difference (*P*=0.058).

A total of 26 patients were initiated on OCT-LAR after surgery. In 10 patients (38%) acromegaly was considered controlled after OCT-LAR therapy. Only one out of nine patients (11%) whose tumors presented low AIP expression achieved disease control with medical treatment, while nine out of 17 patients (53%) harboring tumors with high AIP expression achieved disease control with OCT-LAR therapy (*P*=0.045). The miR-34a levels were lower in those patients controlled with OCT-LAR therapy than in the uncontrolled patients [0.14 (range 0.08 – 4.96) and 1.12 (range 0.72 – 2.19), respectively, *P*=0.003].

There was no correlation of miR-22 levels with tumor invasiveness, granulation pattern or response to OCT-LAR therapy.

6.1.6. miR-34a and miR-22 predicted binding sites in the human *AIP*-3'UTR

FindTar predicted three different target seed regions for miR-34a in the human *AIP*-3'UTR sequence: site A, site B and site C, located respectively at 25-29 bp, 35-40 bp and 46-50 bp downstream of the stop codon of *AIP* (Figure 5). Site B was predicted also by Microcosm. miRanda and FindTar predicted miR-34a to bind to the rat *Aip*-3'UTR sequence as well. miRanda predicted that miR-22 has one binding site, located 42-47 bp downstream of the stop codon of human *AIP*.

DOI:10.14753/SE.2015.2110

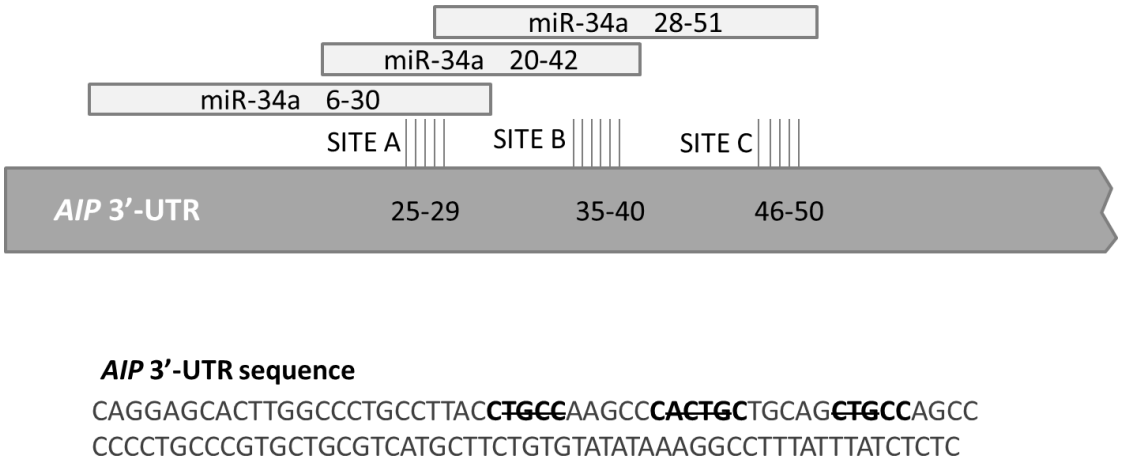

Figure 5. Graphic representation of the three predicted target sites of miR-34a in *AIP*-3'UTR (untranslated region). The highlighted sequences represent the three predicted binding sites (SITE A, B and C) and the basepairs marked with strikeout represent the deleted nucleotides in MUT_A, MUT_B and MUT_C plasmids.

6.1.7. miR-34a effect on regulation of AIP expression *in vitro*

To verify the *in silico* predicted interaction between miR-34a and miR-22 and *AIP*, we used a pGL3 vector containing the human wild type *AIP*-3'UTR downstream of the coding sequence of Firefly luciferase. Transfection of pre-miR-34a precursor and WT-*AIP*-3'UTR into GH3 cells resulted in a 31±4% reduction of luciferase activity compared with the control scrambled miR ($P<0.0001$) (Figure 6). To confirm that this effect was caused by miR-34a interaction with the cloned fragment and not by nonspecific binding, we compared the effect exerted by the pre-miR-34a precursor and the scrambled miR on the empty pGL3 vector. miR-34a did not change the luciferase activity of the empty vector compared with the control scrambled miR (Figure 7). As the endogenous level of miR-34a in GH3 cells was low (Figure 8), we predict that the endogenous miR-34a did not interfere significantly in our experimental setting. Transfection of pre-miR-22 precursor and WT- *AIP*-3'UTR into GH3 cells resulted in no reduction of the luciferase activity (172±14% increase in luciferase activity $P<0.0001$).

DOI:10.14753/SE.2015.2110

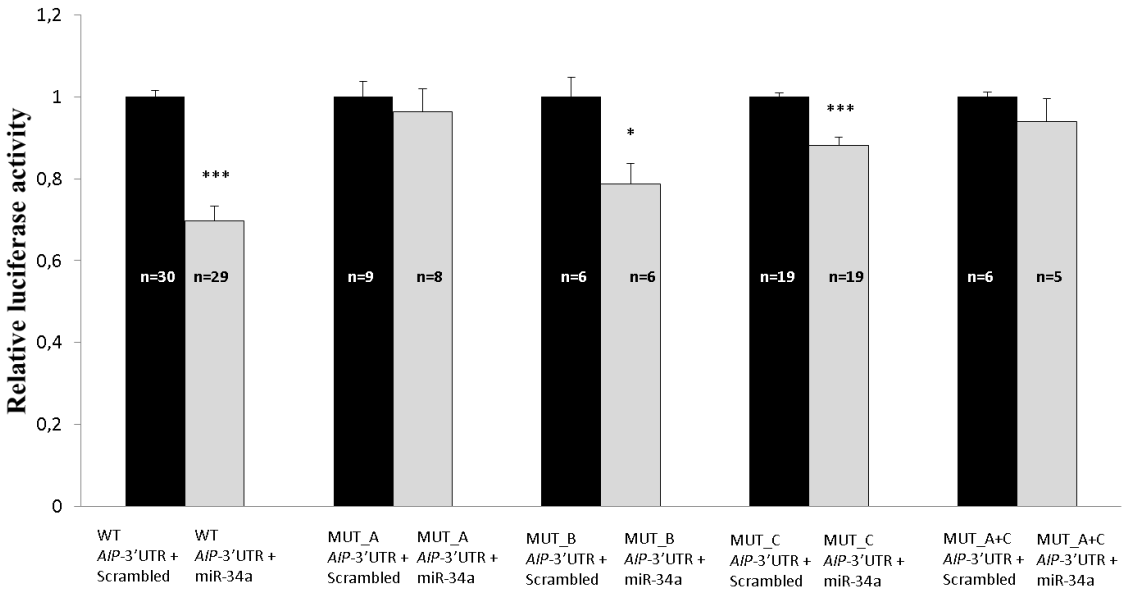

Figure 6. The effect of miR-34a on *AIP*-3'UTR activity *in vitro*. GH3 cells were transfected with plasmids containing pGL3-*AIP*-3'UTR WT and constructs with mutation in SITE A, SITE B, SITE C and SITE A+C and co-transfected with miR-34a or scrambled control. Data are shown as Firefly/Renilla activity ratios compared to that of the scrambled control transfected cells. Mean ±SEM, *, $P<0.05$, ***, $P<0.001$.

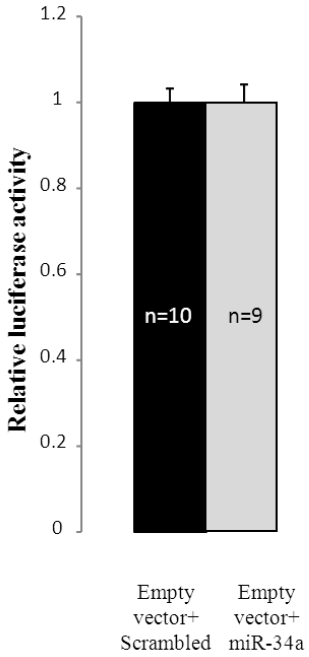

Figure 7. GH3 cells transfected with empty pGL3 vector and miR-34a or its scrambled control. Data are shown as Firefly/Renilla activity ratios compared to that of the scrambled miR transfected cells. Mean ±SEM.

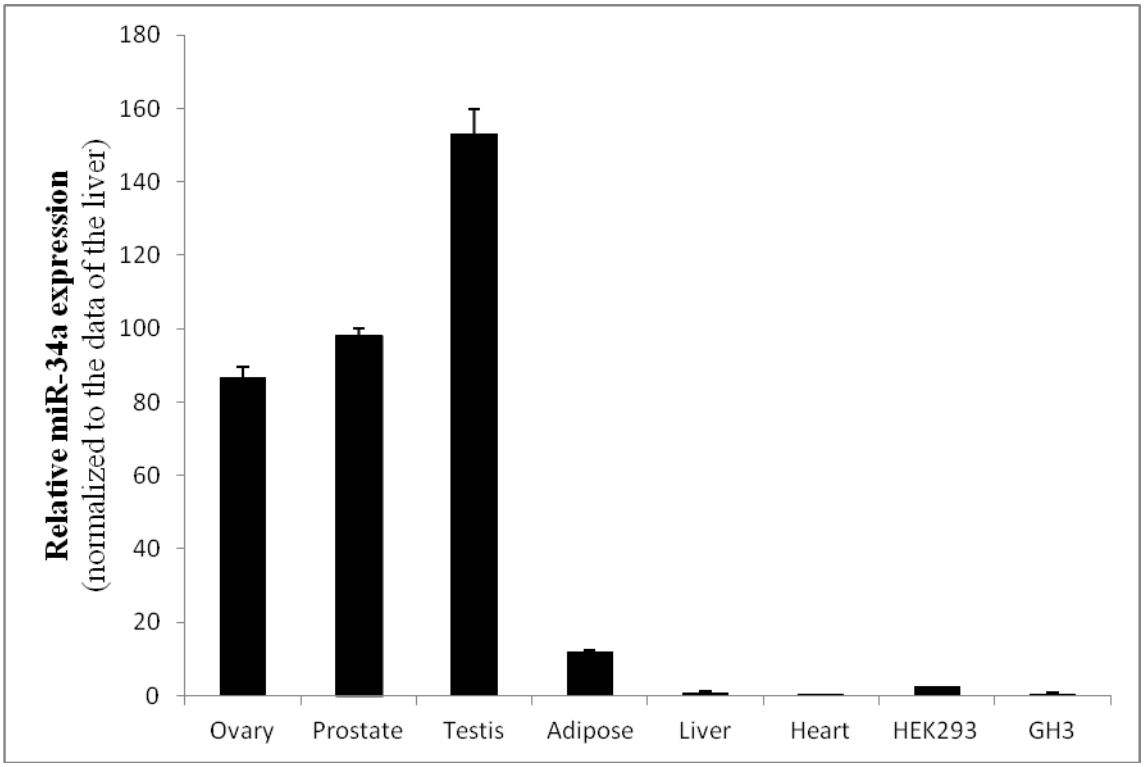

Figure 8. Endogenous miR-34a expression levels in different tissues and cell lines assessed in triplicates by RT-qPCR. Data were normalized to the data of the liver and shown as mean ±SEM.

6.1.8. Confirmation of predicted miR-34a binding sites

To confirm the importance of miRNA binding and to investigate which predicted binding site of miR-34a is involved in the miR-34a effect we used deletion mutants targeting the three different bindig sites: MUT_A for the mutated binding site A, MUT_B for site B and MUT_C for site C. MUT_A leads to a complete loss of miR-34a effect on luciferase activity (Figure 6), while MUT_B did not change the inhibitory effect of miR-34a on the luciferase assay (Figure 6). Although MUT_C overall did not change significantly the inhibitory effect of miR-34a, in some of the experiments a small effect was observed. Therefore we created a combined mutant of site A and site C: MUT_A+C. The data with the combined mutant was similar to the one with MUT_A only (Figure 6).

6.1.9. Regulation of endogenous AIP expression by miR-34a *in vitro*

To further characterize the interaction of miR-34a and *AIP in vitro* we measured mRNA and protein levels of endogenous AIP after miR-34a overexpression and inhibition in HEK293 cells. Significant decrease in AIP protein level was observed 48h post-transfection with miR-34a compared to scrambled miR control (n=7, 17±3%, *P*=0.001, Figure 9 A), suggesting that high levels of miR-34a can suppress endogenous AIP protein expression *in vitro*. Transfection with anti-miR-34a did not change AIP protein levels (n=3, 0±7%, *P*=0.998, Figure 9 B). We have also observed a significant decrease in endogenous AIP protein levels in GH3 cells after miR-34a overexpression (n=4, 25±1%, *P*=0.0005, Figure 9 C).

Although miR-34a overexpression induced a significant decrease in endogenous AIP protein levels, no significant change was seen at the mRNA level in HEK293 and GH3 cells, matching observations in our human adenomas. After miR-34a overexpression in HEK293 and GH3 cells we have observed no significant change in AIP mRNA levels compared to scrambled miR control (Figure 9 D, 9 E).

DOI:10.14753/SE.2015.2110

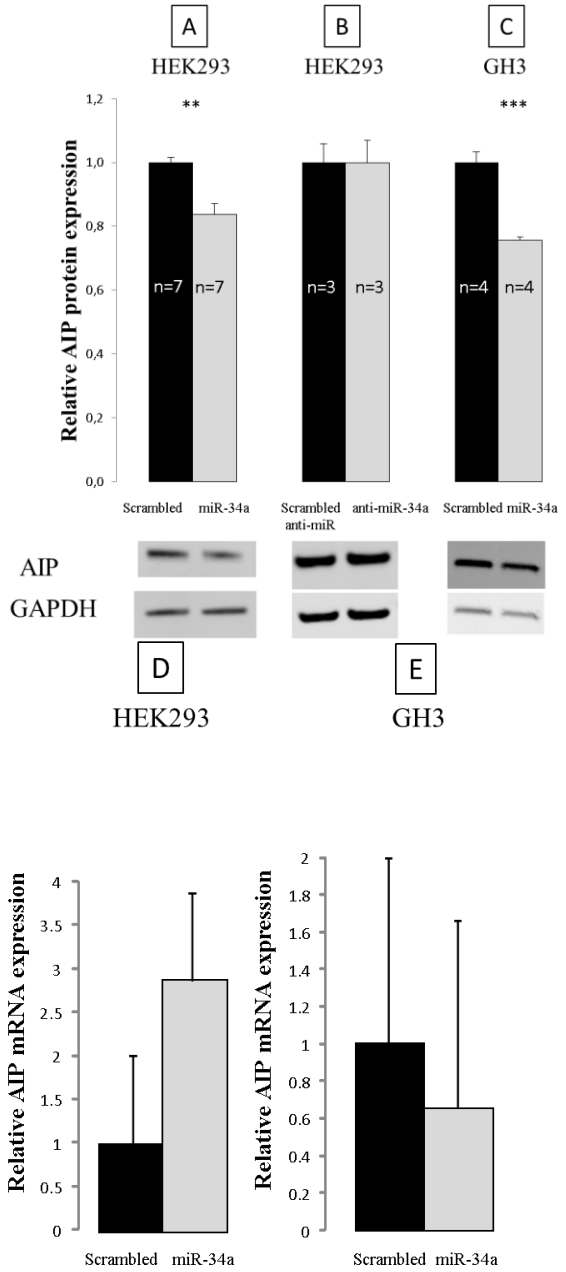

Figure 9. Effect of miR-34a (A) and anti-miR-34a (B) on endogenous AIP protein levels in HEK293 and in GH3 (C) cells 48 hours after transfection. Effect of miR-34a on endogenous AIP mRNA expression in HEK293 (D) and in GH3 (E) cells 48 hours after transfection measured by RT-qPCR. Data are shown as mean±SEM, **, $P<0.01$ ***, $P<0.001$

6.1.10. The effect of miR-34a on cell proliferation and colony formation

To determine the biological effect of miR-34a overexpression, we investigated its effect on cell proliferation and colony formation in BXPC3 and GH3 cells. Using a cell proliferation assay we observed a significant increase in the number of living cells in culture 24h and 48h post-transfection (13±3% P=0.007, 9±5% P=0.02), and an almost significant difference (P=0.055) 72h post-transfection (Figure 10).

The wound-healing assay was used to study cell migration *in vitro.* Although the wound seemed to heal faster in case of BXPC3 cells transfected with miR-34a compared to scrambled control, there was no significant difference in cell migration (Figure 11).

Colony formation assay was used to determine the clonogenic ability of transiently transfected GH3 cells. Although GH3 cells transfected with miR-34a showed increased clonogenic capacity compared to cells transfected with scrambled control, the difference was not significant (Figure 12).

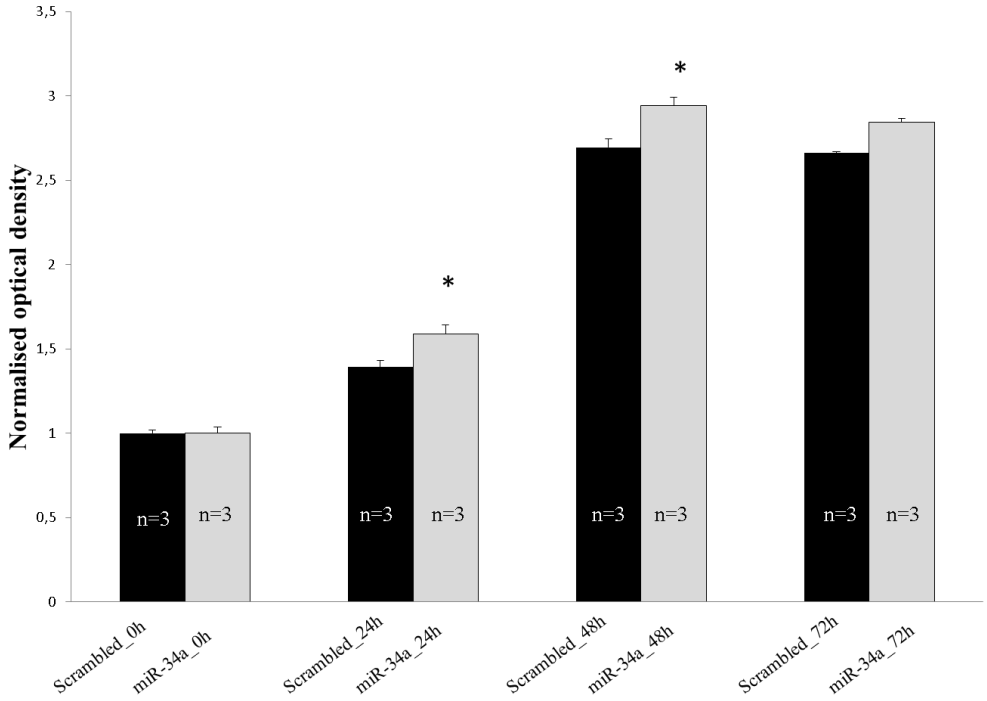

Figure 10. Effect of miR-34a on the number of living BXPC3 cells in culture 24h, 48h and 72h post-transfection.*, P<0.05

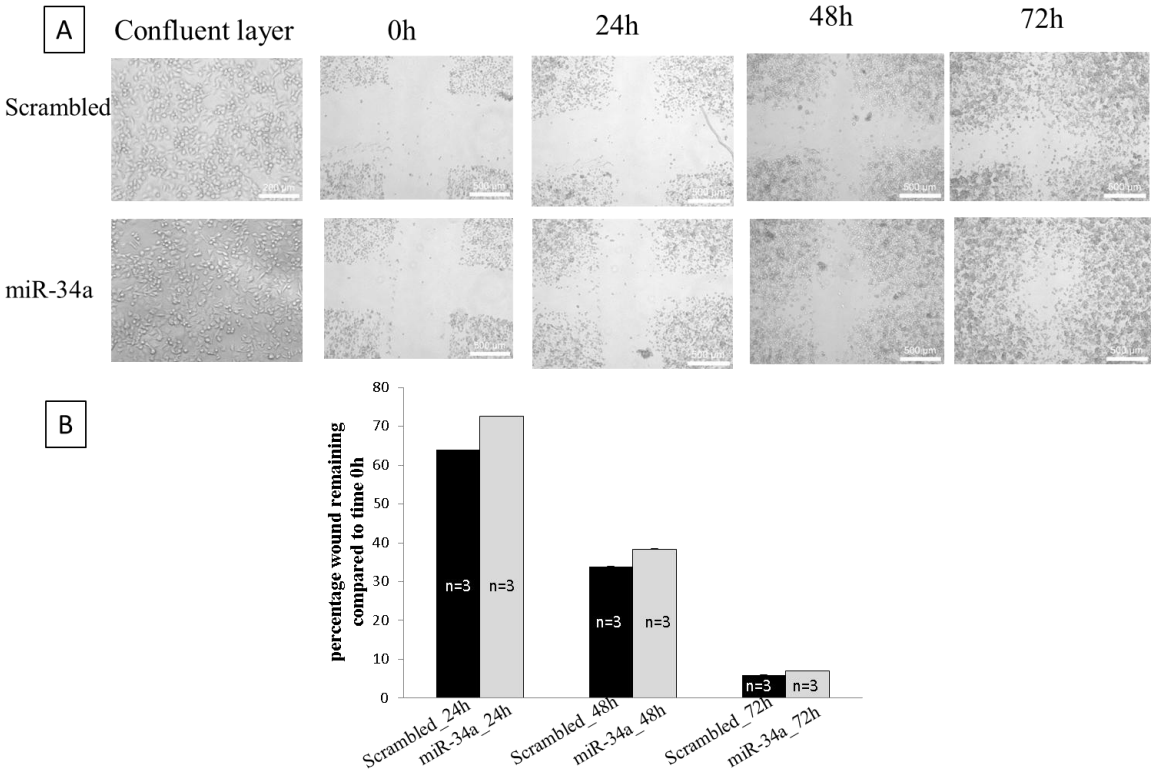

Figure 11. Effect of miR-34a on cell migration 24h, 48h and 72h post-transfection. (A) Representative pictures of wound closure in BXPC3 cells transfected with miR-34a or its scrambled control. (B) Percentage wound remaining compared to time 0h; 24h, 48h and 72h post-transfection. Data are shown as mean±SEM.

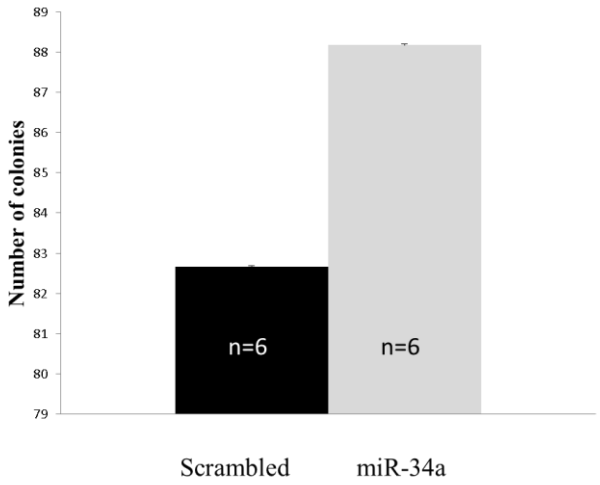

Figure 12. Effect of miR-34a on the clonogenic ability of transiently transfected GH3 cells. Cells were transfected with miR-34a or its scrambled control. Data are shown as mean±SEM.

6.2. Study II

6.2.1. Clinical data

We identified 39 patients with sporadic (n=19) or familial (n=20 from 8 families) pheo/PGL and pituitary adenoma. The gender distribution did not differ significantly (*P*=0.6) in our cohort (18 males, 21 females) compared to the control group (12 males, 11 females). The mean age at diagnosis was 43.7±18.2 years (mean ± SD) for pituitary adenoma and 47.2±15.6 years for pheo/PGL (Table 12). There was no significant difference in age of onset of pituitary adenomas compared to the control group (35±15.4; *P*=0.08). In the pituitary adenoma-pheo/PGL cohort, comparing patients with and without mutation, no difference was identified in the age at diagnosis of the pituitary adenoma [mutation positive group (n=12) 43.4±18.9 years vs mutation negative group (n=16) 44.8±17.1, *P*=0.8] or in the age of diagnosis of the pheo/PGL [mutation positive group (n=15) 46.7±14.3 years vs mutation negative group (n=14) 48.4±19.7 years, *P*=0.8].

Nineteen patients had both pheo/PGL and pituitary adenoma, while a further 20 patients had pheo/PGL or pituitary adenoma in a setting detailed below. In two families (Families 1&6) the proband had both pituitary adenoma and pheo/PGL, while other family members had either pituitary adenoma or pheo/PGL. In 5 families the pituitary and pheo/PGL tumors occurred in the same family but not in the same individual. One patient with a *VHL* mutation and a family history of clear cell renal tumor and multiple hemangioblastomas had a pituitary adenoma presenting at 15 years (no typical VHL manifestations at this stage) (173). Two patients with *MEN1* mutations had a pheochromocytoma. One patient had acromegaly due to a GHRH-secreting pheochromocytoma (206).

The majority of PAs were lactotroph adenomas (n=15), but somatotroph (n=6), clinically non-functioning (n=5, four of them showing positive FSH, LH or alpha-subunit immunostaining) and corticotroph (n=1) adenomas were also seen. Twenty patients had macroadenomas and 4 patients had a microadenoma (for 3 patients pituitary

adenoma size was not available). There was no significant difference (*P*=0.8) in the pituitary adenoma size compared to the control group. Therapeutic modalities for pituitary disease included surgery, medical therapy (cabergoline or bromocriptine and somatostatin analogues) or radiotherapy. Twelve patients needed only one therapeutic intervention, 4 patients needed two, 3 patients needed three, 3 patients needed four and one patient needed five different therapeutic interventions (for 3 patients information on treatment modality was not available). One patient developed pituitary apoplexy.

Sixteen patients had pheochromocytomas and 14 patients had PGLs, of which 12 were head and neck PGLs (HNPGL) and two were abdominal (retroperitoneal) PGLs.

DOI:10.14753/SE.2015.2110

Table 12. Patient cohort with pheo/PGL+pituitary adenoma and their clinical details

Family	Patient	Sex	Diagnosis	Age at diagnosis	Family history	Mutation	Size of pituitary adenoma/ Location of Pheo/PGL	LOH	Staining	Therapy
1	1 (207)	M	Prolactinoma +PGL	Pit: 33y PGL: 33y	Mother: Prolactinoma Brother: PGL	*SDHB* c.298T>C p.Ser100Pro	Macro+SSE+apoplexy Head&Neck	LOH at *SDHB* locus in the pituitary adenoma	H&E staining of the pituitary adenoma: intracytoplasmic vacuoles	Pit: Cabergoline (2nd)+surgery (1st) PGL: Surgery
	2	F	Prolactinoma	35y		c.298T>C	Macro		H&E staining of the pituitary adenoma: intracytoplasmic vacuoles	Surgery
	3	M	PGL	42y		c.298T>C	Head&Neck			Surgery
2	4	F	NFPA+PGL	Pit: 53y PGL: 28y	Sister: glioma	*SDHB* c.587G>A p.Cys196Tyr	Macro+SSE Head&Neck	LOH at *SDHB* locus in the pituitary adenoma	H&E staining of the pituitary adenoma: intracytoplasmic vacuoles SDHB staining: diffuse cytoplasmic blush and lack true granularity	Pit: Surgery (3x) + radiotherapy PGL: Radiotherapy
3	5	F	Prolactinoma	31y	Grandmother's first cousin PGL	*SDHB* del ex 6 to 8	Macro	LOH at *SDHB* locus in the pituitary adenoma	H&E staining of the pituitary adenoma: intracytoplasmic vacuoles SDHB staining: loss of expression of SDHB	Surgery (2x)+Cabergoline (after the 1st surgery)+radiotherapy
	6	M	PGL	58y		*SDHB* del ex 6 to 8	Head&Neck			NA
4	7	F	Prolactinoma +PGL	60y	not known	*SDHB* c.423+1G>A	Macro+SSE Head&Neck			Pit: Cabergoline+ pituitary tumour was kept in the trajectory of glomus tumor radiotherapy PGL: radiotherapy
5	8	F	Abnormality on pituitary MRI+ + pheo + adrenal cortical hyperplasia	50y	not known	*SDHB* c.770dupT p.Asn258GlufsTer17	Pheo		pheo of the left and macronodular hyperplasia of the right adrenal gland	Surgery

DOI:10.14753/SE.2015.2110

Table 12. Patient cohort with pheo/PGL+pituitary adenoma and their clinical details – cont.

Family	Patient	Sex	Diagnosis	Age at diagnosis	Family history	Mutation	Size of pituitary adenoma/ Location of Pheo/PGL	LOH	Staining	Therapy
6	9	M	Prolactinoma + PGL	Pit: 53y PGL: 38y, 45y	Brother: PGL Cousin: NFPA	*SDHC* c.380A>G p.His127Arg	Macro Head&Neck			Pit: Cabergoline PGL: surgery
	10	M	PGL	59y		c.380A>G	Head&Neck			Radiotherapy
	11	M	NFPA	~55y		No mutation!	Macro			Surgery
7	12	F	Multiple PGL	42y	Father: PGL Sister: pituitary adenoma	*SDHD* c.242C>T p.Pro81Leu	Head&Neck			Surgery
	13	M	PGL	NA	As above	c.242C>T	Head&Neck			NA
	14	F	Prolactinoma	32y		No mutation!	Micro			Bromocriptine
8	15	M	NFPA + PGL + Wilms tumor + retroperitoneal liposarcomas + renal oncocytoma	Pit: 53y PGL: 50y	Father: NFPA	*SDHA* variant c.969C>T p.= (p.Gly323Gly)	Macro/ abdominal PGL	no LOH at *SDHA* locus in the pituitary adenoma	H&E staining of the pituitary adenoma: intracytoplasmic vacuoles SDHA and SDHB staining: SDHA and B are preserved	Pit: surgery PGL: surgery
	16	M	NFPA	44y, 74y		tumor DNA sample - negative for *SDHA* c.969C>T	Macro		H&E staining of the pituitary adenoma: intracytoplasmic vacuoles SDHA and SDHB staining: SDHA and B are preserved	Surgery (2x) + radiotherapy
9	17	M	Pheochromocytoma	44y	mother: Cushing disease	*SDHB* variant c.80G>A p.Arg27Gln	Pheo	LOH at *SDHB* locus in the pheo	no loss of SDHB expression in the pheo	Surgery
	18	F	Cushing disease	51y		no	Macro			Bilateral adrenalectomy
10	19	M	Acromegaly+ PGL	Pit: 84y PGL: 84y	not known	*SDHAF2* variant c.-52T>C	Macro Head&Neck			SSA (good IGF-1 response)

DOI:10.14753/SE.2015.2110

Table 12. Patient cohort with pheo/PGL+pituitary adenoma and their clinical details – cont.

Family	Patient	Sex	Diagnosis	Age at diagnosis	Family history	Mutation	Size of pituitary adenoma/ Location of Pheo/PGL	LOH	Staining	Therapy
11	20 (173)	M	GH+PRL positive PA	15y	Mother, mat. aunt and grandmother: VHL	*VHL* c.340G>C p.Gly114Arg	Macro+SSE	no LOH at *VHL* locus in the PA	H&E staining of the pituitary adenoma: no intracytoplasmic vacuoles	Surgery (2x) (1st, 3rd)+ Radiotherapy (4th)+Cabergoline(2nd)+SSA (5th)
12	21	F	Prolactinoma + pheo	Pit: 27y Pheo:NA	not known	*VHL* c.589G>A (p.Asp197Asn) *SDHA* c.91C>T p.Arg31Ter*** *AIP*, *MEN1* and *CDKN1B* are not available	Size:NA Pheo			NA
13	22	M	GH+PRL-secreting PA + Pheo + Hyperparatyhroidism + Carcinoid tumor	Pit: 27y Pheo: 31y	not known	*MEN1* c.1452delG p.Thr557Ter	Macro Pheo	LOH at *MEN1* locus in the pheo	menin staining of the pheo: no menin positive cells	Pit: Surgery (1st)+ raditoherapy (2nd)+Bromocriptine/Cabergoline (3rd) Pheo: surgery
14	23	M	Pheo + Parathyroid hyperplasia + pancreatic neuroendocrine tumors	Pheo: 36y	Father: renal calculi	*MEN1* c.783+1G>A	Pheo	LOH at *MEN1* locus in the pheo	menin staining of the pheo: some weakly positive staining nuclei	Surgery

DOI:10.14753/SE.2015.2110

Table 12. Patient cohort with pheo/PGL+pituitary adenoma and their clinical details – cont.

Family	Patient	Sex	Diagnosis	Age at diagnosis	Family history	Mutation	Size of pituitary adenoma/ Location of Pheo/PGL	LOH	Staining	Therapy
15	24 (208)	F	Acromegaly + pheo + gastrointestinal stromal tumour + thyroid follicular adenoma	Pit: 56y Pheo: 66y	not known	no	Macro Pheo			Pit: Surgery+Bromocriptine+SSA +radiotherapy Pheo: surgery
16	25	F	Acromegaly + pheo	Pit: 39y Pheo: 20y	not known	no	Macro Pheo			Pit: Surgery+radiotherapy+SSA Pheo: Surgery
17	26	F	NFPA + PGL	Pit: 73y PGL: 73y, 76y	not known	no	Macro Head&Neck			Pit: Surgery+radiotherapy PGL: Radiotherapy
18	27	F	Acromegaly + pheo	Pit: 16y Pheo: 16y	not known	no	Macro Pheo			Pituitary infarction Pheo:NA
19	28	M	Prolactinoma + PGL	Pit: in 40's PGL:52 y	not known	no	Macro Head&Neck			Pit: Surgery PGL: NA
20	29	F	Prolactinoma + pheochromomocytoma	Pit: 27y Pheo: 41y	not known	no	Size:NA Pheo			NA
21	30	M	Pheo/PGL + PA		not known	no	NA			NA
22	31	F	Prolactinoma + pheo	Pit: 40y Pheo: 38y, 44y	not known	no	Micro Pheo			Pit: Bromocriptine Pheo: Surgery

DOI:10.14753/SE.2015.2110

Table 12. Patient cohort with pheo/PGL+pituitary adenoma and their clinical details – cont.

Family	Patient	Sex	Diagnosis	Age at diagnosis	Family history	Mutation	Size of pituitary adenoma/ Location of Pheo/PGL	LOH	Staining	Therapy
23	32	F	Pheochromocytoma + hyperparathyroidism	64y	maternal aunt: acromegaly	no	Pheo			Surgery
	33	F	acromegaly	NA			NA			NA
24	34	M	Prolactinoma + pheo	Pit: 56y Pheo: 56y	not known	no	Micro Pheo			Pit: Dopamine agonist Pheo: Surgery
25	35	F	Prolactinoma + pheo	Pit: 61y Pheo: 61y	not known	no	Macro Pheo			Pit: Cabergoline Pheo: Surgery
26	36	F	Acromegaly	28y	daughter: Prolactinoma son: PGL	no	Macro			Surgery, bromocriptine
	37	F	Prolactinoma	24y			Micro			Cabergoline
	38	M	PGL	19y			Abdominal			Surgery
27	39 (206)	F	GHRH-secreting pheo	51y	not known	no	Pheo		GHRH staining of the pheo: positive	Surgery

PA: pituitary adenoma, M: male, F: female, pit: pituitary, SSE: suprasellar extension, H&E: hematoxylin and eosin., NA: not available

*This variant affects a highly conserved basepair and amino acid. This amino acid change has been described in a patient with Cowden syndrome.

**This variant may effect the promoter, but no functional studies are available to show this

*** this variant has been described in polycythemia vera but not in classical VHL syndrome

6.2.2. Genetic screening

Germline alterations were identified in *SDHA*, *SDHB*, *SDHC*, *SDHD*, *SDHAF2*, *VHL* and *MEN1* genes in 19 patients with pheo/PGL and/or pituitary adenomas. Fourteen of the 19 patients who harbored a genetic variant were index patients. All patients harbored one gene mutation except one patient who had a *VHL* mutation and an *SDHA* variant of unknown significane. Twenty patients (including 10 harboring both pheo/PGL and pituitary adenoma) had no identifiable mutations in any of the genes tested (Table 13 and Table 12). None of the patients in our cohort had *AIP* or *CDKN1B* mutations.

Table 13. Genes tested in pheo/PGL+pituitary adenoma patient cohort

Genes	**Number of patients with sequence variant**	**Sequence variant**	LOH in the pituitary adenoma	LOH in the pheochromocytoma
SDHA	2 (2 variants)°	c.969C>T (p.Gly323Gly) c.91C>T (p.Arg31Ter)	**no LOH**	Not tested
SDHB	9 (8 mutations and 1 variant)	c.298T>C (p.Ser100Pro) c.587G>A (p.Cys196Tyr) *SDHB* del ex 6 to 8 c.423+1G>A c.770dupT (p.Asn258GlufsTer17) variant: c.80G>A (p.Arg27Gln)	**3 LOH**	Tested and identified in 1 case
SDHC	2 (2 mutations)	c.380A>G (p.His127Arg)	**NA**	Not tested
SDHD	2 (2 mutations)	c.242C>T (p.Pro81Leu)	**NA**	Not tested
SDHAF2	1 (variant)	c.-52T>C	**NA**	Not tested
VHL	2°	c.340G>C (p.Gly114Arg) c.589G>A (p.Asp197Asn)	**no LOH** *	Not tested
MEN1	2	c.1452delG (p.Thr557Ter) c.783+1G>A	Not tested	**2 LOH**
RET	0			
TMEM127	0			
MAX	0			
FH	0			
AIP	0			
CDKN1B	0			

NA: not available

* LOH is not obligatory in VHL-related tumors (209)

6.2.2.1. *SDHX* mutation

We identified 11 kindreds (including 16 patients) with germline *SDHX* variants (Table 12). Seven families had a pathogenic *SDH* mutation, while 4 had a variant of unknown significance. All patients with *SDHX* mutations/variants had a pituitary macroadenoma. In the pituitary adenomas, where suitable sample was available, we identified the loss of the wild-type allele in the adenoma sample compared to the germline DNA (Figures 13, 14 and 15). In particular, Patient 5 was interesting where the germline mutation was a large deletion affecting exon 6-8 of the *SDHB* gene, while in the tumor sample the whole gene was deleted with no detectable exon 6-8 and a reduced amount of the other exons.

We identified 2 *SDHA* variants of unknown significance. One of these (c.969C>T, p.Gly323Gly) was identified in a patient (Patient 15) with a Wilms tumor (at the age of 1y), retroperitoneal liposarcomas (32y and 40y), a PGL in the retroperitoneum (50y), a renal oncocytoma (50y) and an NFPA (53y). His father had an NFPA operated at 44y and again at 74y. *In silico* splicing analysis software packages predicted that this variant may create a new splice donor site. RNA was extracted from peripheral blood but RT-PCR analysis found no evidence of aberrant splicing of the *SDHA* gene. Sequence analysis of DNA extracted from a paraffin embedded pituitary adenoma sample from this patient showed the presence of this variant with no evidence of loss of the normal allele in the tumor DNA when compared to the peripheral blood DNA. Tissue extracted from the father's NFPA did not harbor the variant, while it was present in the germline DNA of the mother, suggesting that it is not the cause of NFPA in father and son. Its role in the proband's other tumors is unknown. The other *SDHA* variant was identified in a patient with a *VHL* mutation and pituitary adenoma (Patient 21). We have also identified an *SDHB* variant (c.80G>A p.Arg27Gln, Patient 17) of unknown significance. We have tested the proband's pheochromocytoma and showed LOH at the *SDHB* locus; however, the SDHB staining of the pheochromocytoma did not show loss of SDHB expression. No pituitary tissue was available for testing in this family.

An *SDHAF2* variant c.-52T>C was identified in a patient with somatotroph macroadenoma and head & neck PGL. The patient was not operated upon and therefore no tissue is available.

We identified two families with *SDH* mutations where a family member with a pituitary adenoma did not carry the germline *SDHX* mutation: Family 6 - two *SDHC* mutation positive siblings had pituitary adenoma and/or PGL, while a first cousin had an NFPA but no *SDHC* mutation, and Family 7 – the parent and child both with *SDHD* mutation positive PGL and

another child with a microprolactinoma but no *SDHD* mutation (Figure 16). These cases are either phenocopies or could, theoretically, be explained by a digenic disease pattern where the second disease causing gene has not been identified.

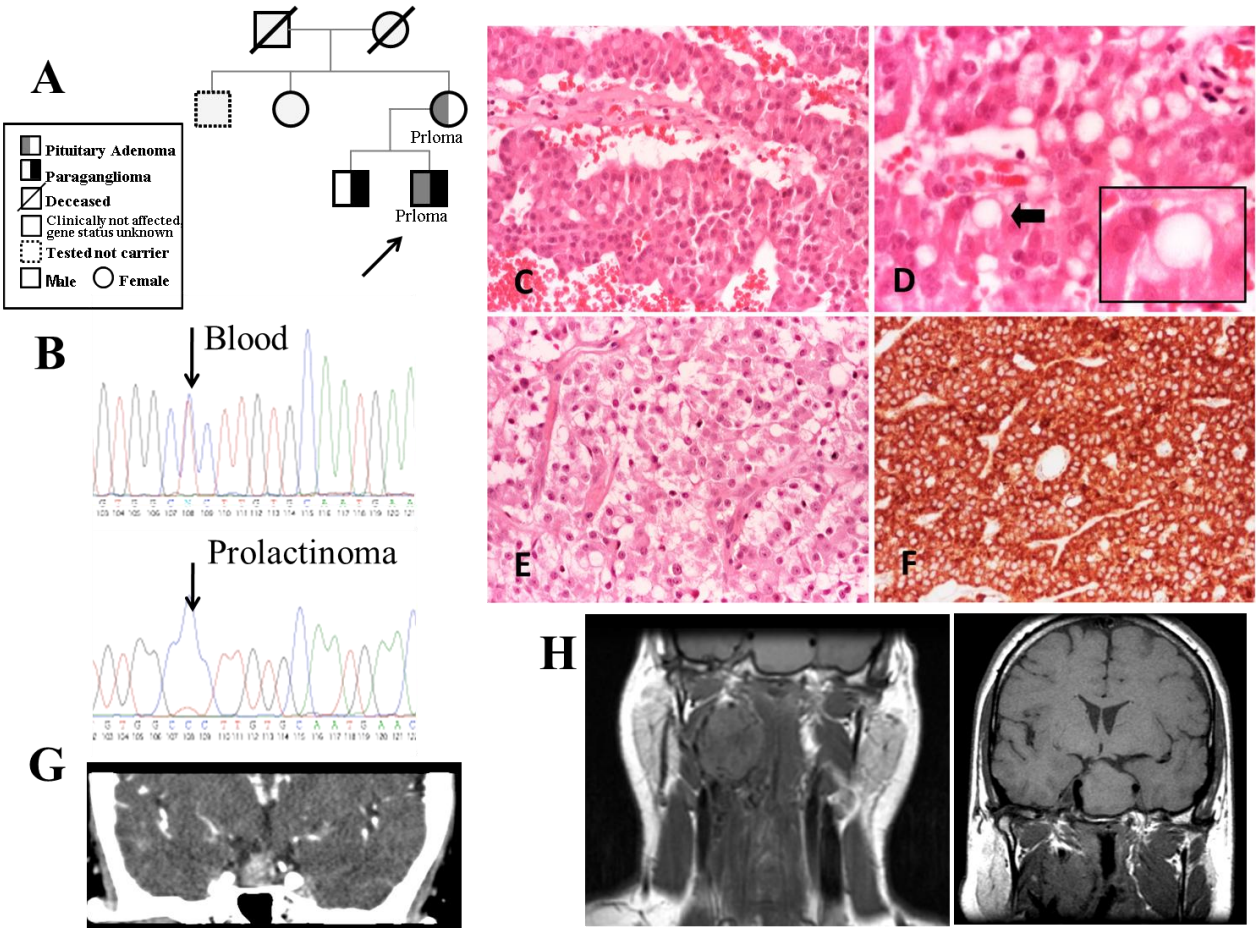

Figure 13. (A) pedigree and (B) loss of heterozygosity at *SDHB* locus in the pituitary adenoma of Patient 1 in Family 1; (C) H&E staining of the pituitary adenoma of the proband (Patient 1 in Family 1) shows predominant trabecular architecture (20x); (D) vacuoles at times filling the entire cytoplasm characterise this case (arrow) (H&E, 40x). (E) H&E staining (20x) of the pituitary adenoma of the proband's mother (Patient 2 in Family 1) also shows similar intracytoplasmic vacuoles; (F) the immunoreaction with the anti-113-1 antibody (immunoperoxidase, 20x) shows the mitochondria content. (G) MRI imaging of proband's mother's pituitary adenoma (H) MRI imaging of the proband's pituitary adenoma and glomus vagale tumor.

DOI:10.14753/SE.2015.2110

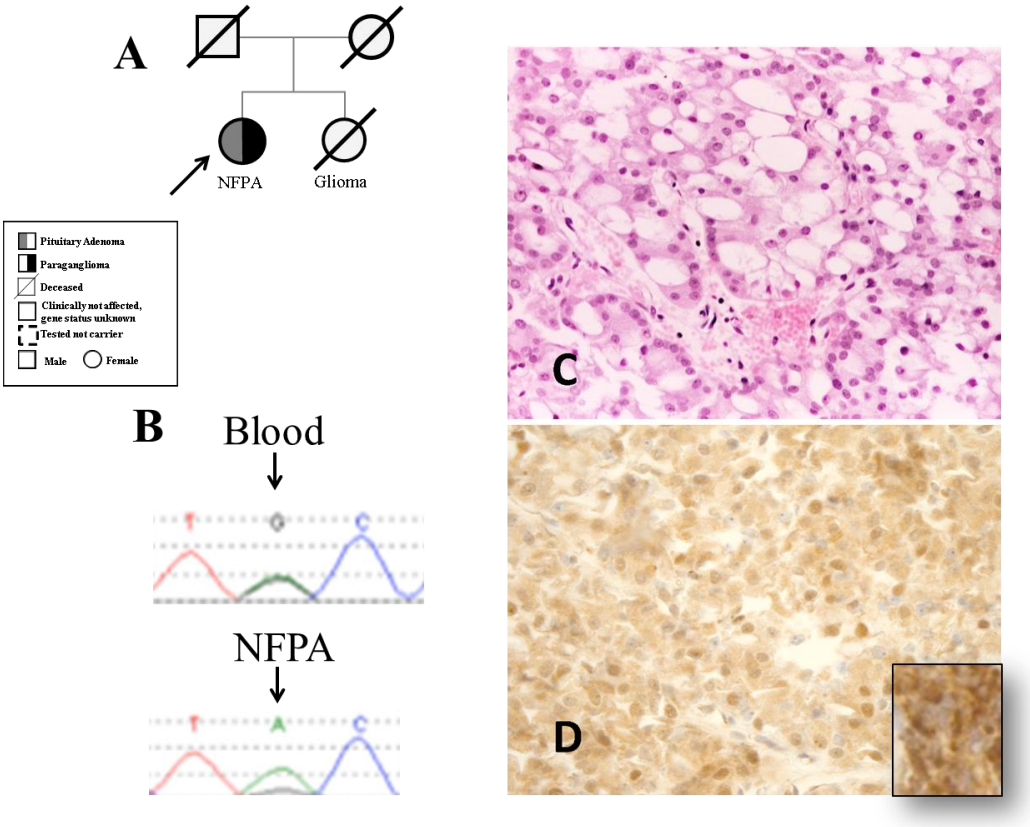

Figure 14. (A) pedigree and (B) loss of heterozygosity at *SDHB* locus in the pituitary adenoma of Patient 4, microsatellite upstream of the mutation has also shown to be lost; (C) H&E-stained section (x20) of this adenoma shows prominent vacuolar changes in the majority of neoplastic cells; the cytoplasm otherwise appears weakly eosinophilic; (D) *SDHB* staining suggesting lack of strong granular staining of the pituitary adenoma of the proband (immunoperoxidase, x20) (inset: positive SDHB staining as positive control in a paraganglioma).

DOI:10.14753/SE.2015.2110

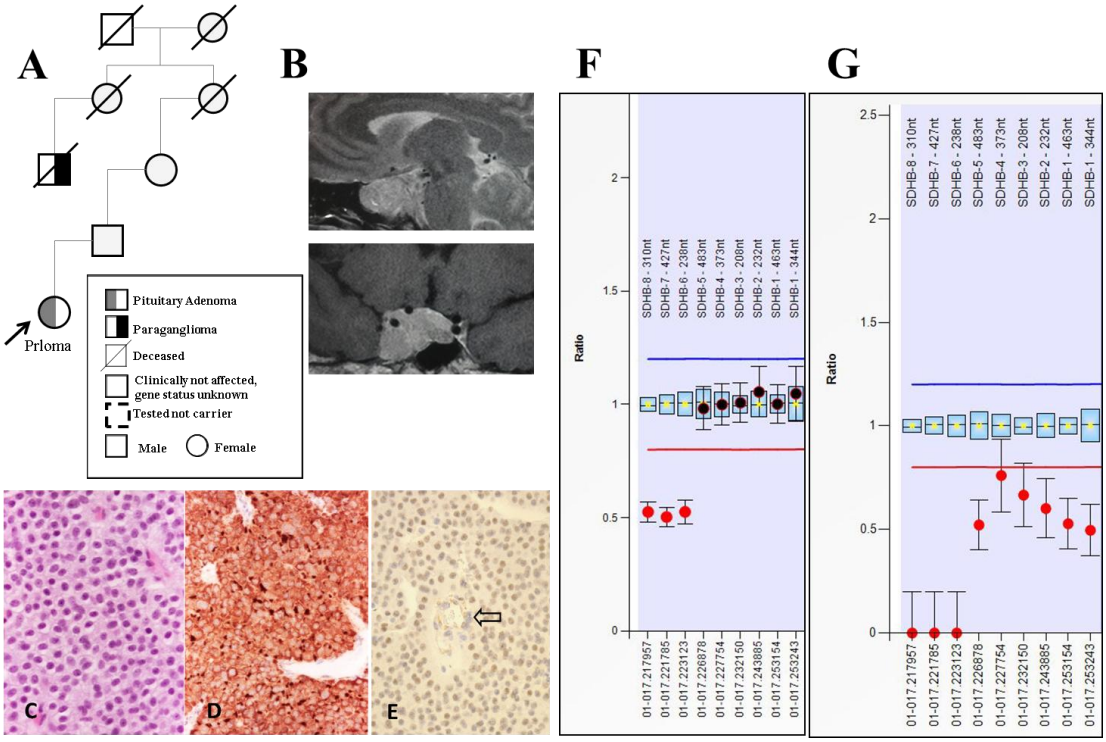

Figure 15. (A) pedigree and (B) sagittal and coronal MR images of the pituitary adenoma. (C) H&E stained section (x20) shows that the tumor of Patient 5 contains multiple vacuoles. (D) the immunoreaction with the anti-113-1 antibody (immunoperoxidase, 20x) highlights the mitochondria content. (E) SDHB immunostaining shows loss of expression in neoplastic cells while endothelial cells (arrow) retain the expression (immunoperoxidase, x20). Loss of *SDHB* gene in germline and pituitary tumor tissue in Patient 5: (F) Germline DNA shows a deletion affecting MLPA *SDHB* probes 6-8 in DNA derived from leukocytes (G) In pituitary adenoma tissue complete loss of genetic material at the *SDHB* probe 6-8 area and heterozygous loss of *SDHB* probe 1-5.

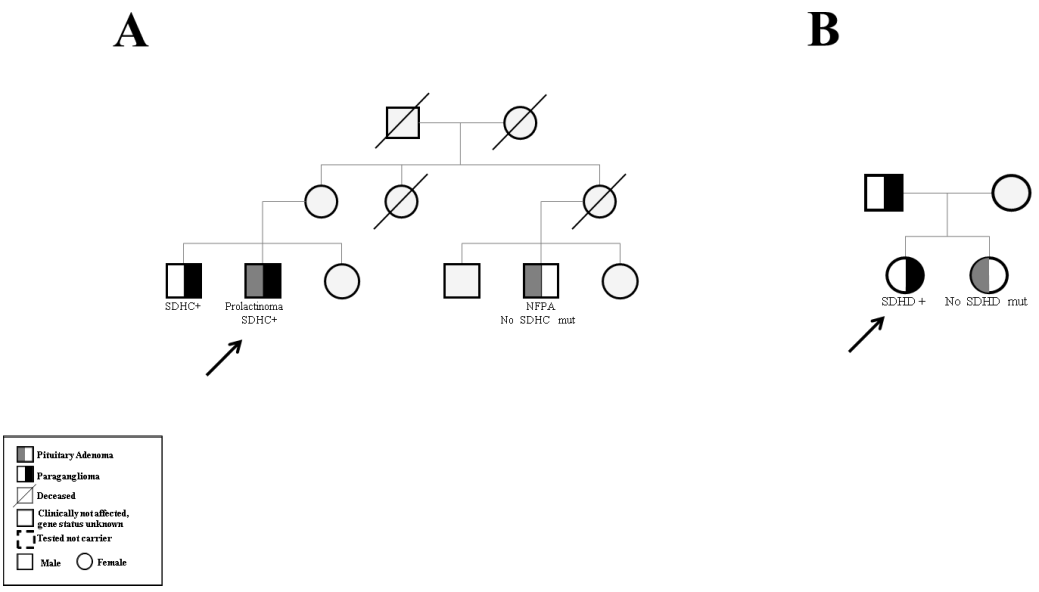

Figure 16. (A) pedigree of Family 6 and (B) Family 7. Family 6, the proband with glomus jugulare tumor was operated twice and 8 years later he was diagnosed with a macroprolactinoma. His brother had a glomus tumor and his first cousin had a clinically nonfunctioning pituitary macroadenoma showing LH/FSH staining on histopathology. The proband and his brother have a novel missense *SDHC* mutation c.380A>G (p.His127Arg), while their cousin is negative for the mutation therefore representing a phenocopy. The proband's prolactinoma is controlled on dopamine agonist therapy therefore no tissue is available for LOH testing at the *SDHC* locus. Patient 12 from Family 7 had multiplex PGLs, her father had a PGL (carotid body tumor), and her sister had a pituitary tumor. The proband, and her father harbor the same heterozygous missense mutation in exon 3 of the *SDHD* gene (c.242C>T, p.Pro81Leu), while her sister is negative for the mutation, therefore this also represents a phenocopy.

6.2.2.2. *VHL* mutation

An 18-year old patient with a pathogenic *VHL* mutation (c.340G>C, a missense mutation affecting a surface amino-acid (172)), had an invasive GH- and PRL-positive pituitary adenoma as shown in Table 12 and Figure 17 (173).

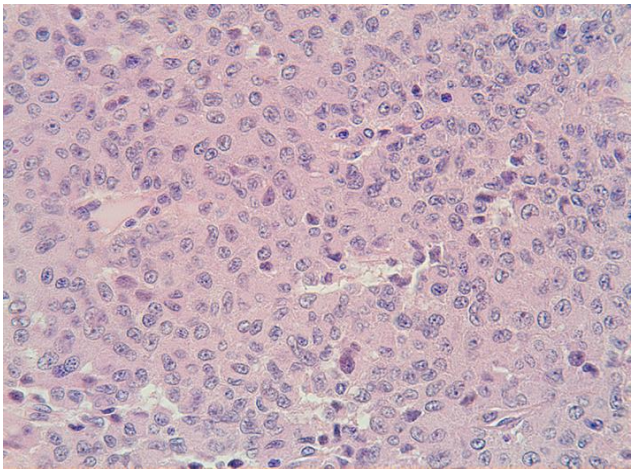

Figure 17. H&E staining (40x) of the pituitary adenoma of Patient 20 with *VHL* mutation shows no cytoplasmic vacuoles.

6.2.2.3. *MEN1* mutation

We identified two patients (Patient 22 and 23) with germline *MEN1* mutation and pheochromocytoma, while all the other tested genes were normal (Table 12). Both pheochromocytomas showed LOH in the *MEN1* gene supporting, although not proving, the pathogenic role of *MEN1* in these tumors (Figure 18). Although the association of pheo/PGLs and an MEN1-like syndrome has been described in the literature in 13 cases, in only 4 of these have *MEN1* mutations been identified (99, 112, 113) and none of them has previously been studied for LOH in the pheochromocytoma tissue.

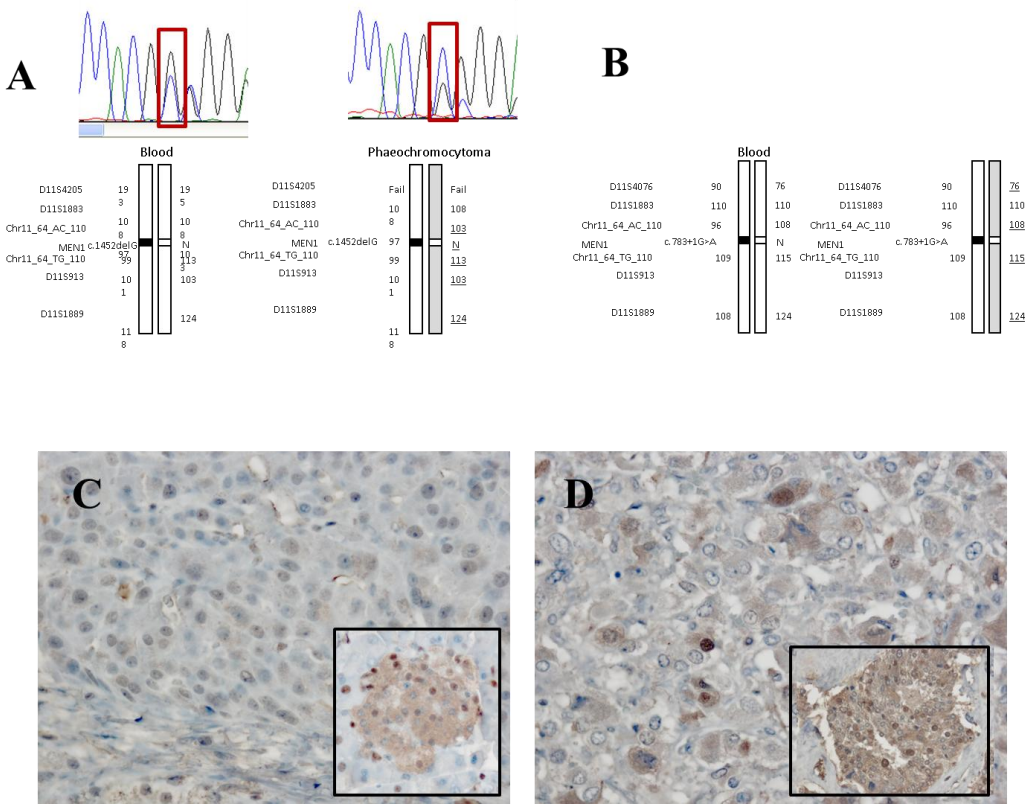

Figure 18. (A) LOH analysis at *MEN1* locus of the pheochromocytoma of Patient 22 and (B) Patient 23. Underlined microsatellite results identify markers which show a reduction in peak height in the pheochromocytoma sample compared to blood, indicating LOH but suggesting that some non-tumoral tissue was also retained in the operated samples. (C) Pheochromocytoma of Patient 22 shows loss of menin staining (inset: positive menin staining in mouse Langerhans islet); (D) the menin staining of the pheochromocytoma of Patient 23 shows some weakly positive staining nuclei (inset: positive menin staining in a sporadic pheochromocytoma used as a positive control).

6.2.2.4. Control patients

We studied 23 *MEN1*, *AIP* and *CDKN1B* -negative FIPA family probands without features of Carney complex or a personal or family history of pheo/PGL (Table 14). We analyzed their DNA for all the pheo/PGL-related genes included in our panel to investigate the role of these genes in FIPA families. No pheo/PGL-related gene mutations were found in these families.

Table 14. Clinical data of control patients

Sex	Diagnosis	Age at diagnosis	Size of pituitary adenoma	Family history
F	PRLoma	30y	Macro	Father: PRLoma
F	PRLoma	23y	Macro	Paternal aunt: PRLoma
M	PRLoma	39y	Macro	First cousin: PRLoma
M	PRLoma	20y	Macro	Brother:PRLoma
M	Acromegaly	21y	Macro	Half sister: acromegaly
F	Acromegaly	28y	Macro	Grandfather: acromegaly
F	Acromegaly	38y	Macro	Cousin: acromegaly
M	Acromegaly	25y	NA	First cousin: acromegaly
M	Acromegaly	54y	Macro	Nephew: acromegaly
F	Acromegaly	28y	Micro	Daughter: acromegaly
F	NFPA	63y	NA	Brother: NFPA
M	NFPA	24y	NA	Half brother: NFPA
M	NFPA	57y	NA	Mother: NFPA
M	Acromegaly	21y	Micro	Father:NFPA
F	NFPA	40y	NA	Sister: acromegaly
M	NFPA	51y	Macro	Sister: PRLoma, paternal uncle: acromegaly
F	PRLoma	NA	NA	Grandfather: NFPA
M	PRLoma	50y	Macro	Mother:acromegaly
F	PRLoma	22y	NA	Mother: acromegaly
M	Acromegaly	23y	NA	First cousin: PRLoma
M	Acromegaly	68y	Macro	Nephew: PRLoma
F	PRLoma	20y	Macro	Grandson: acromegaly
F	PRLoma	25y	NA	Brother: acromegaly

M: male, F: female, NA: not available

6.2.3. Pathological features

The pituitary adenomas of patients with *SDHX* mutations (Patient 1&2 from Family 1, Patient 4 and Patient 5) were characterized by intracytoplasmic vacuoles. The extent of vacuolization was not related to the histological type (prolactinoma or NFPA) of the tumor (Figure 13, 14 and 15). The number of vacuolated cells varied from about 50% to 80% of the neoplastic cell population. Vacuoles ranged from small and multiple (Figure 15 C) to large occupying most of the cytoplasm and mimicking signet-ring cells (Figure 14 C). None of the vacuoles indented the nucleus as commonly seen with accumulation of lipids. One case showed focal oncocytic changes identifiable on the HE-stained sections. The histochemical stain periodic acid of Schiff (PAS)/diastase-resistant PAS (DPAS) did not reveal any glycogen accumulation. Vacuoles were not seen in the pituitary adenoma of the patient with the germline *VHL* mutation (without *SDH* mutation) (Figure 17). The SDHB staining of pituitary adenomas with *SDHB* mutation showed either loss of expression of SDHB or faint expression (Figure 14 D and Figure 15 E).

As *SDHX* mutations are known to alter mitochondrial function, immunostaining was performed for a mitochondrial membrane protein with the anti-113-1 antibody. This staining documented variable accumulation of mitochondria in *SDHX* mutation-positive pituitary adenoma cells. Some adenomas in particular showed increased immunostaining compared to the other cases (Figure 13 F and 15 D) in keeping with the focal oncocytic changes observed in the HE-stained sections. Vacuoles did not appear to be rimmed by this protein suggesting that vacuolization is not secondary to dilatation of mitochondria. To understand if vacuoles were the result of swelling of the endoplasmic reticulum (ER), we immunostained our samples for the ER marker ERLEC1. None of the vacuoles was lined by this protein indicating that they were not releated to the ER (Figure19). We used electron microscopy to further study the nature of vacuoles. Interpretation of ultrastructural features of the tissue retrived from paraffin was limited by suboptimal preservation. The cytoplasm appeared to contain large empty vacuoles unrelated to mitochondria and no obvious membrane were identified to rim vacuoles.

Menin staining of the pheochromocytoma samples of patients with *MEN1* mutations showed either no menin positive cells or weakly positive staining nuclei (Figure18).

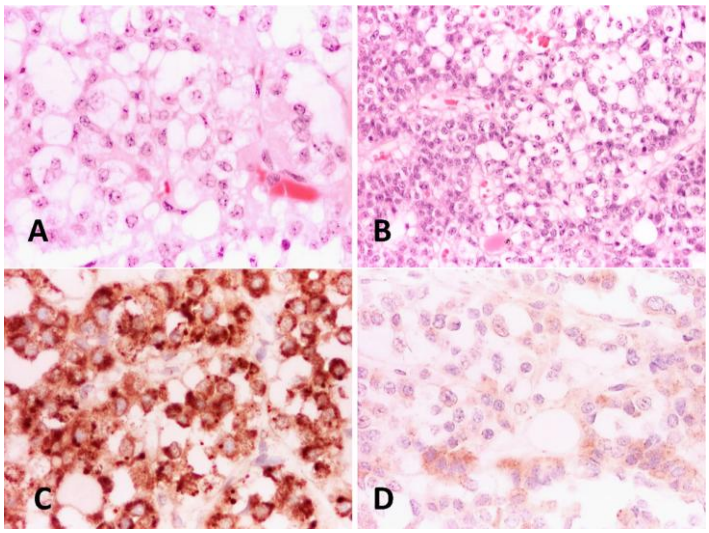

Figure 19. (A) Pituitary adenoma of Patient 15 is composed of nests and trabeculae of cells with weakly eosinophilic or clear cells with vacuolar cytoplasm; vacuoles are variable in size, single or multiple (H&E, x20); (B) regions of the tumor show much less prominent clear cell changes (H&E, x10). (C) The immunoreaction with anti-113-1 antibody demonstrates variability in mitochondrial content; there is no convincing evidence that vacuoles are rimmed by mitochondrial membranes (immunoperoxidase, x20); (D) similarly, vacuoles are not rimmed by endoplasmic reticulum, as shown with the immunoreaction for ERLEC1 (immunoperoxidase, x20).

7. Discussion

7.1. Study I

In this study we showed that low AIP protein levels in human sporadic somatotropinomas are associated with high miR-34a expression and that miR-34a can down-regulate AIP protein levels in *in vitro* experiments. In addition, we showed that high miR-34a levels are associated with a lower chance of acromegaly control with SSA therapy and we confirmed our previous findings (192) that low AIP protein expression is associated with a poor response to SSA. Our data demonstrates that the inhibition involves AIP translation repression without reduction in AIP mRNA, as there was no difference in the AIP mRNA levels between tumors with low or high AIP protein levels. Thirteen out of 31 (42%) tumor samples showed low AIP protein levels (score 1-2 out of 1-6), a percentage similar to the data previously published by Jaffrain-Rea et al. (48%) (179) and also by Kasuki et al. in two different sets of samples (55% and 51%) (178, 192). Most of the tumors exhibiting low AIP expression (with or without germline *AIP* mutations) were invasive (178, 179), and patients harboring those tumors have a poor response to the medical treatment with SSAs, the mainstay of the medical treatment of acromegaly (192). Recent data suggest that the expression of AIP is important in the mechanism of action of this class of drugs (181, 210). In addition, we showed that the majority of the tumors showing low AIP expression are sparsely granulated adenomas. Tumors with this cytokeratin pattern are known to be more invasive and associated with a poor response to SSA therapy (211). Therefore, one of the possible explanations for this adenoma phenotype is the low AIP expression in these tumors.

As our data showed that there is no correlation between AIP mRNA expression and protein levels, we hypothesized that the low AIP protein levels could be explained by miRNA regulation. Therefore, we studied the miRNAs predicted to regulate the *AIP* gene. After a careful selection using *in silico* prediction, we studied 11 miRNAs. Although miR-107 has been previously shown to inhibit *AIP in vitro* (201), this miRNA did not fulfill the strict selection criteria in this study and was not included in the analysis. Out of our selected 11 miRNAs, two (miR-22 and miR-34a) were significantly

overexpressed in the tumors with low AIP protein levels. We note that our sample size is the largest to date of the studies concentrating on miRNA expression in somatotropinomas. According to our results, we hypothesized that these miRNAs could be responsible for the reduced AIP levels. Our findings showed that miR-34a down-regulates AIP protein levels, while miR-22 had no inhibitory effect. We also showed that higher miR-34a levels are associated with a lower chance of disease control with SSA therapy. Therefore, elucidation of the mechanism involved in reducing AIP protein levels in sporadic somatotropinomas may help to predict response to SSAs and help with the development of novel therapeutic options for the treatment of this subgroup of invasive tumors.

To study the effect of miR-34a on AIP we have used a reporter vector in which the entire human *AIP*-3'-UTR has been fused to a luciferase reporter plasmid. We observed that high levels of miR-34a reduce the luciferase activity using the vector containing the WT *AIP*-3'UTR suggesting that miR-34a can bind to the *AIP*-3'UTR. To validate the three predicted target sites for miR-34a within the 3'-UTR of human *AIP* we created mutants for each predicted miR-34a binding sites. MUT_B and MUT_C plasmids exerted a significant inhibitory effect on the luciferase activity, similar to the wild-type plasmid, suggesting that these sites are not important for miR-34a binding. SITE_A plasmid, however, failed to induce inhibition of luciferase activity, suggesting that this binding site is responsible for miR-34a-mediated AIP repression. To study the regulation of endogenous AIP expression by miR-34a *in vitro* we have used rat GH3 cells and human HEK293 cells. We found that overexpression of miR-34a significantly decreases AIP protein levels measured 48h after transfection, while there was no significant change in AIP mRNA levels. When we transfected the cells with anti-miR-34a we could not see any change in AIP protein levels, which might be due to the fact that these cell lines have very low endogenous miR-34a levels therefore antagonism with anti-mir-34a may not produce detectable effects (Figure 8). We have attempted to see if cells would proliferate more when transfected with miR-34a. In MTS assay we have detected significant difference in the number of living cells 24h and 48h after transfection. Regarding the migration and clonogenic ability of transiently transfected GH3 or BXPC3 cells, although a trend was observed, this has not reached significance.

The miR-34 family consists of three miRNAs: miR-34a, miR34b and miR-34c. miR-34b and -34c share a common primary transcript (located on chromosome 11q23), while miR-34a is encoded by its own transcript on chromosome 1p26 (212). miR-34a is an intergenic miRNA located between the genes coding for the G-protein coupled receptor 157 and hexose-6-phosphatase dehydrogenase (212). Recent miRNA profiling analysis did not find differences in overall miR-34a expression in somatotropinomas compared to normal pituitary (213, 214). This is in line with our findings that showed that miR-34a was overexpressed only in tumors with low AIP expression, but not in all somatotropinomas. There were a few cases with high miR-34a level and high AIP expression. We have not identified sequence variants in the 3'UTR of the *AIP* gene in these samples. Therefore as high miR-34 expression does not always correlate with a low AIP protein level, other factors could also influence AIP expression. To elucidate the complex regulation of AIP expression will need future studies.

miRNAs have unique tissue-specific patterns and the same miRNA can behave as an oncogene or tumor suppressor gene depending on their target mRNAs in that particular organ (23, 27). miR-34a has been shown to behave as a tumor suppressor miRNA by reducing proliferation and enhancing apoptosis in many human neoplasias, including osteosarcoma, colorectal, pancreatic and ovarian cancer (215, 216). In contrast, miR-34a has also been shown to have oncomiR properties in other studies, including a pro-proliferative role in follicular lymphoma cell lines and an anti-apoptotic effect in B-lymphoid cells (217, 218). It has also been shown to antagonize the anti-tumoral effects of docetaxel in human breast cancer cells (219). Our data show higher miR-34a levels in human adenomas with low AIP protein levels. In addition, we demonstrated that miR-34a can bind to *AIP* and decrease its expression *in vitro*. Interestingly, miR-34a overexpression in HCT116 human colon carcinoma cells also showed down-regulation of AIP expression (220) (http://www.ncbi.nlm.nih.gov/geoprofiles/39833130), suggesting that the putative role of miR-34a in regulating AIP expression may also be present in other tumors. Patients with loss-of-function *AIP* mutations usually harbor large and invasive somatotropinomas (184, 221). In the absence of mutations, low AIP protein level is associated with a similar phenotype (178, 179). In this study we postulated that miR-34a acts as an oncomiR in somatotropinomas, being an inhibitor of *AIP*, a tumor suppressor gene, and therefore miR-34a might be implicated in the

pathogenesis of these tumors. On the other hand, as miR-34 is involved in a wide range of tumorigenesis, the role of miR-34 on somatotropinomas may not solely rely on AIP.

The involvement of miR-34a in the pathogenesis of sporadic somatotropinomas may allow the development of new therapeutic strategies for the treatment of these tumors. The therapeutic inhibition of miR-34 has previously been attempted in the context of heart disease. This resulted in the attenuation of pathological cardiac remodeling and improvement in heart function in a mouse myocardial infarct model (222). In the same study, the authors used a 15-mer locked nucleic acid (LNA) anti-miR-34a and observed that a single dose in three consecutive days inhibited the miR-34a as early as day one and that the inhibition persisted for two months after the last dose (222). Therefore, future studies addressing the use of LNA anti-miR-34a in the setting of invasive somatotropinomas with low AIP protein levels may provide a new approach for the treatment of these tumors. The use of anti-miRNAs has been previously described in other tumor models, for example, in an orthotopic xenograft breast cancer model with systemically injected liposomes that delivered 2'-O-Me anti-miRNAs against miR-132, resulting in delayed tumor growth and suppressed angiogenesis (223).

7.2. Study II

Syndromic presentation of pituitary adenoma and pheo/PGL is rare and it is not part of the classical multiple endocrine tumor syndromes. This study describes, we believe, the largest cohort of patients with pituitary adenomas & pheo/PGLs. Systematic testing of this population for alterations of the known pituitary and pheo/PGL-related genes suggest that *SDH* mutations play a pathogenic role in the development of pituitary adenomas in some of these patients. Cases of other pheo/PGL genes associated with pituitary adenoma, *VHL* and *RET*, are exceptionally rare. On the other hand, the *MEN1* mutations can sometimes lead to pheo/PGLs, as suggested previously (99, 112, 113), and here we present supporting LOH and immunostaining findings. An endocrine rather than genetic association occurs when pheochromocytomas secrete hypothalamic releasing hormones (GHRH or CRH) mimicking the pituitary adenoma & pheo/PGL syndrome, described previously in 8 cases (Table 6). Although in these cases only the adrenal gland harbors a tumor, while the pituitary usually displays hyperplasia in response to the ectopic hormone secretion, this is a relevant clinical differential diagnostic scenario and should be kept in mind in patients with pituitary disease and

pheo/PGLs. In about half of our cases no germline abnormalities were seen, suggesting either the presence of other disease-causing genes or the coincidental occurrence of the pituitary and pheo/PGL tumors. As this is a multicentric study with a patient cohort from all over the world - with heterogeneous genetic background - it is difficult to estimate whether the coincidence of these two tumors occurred randomly, or other, yet not specified, genetic factors could be playing a role. Using the ranges of the available prevalence data for pituitary adenomas and pheo/PGLs in the general population (2, 3, 129, 130), the coincidental chance for the 2 diseases occurring in the same patient ranges between 1 in 2.5 and 1 in 8.5 million subjects. In the single centre of Barts Hospital we have 828 patients with pituitary tumors and 150 with pheo/PGL (224, 225). Assuming a maximum population frequency of pheo/PGL of 1 in 2500, we predict that 0.33 cases in a population based series of 828 pituitary adenoma patients would have a pheo/PGL, whereas the actual frequency in patients seen at our centre was 2 in 828 (P=0.048; Exact test on single proportions). Likewise, assuming the maximum population frequency of pituitary adenoma of 1 in 1000 (2, 3), we expect 0.06 cases in a population based series of 150 pheo/PGL patients would have a pituitary adenoma, whereas the actual frequency is 2 in 150 (P=0.01). Both of these datasets suggest an increased incidence.

Of the six suggested explanations for the coexistence of pituitary adenoma and pheo/PGL that we outlined in the introduction, we could confirm the following (i) a pheo/PGL-related gene causes pituitary adenoma, (ii) a pituitary gene causes pheo/PGL (v) ectopic hypothalamic hormone synthesis in a pheochromocytoma, and probably one or more families in our cohort match option (vi) representing pure coincidence. Regarding option (iii), we have not found any patients with mutations in two genes, such as a classical pheo/PGL and a pituitary tumor gene. In addition, we found LOH at the *SDH* locus in pituitary adenomas and at the *MEN1* locus in pheochromocytomas suggesting, although not proving, that in these patients a single gene is reponsible for both tumors. Exome or whole genome sequencing studies in the future might find novel genes causing both diseases (option iv). In our cohort 19 patients (48%) had a germline alteration, among them 17 (43%) had a genetic variant in the pheo/PGL genes. Large studies showed that about one third of pheo/PGL patients (most familial cases and 10-20% of the sporadic cases) carry a germline mutation in *RET*, *VHL*, *NF1*, *SDHA*, *SDHB*,

SDHC, SDHD, SDHAF2, MAX or *TMEM127* genes (131, 132), suggesting that our cohort may have a slightly higher percent of germline alterations.

The clinical features of the published cases of the association of pituitary disease and pheo/PGLs are summarized in Table 5, 7 and 8. More recently, three screening studies have been performed. One of them screened a group of patients (26 PGL patients and 8 carriers) with a particular *SDHD* mutation due to a founder effect for the presence of a pituitary adenoma. One GH-secreting macroadenoma and 3 non-functioning microadenomas (suggested to be incidentalomas) were diagnosed in this patient cohort. No LOH was found at the *SDHD* locus in the GH-secreting pituitary adenoma (156). In the second study, 309 pituitary adenomas were screened for *SDH* mutations and a macroprolactinoma with 2 different somatic *SDHA* mutations with normal sequence in the germline (159) was found. In the third study screening has been performed in *SDHX*-mutated patients for non-pheo/PGL tumors. Two patients with *SDHD* mutations were found to have a pituitary adenoma, and in one of these cases LOH at the *SDHD* locus was shown in the macroprolactinoma (157). Whether it is cost effective to measure prolactin in patients with pheo/PGLs needs to be studied further.

Summarizing our cases combined with the cases available in the literature (altogether 109 cases since 1952) we have tried to identify any particular features for each gene alteration for the tumor not classically associated with that gene. Twenty cases have a confirmed *SDHX* mutation with pituitary adenoma; [(2 *SDHA* (60, 159), 8 *SDHB* (152, 153), 2 *SDHC* (158) and 8 *SDHD* (154-157)]. The patients with *SDH* mutation had various pituitary adenoma types (Table 8 and 12): 9 macroprolactinomas, 3 somatotroph adenomas and 5 NFPAs have been described. In 3 cases the pituitary adenoma subtypes could not be classified. All the pituitary adenomas were macroadenomas, except for three non-functioning microadenomas (possibly incidentalomas). The patients needed 1-4 therapeutic interventions. Five patients needed a single therapeutic intervention, 5 patients needed two, 1 patient needed three and 2 patients needed four therapeutic interventions. Of the 109 patients 5 patients had *RET* mutations (145-148); 2 cases with acromegaly, 2 cases with prolactinoma and one NFPA (1 macroadenoma, 1 microadenoma and in 3 cases the adenoma size is not available). Four patients needed one therapeutic intervention (3 surgeries and 1 medical treatment), while one patient needed medical therapy after transsphenoidal resection of the pituitary tumor. Two

patients had a *VHL* mutation (173), one with a PRL- and one with a GH- and PRL-secreting adenoma. Six patients had a confirmed *MEN1* mutation and pheo/PGL (99, 112, 113): 5 patients with pheochromocytoma and one head and neck PGL.

We have identified a novel feature of the pituitary adenomas of patients harboring *SDHX* variants. The adenoma tissues show extensive vacuolization of cytoplasm with features reminiscent of signet-ring cells or physalipherous cells (226). The origin of vacuoles remains unclear. Lipid and glycogen accumulation was suggested in the literature, but none of the vacuoles indented the nucleus as commonly seen in cells with accumulation of lipids and the histochemical stain PAS/DPAS did not reveal any glycogen accumulation. The vacuoles also do not resemble particle-rich cytoplasmic structures (PaCS), described in epithelial neoplasms (227). Vacuolization of the non-tumorous adenohypophyseal cells has been described in cases of fatal hypothermia in two separate studies (228, 229). Ishikawa *et al.* suggested that the vacuoles are different from dilated cisternae of rough ER, and from distended Golgi apparatus which are result of castration or gonadal dysfunction and raised the possibility that they are lipid droplets due to metabolic dysfunction initiated by the hypothermia. Doberentz *et al.* also noted cytoplasmic vacuolation of the anterior pituitary cells in case of hypothermia, and they suggested that this could be due to gradually developing tissue hypoxia. Oncocytic pituitary adenomas have recently been identified to contain somatic mutations affecting mitochondrial respiratory chain complex I, but these tumors do not show the vacuolar changes we have identified in the *SDH*-related samples (230).

Inactivation of succinate dehydrogenase or VHL can lead to activation of the hypoxia inducible factor (HIF) pathway and a pseudohypoxic state. Indeed, it has been shown increased HIF-1α in an *SDHD* mutated case linked to pituitary adenoma (154). It is not known whether the vacuoles seen in the *SDH*-related tumors are due to the pseudohypoxic state, but we did not observe this phenomenon in the *VHL* mutation-related pituitary adenoma (Figure 17).

Immunostaining for a mitochondrial membrane protein or for an ER marker did not prove that the vacuoles arise from these organelles. We attempted electron microscopy to identify the nature of the vacuoles but this was inconclusive due to the poor preservation of formalin-fixed tissue recovered from paraffin (data not shown). These vacuoles were not specifically described in the studies recently published *SDHX*

mutations associated with pituitary adenomas, but based on the available histological pictures, the presence of vacuoles cannot be ruled out (60, 154, 159). Vacuoles have been described in *SDHB* mutation-related renal carcinoma and were attributed to giant mitochondria (231), but the clear cytoplasm observed in these tumors can also represent glycogen or fat (232). Large cytoplasmic vacuoles suggested to be mitochondria based on electron microscopy have previously been described in pituitary adenomas (233), possibly due to ischemia. Acidophil stem cell adenomas can also contain paranuclear vacuoles resulting from giant mitochondria (234).

The activity of certain mitochondrial enzymes involved in oxidative phosphorylation is decreased in cancer cells compared to normal tissue (235). Taking into account that succinate dehydrogenase enzymes - being part of the mitochondrial complex II - play an important role in mitochondrial function, mutations which affect the activity of these enzymes might have a role in mitochondria dysfunction (236). We believe that the vacuoles represent a hallmark of pituitary adenoma in patients with *SDHX* variant but their nature remains to be further investigated. In addition, further study of the metabolic pathways in *SDH*-related endocrine tumors are awaited.

Our study has several shortcomings. First of all, being a specialist pituitary and adrenal center with an interest of familial pituitary adenomas, which might attract more unusual genetic conditions therefore representing higher prevalence of these cases. In a significant portion of the patients tumor samples were not available, often due to lack of surgical intervention, therefore no appropriate material was available to study in further detail the unusual histological phenotype in the pituitary adenomas.

8. Conclusion

8.1. Study I

We have demonstrated that miR-34a is overexpressed in sporadic somatotropinomas with low AIP protein levels in the absence of mutations in this gene and that this overexpression is inversely correlated to the response to SSA. SS-analogues are the mainstay of medical therapy of acromegaly, thus prediction of the responsiveness helps the clinician to decide on the therapy. Tissue SS receptor subtype 2 expression as well as granulation pattern and AIP level correlates with SSA responsiveness. The measurement of miR-34a level could be one of the possible methods to predict the response to this type of medical therapy. Functional studies confirmed that miR-34a down-regulates AIP expression, suggesting the possible involvement of miR-34a in the pathogenesis of sporadic somatotropinomas.

8.2. Study II

Germline mutations were identified in the studied pituitary adenoma or pheo/PGL causing genes in 11/27 kindreds with the combination of pheo/PGL and pituitary adenomas. LOH at the *SDHB* locus in the pituitary adenoma samples and LOH at the *MEN1* locus in the pheochromocytoma samples was demonstrated, suggesting, although not proving, the pathogenic role of these genes in these non classically disease-specific tissues. In addition, we noted intracytoplasmic vacuoles in pituitary adenomas of patients affected by *SDH* mutations. Together with the single case reports available in the literature, this large cohort supports the hypothesis that in some families *SDH* mutations may have a role in pituitary adenoma formation and *MEN1* mutations may have a role in the development of pheochromocytoma. Whether screening for pituitary adenomas in *SDHX* patients is warranted needs to be studied in the future, but our findings suggest that genetic testing for germline mutations in *SDHX* and *MEN1* should be considered in patients with the constellation of pheo/PGLs and pituitary adenomas.

9. Summary

Study I: Patients with germline aryl hydrocarbon receptor-interacting protein *(AIP)* mutations or low AIP protein expression have large, invasive somatotroph adenomas and poor response to somatostatin analogues. To study the mechanism of low AIP protein expression 31 sporadic somatotropinomas with low or high AIP protein expression were analyzed, and no significant difference was observed in *AIP* mRNA expression, suggesting post-transcriptional regulation. Among the 11 miRNAs predicted to bind the 3'UTR of *AIP* miR-34a was highly expressed in low AIP protein samples and miR-34a levels were inversely correlated with response to SSA therapy. Using a luciferase reporter assay, miR-34a inhibited the luciferase-*AIP*-3'UTR construct. Deletion mutants of the predicted binding sites in *AIP*-3'UTR identified the c.*6-30 site to be involved in miR-34a's activity. miR-34a overexpression in HEK293 and GH3 cells resulted in inhibition of endogenous AIP protein expression. **In conclusion**, miR-34a is a negative regulator of AIP-protein expression and could be responsible for the low AIP expression observed in somatotropinomas with an invasive phenotype and resistance to SSA.

Study II: Pituitary adenoma and pheo/PGL can occur in the same patient or in the same family. Thirty-nine cases of sporadic or familial pheo/PGL and pituitary adenomas were investigated. Known pheo/PGL genes (*SDHA-D, SDHAF2, RET, VHL, TMEM127, MAX*) and pituitary adenoma genes (*MEN1, AIP, CDKN1B*) were sequenced. Eleven germline mutations (5 *SDHB*, 1 *SDHC*, 1 *SDHD*, 2 *VHL* and 2 *MEN1*) and four variants of unknown significance (2 *SDHA*, a *SDHB*, and a *SDHAF2)* were identified. Tumor tissue analysis identified loss of heterozygosity at the *SDHB* locus in 3 pituitary adenomas and at the *MEN1* locus in 2 pheochromocytomas. All the pituitary adenomas of patients affected by *SDHX* alterations have a unique histological feature showing vacuolarized cells, not previously described in this context. **In conclusion**, mutations in the genes known to cause pheo/PGL can rarely be associated with pituitary adenomas, while mutation in a gene predisposing to pituitary adenomas (*MEN1*) can be associated with pheo/PGL. Our findings suggest that genetic testing should be considered in all patients or families with the constellation of pheo/PGL and pituitary adenoma.

10. Összefoglalás

I. vizsgálat: Azoknál a betegeknél, akiknél aryl hydrocarbon receptor-interacting protein (AIP)-mutáció van jelen, vagy az AIP fehérje szintje alacsony, a szomatotropinomák nagyobbak, invazívak és kevésbé reagálnak szomatosztatin- (SS-) analóg terápiára. 31 sporadikus, *AIP*-mutációt nem hordozó szomatotropinomát vizsgáltunk, amelyek esetében az AIP fehérje szintje eltérő volt. Az *AIP* mRNS szintjében nem volt szignifikáns különbség, ami alapján felmerült, hogy az AIP fehérje poszt-transzkripciós expresszióját microRNS-ek szabályozzák. Az *AIP* 3'UTR-hoz előrejelzetten kötődő 11 miRNS közül a miR-34a szintje magas volt azokban a tumorokban, amelyekben alacsony volt az AIP fehérje szintje, valamint a miR-34a szintje negatívan korrelált a SS-analógra adott válaszkészséggel. A miR-34a gátolta a luciferáz-*AIP*-3'UTR konstrukciót. Az *AIP*-3'UTR 3 előrejelzett kötőhelyén létrehozott deléciós konstrukciókkal történő mérés alapján a c.*6-30 kötőhely játszik szerepet a miR-34a aktivitásában. A miR-34a felülexpresszálása HEK293 és GH3 sejtekben az endogén AIP fehérje expresszióját gátolta. **Összefoglalva** a miR-34a felelős lehet a szomatotrop adenomák felében észlelt alacsony AIP fehérje szintjéért, ami együtt jár a daganat invazivitásával és SS-analóg terápiára adott válaszkészség csökkenésével.

II. vizsgálat: A hypophysis adenomák és phaeochromocytomák/paragangliomák (phaeo/PGL) együttes előfordulása nagyon ritka. 39 sporadikus vagy familiáris hypophysis adenoma és phaeo/PGL beteg szűrővizsgálata történt a phaeo/PGL-t okozó génekre (*SDHA-D, SDHAF2, RET, VHL, TMEM127, MAX)* és hypophysis adenomát okozó génekre *(MEN1, AIP, CDKN1B).* Tizenegy csírasejtes mutációt (5 *SDHB*, 1 *SDHC*, 1 *SDHD*, 2 *VHL* és 2 *MEN1*) és 4, eddig ismeretlen jelentőségű variánst (2 *SDHA*, 1 *SDHB* és 1 *SDHAF2)* találtunk. Három hypophysis adenomában igazoltuk a heterozigócia elvesztését az *SDHB* lókuszon és 2 phaeochromocytoma esetében a *MEN1* lókuszon. *SDHX* eltérés esetén jellegzetes szövettani kép jellemző a hypophysis adenomákra. **Összefoglalva** a phaeo/PGL-t okozó génmutációknak szerepük lehet a hypophysis adenoma kialakulásában, míg a hypophysis daganatokat okozó génmutációknak (*MEN1*) a phaeo/PGL kialakulásának patomechanizmusában. Eredményeink alapján megfontolandó azoknak a betegeknek és családoknak a genetikai szűrővizsgálata, akiknél a két kórkép együttesen fordul elő.

11. Bibliography

1. Ezzat S, Asa SL, Couldwell WT, Barr CE, Dodge WE, Vance ML, McCutcheon IE. (2004) The prevalence of pituitary adenomas: a systematic review. Cancer, 101: 613-619.
2. Daly AF, Rixhon M, Adam C, Dempegioti A, Tichomirowa MA, Beckers A. (2006) High prevalence of pituitary adenomas: a cross-sectional study in the province of Liege, Belgium. J Clin Endocrinol Metab, 91: 4769-4775.
3. Fernandez A, Karavitaki N, Wass JA. (2010) Prevalence of pituitary adenomas: a community-based, cross-sectional study in Banbury (Oxfordshire, UK). Clin Endocrinol (Oxf), 72: 377-382.
4. Raappana A, Koivukangas J, Ebeling T, Pirila T. (2010) Incidence of pituitary adenomas in Northern Finland in 1992-2007. J Clin Endocrinol Metab, 95: 4268-4275.
5. Aflorei ED, Korbonits M. (2014) Epidemiology and etiopathogenesis of pituitary adenomas. J Neurooncol, 117: 379-394.
6. Asa SL, Ezzat S. (2009) The pathogenesis of pituitary tumors. Annu Rev Pathol, 4: 97-126.
7. Jiang X, Zhang X. (2013) The molecular pathogenesis of pituitary adenomas: an update. Endocrinol Metab (Seoul), 28: 245-254.
8. Gadelha MR, Trivellin G, Hernandez Ramirez LC, Korbonits M. (2013) Genetics of pituitary adenomas. Front Horm Res, 41: 111-140.
9. Kopczak A, Renner U, Karl Stalla G. (2014) Advances in understanding pituitary tumors. F1000Prime Rep, 6: 5.
10. Xiao JQ, Liu XH, Hou B, Yao Y, Deng K, Feng M, Xing B, Lian W, Wang RZ, Feng F. (2014) Correlations of pituitary tumor transforming gene expression with human pituitary adenomas: a meta-analysis. PLoS One, 9: e90396.
11. Yu R, Melmed S. (2004) Pituitary tumor transforming gene: an update. Front Horm Res, 32: 175-185.

12. Dudley KJ, Revill K, Clayton RN, Farrell WE. (2009) Pituitary tumours: all silent on the epigenetics front. J Mol Endocrinol, 42: 461-468.
13. Franklin DS, Godfrey VL, Lee H, Kovalev GI, Schoonhoven R, Chen-Kiang S, Su L, Xiong Y. (1998) CDK inhibitors p18(INK4c) and p27(Kip1) mediate two separate pathways to collaboratively suppress pituitary tumorigenesis. Genes Dev, 12: 2899-2911.
14. Abbass SA, Asa SL, Ezzat S. (1997) Altered expression of fibroblast growth factor receptors in human pituitary adenomas. J Clin Endocrinol Metab, 82: 1160-1166.
15. Ezzat S, Zheng L, Zhu XF, Wu GE, Asa SL. (2002) Targeted expression of a human pituitary tumor-derived isoform of FGF receptor-4 recapitulates pituitary tumorigenesis. J Clin Invest, 109: 69-78.
16. Tateno T, Asa SL, Zheng L, Mayr T, Ullrich A, Ezzat S. (2011) The FGFR4-G388R polymorphism promotes mitochondrial STAT3 serine phosphorylation to facilitate pituitary growth hormone cell tumorigenesis. PLoS Genet, 7: e1002400.
17. Hernández-Ramírez LC, Gabrovska P, Denes J, Trivellin G, Radian S, Tilley D, Ferraù F, Akker SA, Grossman AB, Gadelha MR, Korbonits M, Consortium TIF. (2014) Pituitary Adenomas Harboring AIP Mutations Exhibit Phenotype-Genotype Correlation, but No Association with the Germline FGFR4 G388R Variant or Somatic GNAS1 Mutations. Endocrine Reviews, 35: OR09-03.
18. McAndrew J, Paterson AJ, Asa SL, McCarthy KJ, Kudlow JE. (1995) Targeting of transforming growth factor-alpha expression to pituitary lactotrophs in transgenic mice results in selective lactotroph proliferation and adenomas. Endocrinology, 136: 4479-4488.
19. Pellegrini I, Barlier A, Gunz G, Figarella-Branger D, Enjalbert A, Grisoli F, Jaquet P. (1994) Pit-1 gene expression in the human pituitary and pituitary adenomas. J Clin Endocrinol Metab, 79: 189-196.
20. Palmieri D, Valentino T, De Martino I, Esposito F, Cappabianca P, Wierinckx A, Vitiello M, Lombardi G, Colao A, Trouillas J, Pierantoni GM, Fusco A, Fedele M. (2012) PIT1 upregulation by HMGA proteins has a role in pituitary tumorigenesis. Endocr Relat Cancer, 19: 123-135.

21. Skelly RH, Korbonits M, Grossman A, Besser GM, Monson JP, Geddes JF, Burrin JM. (2000) Expression of the pituitary transcription factor Ptx-1, but not that of the trans-activating factor prop-1, is reduced in human corticotroph adenomas and is associated with decreased alpha-subunit secretion. J Clin Endocrinol Metab, 85: 2537-2542.
22. Lewis BP, Burge CB, Bartel DP. (2005) Conserved seed pairing, often flanked by adenosines, indicates that thousands of human genes are microRNA targets. Cell, 120: 15-20.
23. Carthew RW, Sontheimer EJ. (2009) Origins and Mechanisms of miRNAs and siRNAs. Cell, 136: 642-655.
24. Friedman RC, Farh KK, Burge CB, Bartel DP. (2009) Most mammalian mRNAs are conserved targets of microRNAs. Genome Res, 19: 92-105.
25. Lee RC, Feinbaum RL, Ambros V. (1993) The C. elegans heterochronic gene lin-4 encodes small RNAs with antisense complementarity to lin-14. Cell, 75: 843-854.
26. Taft RJ, Pang KC, Mercer TR, Dinger M, Mattick JS. (2010) Non-coding RNAs: regulators of disease. J Pathol, 220: 126-139.
27. Fabian MR, Sonenberg N, Filipowicz W. (2010) Regulation of mRNA translation and stability by microRNAs. Annu Rev Biochem, 79: 351-379.
28. Farazi TA, Spitzer JI, Morozov P, Tuschl T. (2011) miRNAs in human cancer. J Pathol, 223: 102-115.
29. Monteys AM, Spengler RM, Wan J, Tecedor L, Lennox KA, Xing Y, Davidson BL. (2010) Structure and activity of putative intronic miRNA promoters. RNA, 16: 495-505.
30. Yi R, Qin Y, Macara IG, Cullen BR. (2003) Exportin-5 mediates the nuclear export of pre-microRNAs and short hairpin RNAs. Genes Dev, 17: 3011-3016.
31. Beilharz TH, Humphreys DT, Clancy JL, Thermann R, Martin DI, Hentze MW, Preiss T. (2009) microRNA-mediated messenger RNA deadenylation contributes to translational repression in mammalian cells. PLoS One, 4: e6783.
32. Wang WX, Wilfred BR, Xie K, Jennings MH, Hu YH, Stromberg AJ, Nelson PT. (2010) Individual microRNAs (miRNAs) display distinct mRNA targeting "rules". RNA Biol, 7: 373-380.

33. Rigoutsos I. (2009) New tricks for animal microRNAS: targeting of amino acid coding regions at conserved and nonconserved sites. Cancer Res, 69: 3245-3248.
34. Bartel DP. (2009) MicroRNAs: target recognition and regulatory functions. Cell, 136: 215-233.
35. Ye W, Lv Q, Wong CK, Hu S, Fu C, Hua Z, Cai G, Li G, Yang BB, Zhang Y. (2008) The effect of central loops in miRNA:MRE duplexes on the efficiency of miRNA-mediated gene regulation. PLoS One, 3: e1719.
36. Long D, Lee R, Williams P, Chan CY, Ambros V, Ding Y. (2007) Potent effect of target structure on microRNA function. Nat Struct Mol Biol, 14: 287-294.
37. Sun G, Li H, Rossi JJ. (2010) Sequence context outside the target region influences the effectiveness of miR-223 target sites in the RhoB 3'UTR. Nucleic Acids Res, 38: 239-252.
38. Kertesz M, Iovino N, Unnerstall U, Gaul U, Segal E. (2007) The role of site accessibility in microRNA target recognition. Nat Genet, 39: 1278-1284.
39. Kedde M, Strasser MJ, Boldajipour B, Oude Vrielink JA, Slanchev K, le Sage C, Nagel R, Voorhoeve PM, van Duijse J, Orom UA, Lund AH, Perrakis A, Raz E, Agami R. (2007) RNA-binding protein Dnd1 inhibits microRNA access to target mRNA. Cell, 131: 1273-1286.
40. Gadelha MR, Kasuki L, Denes J, Trivellin G, Korbonits M. (2013) MicroRNAs: Suggested role in pituitary adenoma pathogenesis. J Endocrinol Invest, 36: 889-895.
41. Wang C, Su Z, Sanai N, Xue X, Lu L, Chen Y, Wu J, Zheng W, Zhuge Q, Wu ZB. (2012) microRNA expression profile and differentially-expressed genes in prolactinomas following bromocriptine treatment. Oncol Rep, 27: 1312-1320.
42. Bottoni A, Piccin D, Tagliati F, Luchin A, Zatelli MC, degli Uberti EC. (2005) miR-15a and miR-16-1 down-regulation in pituitary adenomas. J Cell Physiol, 204: 280-285.
43. Bottoni A, Zatelli MC, Ferracin M, Tagliati F, Piccin D, Vignali C, Calin GA, Negrini M, Croce CM, Degli Uberti EC. (2007) Identification of differentially expressed microRNAs by microarray: a possible role for microRNA genes in pituitary adenomas. J Cell Physiol, 210: 370-377.

44. Mao ZG, He DS, Zhou J, Yao B, Xiao WW, Chen CH, Zhu YH, Wang HJ. (2010) Differential expression of microRNAs in GH-secreting pituitary adenomas. Diagn Pathol, 5: 79.

45. Amaral FC, Torres N, Saggioro F, Neder L, Machado HR, Silva WA, Jr., Moreira AC, Castro M. (2009) MicroRNAs differentially expressed in ACTH-secreting pituitary tumors. J Clin Endocrinol Metab, 94: 320-323.

46. Butz H, Liko I, Czirjak S, Igaz P, Korbonits M, Racz K, Patocs A. (2011) MicroRNA profile indicates downregulation of the TGFbeta pathway in sporadic non-functioning pituitary adenomas. Pituitary, 14: 112-124.

47. Cheunsuchon P, Zhou Y, Zhang X, Lee H, Chen W, Nakayama Y, Rice KA, Tessa Hedley-Whyte E, Swearingen B, Klibanski A. (2011) Silencing of the imprinted DLK1-MEG3 locus in human clinically nonfunctioning pituitary adenomas. Am J Pathol, 179: 2120-2130.

48. Chen YX, Li Q, Wang CD, Su ZP, Li WQ, Chen XB, Wu ZB. (2012) [Differential expression analysis of prolactinoma-related microRNAs]. Zhonghua Yi Xue Za Zhi, 92: 320-323.

49. Qian ZR, Asa SL, Siomi H, Siomi MC, Yoshimoto K, Yamada S, Wang EL, Rahman MM, Inoue H, Itakura M, Kudo E, Sano T. (2009) Overexpression of HMGA2 relates to reduction of the let-7 and its relationship to clinicopathological features in pituitary adenomas. Mod Pathol, 22: 431-441.

50. Butz H, Liko I, Czirjak S, Igaz P, Khan MM, Zivkovic V, Balint K, Korbonits M, Racz K, Patocs A. (2010) Down-regulation of Wee1 kinase by a specific subset of microRNA in human sporadic pituitary adenomas. J Clin Endocrinol Metab, 95: E181-191.

51. Trivellin G, Butz H, Delhove J, Igreja S, Chahal HS, Zivkovic V, McKay T, Patocs A, Grossman AB, Korbonits M. (2012) MicroRNA miR-107 is overexpressed in pituitary adenomas and in vitro inhibits the expression of aryl hydrocarbon receptor-interacting protein (AIP). Am J Physiol Endocrinol Metab, 303: E708-719.

52. Pais H, Nicolas FE, Soond SM, Swingler TE, Clark IM, Chantry A, Moulton V, Dalmay T. (2010) Analyzing mRNA expression identifies Smad3 as a microRNA-140 target regulated only at protein level. RNA, 16: 489-494.

53. D'Angelo D, Palmieri D, Mussnich P, Roche M, Wierinckx A, Raverot G, Fedele M, Croce CM, Trouillas J, Fusco A. (2012) Altered microRNA expression profile in human pituitary GH adenomas: down-regulation of miRNA targeting HMGA1, HMGA2, and E2F1. J Clin Endocrinol Metab, 97: E1128-1138.

54. Palumbo T, Faucz FR, Azevedo M, Xekouki P, Iliopoulos D, Stratakis CA. (2013) Functional screen analysis reveals miR-26b and miR-128 as central regulators of pituitary somatomammotrophic tumor growth through activation of the PTEN-AKT pathway. Oncogene, 32: 1651-1659.

55. Gentilin E, Tagliati F, Filieri C, Mole D, Minoia M, Rosaria Ambrosio M, Degli Uberti EC, Zatelli MC. (2013) miR-26a plays an important role in cell cycle regulation in ACTH-secreting pituitary adenomas by modulating protein kinase Cdelta. Endocrinology, 154: 1690-1700.

56. Leone V, Langella C, D'Angelo D, Mussnich P, Wierinckx A, Terracciano L, Raverot G, Lachuer J, Rotondi S, Jaffrain-Rea ML, Trouillas J, Fusco A. (2014) Mir-23b and miR-130b expression is downregulated in pituitary adenomas. Mol Cell Endocrinol, 390: 1-7.

57. Iversen K. (1952) Acromegaly associated with phaeochromocytoma. Acta Med Scand, 142: 1-5.

58. Beckers A. (2013) Means, motive, and opportunity: SDH mutations are suspects in pituitary tumors. J Clin Endocrinol Metab, 98: 2274-2276.

59. Xekouki P, Stratakis CA. (2012) Succinate dehydrogenase (SDHx) mutations in pituitary tumors: could this be a new role for mitochondrial complex II and/or Krebs cycle defects? Endocr Relat Cancer, 19: C33-40.

60. Dwight T, Mann K, Benn DE, Robinson BG, McKelvie P, Gill AJ, Winship I, Clifton-Bligh RJ. (2013) Familial SDHA Mutation Associated With Pituitary Adenoma and Pheochromocytoma/Paraganglioma. J Clin Endocrinol Metab, 98: E1103-1108.

61. Kahn MT, Mullon DA. (1964) PHEOCHROMOCYTOMA WITHOUT HYPERTENSION. REPORT OF A PATIENT WITH ACROMEGALY. JAMA, 188: 74-75.

62. German WJ, Flanigan S. (1964) PITUITARY ADENOMAS: A FOLLOW-UP STUDY OF THE CUSHING SERIES. Clin Neurosurg, 10: 72-81.
63. Breckenridge SM, Hamrahian AH, Faiman C, Suh J, Prayson R, Mayberg M. (2003) Coexistence of a pituitary macroadenoma and pheochromocytoma--a case report and review of the literature. Pituitary, 6: 221-225.
64. O'Higgins NJ, Cullen MJ, Heffernan AG. (1967) A case of acromegaly and phaeochromocytoma. J Ir Med Assoc, 60: 213-216.
65. Miller GL, Wynn J. (1971) Acromegaly, pheochromocytoma, toxic goiter, diabetes mellitus, and endometriosis. Arch Intern Med, 127: 299-303.
66. Melicow MM. (1977) One hundred cases of pheochromocytoma (107 tumors) at the Columbia-Presbyterian Medical Center, 1926-1976: a clinicopathological analysis. Cancer, 40: 1987-2004.
67. Janson KL, Roberts JA, Varela M. (1978) Multiple endocrine adenomatosis: in support of the common origin theories. J Urol, 119: 161-165.
68. Alberts WM, McMeekin JO, George JM. (1980) Mixed multiple endocrine neoplasia syndromes. JAMA, 244: 1236-1237.
69. Anderson RJ, Lufkin EG, Sizemore GW, Carney JA, Sheps SG, Silliman YE. (1981) Acromegaly and pituitary adenoma with phaeochromocytoma: a variant of multiple endocrine neoplasia. Clin Endocrinol (Oxf), 14: 605-612.
70. Meyers DH. (1982) Association of phaeochromocytoma and prolactinoma. Med J Aust, 1: 13-14.
71. Blumenkopf B, Boekelheide K. (1982) Neck paraganglioma with a pituitary adenoma. Case report. J Neurosurg, 57: 426-429.
72. Baughan J, de Gara C, Morrish D. (2001) A rare association between acromegaly and pheochromocytoma. Am J Surg, 182: 185-187.
73. Dunser MW, Mayr AJ, Gasser R, Rieger M, Friesenecker B, Hasibeder WR. (2002) Cardiac failure and multiple organ dysfunction syndrome in a patient with endocrine adenomatosis. Acta Anaesthesiol Scand, 46: 1161-1164.
74. Yaylali GF, Akin F, Bastemir M, Yaylali YT, Ozden A. (2008) Phaeochromocytoma combined with subclinical Cushing's syndrome and pituitary microadenoma. Clin Invest Med, 31: E176-181.

75. Sisson JC, Giordano TJ, Avram AM. (2012) Three endocrine neoplasms: an unusual combination of pheochromocytoma, pituitary adenoma, and papillary thyroid carcinoma. Thyroid, 22: 430-436.

76. Filipponi S, Rostomyan L, Vroonen L, Daly AF, Beckers A. (2012) THE COEXISTENCE OF A PITUITARY ADENOMA AND PHEOCHROMOCYTOMA (a case report). 13TH INTERNATIONAL WORKSHOP ON MULTIPLE ENDOCRINE NEOPLASIA Final Program&Abstract Book: P48.

77. Parghane RV, Agrawal K, Mittal BR, Shukla J, Bhattacharya A, Mukherjee KK. (2014) 68Ga DOTATATE PET/CT in a rare coexistence of pituitary macroadenoma and multiple paragangliomas. Clin Nucl Med, 39: 91-93.

78. Wass JAH, Trainer PJ, Korbonits M. Acromegaly. In: Wass JAH, Stewart PM, Amiel SA, Davies MC (eds.), Oxford Textbook of Endocrinology and Diabetes. 2 ed. Oxford University Press, Oxford, 2011: 197-209.

79. Rivier J, Spiess J, Thorner M, Vale W. (1982) Characterization of a growth hormone-releasing factor from a human pancreatic islet tumour. Nature, 300: 276-278.

80. Vieira Neto L, Taboada GF, Correa LL, Polo J, Nascimento AF, Chimelli L, Rumilla K, Gadelha MR. (2007) Acromegaly secondary to growth hormone-releasing hormone secreted by an incidentally discovered pheochromocytoma. Endocr Pathol, 18: 46-52.

81. Thorner MO, Perryman RL, Cronin MJ, Rogol AD, Draznin M, Johanson A, Vale W, Horvath E, Kovacs K. (1982) Somatotroph hyperplasia. Successful treatment of acromegaly by removal of a pancreatic islet tumor secreting a growth hormone-releasing factor. J Clin Invest, 70: 965-977.

82. Guillemin R, Brazeau P, Bohlen P, Esch F, Ling N, Wehrenberg WB. (1982) Growth hormone-releasing factor from a human pancreatic tumor that caused acromegaly. Science, 218: 585-587.

83. Zimmerman D, Young WF, Jr., Ebersold MJ, Scheithauer BW, Kovacs K, Horvath E, Whitaker MD, Eberhardt NL, Downs TR, Frohman LA. (1993) Congenital gigantism due to growth hormone-releasing hormone excess and

pituitary hyperplasia with adenomatous transformation. J Clin Endocrinol Metab, 76: 216-222.

84. Roth KA, Wilson DM, Eberwine J, Dorin RI, Kovacs K, Bensch KG, Hoffman AR. (1986) Acromegaly and pheochromocytoma: a multiple endocrine syndrome caused by a plurihormonal adrenal medullary tumor. J Clin Endocrinol Metab, 63: 1421-1426.

85. Sano T, Saito H, Yamasaki R, Hosoi E, Kameyama K, Saito S, Hirose T, Hizawa K. (1986) Production and secretion of immunoreactive growth hormone-releasing factor by pheochromocytomas. Cancer, 57: 1788-1793.

86. Farhi F, Dikman SH, Lawson W, Cobin RH, Zak FG. (1976) Paragangliomatosis associated with multiple endocrine adenomas. Arch Pathol Lab Med, 100: 495-498.

87. Frohman LA, Szabo M, Berelowitz M, Stachura ME. (1980) Partial purification and characterization of a peptide with growth hormone-releasing activity from extrapituitary tumors in patients with acromegaly. J Clin Invest, 65: 43-54.

88. Schroeder JO, Asa SL, Kovacs K, Killinger D, Hadley GL, Volpe R. (1984) Report of a case of pheochromocytoma producing immunoreactive ACTH and beta-endorphin. J Endocrinol Invest, 7: 117-121.

89. Ballav C, Naziat A, Mihai R, Karavitaki N, Ansorge O, Grossman AB. (2012) Mini-review: pheochromocytomas causing the ectopic ACTH syndrome. Endocrine, 42: 69-73.

90. Ilias I, Torpy DJ, Pacak K, Mullen N, Wesley RA, Nieman LK. (2005) Cushing's syndrome due to ectopic corticotropin secretion: twenty years' experience at the National Institutes of Health. J Clin Endocrinol Metab, 90: 4955-4962.

91. O'Brien T, Young WF, Jr., Davila DG, Scheithauer BW, Kovacs K, Horvath E, Vale W, van Heerden JA. (1992) Cushing's syndrome associated with ectopic production of corticotrophin-releasing hormone, corticotrophin and vasopressin by a phaeochromocytoma. Clin Endocrinol (Oxf), 37: 460-467.

92. Saeger W, Reincke M, Scholz GH, Ludecke DK. (1993) [Ectopic ACTH- or CRH-secreting tumors in Cushing's syndrome]. Zentralbl Pathol, 139: 157-163.

93. Ruggeri RM, Ferrau F, Campenni A, Simone A, Barresi V, Giuffre G, Tuccari G, Baldari S, Trimarchi F. (2009) Immunohistochemical localization and functional characterization of somatostatin receptor subtypes in a corticotropin releasing hormone- secreting adrenal phaeochromocytoma: review of the literature and report of a case. Eur J Histochem, 53: 1-6.

94. Bayraktar F, Kebapcilar L, Kocdor MA, Asa SL, Yesil S, Canda S, Demir T, Saklamaz A, Secil M, Akinci B, Yener S, Comlekci A. (2006) Cushing's syndrome due to ectopic CRH secretion by adrenal pheochromocytoma accompanied by renal infarction. Exp Clin Endocrinol Diabetes, 114: 444-447.

95. Eng PH, Tan LH, Wong KS, Cheng CW, Fok AC, Khoo DH. (1999) Cushing's syndrome in a patient with a corticotropin-releasing hormone-producing pheochromocytoma. Endocr Pract, 5: 84-87.

96. Sano T, Saito H, Yamazaki R, Kameyama K, Ikeda M, Hosoi E, Hizawa K, Saito S. (1984) Production of growth hormone-releasing factor in pheochromocytoma. N Engl J Med, 311: 1520.

97. Thakker RV. Multiple Endocrine Neoplasia Type I. In: Jameson JL, De Groot LJ (eds.), Endocrinology. Saunders Elsevier, Philadelphia, 2010: 2719-2741.

98. Thakker RV. (2010) Multiple endocrine neoplasia type 1 (MEN1). Best Pract Res Clin Endocrinol Metab, 24: 355-370.

99. Langer P, Cupisti K, Bartsch DK, Nies C, Goretzki PE, Rothmund M, Roher HD. (2002) Adrenal involvement in multiple endocrine neoplasia type 1. World J Surg, 26: 891-896.

100. Skogseid B, Larsson C, Lindgren PG, Kvanta E, Rastad J, Theodorsson E, Wide L, Wilander E, Oberg K. (1992) Clinical and genetic features of adrenocortical lesions in multiple endocrine neoplasia type 1. J Clin Endocrinol Metab, 75: 76-81.

101. Burgess JR, Harle RA, Tucker P, Parameswaran V, Davies P, Greenaway TM, Shepherd JJ. (1996) Adrenal lesions in a large kindred with multiple endocrine neoplasia type 1. Arch Surg, 131: 699-702.

102. Carty SE, Helm AK, Amico JA, Clarke MR, Foley TP, Watson CG, Mulvihill JJ. (1998) The variable penetrance and spectrum of manifestations of multiple endocrine neoplasia type 1. Surgery, 124: 1106-1113; discussion 1113-1104.

103. Trump D, Farren B, Wooding C, Pang JT, Besser GM, Buchanan KD, Edwards CR, Heath DA, Jackson CE, Jansen S, Lips K, Monson JP, O'Halloran D, Sampson J, Shalet SM, Wheeler MH, Zink A, Thakker RV. (1996) Clinical studies of multiple endocrine neoplasia type 1 (MEN1). QJM, 89: 653-669.

104. Tateishi R, Wada A, Ishiguro S, Ehara M, Sakamoto H, Miki T, Mori Y, Matsui Y, Ishikawa O. (1978) Coexistence of bilateral pheochromocytoma and pancreatic islet cell tumor: report of a case and review of the literature. Cancer, 42: 2928-2934.

105. Carney JA, Go VL, Gordon H, Northcutt RC, Pearse AG, Sheps SG. (1980) Familial pheochromocytoma and islet cell tumor of the pancreas. Am J Med, 68: 515-521.

106. Zeller JR, Kauffman HM, Komorowski RA, Itskovitz HD. (1982) Bilateral pheochromocytoma and islet cell adenoma of the pancreas. Arch Surg, 117: 827-830.

107. Tamasawa N, Terada A, Kodama T, Ishigame M, Ishimaru K, Hishida R, Satoh T, Takebe K, Sasaki M, Imamura K. (1994) Pheochromocytoma with multiple islet cell carcinoma. Presse Med, 23: 32-34.

108. Barnard PJ, Jacobson L. (1965) MALIGNANT PHAEOCHROMOCYTOMA ASSOCIATED WITH ARGENTAFFINOMA AND HYPOTENSIVE CRISES; REPORT OF A CASE. Cent Afr J Med, 11: 185-190.

109. Manger WM, Gifford RW. Pheochromocytoma. Springer-Verlag, New York, 1977.

110. Myers JH, Eversman JJ. (1981) Acromegaly, hyperparathyroidism, and pheochromocytoma in the same patient. A multiple endocrine disorder. Arch Intern Med, 141: 1521-1522.

111. Marx S, Spiegel AM, Skarulis MC, Doppman JL, Collins FS, Liotta LA. (1998) Multiple endocrine neoplasia type 1: clinical and genetic topics. Ann Intern Med, 129: 484-494.

112. Dackiw AP, Cote GJ, Fleming JB, Schultz PN, Stanford P, Vassilopoulou-Sellin R, Evans DB, Gagel RF, Lee JE. (1999) Screening for MEN1 mutations in patients with atypical endocrine neoplasia. Surgery, 126: 1097-1103; discussion 1103-1094.

113. Jamilloux Y, Favier J, Pertuit M, Delage-Corre M, Lopez S, Teissier MP, Mathonnet M, Galinat S, Barlier A, Archambeaud F. (2014) A MEN1 syndrome with a paraganglioma. Eur J Hum Genet, 22: 283-285.

114. Pellegata NS, Quintanilla-Martinez L, Siggelkow H, Samson E, Bink K, Hofler H, Fend F, Graw J, Atkinson MJ. (2006) Germ-line mutations in p27Kip1 cause a multiple endocrine neoplasia syndrome in rats and humans. Proc Natl Acad Sci U S A, 103: 15558-15563.

115. Occhi G, Regazzo D, Trivellin G, Boaretto F, Ciato D, Bobisse S, Ferasin S, Cetani F, Pardi E, Korbonits M, Pellegata NS, Sidarovich V, Quattrone A, Opocher G, Mantero F, Scaroni C. (2013) A novel mutation in the upstream open reading frame of the CDKN1B gene causes a MEN4 phenotype. PLoS Genet, 9: e1003350.

116. Sambugaro S, Di Ruvo M, Ambrosio MR, Pellegata NS, Bellio M, Guerra A, Buratto M, Foschini MP, Tagliati F, Degli Uberti E, Zatelli MC. (2015) Early onset acromegaly associated with a novel deletion in CDKN1B 5'UTR region. Endocrine, 49: 58-64.

117. Marinoni I, Lee M, Mountford S, Perren A, Bravi I, Jennen L, Feuchtinger A, Drouin J, Roncaroli F, Pellegata NS. (2012) Characterization of MENX-associated pituitary tumours. Neuropathol Appl Neurobiol, 39: 256-269.

118. Fero ML, Rivkin M, Tasch M, Porter P, Carow CE, Firpo E, Polyak K, Tsai LH, Broudy V, Perlmutter RM, Kaushansky K, Roberts JM. (1996) A syndrome of multiorgan hyperplasia with features of gigantism, tumorigenesis, and female sterility in p27(Kip1)-deficient mice. Cell, 85: 733-744.

119. Molatore S, Liyanarachchi S, Irmler M, Perren A, Mannelli M, Ercolino T, Beuschlein F, Jarzab B, Wloch J, Ziaja J, Zoubaa S, Neff F, Beckers J, Hofler H, Atkinson MJ, Pellegata NS. (2010) Pheochromocytoma in rats with multiple endocrine neoplasia (MENX) shares gene expression patterns with human pheochromocytoma. Proc Natl Acad Sci U S A, 107: 18493-18498.

120. Chahal HS, Chapple JP, Frohman LA, Grossman AB, Korbonits M. (2010) Clinical, genetic and molecular characterization of patients with familial isolated pituitary adenomas (FIPA). Trends Endocrinol Metab, 21: 419-427.

121. Georgitsi M, Karhu A, Winqvist R, Visakorpi T, Waltering K, Vahteristo P, Launonen V, Aaltonen LA. (2007) Mutation analysis of aryl hydrocarbon receptor interacting protein (AIP) gene in colorectal, breast, and prostate cancers. Br J Cancer, 96: 352-356.

122. Trivellin G, Daly AF, Faucz FR, Yuan B, Rostomyan L, Larco DO, Schernthaner-Reiter MH, Szarek E, Leal LF, Caberg JH, Castermans E, Villa C, Dimopoulos A, Chittiboina P, Xekouki P, Shah N, Metzger D, Lysy PA, Ferrante E, Strebkova N, Mazerkina N, Zatelli MC, Lodish M, Horvath A, de Alexandre RB, Manning AD, Levy I, Keil MF, Sierra Mde L, Palmeira L, Coppieters W, Georges M, Naves LA, Jamar M, Bours V, Wu TJ, Choong CS, Bertherat J, Chanson P, Kamenicky P, Farrell WE, Barlier A, Quezado M, Bjelobaba I, Stojilkovic SS, Wess J, Costanzi S, Liu P, Lupski JR, Beckers A, Stratakis CA. (2014) Gigantism and acromegaly due to Xq26 microduplications and GPR101 mutation. N Engl J Med, 371: 2363-2374.

123. Stratakis CA, Kirschner LS, Carney JA. (2001) Clinical and molecular features of the Carney complex: diagnostic criteria and recommendations for patient evaluation. J Clin Endocrinol Metab, 86: 4041-4046.

124. Matyakhina L, Pack S, Kirschner LS, Pak E, Mannan P, Jaikumar J, Taymans SE, Sandrini F, Carney JA, Stratakis CA. (2003) Chromosome 2 (2p16) abnormalities in Carney complex tumours. J Med Genet, 40: 268-277.

125. Forlino A, Vetro A, Garavelli L, Ciccone R, London E, Stratakis CA, Zuffardi O. (2014) PRKACB and Carney complex. N Engl J Med, 370: 1065-1067.

126. Bertherat J. (2006) Carney complex (CNC). Orphanet J Rare Dis, 1: 21.

127. Lloyd RV. (2011) Adrenal cortical tumors, pheochromocytomas and paragangliomas. Mod Pathol, 24 Suppl 2: S58-65.

128. Pacak K, Timmers HJLM, Eisenhofer G. Pheochromocytoma. In: Jameson JL, De Groot LJ (eds.), Endocrinology. Saunders Elsevier, Philadelphia, 2010: 1990-2018.

129. Eisenhofer G, Pacak K, Maher ER, Young WF, de Krijger RR. (2013) Pheochromocytoma. Clin Chem, 59: 466-472.

130. Mazzaglia PJ. (2012) Hereditary pheochromocytoma and paraganglioma. J Surg Oncol, 106: 580-585.

131. Almeida MQ, Stratakis CA. (2010) Solid tumors associated with multiple endocrine neoplasias. Cancer Genet Cytogenet, 203: 30-36.

132. Gimenez-Roqueplo AP, Dahia PL, Robledo M. (2012) An update on the genetics of paraganglioma, pheochromocytoma, and associated hereditary syndromes. Horm Metab Res, 44: 328-333.

133. Castro-Vega LJ, Buffet A, De Cubas AA, Cascon A, Menara M, Khalifa E, Amar L, Azriel S, Bourdeau I, Chabre O, Curras-Freixes M, Franco-Vidal V, Guillaud-Bataille M, Simian C, Morin A, Leton R, Gomez-Grana A, Pollard PJ, Rustin P, Robledo M, Favier J, Gimenez-Roqueplo AP. (2014) Germline mutations in FH confer predisposition to malignant pheochromocytomas and paragangliomas. Hum Mol Genet, 23: 2440-2446.

134. Yang C, Zhuang Z, Fliedner SM, Shankavaram U, Sun MG, Bullova P, Zhu R, Elkahloun AG, Kourlas PJ, Merino M, Kebebew E, Pacak K. (2015) Germ-line PHD1 and PHD2 mutations detected in patients with pheochromocytoma/paraganglioma-polycythemia. J Mol Med (Berl), 93: 93-104.

135. Gimm O, Armanios M, Dziema H, Neumann HP, Eng C. (2000) Somatic and occult germ-line mutations in SDHD, a mitochondrial complex II gene, in nonfamilial pheochromocytoma. Cancer Res, 60: 6822-6825.

136. Burnichon N, Buffet A, Parfait B, Letouze E, Laurendeau I, Loriot C, Pasmant E, Abermil N, Valeyrie-Allanore L, Bertherat J, Amar L, Vidaud D, Favier J, Gimenez-Roqueplo AP. (2012) Somatic NF1 inactivation is a frequent event in sporadic pheochromocytoma. Hum Mol Genet, 21: 5397-5405.

137. Weber A, Hoffmann MM, Neumann HP, Erlic Z. (2012) Somatic mutation analysis of the SDHB, SDHC, SDHD, and RET genes in the clinical assessment of sporadic and hereditary pheochromocytoma. Horm Cancer, 3: 187-192.

138. Crona J, Delgado Verdugo A, Maharjan R, Stalberg P, Granberg D, Hellman P, Bjorklund P. (2013) Somatic mutations in H-RAS in sporadic pheochromocytoma and paraganglioma identified by exome sequencing. J Clin Endocrinol Metab, 98: E1266-1271.

139. Zhuang Z, Yang C, Lorenzo F, Merino M, Fojo T, Kebebew E, Popovic V, Stratakis CA, Prchal JT, Pacak K. (2012) Somatic HIF2A gain-of-function mutations in paraganglioma with polycythemia. N Engl J Med, 367: 922-930.

140. Hu M, Gagel RF. Multiple endocrine neoplasia type 2. In: Jameson JL, De Groot LJ (eds.), Endocrinology. Saunders Elsevier, Philadelphia, 2010: 2742-2758.

141. Steiner AL, Goodman AD, Powers SR. (1968) Study of a kindred with pheochromocytoma, medullary thyroid carcinoma, hyperparathyroidism and Cushing's disease: multiple endocrine neoplasia, type 2. Medicine (Baltimore), 47: 371-409.

142. Wolf LM, Duduisson M, Schrub JC, Metayer J, Laumonier R. (1972) [Sipple's syndrome associated with pituitary and parathyroid adenomas]. Ann Endocrinol (Paris), 33: 455-463.

143. Bertrand JH, Ritz P, Reznik Y, Grollier G, Potier JC, Evrad C, Mahoudeau JA. (1987) Sipple's syndrome associated with a large prolactinoma. Clin Endocrinol (Oxf), 27: 607-614.

144. Mulligan LM, Kwok JB, Healey CS, Elsdon MJ, Eng C, Gardner E, Love DR, Mole SE, Moore JK, Papi L, Ponder MA, Telenius H, Tunnacliffe A, Ponder BAJ. (1993) Germ-line mutations of the RET proto-oncogene in multiple endocrine neoplasia type 2A. Nature, 363: 458-460.

145. Brauer VF, Scholz GH, Neumann S, Lohmann T, Paschke R, Koch CA. (2004) RET germline mutation in codon 791 in a family representing 3 generations from age 5 to age 70 years: should thyroidectomy be performed? Endocr Pract, 10: 5-9.

146. Saito T, Miura D, Taguchi M, Takeshita A, Miyakawa M, Takeuchi Y. (2010) Coincidence of multiple endocrine neoplasia type 2A with acromegaly. Am J Med Sci, 340: 329-331.

147. Heinlen JE, Buethe DD, Culkin DJ, Slobodov G. (2011) Multiple endocrine neoplasia 2a presenting with pheochromocytoma and pituitary macroadenoma. ISRN Oncol, 2011: 732452.

148. Lugli F, Leone E, Iacovazzo D, Fusco A, Milardi D, Piacentini S, Lucci-Cordisco E, Minucci A, Capoluongo E, Neri G, L. DM. (2012) FMTC and prolactinoma: a casual association or a new genetic syndrome? 13TH

INTERNATIONAL WORKSHOP ON MULTIPLE ENDOCRINE NEOPLASIA Final Program&Abstract Book: 77 P43.

149. Vargiolu M, Fusco D, Kurelac I, Dirnberger D, Baumeister R, Morra I, Melcarne A, Rimondini R, Romeo G, Bonora E. (2009) The tyrosine kinase receptor RET interacts in vivo with aryl hydrocarbon receptor-interacting protein to alter survivin availability. J Clin Endocrinol Metab, 94: 2571-2578.

150. Canibano C, Rodriguez NL, Saez C, Tovar S, Garcia-Lavandeira M, Borrello MG, Vidal A, Costantini F, Japon M, Dieguez C, Alvarez CV. (2007) The dependence receptor Ret induces apoptosis in somatotrophs through a Pit-1/p53 pathway, preventing tumor growth. EMBO J, 26: 2015-2028.

151. Heliovaara E, Tuupanen S, Ahlsten M, Hodgson S, de Menis E, Kuismin O, Izatt L, McKinlay Gardner RJ, Gundogdu S, Lucassen A, Arola J, Tuomisto A, Makinen M, Karhu A, Aaltonen LA. (2011) No evidence of RET germline mutations in familial pituitary adenoma. J Mol Endocrinol, 46: 1-8.

152. Majumdar S, Friedrich CA, Koch CA, Megason GC, Fratkin JD, Moll GW. (2010) Compound heterozygous mutation with a novel splice donor region DNA sequence variant in the succinate dehydrogenase subunit B gene in malignant paraganglioma. Pediatr Blood Cancer, 54: 473-475.

153. Benn DE, Gimenez-Roqueplo AP, Reilly JR, Bertherat J, Burgess J, Byth K, Croxson M, Dahia PL, Elston M, Gimm O, Henley D, Herman P, Murday V, Niccoli-Sire P, Pasieka JL, Rohmer V, Tucker K, Jeunemaitre X, Marsh DJ, Plouin PF, Robinson BG. (2006) Clinical presentation and penetrance of pheochromocytoma/paraganglioma syndromes. J Clin Endocrinol Metab, 91: 827-836.

154. Xekouki P, Pacak K, Almeida M, Wassif CA, Rustin P, Nesterova M, de la Luz Sierra M, Matro J, Ball E, Azevedo M, Horvath A, Lyssikatos C, Quezado M, Patronas N, Ferrando B, Pasini B, Lytras A, Tolis G, Stratakis CA. (2012) Succinate dehydrogenase (SDH) D subunit (SDHD) inactivation in a growth-hormone-producing pituitary tumor: a new association for SDH? J Clin Endocrinol Metab, 97: E357-366.

155. Varsavsky M, Sebastian-Ochoa A, Torres Vela E. (2013) Coexistence of a pituitary macroadenoma and multicentric paraganglioma: a strange coincidence. Endocrinol Nutr, 60: 154-156.

156. Dematti S, Branz G, Casagranda G, Recla M, Sartorato P, Zovato S, Schiavi F, Opocher G. (2013) Pituitary tumors in SDH mutation carriers. 12th ENSAT Meeting Abstract Book: P29.

157. Papathomas TG, Gaal J, Corssmit EP, Oudijk L, Korpershoek E, Heimdal K, Bayley JP, Morreau H, van Dooren M, Papaspyrou K, Schreiner T, Hansen T, Andresen PA, Restuccia DF, van Kessel I, van Leenders GJ, Kros JM, Looijenga LH, Hofland LJ, Mann W, van Nederveen FH, Mete O, Asa SL, de Krijger RR, Dinjens WN. (2014) Non-pheochromocytoma (PCC)/paraganglioma (PGL) tumors in patients with succinate dehydrogenase-related PCC-PGL syndromes: a clinicopathological and molecular analysis. Eur J Endocrinol, 170: 1-12.

158. Lopez-Jimenez E, de Campos JM, Kusak EM, Landa I, Leskela S, Montero-Conde C, Leandro-Garcia LJ, Vallejo LA, Madrigal B, Rodriguez-Antona C, Robledo M, Cascon A. (2008) SDHC mutation in an elderly patient without familial antecedents. Clin Endocrinol (Oxf), 69: 906-910.

159. Gill AJ, Toon CW, Clarkson A, Sioson L, Chou A, Winship I, Robinson BG, Benn DE, Clifton-Bligh RJ, Dwight T. (2014) Succinate dehydrogenase deficiency is rare in pituitary adenomas. Am J Surg Pathol, 38: 560-566.

160. Larraza-Hernandez O, Albores-Saavedra J, Benavides G, Krause LG, Perez-Merizaldi JC, Ginzo A. (1982) Multiple endocrine neoplasia. Pituitary adenoma, multicentric papillary thyroid carcinoma, bilateral carotid body paraganglioma, parathyroid hyperplasia, gastric leiomyoma, and systemic amyloidosis. Am J Clin Pathol, 78: 527-532.

161. Teh BT, Hansen J, Svensson PJ, Hartley L. (1996) Bilateral recurrent phaeochromocytoma associated with a growth hormone-secreting pituitary tumour. Br J Surg, 83: 1132.

162. Sleilati GG, Kovacs KT, Honasoge M. (2002) Acromegaly and pheochromocytoma: report of a rare coexistence. Endocr Pract, 8: 54-60.

163. Zhang C, Ma G, Liu X, Zhang H, Deng H, Nowell J, Miao Q. (2011) Primary cardiac pheochromocytoma with multiple endocrine neoplasia. J Cancer Res Clin Oncol, 137: 1289-1291.

164. Efstathiadou ZA, Sapranidis M, Anagnostis P, Kita MD. (2014) Unusual case of Cowden-like syndrome, neck paraganglioma, and pituitary adenoma. Head Neck, 36: E12-16.

165. Boudin G, Pepin B, Vernant CL. (1970) [Multiple tumours of the nervous system in Recklinghausen's disease. An anatomo-clinical case with chromophobe adenoma of the pituitary gland]. Presse Med, 78: 1427-1430.

166. Barberis M, Gambacorta M, Versari P, Filizzolo F. (1979) [About a case of Recklinghausen's disease associated with pituitary adenoma (author's transl)]. Pathologica, 71: 265-272.

167. Pinnamaneni K, Birge SJ, Avioli LV. (1980) Prolactin-secreting pituitary tumor associated with von Recklinghausen's disease. Arch Intern Med, 140: 397-399.

168. Nakajima M, Nakasu Y, Nakasu S, Matsuda M, Handa J. (1990) [Pituitary adenoma associated with neurofibromatosis: case report]. Nihon Geka Hokan, 59: 278-282.

169. Kurozumi K, Tabuchi A, Ono Y, Tamiya T, Ohmoto T, Furuta T, Hamasaki S. (2002) [Pituitary adenoma associated with neurofibromatosis type 1: case report]. No Shinkei Geka, 30: 741-745.

170. Gatta-Cherifi B, Chabre O, Murat A, Niccoli P, Cardot-Bauters C, Rohmer V, Young J, Delemer B, Du Boullay H, Verger MF, Kuhn JM, Sadoul JL, Ruszniewski P, Beckers A, Monsaingeon M, Baudin E, Goudet P, Tabarin A. (2012) Adrenal involvement in MEN1. Analysis of 715 cases from the Groupe d'etude des Tumeurs Endocrines database. Eur J Endocrinol, 166: 269-279.

171. Woodward ER, Maher ER. (2006) Von Hippel-Lindau disease and endocrine tumour susceptibility. Endocr Relat Cancer, 13: 415-425.

172. Ong KR, Woodward ER, Killick P, Lim C, Macdonald F, Maher ER. (2007) Genotype-phenotype correlations in von Hippel-Lindau disease. Hum Mutat, 28: 143-149.

173. Tudorancea A, Francois P, Trouillas J, Cottier JP, Girard JJ, Jan M, Gilbert-Dussardier B, Richard S, Lecomte P. (2012) Von Hippel-Lindau disease and

aggressive GH-PRL pituitary adenoma in a young boy. Ann Endocrinol (Paris), 73: 37-42.

174. Bausch B, Borozdin W, Neumann HP. (2006) Clinical and genetic characteristics of patients with neurofibromatosis type 1 and pheochromocytoma. N Engl J Med, 354: 2729-2731.

175. Kantorovich V, King KS, Pacak K. (2010) SDH-related pheochromocytoma and paraganglioma. Best Pract Res Clin Endocrinol Metab, 24: 415-424.

176. Bardella C, Pollard PJ, Tomlinson I. (2011) SDH mutations in cancer. Biochim Biophys Acta, 1807: 1432-1443.

177. Baysal BE. (2013) Mitochondrial complex II and genomic imprinting in inheritance of paraganglioma tumors. Biochim Biophys Acta, 1827: 573-577.

178. Kasuki Jomori de Pinho L, Vieira Neto L, Armondi Wildemberg LE, Gasparetto EL, Marcondes J, de Almeida Nunes B, Takiya CM, Gadelha MR. (2011) Low aryl hydrocarbon receptor-interacting protein expression is a better marker of invasiveness in somatotropinomas than Ki-67 and p53. Neuroendocrinology, 94: 39-48.

179. Jaffrain-Rea ML, Angelini M, Gargano D, Tichomirowa MA, Daly AF, Vanbellinghen JF, D'Innocenzo E, Barlier A, Giangaspero F, Esposito V, Ventura L, Arcella A, Theodoropoulou M, Naves LA, Fajardo C, Zacharieva S, Rohmer V, Brue T, Gulino A, Cantore G, Alesse E, Beckers A. (2009) Expression of aryl hydrocarbon receptor (AHR) and AHR-interacting protein in pituitary adenomas: pathological and clinical implications. Endocr Relat Cancer, 16: 1029-1043.

180. Giustina A, Chanson P, Bronstein MD, Klibanski A, Lamberts S, Casanueva FF, Trainer P, Ghigo E, Ho K, Melmed S. (2010) A consensus on criteria for cure of acromegaly. J Clin Endocrinol Metab, 95: 3141-3148.

181. Chahal HS, Trivellin G, Leontiou CA, Alband N, Fowkes RC, Tahir A, Igreja SC, Chapple JP, Jordan S, Lupp A, Schulz S, Ansorge O, Karavitaki N, Carlsen E, Wass JA, Grossman AB, Korbonits M. (2012) Somatostatin analogs modulate AIP in somatotroph adenomas: the role of the ZAC1 pathway. J Clin Endocrinol Metab, 97: E1411-1420.

182. Knosp E, Steiner E, Kitz K, Matula C. (1993) Pituitary adenomas with invasion of the cavernous sinus space: a magnetic resonance imaging classification compared with surgical findings. Neurosurgery, 33: 610-617; discussion 617-618.

183. Ferner RE, Huson SM, Thomas N, Moss C, Willshaw H, Evans DG, Upadhyaya M, Towers R, Gleeson M, Steiger C, Kirby A. (2007) Guidelines for the diagnosis and management of individuals with neurofibromatosis 1. J Med Genet, 44: 81-88.

184. Leontiou CA, Gueorguiev M, van der Spuy J, Quinton R, Lolli F, Hassan S, Chahal HS, Igreja SC, Jordan S, Rowe J, Stolbrink M, Christian HC, Wray J, Bishop-Bailey D, Berney DM, Wass JA, Popovic V, Ribeiro-Oliveira A, Jr., Gadelha MR, Monson JP, Akker SA, Davis JR, Clayton RN, Yoshimoto K, Iwata T, Matsuno A, Eguchi K, Musat M, Flanagan D, Peters G, Bolger GB, Chapple JP, Frohman LA, Grossman AB, Korbonits M. (2008) The role of the aryl hydrocarbon receptor-interacting protein gene in familial and sporadic pituitary adenomas. J Clin Endocrinol Metab, 93: 2390-2401.

185. Korbonits M, Storr H, Kumar AV. (2012) Familial pituitary adenomas - who should be tested for AIP mutations? Clin Endocrinol (Oxf), 77: 351-356.

186. Owens M, Stals K, Ellard S, Vaidya B. (2009) Germline mutations in the CDKN1B gene encoding p27 Kip1 are a rare cause of multiple endocrine neoplasia type 1. Clin Endocrinol (Oxf), 70: 499-500.

187. Schouten JP, McElgunn CJ, Waaijer R, Zwijnenburg D, Diepvens F, Pals G. (2002) Relative quantification of 40 nucleic acid sequences by multiplex ligation-dependent probe amplification. Nucleic Acids Res, 30: e57.

188. Rattenberry E, Vialard L, Yeung A, Bair H, McKay K, Jafri M, Canham N, Cole TR, Denes J, Hodgson SV, Irving R, Izatt L, Korbonits M, Kumar AV, Lalloo F, Morrison PJ, Woodward ER, Macdonald F, Wallis Y, Maher ER. (2013) A comprehensive next generation sequencing-based genetic testing strategy to improve diagnosis of inherited pheochromocytoma and paraganglioma. J Clin Endocrinol Metab, 98: E1248-1256.

189. Chahal HS, Stals K, Unterlander M, Balding DJ, Thomas MG, Kumar AV, Besser GM, Atkinson AB, Morrison PJ, Howlett TA, Levy MJ, Orme SM,

Akker SA, Abel RL, Grossman AB, Burger J, Ellard S, Korbonits M. (2011) AIP mutation in pituitary adenomas in the 18th century and today. N Engl J Med, 364: 43-50.

190. Kasuki L, Wildemberg LE, Neto LV, Marcondes J, Takiya CM, Gadelha MR. (2013) Ki-67 is a predictor of acromegaly control with octreotide LAR independent of SSTR2 status and relates to cytokeratin pattern. Eur J Endocrinol, 169: 217-223.

191. Obari A, Sano T, Ohyama K, Kudo E, Qian ZR, Yoneda A, Rayhan N, Mustafizur Rahman M, Yamada S. (2008) Clinicopathological features of growth hormone-producing pituitary adenomas: difference among various types defined by cytokeratin distribution pattern including a transitional form. Endocr Pathol, 19: 82-91.

192. Kasuki L, Vieira Neto L, Wildemberg LE, Colli LM, de Castro M, Takiya CM, Gadelha MR. (2012) AIP expression in sporadic somatotropinomas is a predictor of the response to octreotide LAR therapy independent of SSTR2 expression. Endocr Relat Cancer, 19: L25-29.

193. Sassolas G, Chayvialle JA, Partensky C, Berger G, Trouillas J, Berger F, Claustrat B, Cohen R, Girod C, Guillemin R. (1983) [Acromegaly, clinical expression of the production of growth hormone releasing factor in pancreatic tumors]. Ann Endocrinol (Paris), 44: 347-354.

194. Berger G, Trouillas J, Bloch B, Sassolas G, Berger F, Partensky C, Chayvialle JA, Brazeau P, Claustrat B, Lesbros F, et al. (1984) Multihormonal carcinoid tumor of the pancreas. Secreting growth hormone-releasing factor as a cause of acromegaly. Cancer, 54: 2097-2108.

195. Harding B, Lemos MC, Reed AA, Walls GV, Jeyabalan J, Bowl MR, Tateossian H, Sullivan N, Hough T, Fraser WD, Ansorge O, Cheeseman MT, Thakker RV. (2009) Multiple endocrine neoplasia type 1 knockout mice develop parathyroid, pancreatic, pituitary and adrenal tumours with hypercalcaemia, hypophosphataemia and hypercorticosteronaemia. Endocr Relat Cancer, 16: 1313-1327.

196. Gill AJ, Benn DE, Chou A, Clarkson A, Muljono A, Meyer-Rochow GY, Richardson AL, Sidhu SB, Robinson BG, Clifton-Bligh RJ. (2010)

Immunohistochemistry for SDHB triages genetic testing of SDHB, SDHC, and SDHD in paraganglioma-pheochromocytoma syndromes. Hum Pathol, 41: 805-814.

197. Pabinger S, Thallinger GG, Snajder R, Eichhorn H, Rader R, Trajanoski Z. (2009) QPCR: Application for real-time PCR data management and analysis. BMC Bioinformatics, 10: 268.

198. Hsu SD, Chu CH, Tsou AP, Chen SJ, Chen HC, Hsu PW, Wong YH, Chen YH, Chen GH, Huang HD. (2008) miRNAMap 2.0: genomic maps of microRNAs in metazoan genomes. Nucleic Acids Res, 36: D165-169.

199. Lu J, Getz G, Miska EA, Alvarez-Saavedra E, Lamb J, Peck D, Sweet-Cordero A, Ebert BL, Mak RH, Ferrando AA, Downing JR, Jacks T, Horvitz HR, Golub TR. (2005) MicroRNA expression profiles classify human cancers. Nature, 435: 834-838.

200. Patel MI, Tuckerman R, Dong Q. (2005) A Pitfall of the 3-(4,5-dimethylthiazol-2-yl)-5(3-carboxymethonyphenol)-2-(4-sulfophenyl)-2H-tetra zolium (MTS) assay due to evaporation in wells on the edge of a 96 well plate. Biotechnol Lett, 27: 805-808.

201. Trivellin G, Butz H, Delhove J, Igreja S, Chahal HS, Zivkovic V, McKay T, Patocs A, Grossman AB, Korbonits M. (2012) MicroRNA miR-107 is overexpressed in pituitary adenomas and in vitro inhibits the expression of aryl hydrocarbon receptor-interacting protein (AIP). Am J Physiol Endocrinol Metab, 303: E708-719.

202. Rodriguez LG, Wu X, Guan JL. (2005) Wound-healing assay. Methods Mol Biol, 294: 23-29.

203. Igreja S, Chahal HS, King P, Bolger GB, Srirangalingam U, Guasti L, Chapple JP, Trivellin G, Gueorguiev M, Guegan K, Stals K, Khoo B, Kumar AV, Ellard S, Grossman AB, Korbonits M. (2010) Characterization of aryl hydrocarbon receptor interacting protein (AIP) mutations in familial isolated pituitary adenoma families. Hum Mutat, 31: 950-960.

204. Daly AF, Vanbellinghen JF, Khoo SK, Jaffrain-Rea ML, Naves LA, Guitelman MA, Murat A, Emy P, Gimenez-Roqueplo AP, Tamburrano G, Raverot G, Barlier A, De Herder W, Penfornis A, Ciccarelli E, Estour B, Lecomte P, Gatta

B, Chabre O, Sabate MI, Bertagna X, Garcia Basavilbaso N, Stalldecker G, Colao A, Ferolla P, Wemeau JL, Caron P, Sadoul JL, Oneto A, Archambeaud F, Calender A, Sinilnikova O, Montanana CF, Cavagnini F, Hana V, Solano A, Delettieres D, Luccio-Camelo DC, Basso A, Rohmer V, Brue T, Bours V, Teh BT, Beckers A. (2007) Aryl hydrocarbon receptor-interacting protein gene mutations in familial isolated pituitary adenomas: analysis in 73 families. J Clin Endocrinol Metab, 92: 1891-1896.

205. Zatelli MC, Torre ML, Rossi R, Ragonese M, Trimarchi F, degli Uberti E, Cannavo S. (2013) Should aip gene screening be recommended in family members of FIPA patients with R16H variant? Pituitary, 16: 238-244.

206. Mumby C, Davis JR, Trouillas J, Higham CE. (2014) Phaeochromocytoma and Acromegaly: a unifying diagnosis. Endocrinol Diabetes Metab Case Rep, 2014: 140036.

207. Brahma A, Heyburn P, Swords F. (2009) Familial prolactinoma occuring in association with SDHB mutation positive paraganglioma. Endocrine Abstracts, 19: P239.

208. Boguszewski CL, Fighera TM, Bornschein A, Marques FM, Denes J, Rattenbery E, Maher ER, Stals K, Ellard S, Korbonits M. (2012) Genetic studies in a coexistence of acromegaly, pheochromocytoma, gastrointestinal stromal tumor (GIST) and thyroid follicular adenoma. Arq Bras Endocrinol Metabol, 56: 507-512.

209. Banks RE, Tirukonda P, Taylor C, Hornigold N, Astuti D, Cohen D, Maher ER, Stanley AJ, Harnden P, Joyce A, Knowles M, Selby PJ. (2006) Genetic and epigenetic analysis of von Hippel-Lindau (VHL) gene alterations and relationship with clinical variables in sporadic renal cancer. Cancer Res, 66: 2000-2011.

210. Gadelha MR, Kasuki L, Korbonits M. (2013) Novel pathway for somatostatin analogs in patients with acromegaly. Trends Endocrinol Metab, 24: 238-246.

211. Fougner SL, Casar-Borota O, Heck A, Berg JP, Bollerslev J. (2012) Adenoma granulation pattern correlates with clinical variables and effect of somatostatin analogue treatment in a large series of patients with acromegaly. Clin Endocrinol (Oxf), 76: 96-102.

212. Hermeking H. (2010) The miR-34 family in cancer and apoptosis. Cell Death Differ, 17: 193-199.

213. Mao ZG, He DS, Zhou J, Yao B, Xiao WW, Chen CH, Zhu YH, Wang HJ. (2010) Differential expression of microRNAs in GH-secreting pituitary adenomas. Diagn Pathol, 5: 79.

214. D'Angelo D, Palmieri D, Mussnich P, Roche M, Wierinckx A, Raverot G, Fedele M, Maria Croce C, Trouillas J, Fusco A. (2012) Altered microRNA expression profile in human pituitary GH adenomas: down-regulation of miRNA targeting HMGA1, HMGA2, and E2F1. J Clin Endocrinol Metab, 97: E1128-1138.

215. Vogt M, Munding J, Gruner M, Liffers ST, Verdoodt B, Hauk J, Steinstraesser L, Tannapfel A, Hermeking H. (2011) Frequent concomitant inactivation of miR-34a and miR-34b/c by CpG methylation in colorectal, pancreatic, mammary, ovarian, urothelial, and renal cell carcinomas and soft tissue sarcomas. Virchows Arch, 458: 313-322.

216. Yan K, Gao J, Yang T, Ma Q, Qiu X, Fan Q, Ma B. (2012) MicroRNA-34a inhibits the proliferation and metastasis of osteosarcoma cells both in vitro and in vivo. PLoS One, 7:e33778.

217. Rizzo M, Mariani L, Cavallini S, Simili M, Rainaldi G. (2012) The over-expression of miR-34a fails to block DoHH2 lymphoma cell proliferation by reducing p53 via c-MYC down-regulation. Nucleic Acid Ther, 22: 283-288.

218. Sotillo E, Laver T, Mellert H, Schelter JM, Cleary MA, McMahon S, Thomas-Tikhonenko A. (2011) Myc overexpression brings out unexpected antiapoptotic effects of miR-34a. Oncogene, 30: 2587-2594.

219. Kastl L, Brown I, Schofield AC. (2012) miRNA-34a is associated with docetaxel resistance in human breast cancer cells. Breast Cancer Res Treat, 131: 445-454.

220. Chang TC, Wentzel EA, Kent OA, Ramachandran K, Mullendore M, Lee KH, Feldmann G, Yamakuchi M, Ferlito M, Lowenstein CJ, Arking DE, Beer MA, Maitra A, Mendell JT. (2007) Transactivation of miR-34a by p53 broadly influences gene expression and promotes apoptosis. Mol Cell, 26: 745-752.

221. Daly AF, Tichomirowa MA, Petrossians P, Heliovaara E, Jaffrain-Rea ML, Barlier A, Naves LA, Ebeling T, Karhu A, Raappana A, Cazabat L, De Menis E, Montanana CF, Raverot G, Weil RJ, Sane T, Maiter D, Neggers S, Yaneva M, Tabarin A, Verrua E, Eloranta E, Murat A, Vierimaa O, Salmela PI, Emy P, Toledo RA, Sabate MI, Villa C, Popelier M, Salvatori R, Jennings J, Longas AF, Labarta Aizpun JI, Georgitsi M, Paschke R, Ronchi C, Valimaki M, Saloranta C, De Herder W, Cozzi R, Guitelman M, Magri F, Lagonigro MS, Halaby G, Corman V, Hagelstein MT, Vanbellinghen JF, Barra GB, Gimenez-Roqueplo AP, Cameron FJ, Borson-Chazot F, Holdaway I, Toledo SP, Stalla GK, Spada A, Zacharieva S, Bertherat J, Brue T, Bours V, Chanson P, Aaltonen LA, Beckers A. (2010) Clinical characteristics and therapeutic responses in patients with germ-line AIP mutations and pituitary adenomas: an international collaborative study. J Clin Endocrinol Metab, 95: E373-383.

222. Bernardo BC, Gao XM, Winbanks CE, Boey EJ, Tham YK, Kiriazis H, Gregorevic P, Obad S, Kauppinen S, Du XJ, Lin RC, McMullen JR. (2012) Therapeutic inhibition of the miR-34 family attenuates pathological cardiac remodeling and improves heart function. Proc Natl Acad Sci U S A, 109: 17615-17620.

223. Anand S, Majeti BK, Acevedo LM, Murphy EA, Mukthavaram R, Scheppke L, Huang M, Shields DJ, Lindquist JN, Lapinski PE, King PD, Weis SM, Cheresh DA. (2010) MicroRNA-132-mediated loss of p120RasGAP activates the endothelium to facilitate pathological angiogenesis. Nat Med, 16: 909-914.

224. Herincs M, Owusu-Antwi S, Chahal HS, Kumar SR, Ozfirat Z, Grossman AB, Druce MR, Akker SA, Drake WM, Korbonits M. (2013) Prevalence of familial isolated pituitary adenomas. Endocrine Abstracts, 31: P258.

225. Srirangalingam U, Khan F, Gunganah K, Sahdev A, Waterhouse M, Druce MR, Drake WM, Akker SA. (2014) SDHB surveillance regime: a single UK institution experience. Endocrine Abstracts, 34: P188.

226. Klijanienko J, Lagace R. Particular aspects. In: Klijanienko J, Lagace R (eds.), Soft Tissue Tumors: A Multidisciplinary Decisional Diagnostic Approach. Hoboken, New Jersey: John Wiley Blackwell, 2011: 121-411.

227. Necchi V, Sommi P, Vanoli A, Manca R, Ricci V, Solcia E. (2011) Proteasome particle-rich structures are widely present in human epithelial neoplasms: correlative light, confocal and electron microscopy study. PLoS One, 6: e21317.
228. Ishikawa T, Miyaishi S, Tachibana T, Ishizu H, Zhu BL, Maeda H. (2004) Fatal hypothermia related vacuolation of hormone-producing cells in the anterior pituitary. Leg Med (Tokyo), 6: 157-163.
229. Doberentz E, Preuss-Wossner J, Kuchelmeister K, Madea B. (2011) Histological examination of the pituitary glands in cases of fatal hypothermia. Forensic Sci Int, 207: 46-49.
230. Kurelac I, MacKay A, Lambros MB, Di Cesare E, Cenacchi G, Ceccarelli C, Morra I, Melcarne A, Morandi L, Calabrese FM, Attimonelli M, Tallini G, Reis-Filho JS, Gasparre G. (2013) Somatic complex I disruptive mitochondrial DNA mutations are modifiers of tumorigenesis that correlate with low genomic instability in pituitary adenomas. Hum Mol Genet, 22: 226-238.
231. Housley SL, Lindsay RS, Young B, McConachie M, Mechan D, Baty D, Christie L, Rahilly M, Qureshi K, Fleming S. (2010) Renal carcinoma with giant mitochondria associated with germ-line mutation and somatic loss of the succinate dehydrogenase B gene. Histopathology, 56: 405-408.
232. Srigley JR, Delahunt B, Eble JN, Egevad L, Epstein JI, Grignon D, Hes O, Moch H, Montironi R, Tickoo SK, Zhou M, Argani P. (2013) The International Society of Urological Pathology (ISUP) Vancouver Classification of Renal Neoplasia. Am J Surg Pathol, 37: 1469-1489.
233. Horoupian DS. (1980) Large mitochondria in a pituitary adenoma with hyperprolactinemia. Cancer, 46: 537-542.
234. Horvath E, Kovacs K, Singer W, Smyth HS, Killinger DW, Erzin C, Weiss MH. (1981) Acidophil stem cell adenoma of the human pituitary: clinicopathologic analysis of 15 cases. Cancer, 47: 761-771.
235. Kroemer G. (2006) Mitochondria in cancer. Oncogene, 25: 4630-4632.
236. Zhan X, Desiderio DM. (2010) Signaling pathway networks mined from human pituitary adenoma proteomics data. BMC Med Genomics, 3: 13.

12. Bibliography of the candidate's publications

Related to the thesis:

1. Dénes J, Korbonits M, Hubina E, Kovács GL, Kovács L, Görömbey Z, Czirják S, Góth. (2011) Familial isolated pituitary adenoma syndrome. Orv Hetil, 152: 722-730.

2. Boguszewski CL, Fighera TM, Bornschein A, Marques FM, **Dénes J**, Rattenbery E, Maher ER, Stals K, Ellard S, Korbonits M. (2012) Genetic studies in a coexistence of acromegaly, pheochromocytoma, gastrointestinal stromal tumor (GIST) and thyroid follicular adenoma. Arq Bras Endocrinol Metabol, 56: 507-512. IF: 0.682

3. Rattenberry E, Vialard L, Yeung A, Bair H, McKay K, Jafri M, Canham N, Cole TR, **Denes J**, Hodgson SV, Irving R, Izatt L, Korbonits M,Kumar AV, Lalloo F, Morrison PJ, Woodward ER, Macdonald F, Wallis Y, Maher ER. (2013) A comprehensive next generation sequencing based genetic testing strategy to improve diagnosis of inherited pheochromocytoma and paraganglioma. J Clin Endocrinol Metab, 98: E1248-56. IF: 6.310

4. **Dénes J**, Kasuki L, Trivellin G, Colli LM, Takiya CM, Stiles CE, Barry S, De Castro M, Gadelha M, Korbonits M. (2015) Regulation of aryl hydrocarbon receptor interacting protein (AIP) protein expression by miR-34a in sporadic somatotropinomas. PlosOne, 10: e0117107. IF: 3.534

5. **Dénes J**, Swords F, Rattenberry E, Stals K, Owens M, Cranston T, Xekouki P, Moran L, Kumar A, Wassif C, Fersht N, Baldeweg SE, Morris D, Lightman S, Agha A, Rees A, Grieve J, Powell M, Luiz Boguszewski C, Dutta P, Thakker RV, Srirangalingam U, Thompson CJ, Druce M, Higham C, Davis J, Eeles R, Stevenson M, O'Sullivan B, Taniere P, Skordilis K, Gabrovska P, Barlier A, Webb SM, Aulinas A, Drake WM, Bevan JS, Preda C, Dalantaeva N, Ribeiro-Oliveira A Jr, Tena Garcia I, Yordanova G, Iotova V, Evanson J, Grossman AB, Trouillas J, Ellard S, Stratakis CA, Maher ER, Roncaroli F, Korbonits M. (2015) Heterogeneous genetic background of the association of pheochromocytoma/paraganglioma and pituitary adenoma - results from a large patient cohort. J Clin Endocrinol Metab, 100: E531-541. IF: 6.310

Not related to the thesis:

1. Dénes J, Korbonits M, Hubina E, Góth M. (2010) The treatment of acromegaly. Orv Hetil, 151: 1384-1393.

2. Dénes J, Hubina E, Góth M. (2011) Growth hormone replacement therapy in growth hormone deficient adults. Háziorvos Továbbképző Szemle (Journal of Postgraduate Course for General Practioner), 16: 389.

3. Kovács GL, **Dénes J**, Hubina E, Kovács L, Czirják S, Góth M. (2011) The change of consensus on criteria for cure of acromegaly during the last decade. Orv Hetil, 152: 703-708.

4. Hubina E, Tóth Á, Kovács GL, **Dénes J**, Kovács L, Góth M. (2011) Growth hormone receptor antagonist int he treatment of acromegaly. Orv Hetil, 152: 709-714.

5. Kovács GL, Szabolcs I, Görömbey Z, Kovács L, Hubina E, **Dénes J**, Kósa R, Góth M. (2011) The possible connection between Borrelia burgdorferi and Riedel thyreoiditis. Case report and review of the literature. Magy Belorv Arch, 64: 300-306.

6. Dinesen PT, Dal J, Gabrovska P, Gaustadnes M, Gravholt CH, Stals K, **Denes J**, Asa SL, Korbonits M, Jørgensen OL. (2015) An unusual case of an adrenocorticotropin-secreting macroadenoma with a germline variant in the aryl hydrocarbon receptor interacting protein (AIP) gene. Endocrinol Diabetes Metab Case Rep, 2015: 140105.

13. Acknowledgements

I would like to express my deepest gratitude to all those who partecipated in this study:

My supervisor Professor Miklós Góth for giving me the opportunity to work at the Division of Endocrinology, 2nd Department of Medicine, Health Center and for his guidance, support and encouragement throughout the years of my PhD.

My consultant Professor Márta Korbonits for accepting me in her group at the Department of Endocrinology, William Harvey Research Institute, Queen Mary University of London and giving me the opportunity to work in the laboratory, she and the members of her group for their constant support and help in my study with their profound knowledge of endocrinology and genetics.

Monica Gadelha and Leandro Kasuki from Clementino Fraga Filho University Hospital, Federal University of Rio de Janeiro, Brazil, who performed part of the experiments for their collaboration.

The members of the Division of Endocrinology, 2nd Department of Medicine, Health Center, Hungarian Defense Forces for their support and guidance in the field of endocrinology.

The head of the Neuromorphological and Neuroendocrine Laboratory, Department of Human Morphology and Developmental Biology, Semmelweis University, Professor György M Nagy and Ibolya Bodnár for giving me the opportunity to work in their laboratory and teaching me the essential laboratory methods.

My family and friends, for their support and practical help during all these years.

My husband for his trust, patience and support during these years.