

Pneumothorax, Pneumomediastinum and Pneumoperitoneum in a 10-Year-Old Girl Following Colonoscopy

Eszter Vojcek¹, Barbara Vatai, Gabor Veres, Peter Vörös, Attila Szabó and Csaba Lódi

Department of Pediatrics, Semmelweis University, Budapest, Hungary

***Corresponding author:** Eszter Vojcek, Department of Pediatrics, Semmelweis University, Bókay János u. 53-54, Budapest, 1083, Hungary, Tel: 00-36-70-556-1188; E-mail: vojcekeszter@gmail.com

Received date: Jun 12, 2017; **Accepted date:** Jun 22, 2017; **Published date:** Jun 26, 2017

Copyright: © 2017 Vojcek E, et al. This is an open-access article distributed under the terms of the Creative Commons Attribution License, which permits unrestricted use, distribution and reproduction in any medium, provided the original author and source are credited.

Abstract

Colonic perforation is an uncommon but severe complication of colonoscopy. We present a case of a 10-year-old girl who was treated conservatively for inflammatory bowel disease for 6 years. She underwent a diagnostic colonoscopy after which she developed acute respiratory failure. Urgent bedside imaging series revealed pneumothorax, pneumomediastinum and pneumoperitoneum. A chest tube was immediately inserted, and then she was intubated and ventilated. Laparotomy revealed a 1 cm wide perforation of the transverse colon. The rupture was closed and a terminal ileostomy was performed. The postoperative course was uneventful. To best of our knowledge no other case of pneumothorax, pneumomediastinum and pneumoperitoneum after colonoscopy in children has been reported so far in literature.

Keywords: Pneumothorax; Pneumomediastinum; Pneumoperitoneum; Colonoscopy; Inflammatory bowel disease

Abbreviations:

PTX: Pneumothorax; IBD: Inflammatory Bowel Disease; PICU: Pediatric Intensive Care Unit; ASGE: American Society for Gastrointestinal Endoscopy

Introduction

Colonic perforation is an unusual complication of colonoscopy. According to literature the risk for rupture varies between 0.2% to 0.5% of diagnostic colonoscopies and up to 2% of therapeutic colonoscopies [1-4]. Rectosigmoid junction and cecal area are considered to be to most common sites of injury [5].

Potential causes of colonic perforation during flexible fiberoptic colonoscopy may be barotrauma from excessive air inflation, mechanical trauma caused by the colonoscope or biopsy forceps, and therapeutic associated trauma [6]. Depending on the location and mechanism of trauma, colonic rupture may leak into either the peritoneum or retroperitoneum causing pneumoretroperitoneum. “Triple pneumo” is the combination of pneumothorax (PTX), pneumomediastinum and pneumoperitoneum following colonoscopy [7].

Generally retroperitoneal perforations have a more favorable outcome because they are embraced, however from the retroperitoneal space air may spread to any cavity connected with the visceral space [8].

Case Presentation

A 10-year-old girl suffering from inflammatory bowel disease (IBD) has been treated conservatively for 6 years. She did not respond to the internationally recommended medications for ulcerative colitis including steroids, azathioprine, mesalazine, infliximab and

adalimumab medication. Therefore she underwent a diagnostic gastro- and colonoscopy prior to a planned total colectomy. Colonoscopy revealed severe inflammation, pseudopolyps and granulated layer throughout the entire colon and ulceration of the distal part of the colon was prominent. After colonoscopy the patient developed acute respiratory failure. Subcutan emphysema was palpable in her face, neck and chest. The patient was moved to Pediatric Intensive Care Unit (PICU). On admission her vital parameters were unstable, she suffered from extreme chest discomfort and decreased air entry was audible on the left side of her chest.

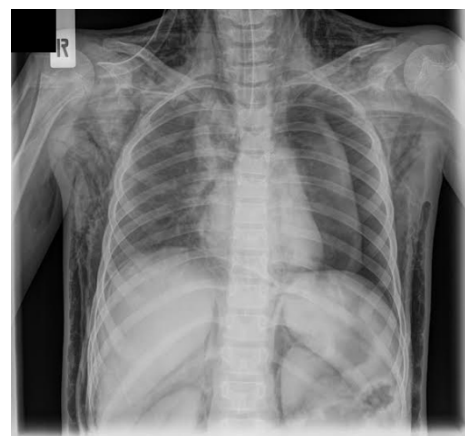

Figure 1: Urgent chest imaging studies revealed left-sided PTX and pneumomediastinum. Neck and chest subcutan emphysema was visible.

Urgent chest and abdominal imaging studies revealed left sided PTX and pneumomediastinum (Figure 1) and an extended pneumoperitoneum with retroperitoneal free air (Figure 2). Neck,

chest and abdominal subcutan emphysema was visible. A chest tube was immediately inserted and then she was intubated and ventilated. Laparotomy revealed a 1 cm wide perforation of the transverse colon (Figure 3) with multiple air bubbles in the mesocolon and omentum (Figure 4). The perforation was closed and a terminal ileostomy was performed. Abdominal tube was inserted. Biopsy supported the diagnosis of severe ulcerative colitis. The patient remained intubated and mechanically ventilated for 1 day postoperatively. She was treated with combined antibiotic therapy (ceftriaxone and metronidazol) for 5 days and received a red blood cell transfusion while being admitted to PICU. The chest and abdominal tubes were removed on the third postoperative day and the patient was successfully transferred back to general ward on the 8th postoperative day. Two months after the intervention she is now scheduled for total colectomy and ileorectal anastomosis with pouch formation.

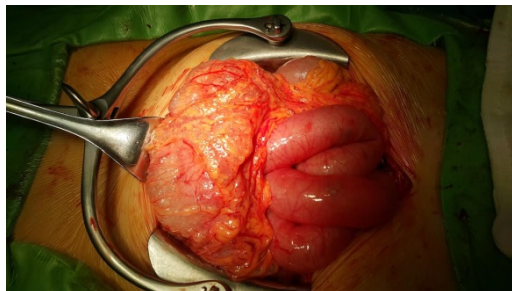


Figure 4: Large amount of air bubbles in the omentum and mesocolon.

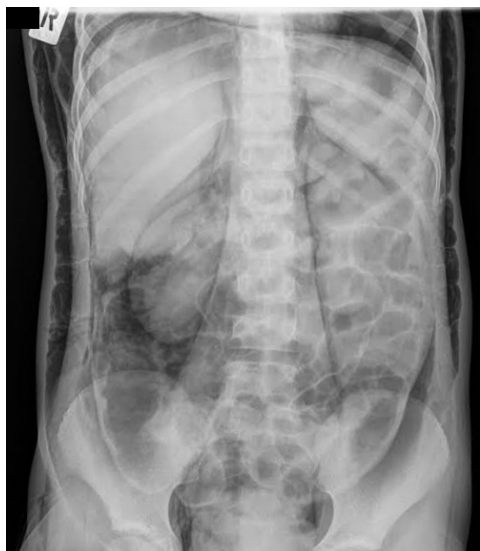

Figure 2: Urgent abdominal imaging studies revealed an extended pneumoperitoneum with retroperitoneal free air. Abdominal subcutan emphysema was visible.

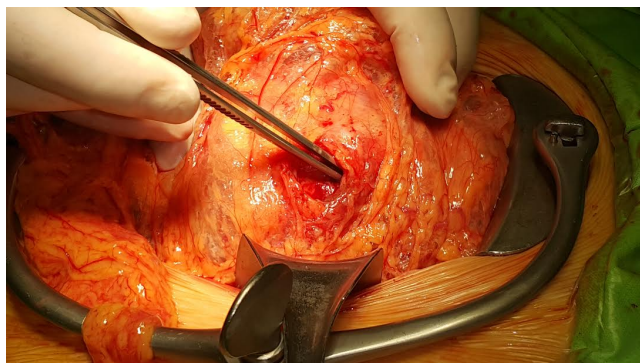


Figure 3: 1 cm wide perforation of the transverse colon was found.

Discussion

PTX after colonic perforation may develop through multiple mechanisms.

- The diaphragm separates the chest and the abdomen however three anterior hiatus remain that allow air to spread from the abdominal cavity to the parietal pleura and space: one between the two slips from the back of xiphoid process and two parasagittal opening between the sternal and costal adherence of the diaphragm through which the internal mammary vessels run. Air travels along these fascial tissues, and it may also spread into the surrounding cavities [9].
- Behind the diaphragm the endothoracic and transversalis fasciae, as well as the aortic and oesophageal hiatus offer a direct route for free gas movement.
- Gas may cross the peritoneum through small apertures in the diaphragm and fill the pleural space along a pressure gradient [3,9].
- The anatomy of visceral area in the neck and chest creates a direct route to the mediastinum and may also be responsible for the PTX and predispose a patient to pneumopericardium [9].
- Similarly gas may travel in the perivertebral space that enables a free diffusion between the mediastinum and the neck [2,4,9].

Data shows that there are certain risk factors for colonic perforations. Therapeutic colonoscopies have a significantly higher possibility of colonic perforation than diagnostic colonoscopies. Patients over 75 years of age have a 4-6 fold increase in the colonoscopic rupture rate compared to younger patients. Perforation from colonoscopy holds 2-4 times greater risk than from flexible sigmoidoscopy [10]. Patients with multiple comorbidities are also at an increased exposure [11]. Other risk factors include existing diseases of the colon such as bleeding, diverticular disease or obstruction as a cause for colonoscopy, female gender or previous intra-abdominal surgery. Certain endoscopic interventions hold an increased risk for colonic perforation such as electrosection of polyps larger than 20 mm, pneumatic dilatation for Crohn's stricture or endoscopic mucosal resection [11-13]. Our case attracted very high risk of perforation as she had a long lasting, therapy resistant (including 2 different anti-tumor necrosis factor medications) severe pancolitis waiting for total colectomy.

Approximately 85% of visceral perforations results in pneumoperitoneum. Nevertheless, pneumoperitoneum in about 5 to

15% can present without any visceral rupture and necessitates conservative treatment [14,15]. In our case, the air leakage from the diagnostic procedure was complicated by a PTX, pneumomediastinum and pneumoperitoneum.

Therapeutic approaches include conservative management consisting of bowel rest and the administration of broad-spectrum antibiotics, endoscopic management or operative treatment of open or laparoscopic intervention [12,16,17].

Approximately 50% of the perforations are diagnosed during colonoscopy, most cases are diagnosed within the first day however some of them are revealed after many days and in certain cases they remain hidden and silent [18].

Severe abdominal or chest discomfort, nausea or vomiting and fever or leukocytosis is alarming signs for perforation [1]. Nevertheless less than 50% of the perforations show symptoms during the colonoscopy [18]. Urgent imaging studies will verify the diagnosis when it is suspected.

Our case is unique since no cases of the combination of PTX, pneumomediastinum and pneumoperitoneum in children have been reported so far after diagnostic colonoscopy. The incidence of IBD in children is worldwide increasing furthermore the patients present with more severe symptoms at younger age. It is crucial that physicians be aware of these severe complications after colonoscopies in order to make a prompt diagnosis and treatment and to improve patient outcome. Patients should be observed for signs of abdominal and chest pain after colonoscopy. Discharge criteria after sedation has carefully been established in children and specific written and verbal information should be given to the parent or responsible adult following colonoscopy of the child according to the Standards of Practice Committee of the American Society for Gastrointestinal Endoscopy (ASGE) [3]. Special instructions should be given in cases in which the child travels in a car seat [3]. Each endoscopy unit should have a written protocol to follow in accordance with the national guidelines for children after colonoscopy.

Acknowledgement

We thank Professor Tivadar Tulassay of the 1st Department of Pediatrics, Semmelweis University Budapest, for his valuable comments and recommendations for this manuscript.

References

1. Kripple JC (2010) Bilateral tension pneumothoraces and subcutaneous emphysema following colonoscopic polypectomy: A case report and discussion of anesthesia considerations. *AANA J* 78: 462-467.
2. Marwan K, Farmer KC, Varley C, Chapple KS (2007) Pneumothorax, pneumomediastinum, pneumoperitoneum, pneumoretroperitoneum and subcutaneous emphysema following diagnostic colonoscopy. *Ann R Coll Surg Engl* 89: W20-W21.
3. ASGE Standards of Practice Committee, Lightdale JR, Acosta R, Shergill AK, Chandrasekhara V, et al. (2014) Modifications in endoscopic practice for pediatric patients. *Gastrointest Endosc* 79: 699-710.
4. Zeno BR, Sahn SA (2006) Colonoscopy-associated pneumothorax: A case of tension pneumothorax and review of literature. *Am J Med Sci* 332: 153-155.
5. Korman LY, Overholt BF, Box T, Winker CK (2003) Perforation during colonoscopy in endoscopic ambulatory surgical centers. *Gastrointestinal Endosc* 58: 554-557.
6. Damore LJ, Rantis PC, Vernava AM, Longo WE (1996) Colonoscopic perforations: Etiology, diagnosis, and management. *Dis Colon Rectum* 39: 1308-1314.
7. Pourmand A, Shokoohi H (2013) Tension pneumothorax, pneumoperitoneum, and cervical emphysema following a diagnostic colonoscopy. *Case Rep Emerg Med* 2013: 1-3.
8. Ball CG, Kirkpatrick AW, Mackenzie S, Bagshaw SM, Peets AD, et al. (2006) Tension pneumothorax secondary to colonic perforation during diagnostic colonoscopy: Report of a case. *Surg Today* 36: 478-480.
9. Vilaça AF, Reis AM, Vidal IM (2013) The anatomical compartments and their connections as demonstrated by ectopic air. *Insights Imaging* 4: 759-772.
10. Gatto NM, Frucht H, Sundararajan V, Jacobson JS, Grann VR, et al. (2003) Risk of perforation after colonoscopy and sigmoidoscopy: A population based study. *J Natl Cancer Inst* 95: 230-236.
11. Ettersperger L, Zeitoun P, Thieffn G (1995) Colonic perforations complicating colonoscopy. Apropos of 15 consecutive cases observed over 16 years. *Gastroenterol Clin Biol* 19: 1018-1022.
12. Lohsiriwat V (2010) Colonoscopic perforation: Incidence, risk factors, management and outcome. *World J Gastroenterol* 16: 425-430.
13. Ho HC, Burchell S, Morris P, Yu M (1996) Colon perforation, bilateral pneumothoraces, pneumopericardium, pneumomediastinum, and subcutaneous emphysema complicating endoscopic polypectomy: Anatomic and management considerations. *Am Surg* 62: 770-774.
14. McGlone FB, Vivion CG, Meir L (1966) Spontaneous pneumoperitoneum. *Gastroenterol* 51: 393-398.
15. Roh JJ, Thompson JS, Harned RK, Hodgson PE (1983) Value of pneumoperitoneum in the diagnosis of visceral perforation. *Am J Surg* 146: 830-833.
16. Webb T (1998) Pneumothorax and pneumomediastinum during colonoscopy. *Anaesth Intensive Care* 26: 302-304.
17. Orsoni P, Berdah S, Verrier C, Caamano A, Sastre B, et al. (1997) Colonic perforation due to colonoscopy: A retrospective study of 48 cases. *Endoscopy* 29: 160-164.
18. Ignjatovic M, Jovic J (2009) Tension pneumothorax, pneumoretroperitoneum and subcutaneous emphysema after colonoscopic polypectomy: A case report and review of the literature. *Langenbecks Arch Surg* 394: 185-189.