


Adjuvant role of conservative therapies in the anterior segment diseases of the eye

PhD Thesis

Dr. Huba Kiss

Semmelweis University

School of Clinical Medicine



Supervisors:

Dr. János Németh, DSc
Professor

Dr. Zoltán Zsolt Nagy, DSc
Professor

Official reviewer:

Dr. Ágnes Kerényi, PhD, Assistant Professor
Dr. Péter Kóthy, PhD, Associate Professor

Chairman of the examination committee: Dr. Miklós Sándor Zoltán Kellermayer, DSc
Professor

Members of the examination committee: Dr. Mária Éva Ferencz, PhD, Chief Physician
Dr. Csaba Sőti, DSc, Associate Professor

Budapest

2017

Introduction

In my thesis, I summarize some of our latest results demonstrating the adjuvant effects of conservative therapies in two research directions of the anterior segment of the eye, dry eye disease and cataract surgery. Although ophthalmology is becoming an increasingly surgical discipline, our results suggest that conservative therapies, such as the use of eye drops, may prevent the surgical intervention, or may improve the safety of some surgeries.

Changes of dry eye disease symptoms after treatment with Conheal® eye drops

Dry eye disease affects 5% to 30% of the population, and it is especially prevalent in post-menopausal women. Dry eye complaints are ranked as the most frequent symptoms of patients visiting ophthalmologists. Dry eye disease is induced by the complex, multifactorial pattern of decreased production of tear and/or the pathologically disturbed composition of tear film, damaging the eye surface. During dry eye disease, a chronic inflammation of the eye surface develops, which leads to pathological changes of the tissues of the eye surface. These changes damage the epithelium of the cornea and the conjunctiva. Consequently conjunctiva sags and severe conjunctivochalasis, i.e. the occurrence of Lid-Parallel-CONjunctival-Folds (LIPCOF) may develop.

The degree of conjunctivochalasis (measured in LIPCOF degree) correlates well to the other objective and subjective symptoms of dry eye disease, *viz.* tear film break-up time, and the degree of subjective symptoms measured by the Ocular Surface Disease Index (OSDI). These tests are generally accepted as a “best practice” to detect dry eye disease. Due to these reasons, we have selected these three measures together with the level of lissamine green staining assessing epithelial damages as endpoints of our investigations shown in my thesis.

The most important conservative therapy of dry eye disease is the treatment using artificial tear drops to increase the amount and/or quality of tear. Patients with dry eye symptoms buy artificial tears having a value of approx. 100 million USD per year in the USA alone.

Advanced conjunctivochalasis characterized by level 3 lid-parallel conjunctival folds (LIPCOF) may require a surgical intervention to achieve a significant decrease of dry eye symptoms. Patients with level 2 or lower LIPCOF values are usually adequately treated with conservative therapy. There is a wide range of surgical procedures applicable in severe conjunctivochalasis having a LIPCOF degree of 3, such as the surgical resection of lid-parallel conjunctival folds, or their treatment with argon laser or heat cauterization. The results of the resection of the loose conjunctiva may be improved by transplantation of amnion grafts.

Severe cases of dry eye disease, such as advanced conjunctivochalasis would greatly benefit of non-invasive, conservative therapies, which may better the general status of dry eye symptoms to a level, no longer requiring surgical intervention. In my thesis I summarize our studies demonstrating the efficiency of such a therapy.

Increase of intracameral prostaglandin level after femtosecond laser-assisted cataract surgery, with or without Nevanac® non-steroid anti-inflammatory eye drop pretreatment

The number of cataract surgeries rapidly increases worldwide. In 2010 there were approximately 20 million cataract surgeries annually. According to WHO estimates in 2020 we will have approx. 32 million cataract surgeries per year. Femtosecond laser-assisted cataract surgery has been performed first in human subjects in our Department in 2008. Since then this procedure became an EU/USA officially registered and generally used procedure due to its highly precise and reproducible results, which proved to be especially useful in the implantation of premium lenses. The continuous improvements of the laser technique help to decrease the possibility of the adverse events related to this method [Nagy et al, 2015].

In 2013 Schultz et al described first that during the femtosecond laser-assisted cataract surgery the prostaglandin content of the aqueous humour increases. Earlier studies indicated that the increase of prostaglandins during traditional cataract surgeries may play an important role in the post-surgical, occasional development of mild forms of macular edema including no clinical symptoms. Earlier studies of Schultz et al hypothesized that the elevated prostaglandin level of the aqueous humour during femtosecond laser-assisted cataract surgery also contributes to the increased miosis after the surgery.

The consequences of cataract surgery and/or femtosecond laser treatment can be attenuated by conservative preventive therapies. As one example of these therapies non-steroid anti-inflammatory drug (NSAID), such as ketorolac, bromfenac, amfenac or nepafenac, containing eye drops decrease the level of prostaglandins in the aqueous humour by inhibiting the anterior segment COX-1 and COX-2 enzymes. Earlier studies showed that pre-surgical application of NSAID drops may decrease the miosis that occurs in the one-third of all surgeries, the post-surgical inflammatory processes, the development a macula edema, as well as may diminish post-surgical pain. In agreement with these findings Schultz et al hypothesized that the use of anti-inflammatory agents in femtosecond-assisted cataract surgeries may prevent the increase of prostaglandin level in the aqueous humour, and – consequently – may decrease the occurrence of post-surgical miosis and macula edema.

Based on the above findings and assumptions our research work aimed to answer to the question, whether the pre-surgical application of non-steroid anti-inflammatory eye drops may attenuate the increase of prostaglandins in the aqueous humour during femtosecond laser-assisted cataract surgeries, and – consequently – may perhaps contribute to the decrease of post-surgical complications such as miosis or macula edema.

Aims

The aim of my doctoral work was to examine the adjuvant effects of conservative therapies (in my work: eye drops) to avoid the surgery or the post-surgical complications of the anterior segment.

1. During our work, we wanted to answer the question, whether one and/or three months regular treatment using Conheal[®] eye drops containing 0.015% sodium hyaluronate and isotonic glycerol may decrease the severity of the symptoms of patients with advanced conjunctivochalasis.
2. With our other clinical trial we wanted to answer to the question, whether non-steroid anti-inflammatory drug pretreatment of the eyes undergoing femtosecond laser-assisted cataract surgery may attenuate the increase of the prostaglandin level of the aqueous humour.

Patients and methods

Changes of dry eye disease symptoms after treatment with Conheal® eye drops

Twenty adult patients from the patients of the general outpatient unit of the Department of Ophthalmology of the Semmelweis University between the August of 2012 and July of 2013 were enrolled into our prospective study approved by the Hungarian Scientific and Research-Ethics Committee (permission No. 21455-1/2011-EKU given on 7th December 2011). Ethical principles for Medical Research Involving Human subjects were kept while conducting the trial. All patients signed an informed consent about the study. The trial was registered at the international ISRCTN database (registration number: ISRCTN81112701).

All patients have already used commercially available artificial tears regularly (17 out of the 20 for many months or years, 3 out of the 20 for a few weeks) before entering the study. Enrolled patients stopped the use of their earlier artificial tears 3 days before the first visit. Despite all of our dry eye patients have been continuously using artificial tears prior our study, they still had subjective symptoms, and their objective dry eye symptoms reached the advanced stage of LIPCOF 3. Since in spite of the use of the commercially available artificial tears each patient reached conjunctivochalasis LIPCOF grade 3 each patient served as his/her own control during the time of our study.

At the first visit the required amount of unit-doses of the preservative-free, inorganic salt-free artificial tear, Conheal® (provided by Pannonpharma Ltd., Pécsvárad, Hungary), containing isotonic glycerol and 0.015% hyaluronic acid in purified water was given to our patients. Patients were instructed to apply these artificial tears on both eyes four times a day during the three months of the study.

The severity of the conjunctivochalasis was determined in terms of LIPCOF degrees according to the Höh method. The tear-film breakup time (TFBUT) was measured by a standard method using fluorescein. Epithelial damages were detected by lissamine green staining which was evaluated according to the Oxford Scheme grade. The subjective complaints of the patients, as well as the impact of the dry eye

complaints on their everyday life were recorded by the help of the OSDI questionnaire.

During the three months long trial results of the tests were recorded at the beginning of the study, after one and three months use of the artificial tear. Results of the one-month and the three-months visits were compared to that of the results of the enrolment visit. For the comparison of ordinal data (LIPCOF degree, Oxford Scheme grade) and non-normally distributed data (OSDI) the non-parametric Wilcoxon Signed Rank Test was used, meanwhile the normally distributed data (TFBUT) were compared by the help of the parametric Paired T Test using the SPSS Statistics 22 software (IBM Corporation, Armonk, NY, USA). For conservative power estimation, the highest observed within-group standard deviation of 0.9 was supposed, and a low correlation value of 0.2 was assumed for correlated measurements performed on the same subject at month 0 and month 3. A mean decrease from baseline of 1.0 LIPCOF degree was assumed to be clinically relevant. Power estimation was performed for a paired t-test at a two-sided significance level of 5%, and corrected for the asymptotic relative efficiency of $3/\pi$ because during the statistical evaluation the Wilcoxon Signed Rank Test was applied instead. Power calculations were performed in SAS v9.4.

Measurement of the increase of intracameral prostaglandin level after femtosecond laser-assisted cataract surgery, with or without Nevanac® non-steroid anti-inflammatory eye drop pretreatment

36 adult patients of the Semmelweis University Department of Ophthalmology general outpatient unit were enrolled to our study. The study was approved by the Scientific and Research Ethics Committee of the Semmelweis University under the permission number 235/2013. The age of the patients was 62.3 ± 13.1 years. We had 3 patient groups in our study. The 12 patients of the Control group received traditional cataract surgery. The 12 patients of the FLACS group received femtosecond laser-assisted cataract surgery. The 12 patients of the NSAID group were treated by non-steroid anti-inflammatory eye drops before and on the day of the femtosecond laser-assisted cataract surgery.

In the FLACS and FLACS+NSAID patient groups anterior capsulotomy, nuclear fragmentation of the lens (using cylindrical pattern) were created by femtosecond beam produced by the LenSx® Laser System (Alcon Laboratories Inc.

Fort Worth, TX USA). After these steps a side port was created by a 15 degree stab knife and approximately 110 μL of aqueous humour was collected by the help of a cannula and a 1 mL syringe. In the “Control group” only the aqueous humour sample collection happened before the traditional phacoemulsification cataract surgery. The aqueous humour samples were put into 0.5 mL Eppendorf Tubes[®] into dry ice in the operation theater. Samples were stored on -80°C until further processing. After the collection of the aqueous humour, phacoemulsification of the lens by Alcon INFINITI[®] Vision System (Alcon Laboratories, Inc., Fort Worth, TX, USA) and lege artis posterior chamber lens implantation was performed on all patients.

Total prostaglandin concentrations of the aqueous humour samples were determined using Enzyme Immunoassay (EIA) method. Total prostaglandin levels were measured using a Prostaglandin Screening EIA Kit (Cat. #514012) distributed by Cayman Europe. The EIA kit was used as instructed by the manufacturer. 50 μL of the aqueous humour sample with 50 μL of tracer and 50 μL of antibody provided in the kit was incubated for 18 hours on 22°C . The used wells were thoroughly washed five times. Thereafter 200 μL of Ellman’s reagent was added. After 60 minutes of incubation combined by gentle shake, at 60, 75, 90 and 95 minutes the plate was read at 412 nm. Measurement values of the calibration curve correlated the most to the provided calibration curve at 90 minutes ($R>0.985$), therefore values of this time point were used for further analysis. The best-fit measured calibration curve was found by using curve fitting regression analysis.

Statistical differences between the age, anterior chamber flare, intra-operative prostaglandin levels of the 3 groups were tested by One-Way ANOVA, in case of statistically significant differences among the groups independent-samples T-tests were also performed to compare the means of the individual groups to each other. SPSS Statistics v20, IBM Corp. was used for running the statistical tests.

Results

The most important results of my work are the followings.

Changes of dry eye disease symptoms after treatment with Conheal® eye drops

The primary outcome measure of our study applying Conheal® eye drops containing 0.015% sodium hyaluronate and isotonic glycerol to patients having severe conjunctivochalasis for one or three months regularly four times a day was the measurement of conjunctivochalasis by measuring the occurrence of lid-parallel conjunctival folds (LIPCOF). The mean grade of the conjunctivochalasis was reduced on both eyes significantly at the one-month-visit, and was decreased further at the three-month-visit. After three months the grade of conjunctivochalasis was decreased from an advanced value of a mean LIPCOF degree of 2.9 ± 0.4 on both eyes to 1.4 ± 0.6 on the right (median decrease of -2 points, 95% CI from -2.0 to -1.0), and to 1.4 ± 0.7 on the left eye (median decrease of -1 points, 95% CI from -2.0 to -1.0) ($P < 0.001$ for both sides; **Figure 1**; [Kiss and Németh, 2013; 2015]). The LIPCOF degree was decreased significantly on both eyes after one month of the treatment. Significant decrease of the LIPCOF degree was not present on the left eyes between the one and three months' results. However, there was a significant decrease on the right eyes between the one and three months results. The LIPCOF degree was decreased significantly on both eyes at the end of the study compared to the enrolment ($P < 0.001$).

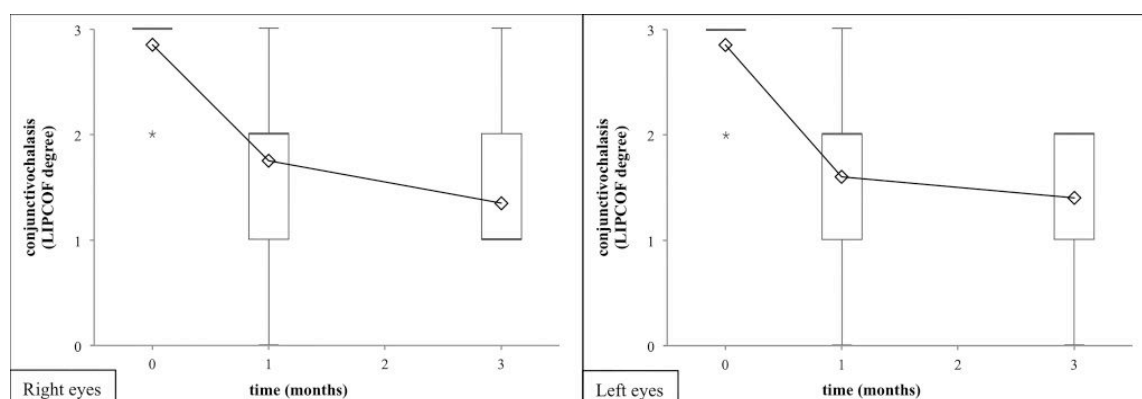


Figure 1. Degree of the conjunctivochalasis in terms of LIPCOF degrees after 1 and 3 months of artificial tear treatment. Artificial tear treatment and measurement of LIPCOF

degree on 20 patients were performed as described in section of Patients and methods. The artificial tear investigated caused a significant decrease of LIPCOF degree on both eyes after one month of use that advanced further on the right eye significantly after three months, significant decrease on the left eyes was not present during the same period. The LIPCOF degree was decreased significantly on both eyes at the end of the study compared to the enrolment ($P < 0.001$). In the box plot medians, interquartile ranges and end values of the LIPCOF degree are shown. Statistical evaluation was performed using the Wilcoxon Signed Rank Test. [Kiss and Németh, 2013; 2015].

Changes in the degree of conjunctivochalasis, as measured by LIPCOF degrees in earlier studies of the literature using liposome containing eye drops for evaporative dry eyes, were compared to the results of our study (Figure 2; [Kiss and Németh, 2013; 2015]).

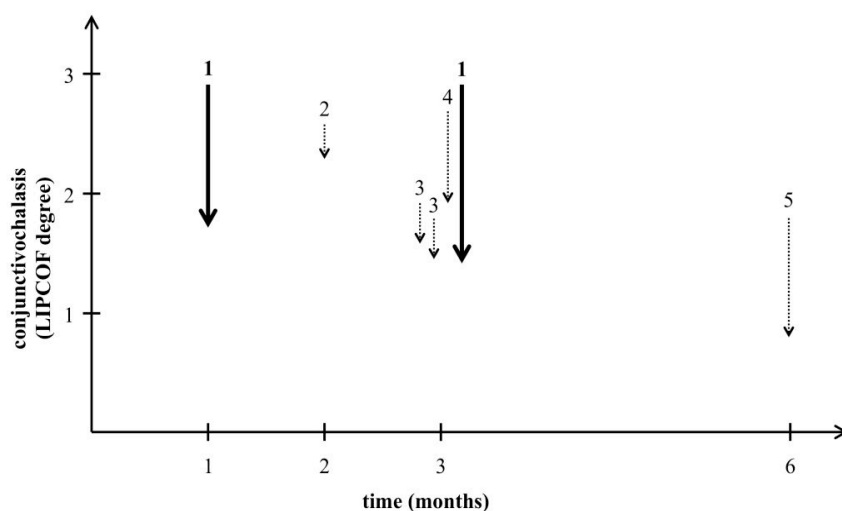


Figure 2. Comparative analysis of the decrease of conjunctivochalasis in various studies. The figure shows the decrease of the degree of conjunctivochalasis compared to that measure at the start of the treatment in previous studies using a liposome eye spray (dotted arrows) compared to our results using an isotonic glycerol and 0.015% hyaluronate-containing artificial tear (solid lines). Numbers above the arrows represent the different studies on a time scale of their duration in months [Kiss and Németh, 2015]: arrows indicated by 1 represent the result of our study, arrows indicated by numbers from 2 to 5 represent the results of the other study groups with the liposome eye spray.

After three months of Conheal[®] treatment the tear film breakup time (TFBUT) lengthened from the initial value of 4.8 s on both eyes to 5.9 s on the right eyes and 5.7 s on the left eyes. The lissamine green staining, indicating the epithelial damage of the cornea and the conjunctiva, evaluated by the application of the Oxford Scheme grade, was decreased significantly from 1.3 to 0.3 on the right eyes and from 1.4 to 0.2 on the left eyes. The subjective complaints of the patients measured with the Ocular Surface Disease Index (OSDI) questionnaire significantly improved from the initial result of 36.2 to 15.6.

Increase of intracameral prostaglandin level after femtosecond laser-assisted cataract surgery, with or without Nevanac® non-steroid anti-inflammatory eye drop pretreatment

The total prostaglandin concentration of the FLACS+NSAID group was decreased significantly to 92.2 ± 51.7 pg/mL compared to the FLACS group, that had a total prostaglandin concentration of 1449.1 ± 1019.7 pg/mL. The total prostaglandin level of the pretreated group was even lower, than that of the Control group, which was 208.8 ± 140.5 pg/mL. (**Figure 3**). [Kiss et al, 2015; 2016].

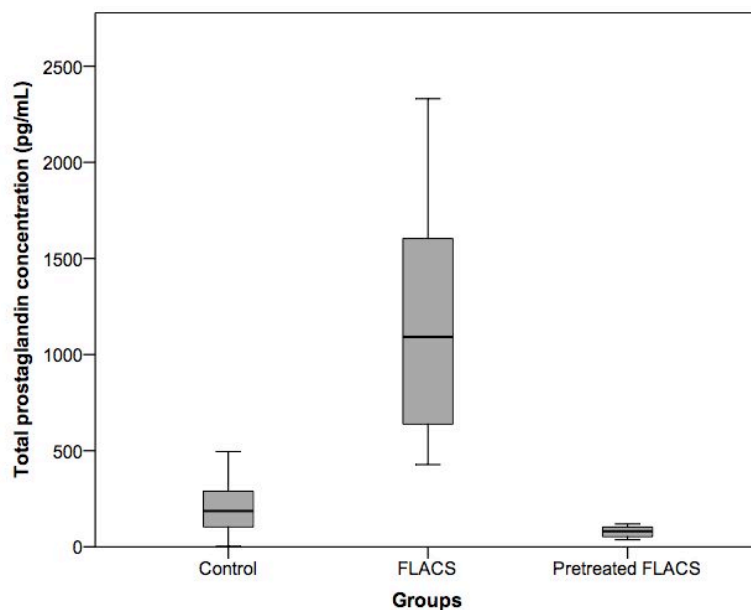


Figure 3. Nepafenac normalizes elevated intracameral total prostaglandin levels after femtosecond laser-assisted cataract surgery. The boxplot shows that the topical NSAID pretreatment (nepafenac) completely inhibited ($P < 0.001$) the intracameral total prostaglandin concentration elevation that was observed in the “FLACS group” ($P < 0.001$). The total prostaglandin concentration of the “Pretreated FLACS group” samples was even lower, than that of the “Control group” ($P < 0.01$). There were no outliers in our data. [Kiss et al, 2015; 2016].

The total prostaglandin concentration in the FLACS+NSAID group was significantly lower, than that of the FLACS group ($P < 0.001$), and was even lower than in the Control group ($P < 0,01$; **Figure 3**). [Kiss et al, 2015; 2016].

Conclusions

The most important results of my work can be summarized as follows:

1. Treatment of 20 patients, having dry eye with advanced conjunctivochalasis, for one or three month regularly, 4 times a day with Conheal[®] eye drops containing 0.015% sodium hyaluronate and isotonic glycerol, decreased the severity of dry eye disease of these patients significantly and in a clinically relevant fashion.
 - a. As the primary outcome of these studies after three months of Conheal[®] treatment the lid-parallel conjunctival folds (LIPCOF) degree of the patients was decreased from the close-to-maximal, advanced 2.9 degrees that may require a surgery to improve symptoms to less than its half, which can be successfully treated by conservative treatment.
 - b. Tear film breakup time after 3 month of Conheal[®] treatment was increased by 20% on both eyes.
 - c. Lissamine green staining showing epithelial damages of the cornea and conjunctiva was decreased from 1.3 to 0.3 and 1.4 to 0.2 in the right and left eyes, respectively due to the treatment.
 - d. The Ocular Surface Disease Index (OSDI), measuring the subjective complaints of the patients, was decreased to less than its half [Kiss and Németh, 2015; 2016].
2. Applying 0.1% nepafenac three times on the day before the cataract surgery and on the morning of the surgery decreased the total prostaglandin level of the anterior chamber of the patients undergoing femtosecond laser-assisted cataract surgery significantly. The total prostaglandin concentration in the FLACS+NSAID group was even lower than that of the Control group [Kiss et al, 2015; 2016].

From the main results of my thesis summarized above the following main conclusions can be drawn:

Changes summarized in points 1.a to 1.d. above were all significantly different. The LIPCOF degree characterizing the severity of conjunctivochalasis was decreased

from the initial 2.9 requiring surgical intervention to 1.8 or 1.6 on the right or left eyes, respectively even after one month of Conheal[®] treatment reaching already the LIPCOF degree range, which can be treated by conservative therapies and does not require surgery. All other measures of dry eye disease recorded also showed significant improvements already after one month of Conheal[®] treatment. The only other known conservative therapy for conjunctivochalasis was published in 4 papers with a liposome containing eye spray, showing more moderate results for evaporative dry eye. In our papers, we were the first to publish a conservative treatment for conjunctivochalasis in keratoconjunctivitis sicca.

Concerning the results of our study with the femtosecond-laser assisted cataract surgery, we were the first to publish that the prostaglandin level elevating effect of the femtosecond laser pretreatment can be prevented by only one day use of topical conservative therapy. Our results were verified four months after our manuscript was submitted for publication.

Results summarized in my thesis indicate that the two types of conservative therapies applied in our studies may prevent the necessity of surgical treatment in patients having advanced forms of keratoconjunctivitis sicca-induced conjunctivohalasis. Furthermore, the prevention of prostaglandin level increase during femtosecond laser-assisted cataract surgeries may diminish the chances of intra- and postoperative complications.

Acknowledgements

First and foremost I would like to thank my supervisors Prof. Dr. **Zoltán Zsolt Nagy** and Prof. Dr. **János Németh**, for the possibility to participate in the work of the Department of Ophthalmology of the Semmelweis University and for all their valuable advice in the past years.

I thank Prof. Dr. **Ildikó Süveges** that as the director of the Program of Ophthalmology of the Doctorial School of Clinical Medicine at the Semmelweis University she suggested me to participate in the part-time training of the program besides my clinical work and supported my studies and preparation of my thesis through all the years.

I thank Prof. Dr. **Shabtay Dikstein** (The Hebrew University, School of Pharmacy, Jerusalem, Israel) for his help and advice and support in the planning, performing and evaluation of the Conheal[®] measurements.

I thank **Pannonpharma Ltd.** the supply of Conheal[®] artificial tears for our studies.

I would like to thank Dr. **Ágnes Takács**, Dr. **Kinga Kránitz**, Dr. **Gábor Sándor** and Dr. **Gábor Tóth** their help in the collection of intracameral liquor samples.

I thank **Beatrix Gilányi** (Department of Medical Chemistry, Semmelweis University) for her advice and help in ELISA measurements.

I thank Dr. **Gábor Somfai**, Dr. **Erika Tátrai** and Dr. **Júlia Singer**, president of the Hungarian Society of Biostatistics, for their help in the statistical evaluation of Conheal[®]-related data.

I thank **Éva Széles** for taking the slit lamp photographs for the representative figure.

I would like to thank **all of my colleagues at the Department of Ophthalmology of the Semmelweis University** for their kind help, advice and the joint work.

I am grateful to **my family** for the continuous support and help in my life.

List of publications

Publications related to the thesis

- **Kiss HJ**, Németh J. (2013) Examination of conservative treatment possibility of conjunctivochalasis – A preliminary report. [A conjunctivochalasis konzervatív kezelési lehetőségének vizsgálata – Előtanulmány. Szemészet.] Ophthalmology (Hung.) 150(4):28-32.
- **Kiss HJ**, Németh J. (2015) Isotonic glycerol and sodium hyaluronate containing artificial tear decreases conjunctivochalasis after one and three months: A self-controlled, unmasked study. PLoS One. 10(7):e0132656. **IF: 3.057**
- **Kiss HJ**, Takács AI, Kránitz K, Sándor GL, Tóth G, Gilányi B, Nagy ZZ. (2015) One-day use of preoperative topical non-steroidal anti-inflammatory drug prevents intraoperative prostaglandin level elevation during femtosecond laser-assisted cataract surgery. Curr Eye Res. 41(8):1064-1067. **IF: 2.025**
- Nagy ZZ, **Kiss HJ**, Takács AI, Kránitz K, Czakó C, Filkorn T, Dunai Á, Sándor GL, Kovács I. (2015) Results of femtosecond laser-assisted cataract surgery using the new 2.16 software and the SoftFit® Patient Interface. [A femtoszekundumlézer-asszisztált szürkehályog-műtét eredményei az új 2.16-os szoftverrel és a módosított SoftFit® páciensi felszínnel. Orv Hetil.] Medical Weekly (Hung.) 156(6):221-5. **IF: 0.291**
- **Kiss HJ**, Takacs AI, Kranitz K, Sandor GL, Toth G, Gilanyi B, Nagy ZZ. (2016) Role of local, non-steroid anti-inflammatory eye drops in the prevention of prostaglandin level increase observed during femtosecond laser-assisted cataract surgery. [A helyi nem-szteroid gyulladáscsökkentő szemcseppek szerepe a femtoszekundum lézer-asszisztált szürkehályogműtétek során tapasztalt prosztoglandinszint-emelkedés kivédésében. Szemészet.] Ophthalmology (Hung.) 153(2):55-60.

Other publications

- Dienes L, **Kiss HJ**, Perényi K, Szepessy Z, Barsi Á, Nagy ZZ, Gallar J, Carmen Acosta M, Kovács I. (2015) The effect of tear supplementation on ocular surface sensations during the interblink interval in patients with dry eye. *PLoS One*. 10(8):e0135629. **IF: 3.057**
- Dienes L, **Kiss HJ**, Perényi K, Nagy ZZ, Acosta MC, Gallar J, Kovács I. (2015) Corneal sensitivity and dry eye symptoms in patients with keratoconus. *PLoS One*. 10(10):e0141621. **IF: 3.057**
- **Kiss HJ**, Takács ÁI, Kránitz K, Filkorn T, Juhász É, Sándor GL, Tóth G, Nagy ZZ. (2015) Femtosecond-assisted cataract surgery of patients having a previous full thickness corneal transplant surgery – A case study. [Femtoszekundum lézer asszisztált szürkehályog-műtét teljes vastagságú szaruhártya-átültetésen átesett betegen – Esetismertetés. *Szemészet*.] *Ophthalmology (Hung.)* 152(2):76-69.
- Barta Á, **Kiss HJ**, Filkorn T, Kránitz K, Nagy ZZ. (2015) Challenges of multifocal intraocular lens implantation after photoreactive keratectomy. [Fotorefraktív keratectomia után végzett multifokális műlencse-beültetés kihívásai. *Szemészet*.] *Ophthalmology (Hung.)* 152(2)80-82.
- Tóth G, Kránitz K, Szigeti A, Sándor GL, Juhász É, **Kiss HJ**, Nagy ZZ. (2015) Comparison of diffractive-refractive multifocal and accommodating intraocular lenses. *South-East European Journal of Ophthalmology*. 1(1):7-10.
- Géhl Z, Kulcsár K, **Kiss HJ**, Németh J, Maneschg OA, Resch MD. (2014) Retinal and choroidal thickness measurements using spectral domain optical coherence tomography in anterior and intermediate uveitis. *BMC Ophthalmol*. 14:103. **IF: 1.020**
- Schneider M, Szekeres O, **Kiss HJ**, Kis M, Papp A, Németh J. (2013) Comparison of thickness values in nine macular subfields using time-domain and spectral-domain optical coherence tomography. [Vastagságértékek sszehasonlítása kilenc makuláris mezőben time-domain és setral-domain optikai koherencia tomográfiával. *Orv Hetil*.] *Medical Weekly (Hung.)* 154(52):2059-64.

- Lukács R, Resch M, Papp A, Szabó A, Borbándy Á, Menkens H, **Kiss HJ**, Németh J. (2013) Long-term treatment with intravitreal ranibizumab for exudative age-related macular degeneration. [Hosszú távú intravitreális ranibizumabkezelés exudatív időskori maculadegenerációban. Orv Hetil.] Medical Weekly (Hung.) 154(45):1790-7.
- Lukács R, **Kiss HJ**, Borbándy Á, Papp A, Resch M, Barta Á, Szabó A, Németh J. (2013) Cataract surgery of patients having a previous treatment of intravitreal injection of ranibizumab against age-related macular degeneration. [Szürkehályog-műtét időskori macula degeneráció miatt intravitreális ranibizumab injekcióval kezelt betegeken. Szemészet.] Ophthalmology (Hung.) 150(1):19-23.
- Csermely P, Korcsmáros T, **Kiss HJ**, London G, Nussinov R. (2013) Structure and dynamics of molecular networks: a novel paradigm of drug discovery: a comprehensive review. Pharmacol Ther. 138(3):333-408. **IF: 7.745**
- Markó K, Mikó-Baráth E, **Kiss HJ**, Török B, Jandó G. (2012) Effects of luminance on dynamic random-dot correlogram evoked visual potentials. Perception. 41(6):648-60. **IF: 1.311**
- Csermely P, Sandhu KS, Hazai E, Hoksza Z, **Kiss HJ**, Miozzo F, Veres DV, Piazza F, Nussinov R. (2012) Disordered proteins and network disorder in network descriptions of protein structure, dynamics and function: hypotheses and a comprehensive review. Curr Protein Pept Sci. 13(1):19-33. **IF: 2.326**
- **Kiss HJ**. (2010) Getting acquainted with the clinical research in Singapore. [Ismerkedés a szingapúri klinikai kutatással. Szemészet.] Ophthalmology (Hung.) 147:104.
- Markó K, **Kiss HJ**, Mikó-Baráth E, Bártfai O, Török B, Kovács I, Jandó G. (2009) Contrast independence of dynamic random dot correlogram evoked VEP amplitude. J. Vis. 9(4):8.1-10. **IF: 3.022**
- **Kiss HJ**, Mihalik Á, Nánási T, Öry B, Spiró Z, Sóti C, Csermely P. (2009) Ageing as a price of cooperation and complexity: self-organization of complex systems causes the gradual deterioration of constituent networks. Bioessays. 31(6):651-64. **IF: 5.125**