

# **OCULAR SIGNS AND OCULAR COMORBIDITIES IN MONOCLONAL GAMMOPATHY**

**Phd. thesis**

**Kitti Kormányos**

Károly Rácz Doctoral School of Clinical Medicine

Semmelweis University



Supervisor: Nóra Szentmáry, M.D., Ph.D.

Official reviewers: Péter Vámosi M.D., Ph.D.  
Ágnes Takács M.D., Ph.D.

Head of the Complex Examination Committee: Zsolt Nagy, M.D., Ph.D.

Members of the Complex Examination Committee: Miklós Resch M.D., Ph.D.

Tibor Milibák, M.D., Ph.D.

Budapest

2022

## Table of contents

Abbreviations .....	3
<b>1. Introduction</b>	<b>4</b>
<b>2. Objectives</b>	<b>8</b>
<b>3. Results</b>	<b>9</b>
3.1 <i>Ocular signs and ocular comorbidities in monoclonal gammopathy</i>	9
3.2 <i>Corneal densitometry and in vivo confocal microscopy in monoclonal gammopathy</i>	16
<b>4. Discussion</b>	<b>27</b>
4.1 <i>Ocular signs and ocular comorbidities in monoclonal gammopathy</i>	27
4.2 <i>Ocular densitometry and in vivo confocal microscopy in monoclonal gammopathy</i>	30
.....	30
<b>5. Hiba! A könyvjelző nem létezik.</b>	<b>4</b>
<b>6. Hiba! A könyvjelző nem létezik.</b>	<b>5</b>
<b>7. Hiba! A könyvjelző nem létezik.</b>	<b>37</b>
<b>8. Hiba! A könyvjelző nem létezik.</b>	<b>48</b>
<b>9. Acknowledgements.....</b>	<b>49</b>

## List of abbreviations

ACG - angle-closure glaucoma

AL - anterior stromal layer

AMD - age-related macular degeneration

BCVA - best corrected visual acuity

CXL - collagen crosslinking

ITK - immunotactoid keratopathy

IVCM - in vivo confocal cornea microscopy

MG - monoclonal gammopathy

MGCS - monoclonal gammopathy of clinical significance

MGOS - monoclonal gammopathy of ocular significance

MGUS - monoclonal gammopathy of undetermined significance

ML - middle stromal layer

MM - multiple myeloma

OAG - open-angle glaucoma

OCT - optical coherence tomography

OSDI - Ocular Surface Disease Index

PKP - penetrating keratoplasty

PL - posterior stromal layer

PPK - paraproteinemic keratopathy

TL – complete corneal stroma

WM - Waldenström macroglobulinemia

## 1. Introduction

The spectrum of monoclonal gammopathies spans clonal plasma cell diseases from monoclonal gammopathy of undetermined significance (MGUS), solitary plasmacytoma, Waldenström macroglobulinemia (WM), and asymptomatic or symptomatic multiple myeloma (MM) to plasma cell leukemia [1-6] (**Table 1**).

**Table 1.** Spectrum of monoclonal gammopathies (adapted from Brigden M et al, Caers et al. and Allbaracin at al.) [4-6]

\*SLiM: S: >60% bone marrow plasma cells

Li: Light chain ratio >100 I/U

M: MRI with > focal lesion

\*CRAB: Calcium > 0,25mmol/L above the upper limit or normal or >2.75mmol/l

Renal insufficiency: creatinine >173mmol/L

Anaemia: Hb 20g/L below the lower limit of normal or Hb <100g/L

Bone lesions: lytic lesions or osteoporosis with compression fractures

	<b>M protein</b>	<b>Clonal plasma cells</b>	<b>SLiM – CRAB</b>	<b>Others</b>
<b>MGUS</b>	M protein in serum (IgG/IgA) <30g/L	bone marrow clonal plasma cells <10%	no SLiM -CRAB	no myeloma related organ or tissue impairment
<b>Smouldering multiple myeloma</b>	M protein in serum (IgG/IgA) ≥30g/L	bone marrow clonal plasma cells >10%	no SLiM - CRAB	no myeloma related organ or tissue impairment
<b>Solitary plasmacytoma</b>	serum M protein not required	bone marrow cytology negative or <10% plasma cell infiltration	no SLiM - CRAB	no end organ damage
<b>Multiple myeloma</b>	M protein in serum (IgG/IgA) ≥30g/L or urine	Any clonal plasma cell population	≥1 SLiM - CRAB	Hypogammaglobulinaemia Occult bone disease Hyperviscosity Cytopenias
<b>Waldenström macroglobulin aemia</b>	Any IgM monoclonal gammopathy	10% lymphoplasmacytic infiltration	SLiM - CRAB not a defining feature	Anaemia, Other cytopenias, Neuropathy, Hyperviscosity, Cryoglobulinaemia, Retinopathy, Fatigue
<b>Amyloid light chain (AL) amyloidosis</b>	any monoclonal gammopathy or abnormal free light chain	any clonal plasma cell or B-cell lymphoma	SLiM - CRAB present or not present	Any fibrill induced end-organ dysfunction: proteinuria, cardiac, liver, nerve, soft tissue

<b>Plasma cell leukemia</b>	plasma cells >2x10 <sup>9</sup> /L in peripheral blood	plasma cells >20% of blood leukocytes in peripheral blood, primary plasma cell leukemia (pPCL): presents as de novo leukemia	plasma cells >20% of blood leukocytes in peripheral blood, primary plasma cell leukemia (pPCL): presents as de novo leukemia
-----------------------------	--	--	--

MGUS is considered a premalignant state that has three different types with IgM MGUS, non-IgM MGUS (IgA- and IgG-MGUS), and light chain MGUS. All forms of MGUS can cause amyloidosis, a special sort of light chain deposition disease, or non-Hodgkin lymphoma, which are important differential diagnostic entities [7].

Diagnostic criteria for MGUS according to the 2015 recommendation of the International Myeloma Working Group are: bone marrow plasma cell content less than 10%, less than 3g/dL of monoclonal protein level (M-protein) in the serum, and no indication of organ disruption, that is characteristic for malignant B-cell disease (no hypercalcemia, renal failure, anemia, or bone changes) [8-10]. However, with IgG type M-protein of less than 1.5 g/dL, bone marrow biopsy is often deferred if the patient is asymptomatic. The prevalence of MGUS increases with age from 1.7% in individuals with 50–59 years of age to 6.6% in individuals with >80 years of age (Kyle et al. 2006) [11].

In case of monoclonal gammopathy (MG), monoclonal proteins may be deposited in various organs [12-20], resulting in monoclonal gammopathy of clinical significance (MGCS) [21-22].

Monoclonal protein deposition is most commonly described as kidney involvement [12] or unexplained polyneuropathy [13-16]. There may also be an insulin autoimmune syndrome [17], infiltrative or restrictive cardiomyopathy [18], gastrointestinal system involvement [19], infiltrative or „paraneoplastic” like skin disease [20].

If paraprotein deposition occurs exclusively in the eye, the term ”monoclonal gammopathy of ocular significance” (MGOS) is used [23]. As ocular signs of gammopathy, corneal deposits, conjunctival deposits, acute/chronic uveitis [24, 25], maculopathy, foveolar drusen [26-28], Doyme retinal dystrophy [29], central retinal artery or vein occlusion [30], myositis, and proptosis [31] have been described.

Corneal deposits associated with monoclonal gammopathy were first described in 1934 by Meesman [32]. These were later described as chameleon-like changes and have been

named paraproteinemic keratopathy (PPK) [33-35]. These are mostly bilateral, grey-white, yellowish, grey-brown, polychromatic, or crystal-like changes in any layer of the cornea. These may be either diffuse or focal, central or peripheral deposits [8].

In 2012, Lisch et al. created a nomenclature distinguishing five different types of immunotactoid keratopathy (ITK): crystalline-like ITK, lattice-like ITK, peripheral granular-like ITK, peripheral band-like ITK, and peripheral patch-like ITK [34]. In 2016, they expanded their classification to 11 MGUS-induced paraproteinemic keratopathy forms [35].

Corneal properties may be objectively analyzed using a slit lamp, corneal topography or tomography, optical coherence tomography (OCT), ultrasound biomicroscopy and *in vivo* confocal microscopy.

Scheimpflug-based densitometry of the anterior segment is becoming increasingly important in corneal diagnostics, and it is widely used in everyday clinical practice. The most important properties of the healthy cornea are clarity and transparency. Scheimpflug imaging analysis can be used to measure light transmission and backscatter [36-37]. Studies have shown that even in cases of clinically clear corneas, there may be a greater degree of corneal backscatter [38]. The Oculus Pentacam (Oculus Inc., Oculus GmbH, Wetzlar, Germany), as corneal tomographer, employs the Scheimpflug principle to obtain images of the anterior segment. The rotating camera captures 25 anterior segment images in 2 seconds, thus providing a quantifiable measurement of corneal clarity. In addition to the use of Pentacam in routine clinical diagnostics as a tomographer, using Pentacam, corneal light scattering has been extensively studied in a number of ocular diseases. There is an increased corneal light scattering in keratoconus [39], vernal keratoconjunctivitis [41], corneal dystrophies [41], cornea guttata [42], infectious corneal infiltrates [43], following penetrating and lamellar keratoplasty [44], following refractive corneal procedures [45] and after collagen crosslinking (CXL) [46]. Nevertheless, corneal light scattering is decreased in highly myopic corneas and in diabetic patients [47,48]. In 2017, a retrospective study by Enders et al. summarized the capability of Scheimpflug-based densitometry of the cornea, to quantify light chain deposits in five patients with monoclonal gammopathy [49]. In 2017, Busch et al. analyzed 20 eyes [50] and later, in 2019 Ichii et al. examined 30 subjects with monoclonal gammopathy, also using Pentacam [51].

*In vivo* confocal microscopy (IVCM) represents another objective examination method to evaluate corneal morphology and to assess layer reflectivity and cellular density. Corneal deposits, occurring in monoclonal gammopathy, were first described in single case reports using IVCM [33,52-61]. Thereafter, in a cross-sectional study, Aragona et al. examined 31 patients with MGUS, smouldering myeloma and MM, using IVCM [62]. All these studies described hexagonal or round deposits with a crystalline appearance in the corneal stroma.

Nevertheless, no previous study analyzed and compared corneal stromal properties using Pentacam and IVCM at the same time, in monoclonal gammopathy. Although Enders et al. analyzed 5 [49], Busch et al. 20 [50], Ichii et al 30 subjects with monoclonal gammopathy using Pentacam [51] and Aragona et al. analyzed 31 patients with IVCM [62], none of these studies analyzed a larger cohort of subjects, in a cross-sectional manner.

## **2. Objectives**

The objective of our research was to analyze the ocular manifestations of monoclonal gammopathy. In order to achieve this objective, the aims of the present study were:

1. To determine the ocular signs of monoclonal gammopathy and the ocular comorbidities in subjects with monoclonal gammopathy [63-64].
2. To analyze and compare corneal stromal light scattering using Pentacam and corneal properties using IVCN in subjects with monoclonal gammopathy and in controls [65].



### 3. Results

#### 3.1 *Ocular signs and ocular comorbidities in monoclonal gammopathy*

In our prospective, cross-sectional study, we analyzed patients of the Department of Hematology and Stem Cell-Transplantation of the South-Pest Center Hospital – National Institute for Hematology and Infectious Disease, Budapest, Hungary and the 3<sup>rd</sup> Department of Internal Medicine and Hematology, Semmelweis University, Budapest, Hungary, diagnosed and treated with monoclonal gammopathy between 1997-2020. As a control group, randomly selected individuals of the same age group, without hematological disease have been included. The local Ethics Committee gave permission to our study (OGYÉI/50115/2018). Participation has been voluntary, written informed consent was obtained from all participants.

We analyzed altogether 246 eyes of 123 patients (age  $66.2 \pm 11.11$  years). There were 160 eyes of 80 patients (38.75% males; age  $67.61 \pm 10.48$  (range 38-85) years) with monoclonal gammopathy. Eighty-six eyes of 43 subjects (32.56% males; age  $62.44 \pm 11.89$  (range 37-86) years) have been analyzed as controls. The age of the patients in the gammopathy and control groups did not differ significantly ( $p=0.17$ ) (**Table 2**).

**Table 2.** Age (mean $\pm$ SD (minimum-maximum)), gender (n (%)), ocular surface disease index (OSDI) score (mean $\pm$ SD (minimum-maximum)), best corrected visual acuity (BCVA) (mean $\pm$ SD (minimum-maximum)) in control subjects and in patients with monoclonal gammopathy (MG).

P values refer to results of the Mann-Whitney U test (age, OSDI and BCVA) and the  $\chi^2$  test with Yates correction (males)(comparison between both groups), significant values are bold.

	<i>Age</i> (years)	<i>Males</i> (n (%))	<i>OSDI</i>	<i>BCVA</i>
<b>Control</b>	62.44 $\pm$ 11.89 (37-86)	14 (32.56%)	12.66 $\pm$ 11.00 (0-50)	0.94 $\pm$ 0.16 (0.06-1)
<b>MG</b>	67.61 $\pm$ 10.48 (38-85)	31 (38.75%)	21.51 $\pm$ 18.03 (0-65.9)	0.82 $\pm$ 0.26 (0.01-1)
P value	0.17	0.67	<b>0.02</b>	<b>0.0005</b>

In patients with established hematological diagnosis, the time of the hematological diagnosis was in one case (1.25%) within 1 year, in 36 (45.00%) cases within 5 years, in

29 (36,25%) cases within 5-10 years and in 14 (17.50%) cases more than 10 years ago. The hematological diagnosis was MGUS in 9 (11.25%), multiple myeloma in 61 (76.25%), smoldering myeloma in 6 (7.50%), and amyloidosis or Waldenström macroglobulinemia in 2-2 cases (2.50%-2.50%).

With respect to immunoglobulin heavy chains, there was an increased IgG level in 52 individuals (65.00%), an increased IgA level in 20 (25.00%), an increased IgM level in 4 (5.00%), and an increased IgD level in 1 case (1.25%). Considering light chains, in 49 subjects (61.25%) kappa chain, and in 31 patients (38.75%) lambda chain has been verified and in 3 cases (3.75%) heavy chain production was not detectable.

With respect to organ dysfunction in gammopathy patients, osteolytic lesions have been previously described in 39 subjects (48.75%), renal involvement in 19 patients (23.75%), polyneuropathy in 6 (7.50%), spinal cord involvement in 3 cases (3.75%), liver involvement and thrombosis of the upper limb in 2-2 cases (2.5%-2.5%), respectively. In single cases, (1.25%-1.25%) infiltration of the nervus medianus and skin lesions were identified. There was no renal involvement in 4 (5.00%) and no other organ involvement in 8 (10.00%) subjects in the hematological disease history. Thirty-six subjects (45.00%) had previous autologous stem cell transplantation and 65 subjects (81.25%) received chemotherapy, according to their hematological disease history.

In the gammopathy group, there was hypertension in 59 (73.75%), type 2 diabetes mellitus in 15 (18.75%), cardiac arrhythmia in 10 (12.50%), gastro-oesophageal reflux in 9 (11.25%), previous myocardial infarction in 4 (5.00%), deep vein thrombosis in 4 (5.00%), stroke in 3 (3.75%), benign prostate hyperplasia in 3 (3.75%), prostate cancer in 3 (3.75%), cervix cancer in 3 (3.75%), hyperthyroidism in 3 (3.75%), asthma bronchiale in 2 (2.50%), breast cancer in 2 (2.50%), Raynaud's syndrome in 2 (2.50%), rheumatoid arthritis in 2 (2.50%), hypothyroidism in 2 (2.50%), endometriosis in 1 (1.25%), pulmonary embolism in 1 (1.25%), systemic lupus erythematosus in 1 (1.25%), colon cancer in 1 (1.25%), endometrial cancer in 1 (1.25%), squamous cell skin cancer in 1 (1.25%) subjects.

In the control group, there was hypertension in 16 (37.21%), type 2 diabetes in 6 (13.95%), atrial fibrillation in 2 (4.65%), gastro-oesophageal reflux in 1 (2.32%), prostate cancer in 1 (2.32%) and colon cancer in 1 (2.32%) subject in the history, respectively.

Before the ophthalmic examination, 42 subjects with gammopathy (52.50%) and all control subjects filled the Ocular Surface Disease Index (OSDI) questionnaire (Score ranges were designated as normal (0-12), mild (13-22), moderate (23-32), or severe (33-100) ocular surface disease) and for all patients, ophthalmic medical history has been taken. Ophthalmic examination included refractometry, visual acuity test (best corrected visual acuity), Goldmann applanation tonometry, and slit-lamp examination following dilation of the pupil. In case of retinal disease, optical coherence tomography (AngioVue OCTA, RTVue XR Avanti, OptoVue, Fremont CA, USA) has also been performed. For statistical analysis of the data, the Mann-Whitney U test and the  $\chi^2$  test have been used.

In the ophthalmic history of subjects with *monoclonal gammopathy* (**Table 3**), there was no history of ocular disease in 66 (41.25%), there was dry eye disease in 64 (40.00%), cataract in 27 (16.88%), previous cataract surgery in 20 (12.50%), glaucoma in 12 (7.50%), posterior cortical cataract in 4 (2.50%) and previous penetrating keratoplasty in 2 eyes (1.25%). In the subgroup of the 8 subjects with MGUS (16 eyes, without previous systemic corticosteroid treatment), there was cataract in 14 (77.77%) and posterior cortical cataract in 4 (22.23%) eyes. None of them had previous cataract surgery.

In the ophthalmic history of *controls*, there was no history of ocular disease in 22 (25.58%), there was dry eye disease in 17 (19.77%), previous cataract surgery in 12 (13.95%), cataract in 12 (13.95%), glaucoma in 4 (4.65%) and posterior cortical cataract in 1 (1.16%) eyes.

In ophthalmic history, the proportion of subjects with dry eye disease was significantly higher in monoclonal gammopathy subjects as in controls ( $p=0.002$ ).

**Table 3.** Ophthalmic diagnosis in *ophthalmic history* of control subjects and in patients with monoclonal gammopathy (MG). P values refer to results of the  $\chi^2$  test with Yates correction (comparison between both groups), significant values are bold. With „0” value,  $\chi^2$  test could not be calculated.

<b>Ophthalmic diagnoses</b>	<b>Control (n=86)</b>	<b>MG (n= 160)</b>	<b>P values</b>
<i>Dry eye disease</i>	17 (19.77%)	64 (40.00%)	<b>0.002</b>
<i>Penetrating keratoplasty</i>	0	2 (1.25%)	-
<i>Glaucoma</i>	4 (4.65%)	12 (7.50%)	0.55
<i>Previous cataract surgery</i>	12 (13.95%)	20 (12.50%)	0.90
<i>Cataract</i>	12 (13.95%)	27 (16.88%)	0.54
<i>Posterior cortical cataract</i>	1 (1.16%)	4 (2.50%)	0.47
Without previous ophthalmic diagnosis	22 (25.58%)	66 (41.25%)	<b>0.01</b>
<b>Total</b>	<b>86 (100%)</b>	<b>160 (100%)</b>	-

Using the OSDI questionnaire, among patients with *hematological diagnosis*, there were 14 (33.33%) subjects with normal ocular surface, 11 (26.19%) had mild, 6 (14.29%) moderate, and 11 (26.19%) severe ocular surface disease. Among the *control subjects*, there were 27 subjects (62.79%) with normal ocular surface, 7 subjects (16.28%) with mild, 7 (16.28%) with moderate and 2 (4.65%) with severe ocular surface disease. OSDI score was significantly worse in subjects with monoclonal gammopathy than in controls (p=0.02).

In patients with haematological diagnosis, best-corrected visual acuity (BCVA) was  $0.82 \pm 0.26$  (logMAR  $0.1 \pm 0.26$ ), in controls  $0.94 \pm 0.16$  (logMAR  $0.1 \pm 0.16$ ). BCVA was significantly worse in subjects with gammopathy as in controls at the examination time-point (p=0.0005).

Among patients with *gammopathy*, we found 89 (55.63%) eyes of 53 patients with 1.0 (0.0 logMAR), 66 eyes (41.25%) of 42 patients between 0.2-0.9 (0.1-0.7 logMAR) BCVA. Five (3.13%) eyes of 5 patients were not able to read the chart. Between *controls*, the majority of the subjects, 68 (79.07%) eyes had BCVA 1.0 (0.0logMAR), 12 (13.95%) eyes of 10 patient had 0.8-0.9 (0.1 logMAR), 5 (5.81%) eyes of 5 patient had BCVA between 0.2-0.7 (0.2-0.5 logMAR) and 1 (1.16%) eye of 1 patient was not able to read the chart.

Among ophthalmological findings of *gammopathy subjects* (**Table 4.**), there was ocular surface disease in 56 (66.67%), cataract in 86 (53.75%), Meibomian gland dysfunction in 30 (18.75%), no ophthalmic disease in 22 (13.75%), posterior cortical cataract in 21 (13.13%), previous cataract surgery in 20 (12.50%), macular or retinal drusen in 18 (11.25%), chronic blepharitis in 16 (10.00%), glaucoma in 12 (7.50%), age-related macular degeneration in 12 (7.50%), epiretinal membrane in 10 (6.25%), Fuchs dystrophy in 8 (5.00%), peripheral retinal degeneration in 7 (4.38%), corneal immunoglobulin deposition in 6 (3.75%), diabetic retinopathy in 4 (2.50%), amblyopia in 3 (1.88%), macular hole in 1 (0.63%), central retinal artery occlusion in 1 (0.63%), branch retinal vein occlusion in 1 (0.63%), choroideal naevus in 1 (0.63%) and retinal scar in 1 (0.63%) eye.

Among gammopathy subjects, we observed potential corneal immunoglobulin deposition in 6 eyes of 4 (7.50%) patients (**Figure 1**).

One of these patients underwent penetrating keratoplasty (PKP) prior to enrollment (**Figure 1F**). These corneal deposits have been observed in both eyes in 2 patients (**Figures 1A-D**) and in 1 eye in 2 patients (**Figures 1E-F**). The diagnosis was monoclonal gammopathy with ocular significance (MGOS) in 1 (**Figures 1A-B**) and multiple myeloma in 3 (**Figures 1C-F**) of these subjects.

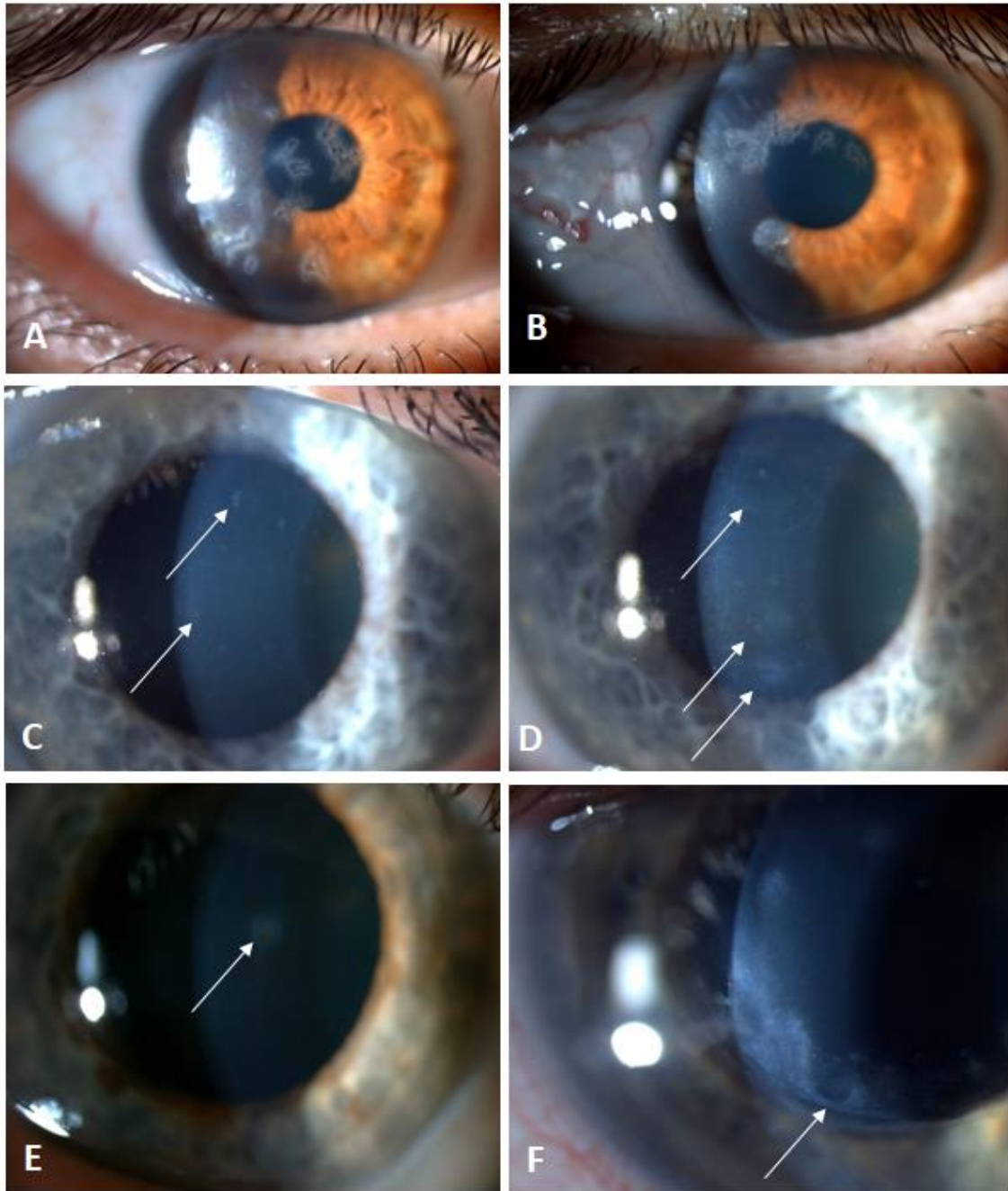
In gammopathy subjects, in the group of corneal scars and degenerations, there was arcus senilis in 8 (5.00%), crocodile shagreen in 6 (3.75%), iron line and corneal scar due to previous corneal foreign body removal in 5 (3.13%), Salzmann nodular degeneration in 1 (0.63%) and stromal scar and calcification due to previous stromal herpes keratitis in 1 (0.63%) eye.

Between ophthalmological findings of *control subjects* (**Table 4.**), there was ocular surface disease in 32 (37.21%), cataract in 17 (19.77%), macular or retinal drusen in 16 (18.60%), chronic blepharitis in 16 (18.60%), no ophthalmic disease in 14 (16.28%), previous cataract surgery in 12 (13.95%), Meibomian gland dysfunction in 10 (11.63%), glaucoma in 4 (4.65%), diabetic retinopathy in 4 (4.65%), peripheral retinal degeneration in 4 (4.65%), posterior cortical cataract in 3 (3.49%), Fuchs dystrophy in 2 (2.33%), epiretinal membrane in 2 (2.33%) and amblyopia in 1 (1.16%) eye.

**Table 4.** *Ophthalmological findings* in control subjects (86 eyes) and in patients with monoclonal gammopathy (MG) (160 eyes, except for ocular surface disease, as OSDI questionnaire has only been filled through 42 subjects). P values refer to results of the  $\chi^2$  test with Yates correction (comparison between both groups), significant values are bold. With „0” value,  $\chi^2$  test could not be calculated.

OSDI: Ocular surface disease index

<b>Ophthalmic diagnoses</b>	<b>Control (n=86)</b>	<b>MG (n=160)</b>	<b>P values</b>
<i>Ocular surface disease (OSDI)</i>	32 (37.21%) (n=86)	56 (66.67%) (n=84)	<b>0.0001</b>
<i>Meibomian gland dysfunction</i>	10 (11.63%)	30 (18.75%)	0.20
<i>Chronic blepharitis</i>	16 (18.60%)	16 (10.00%)	0.08
<i>Corneal scars and degenerations</i>	5 (5.81%)	21 (13.13%)	0.07
<i>Corneal immunoglobulin deposition</i>	0	6 (3.75%)	-
<i>Fuchs dystrophy</i>	2 (2.33%)	8 (5.00%)	0.50
<i>Glaucoma</i>	4 (4.65%)	12 (7.50%)	0.55
<i>Previous cataract surgery</i>	12 (13.95%)	20 (12.50%)	0.90
<i>Cataract</i>	17 (19.76%)	86 (53.75%)	<b>0.0001</b>
<i>Posterior cortical cataract</i>	3 (3.49%)	21 (13.13%)	<b>0.01</b>
<i>Epiretinal membrane</i>	2 (2.33%)	10 (6.25%)	0.29
<i>Age-related macular degeneration</i>	0	12 (7.50%)	-
<i>Macular or retinal drusen</i>	16 (18.60%)	18 (11.25%)	0.16
<i>Macular hole</i>	0	1 (0.63%)	-
<i>Diabetic retinopathy</i>	4 (4.65%)	4 (2.50%)	0.59
<i>Peripheral retinal degeneration</i>	4 (4.65%)	7 (4.38%)	0.82
<i>Central retinal artery occlusion</i>	0	1 (0.63%)	-
<i>Branch retinal vein occlusion</i>	0	1 (0.63%)	-
<i>Choroidal naevus</i>	0	1 (0.63%)	-
<i>Retinal scar after chorioretinitis</i>	0	1 (0.63%)	-
<i>Amyopia</i>	1 (1.16%)	3 (1.88%)	0.93
Without ophthalmic disease	14 (16.28%)	22 (13.75%)	0.72
<b>Total</b>	<b>86 (100%)</b>	<b>160 (100%)</b>	-



**Figure 1. Corneal opacities in six eyes of four patients with monoclonal gammopathy.**

Sharp-edged, branching predescemetal opacities in both eyes of one patient with monoclonal gammopathy of ocular significance (MGOS) (A, B), sharp-edged, round or punctate, fine subepithelial opacities in both eyes of one subject with cornea guttata and multiple myeloma (C, D), round stromal opacity in one eye of one subject with multiple myeloma (E), sand-like stromal deposits along the removed penetrating keratoplasty (PKP) running-suture line in one eye of one subject with multiple myeloma (F).

In control subjects, in the group of corneal scars and degenerations, there was arcus senilis in 2 (2.33%), crocodile shagreen in 2 (2.33%), and iron line and corneal scar due to previous corneal foreign body removal in 1 (1.16%) eye. The proportion of subjects with corneal scars and degenerations in the gammopathy group did not differ from controls ( $p=0.07$ ).

### ***3.2 Corneal densitometry and in vivo confocal microscopy in monoclonal gammopathy***

In our cross-sectional study, patients of the Department of Hematology and Stem Cell-Transplantation of the South-Pest Center Hospital – National Institute for Hematology and Infectious Disease, Budapest, Hungary and the 3<sup>rd</sup> Department of Internal Medicine and Haematology, Semmelweis University, Budapest, Hungary, diagnosed and treated with monoclonal gammopathy between 1999-2021 have been included. As a control group, randomly selected individuals of the same age group, without haematological disease have been included. The local Ethics Committee gave permission to our study (OGYÉI/50115/2018). Participation has been voluntary, written informed consent was obtained from all participants.

In our study, we analyzed altogether 230 eyes of 115 patients (40% males; age  $64.96 \pm 12.28$  (33-86) years). There were 130 eyes of 65 patients (40.0% males; age  $67.71 \pm 9.40$  (range 38-83) years) with monoclonal gammopathy (MG) and 100 eyes of 50 subjects (40.0% males; age  $60.67 \pm 15.06$  (range 33-86) years), as controls. The age of the patients with MG and controls did not differ significantly ( $p=0.267$ ).

In patients with established hematological diagnosis, the time of the hematological diagnosis was in one case (1.54%) within 1 year, in 28 (43.08%) cases within 5 years, in 32 (49.23%) cases within 5-10 years and in 4 (6.15%) cases more than 10 years ago. The hematological diagnosis was MGUS in 6 (9.23%), multiple myeloma in 50 (76.92%), smoldering myeloma, amyloidosis or Waldenström macroglobulinemia in 3-3-3 cases (4.61%-4.61%-4.61%).

With respect to immunoglobulin heavy chains, there was an increased IgG level in 39 individuals (60%), an increased IgA level in 15 (23.08%), an increased IgM level in 6 (9.23%), and an increased IgD level in 1 (1.54%) case. In 1 (1.54%) case we found



biclonal elevation of IgG and IgM heavy chains. Considering light chains, in 40 (61.54%) subjects kappa chain, and in 25 (38.46%) patients lambda chain was verified and in 2 cases (3.08%) heavy chain production was not detectable.

Before ophthalmic examination of MG subjects and controls, ophthalmic medical history has been taken. Thereafter, ophthalmic examination included visual acuity test using trial glasses in a trial frame (best corrected visual acuity), slit-lamp examination following dilation of the pupil, Scheimpflug imaging (Pentacam HR; Oculus GmbH, Wetzlar, Germany) and *in vivo* confocal laser scanning cornea microscopy using Heidelberg Retina Tomograph with Rostock Cornea Module (HRTII/RCM) (Heidelberg Engineering, Heidelberg, Germany).

Using Pentacam, keratometric values, corneal astigmatism and corneal apex pachymetry were measured automatically by the software and these data were collected. In addition, corneal backscattered light values in grey scale unit (light scattering) were recorded from 0 (100% transparent) to 100 (completely opaque, 0% transparent) [49]. For analysis of the data, we used the corneal densitometry average table according to Enders et al. [49]. Values were obtained in 4 annular zones of the cornea, which were centered to the apex of the cornea: (1) central annular 0-2 mm zone; (2) intermediate 2-6 mm zone; (3) peripheral 6-10 mm zone; (4) limbal 10-12 mm zone. Additionally, these annular zones were divided into the following 3 corneal stromal layers according to their depth: (A) anterior 120  $\mu\text{m}$  deep corneal stromal layer (AL), (B) middle corneal stromal layer more than 120  $\mu\text{m}$  from the anterior and less than 60  $\mu\text{m}$  from the posterior corneal stromal surface (ML) and (C) posterior corneal stromal layer (PL), less than 60  $\mu\text{m}$  from the posterior corneal stromal surface. The total corneal stromal volume (between the epithelium and endothelium) has also been analyzed (TL).

Before scanning with the *in vivo* confocal laser scanning cornea microscope, one drop of 0.4% oxybuprocaine hydrochlorid (Novesine, OmniVision GmbH, Puchheim, Germany) was instilled in the conjunctival sac, as anesthetics. As a coupling medium to ensure the airless contact between the plastic cap, covering the immersion lens of the microscope (a sterile poly-methyl-methacrylate cap (TomoCap; Heidelberg Engineering, Heidelberg, Germany), and the ocular surface, one drop of artificial tear gel (0.2% carbomer, Vidisic, Dr Mann Pharma, Berlin, Germany, Bausch&Lomb) was instilled.

Two dimensional images were captured in every corneal layer from the epithelium to the endothelium by the instrument's section mode. These images represent an "en face" section of the cornea with a resolution of 384 x 384 pixels covering a 400  $\mu\text{m}$  x 400  $\mu\text{m}$  area. The depth of the examination field in the cornea was ensured by the inbuilt digital micrometer gauge. A diode laser beam with a wavelength of 670 nm was used by the HRTII/RCM to scan the focal plane of the examined specimen. The same examiner (KK) recorded and analyzed the captured micrographs. Two well focused images were randomly selected in each corneal layer for detailed analysis. For description of the data, we used the classification of Aragona et al. [62], with some modifications. We extended the analysis of Aragona et al. with description of corneal stromal properties in the anterior (anterior 120  $\mu\text{m}$  deep corneal stromal layer), middle (middle corneal stromal layer more than 120  $\mu\text{m}$  from the anterior and less than 60  $\mu\text{m}$  from the posterior corneal stromal surface) and posterior corneal stromal layers (less than 60  $\mu\text{m}$  from the posterior corneal stromal surface) (**Table 5**).

Inorder to analyze hyperreflectivity of the corneal epithelial cells per micrograph, we used the following arbitrary scoring system (**Table 5, Figure 2**): "1"=no hyperreflective epithelial cells (no alteration), "2" $\leq$ 4 hyperreflective epithelial cells (mild alteration), "3" $>$ 4 hyperreflective epithelial cells (moderate alteration), "4"=no images for evaluation.

Describing keratocytes, we used the following arbitrary scoring system (**Table 5, Figure 2**): "0"=no changes, "1" $\leq$ 4 hyperreflective keratocytes per micrograph, "2"=5-7 hyperreflective keratocytes per micrograph, "3"=8-16 hyperreflective keratocytes per micrograph, "4" $>$ 16 hyperreflective keratocytes per micrograph, "5" no images for evaluation in the questioned layer.

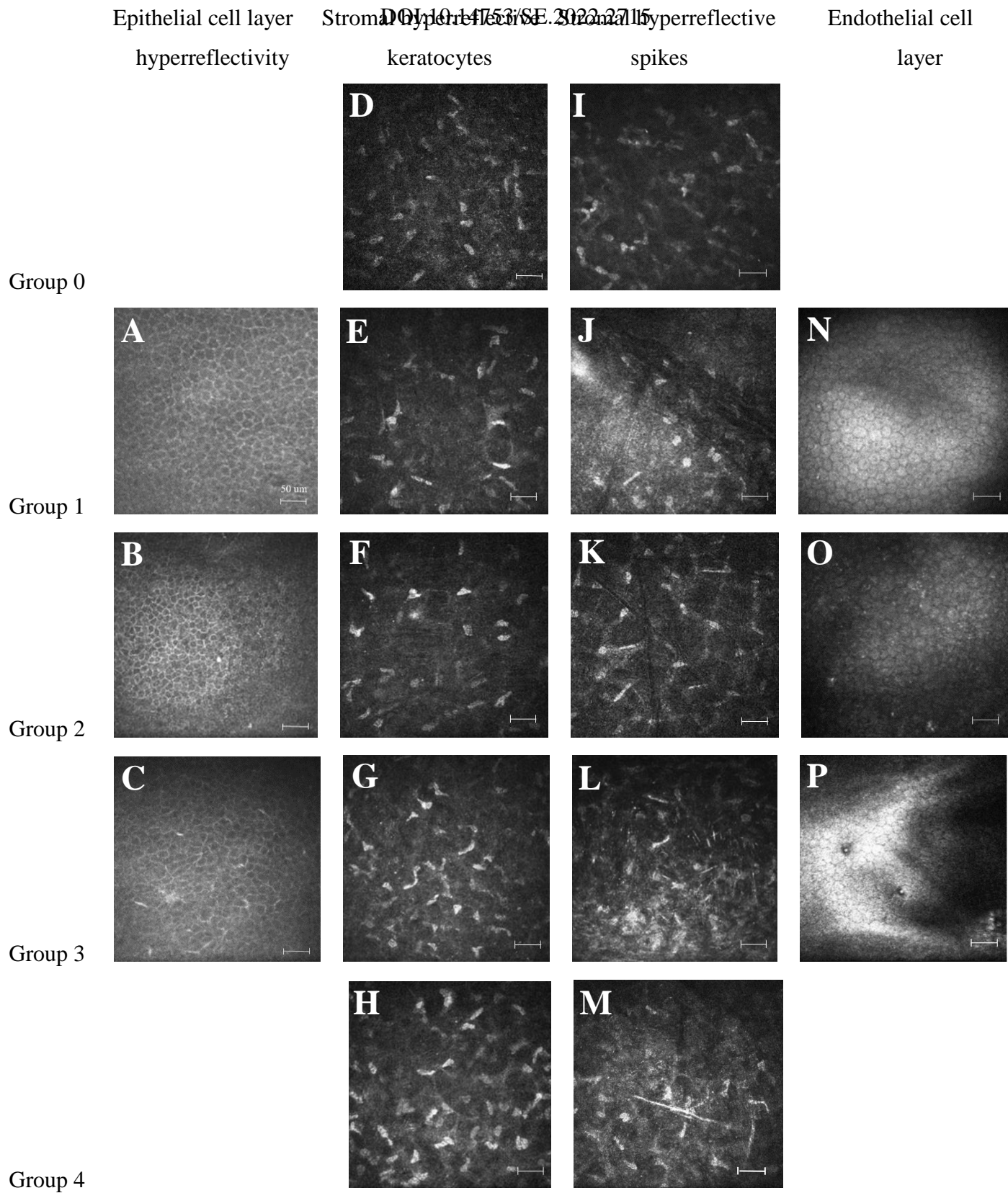
Analysis of stromal hyperreflective spikes was carried out according to the following arbitrary system (**Table 5 and Figure 2**): "0"=no changes, hyporefective matrix, "1"=hyperreflective areas, maximal 1 spike per micrograph, "2"=2-3 spikes per micrograph,"3" $\geq$ 4 spikes per micrograph, "4"= giant spike/s ( $>$  75  $\mu\text{m}$ ), "5"= no images for evaluation.

Descriprion of the endothelial cell layer included the following information (**Table 5, Figure 2**): "1"= no changes, "2"= hyperreflective changes; "3"=guttae, "4"=no images for evaluation.

For statistical analysis of the data, the Mann-Whitney U test and the  $\chi^2$  test were used, with p values below 0.05 considered statistically significant.

**Table 5.** Classification of epithelial cell layer properties, stromal hyperreflective keratocytes, stromal hyperreflective spikes and endothelial cell layer properties. We used a classification modified from Aragona et al. [62].

	<b>Epithelial cell layer hyperreflectivity/ micrograph</b>	<b>Number of stromal hyperreflective keratocytes/ micrograph</b>	<b>Number of stromal hyperreflective spikes/ micrograph</b>	<b>Endothelial cell layer</b>
<b>0</b>	-	no changes	no changes	-
<b>1</b>	no changes	$\leq 4$	$\leq 1$	no changes
<b>2</b>	$\leq 4$	5-7	2-3	hyperreflective changes
<b>3</b>	$> 4$	8-16	$\geq 4$	guttatae
<b>4</b>	no images for evaluation	$> 16$	giant spike/s ( $> 75 \mu\text{m}$ )	no images for evaluation
<b>5</b>	-	no images for evaluation	no images for evaluation	-



**Figure 2.** Classification of epithelial cell layer properties (A-C), stromal hyperreflective keratocytes (D-H), stromal hyperreflective spikes (I-M) and endothelial cell layer properties (N-P) using *in vivo* confocal laser scanning cornea microscopy (IVCM) imaging with Heidelberg Retina Tomograph, with Rostock Cornea Module (HRTII/RCM) (Heidelberg Engineering, Heidelberg, Germany), as described at **Table 5**. We used a classification modified from Aragona et al [62]. Scale bars: 50  $\mu$ m.

**Table 6.** Keratometric values and corneal astigmatism in Diopters (D), axis of astigmatism and apex pachymetry in subjects with monoclonal gammopathy (MG) and in controls, using Pentacam (Oculus, Wetzlar, Germany). P values show results of the statistical analysis using Mann-Whitney U test.

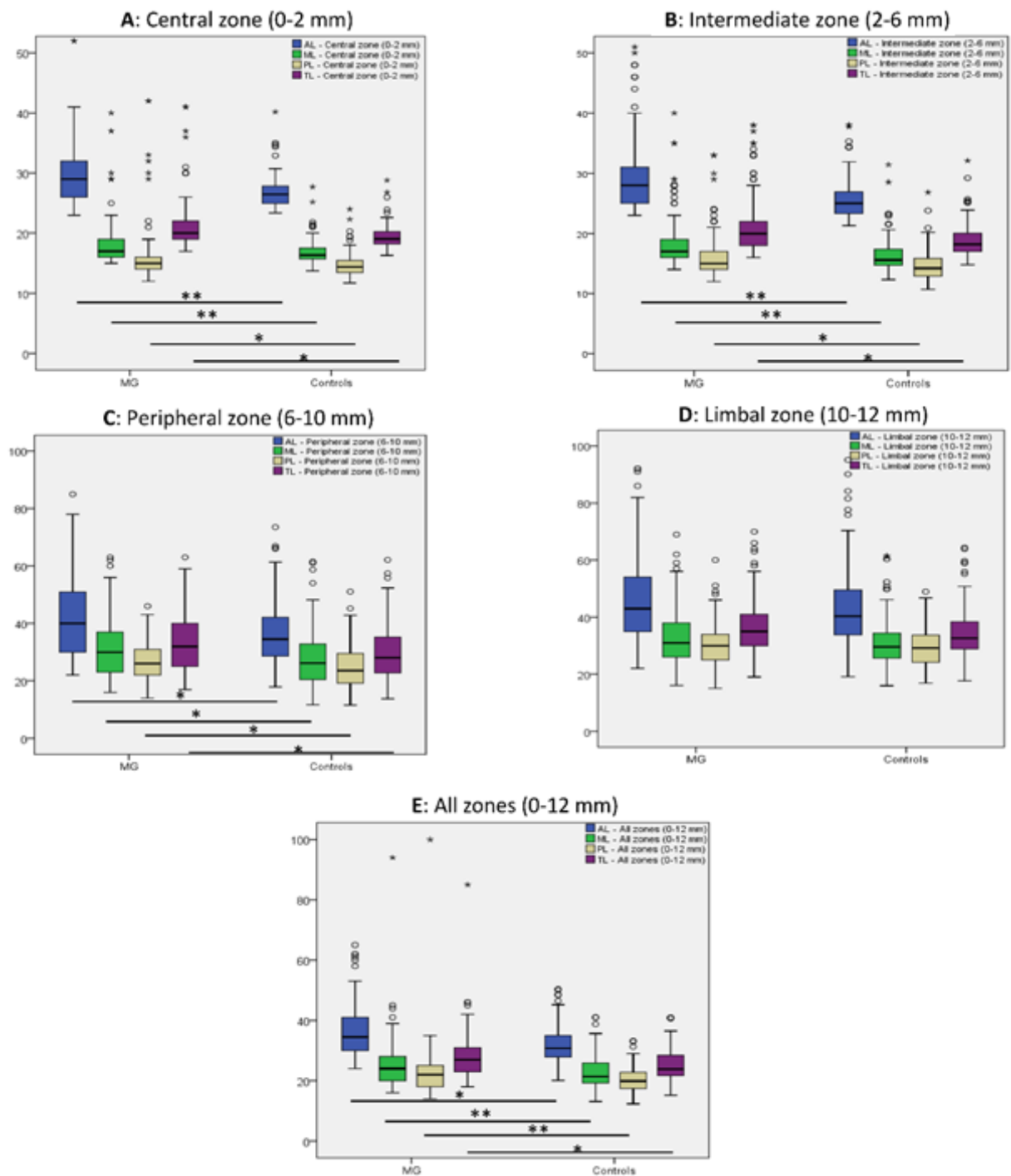
	<i><b>K1</b></i> <i><b>(D)</b></i>	<i><b>K2</b></i> <i><b>(D)</b></i>	<i><b>Corneal</b></i> <i><b>astigmatism (D)</b></i>	<i><b>Axis of corneal</b></i> <i><b>astigmatism (degree)</b></i>	<i><b>Apex pachymetry</b></i> <i><b>(<math>\mu</math>m)</b></i>
<b>MG</b>	43.25 $\pm$ 1.63 (35.70-47.50)	44.24 $\pm$ 1.71 (40.50-52.50)	0.99 $\pm$ 1.06 (0.00-9.70)	0.51 $\pm$ 0.23 (-0.66-0.98)	569.71 $\pm$ 144.04 (465-2662)
<b>Controls</b>	43.22 $\pm$ 1.64 (40.20-47.50)	44.07 $\pm$ 1.70 (41.00-48.00)	0.84 $\pm$ 0.59 (0.10-3.50)	0.49 $\pm$ .23 (-0.56-0.98)	560.51 $\pm$ 36.21 (465-634)
<b>p value</b>	0.255	0.098	0.127	0.137	0.724

BCVA did not differ significantly between subjects with monoclonal gammopathy ( $0.83 \pm 0.25$  (0.01-1.0) (logMAR  $0.1 \pm 0.24$ )) and controls ( $0.92 \pm 0.21$  (0.06-1.0) (logMAR  $0.1 \pm 0.21$ )) at the examination time-point ( $p=0.912$ ). Keratometric values, corneal astigmatism and corneal apex pachymetry also did not show significant difference between both groups (**Table 6**) ( $p \leq 0.724$ ).

Using slitlamp examination, there were corneal opacities (corresponding to paraproteinaemic keratopathy) in 12 (9.23%) eyes of 8 (12.31%) subjects with monoclonal gammopathy.

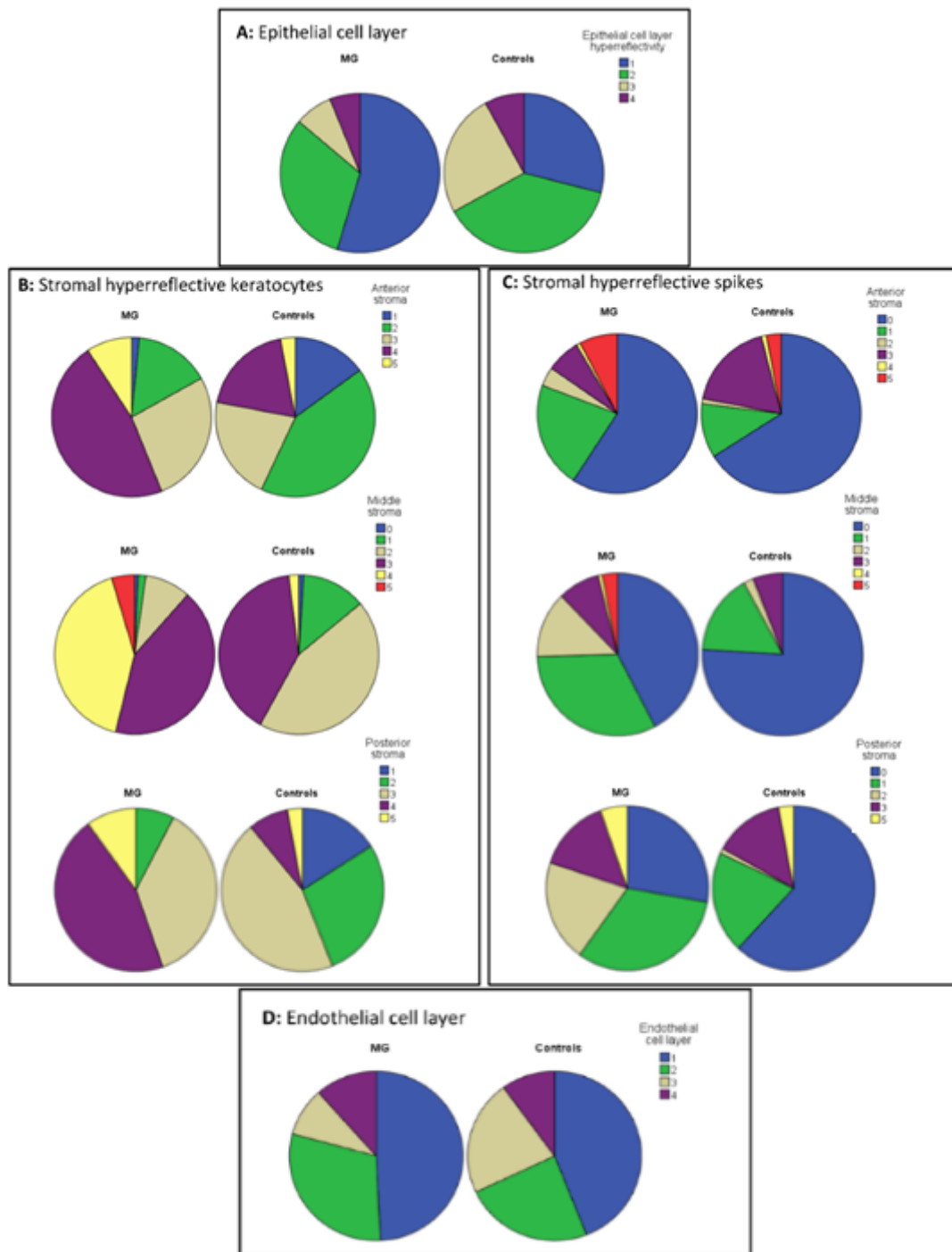
Using Pentacam, in the first, second and third annular zone and along all analyzed corneal zones together, including anterior, middle and posterior corneal stromal layers, light scattering was significantly higher in monoclonal gammopathy subjects, than in controls ( $p \leq 0.04$ ). Nevertheless, in the fourth annular zone (10-12 mm) corneal light scattering did not differ between groups ( $p \geq 0.152$ ) (**Figure 3**).

Using IVCM, epithelial cell layer hyperreflectivity was significantly higher in controls, than in MG subjects ( $p < 0.001$ ) (**Table 7, Figure 4**). With IVCM, the number of stromal hyperreflective keratocytes per micrograph was significantly higher in anterior, middle and posterior stromal layers of subjects with monoclonal gammopathy, than in controls ( $p < 0.001$ ) (**Table 7, Figure 4**). In MG subjects, a higher proportion of subjects belonged to groups 3, 4 and 5, as in controls, concerning stromal hyperreflective keratocytes. The number of stromal hyperreflective spikes per micrograph was also significantly higher in anterior, middle and posterior stromal layers of subjects with monoclonal gammopathy, than in controls ( $p \leq 0.015$ ). Concerning spikes, proportion of MG subjects was higher in groups 3 and 4 as those in controls (**Table 7, Figure 4**). Using *in vivo* confocal microscopy, endothelial cell layer properties did not differ significantly between MG subjects and controls ( $p=0.059$ , **Table 7, Figure 4**).



**Figure 3.** Corneal densitometry values at the central (A), intermediate (B), peripheral (C) and limbal (D) annular corneal zones and in all stromal zones (0-12 mm) (E) using Pentacam (Oculus, Wetzlar, Germany) at the anterior (AL), middle (ML) and posterior (PL) corneal stromal layers and along the complete corneal thickness (TL) in monoclonal gammopathy (MG) and in control subjects. Small circles in the graphs show extreme values and stars (\*) outliers. P values show results of the statistical analysis using Mann-Whitney U test. P values below 0.001 are marked with “\*\*\*”, other significant p values are marked with “\*\*”





**Figure 4.** Proportion of subgroups 0-5 considering epithelial cell layer properties (A), hyperreflective stromal keratocytes per micrograph (B), hyperreflective stromal spikes per micrograph (C) and endothelial cell layer properties (D) among monoclonal gammopathy eyes and control eyes.

**Table 7.** Number (%) of eyes with monoclonal gammopathy and number (%) of control eyes in groups 0–5, concerning epithelial cell layer properties, number of hyperreflective stromal keratocytes and hyperreflective stromal spikes per micrograph and endothelial cell layer properties. *p* values show results of the statistical analysis using  $\chi^2$  test. The arbitrary scoring system, described in Table 4, has been used. \* Significantly higher in controls, as in MG subjects.

	Epithelial cell layer hyperreflectivity/ micrograph	Number of stromal hyperreflective keratocytes/ micrograph			Number of stromal hyperreflective spikes/ micrograph			Endothelial cell layer	
		Anterior stroma	Middle stroma	Posterior stroma	Anterior stroma	Middle stroma	Posterior stroma		
<b>MG</b>	0	-	0	1 (0.8%)	0	77 (59.2%)	55 (42.3%)	36 (27.7%)	-
	1	71 (54.6%)	2 (1.5%)	2 (1.5%)	0	28 (21.5%)	42 (32.3%)	42 (32.3%)	64 (49.2%)
	2	41 (31.5%)	20 (15.4%)	12 (9.2%)	10 (7.7%)	5 (3.8%)	17 (13.1%)	26 (20.0%)	39 (30.0%)
	3	10 (7.7%)	35 (26.9%)	55 (42.3%)	48 (36.9%)	9 (6.9%)	11 (8.5%)	19 (14.6%)	12 (9.2%)
	4	8 (6.2%)	61 (46.9%)	54 (41.5%)	59 (45.4%)	1 (0.8%)	1 (0.8%)	0	15 (11.5%)
	5	-	12 (9.2%)	6 (4.6%)	13 (10.0%)	10 (7.7%)	4 (3.1%)	7 (5.4%)	-
<b>Controls</b>	0	-	0	1 (1.0%)	0	66 (66.0%)	76 (76.0%)	62 (62.0%)	-
	1	29 (29.0%)	15 (15.0%)	13 (13.0%)	16 (16.0%)	11 (11.0%)	16 (16.0%)	20 (20.0%)	44 (44.0%)
	2	38 (38.0%)	42 (42.0%)	44 (44.0%)	28 (28.0%)	1 (1.0%)	2 (2.0%)	1 (1.0%)	24 (24.0%)
	3	25 (25.0%)	21 (21.0%)	40 (40.0%)	45 (45.0%)	18 (18.0%)	6 (6.0%)	14 (14.0%)	22 (22.0%)
	4	8 (8.0%)	19 (19.0%)	2 (2.0%)	8 (8.0%)	1 (150%)	0	0	10 (10.0%)
	5	-	3 (3.0%)	0	3 (3.0%)	3 (3.0%)	0	3 (3.0%)	-
<b>p value</b>	<b>&lt;0.001*</b>	<b>&lt;0.001</b>	<b>&lt;0.001</b>	<b>&lt;0.001</b>	<b>0.015</b>	<b>&lt;0.001</b>	<b>&lt;0.001</b>	<b>&lt;0.001</b>	0.059

## 4. Discussion

### 4.1 *Ocular signs and ocular comorbidities in monoclonal gammopathy*

To the best of our knowledge, this is the first study to analyze ocular signs and ocular comorbidities in monoclonal gammopathy. In Hungary, approximately 350-400 new patients are diagnosed and registered with multiple myeloma yearly and 120-150 autologous bone marrow transplantations are performed due to multiple myeloma [66]. The incidence of MGUS is unknown. Most interestingly, ocular surface disease and cataract are more common and BCVA and OSDI scores are worse (BCVA lower, OSDI scores higher) in patients with gammopathy than in age-matched controls.

In our analyzed cohort with gammopathy with a mean age of 67.61 years and control subjects with a mean age of 62.44 years, the prevalence of ocular surface disease using the OSDI questionnaire was 66.67% and 37.21%, respectively. In the literature, the prevalence of dry eye disease in subjects older than 50 years was described to be 5-34% [67, 68], which confirms our results observed in the control subjects. Nevertheless, in patients with monoclonal gammopathy, the OSDI score and prevalence of ocular surface disease was significantly higher than expected. This could be related to the monoclonal gammopathy itself, or to the previous systemic corticosteroid treatment or chemotherapy, which the patients underwent (for malignant plasma cell disorder). Dry eye disease has been previously described as a side effect of these systemic treatment forms [69].

Although the percentage of patients with previous cataract surgery did not differ significantly between both groups, the proportion of subjects with unoperated posterior cortical cataract or cataract was significantly higher in subjects with gammopathy (13.13% vs 3.49% and 53.75% vs. 19.76%), as in controls ( $p=0.0001$  and  $p=0.01$ ). Similarly to dry eye disease, cataract formation has also been associated with systemic corticosteroid treatment (subjects with plasma cell malignancy exhibiting monoclonal gammopathy often receive systemic steroids over months, mostly due to induction therapy before autologous stem cell transplantation) and multiagent chemotherapy, previously, [70] but could also be associated with the monoclonal gammopathy itself and the changes in protein metabolism. Chen et al. described cataract prevalence in 6725

subjects older than 50 years in 23.1% [71]. In our study population with monoclonal gammopathy, cataract prevalence was more than two times higher than in our control subjects and nearly two times higher than in the study of Chen et al. In addition, cataract prevalence was also similar in the corticosteroid naive MGUS patient group.

Prevalence of chronic blepharitis was described to be 8.1% in subjects older than 40 years by Rim et al. [72] Similarly, there was chronic blepharitis in 10.0% of gammopathy subjects and its percentage did not differ from our control subjects, or historic data.

The prevalence of Meibomian gland dysfunction was described to be 36% in subjects with 50-59 years of age [73]. Interestingly, Meibomian gland dysfunction was rather uncommon with 11.63% in our control and with 18.75% in our gammopathy groups, without statistically significant difference.

Epidemiological data show that patients with myeloproliferative neoplasms suffer from an accelerated accumulation of subretinal drusen and this phenomenon is associated with an increased risk of neovascular age-related macular degeneration (AMD) [74]. Immunoglobulin deposition has also been associated with maculopathy and the appearance of foveolar drusen [26]. Although there was AMD in 7.5% of our gammopathy subjects and none in our control subjects, the percentage of macular or retinal drusen did not differ between both groups with 11.25% vs 18.6%. This needs further analysis.

There are numerous studies in the literature describing corneal deposition in monoclonal gammopathy. In 2004, Garibaldi et al. [33] presented a case report and literature review, summarizing 38 cases with corneal deposition. In our subjects with monoclonal gammopathy, the suggested immunoglobulin deposition was present in only 3.75%, a relatively low percentage of 160 eyes, still, the ophthalmologists have an essential role in detecting paraproteinaemic keratopathy as an ophthalmic sign of the hematological disease, which should never be forgotten.

In our study, 12 eyes of 6 patients (7.50%) with monoclonal gammopathy had glaucoma; 10 eyes (6.25%) had open-angle (OAG) and 2 eyes (1.25%) angle-closure glaucoma (ACG). Bertaud et al. [75] described the prevalence of OAG 3.05% in subjects between 40 and 80 years of age. Wright [76] et al. described the prevalence of ACG 0.02% in subjects with 40-49 years of age and ACG prevalence increases to 0.95% in subjects older than 70 years. Between our controls, there were 4 eyes (4.65%) with glaucoma. The

proportion of glaucoma subjects was slightly higher in monoclonal gammopathy, nevertheless, without a statistically significant difference, compared to our control population. Nevertheless, compared to literature data, both OAG and ACG prevalence was higher in our monoclonal gammopathy subjects as in the general population. Therefore, during an ophthalmic check-up, glaucoma screening should always be performed in monoclonal gammopathy subjects.

Although the percentage of epiretinal membrane was 6.25% among gammopathy subjects, this did not differ significantly from those in controls (2.33%).

In plasma cell disorders, venous thromboembolism is a frequent complication due to hyperviscosity of the blood [30, 77]. This is well displayed in ophthalmic findings in our patients, as we found 1 subject with previous central retinal artery occlusion and one with branch retinal vein occlusion. Both entities warrant regular ophthalmic checkups and ophthalmic treatment.

In addition to immunoglobulin deposition in the cornea and conjunctiva, other ophthalmic abnormalities have been reported in monoclonal gammopathy [24]. Some publications report the simultaneous appearance of monoclonal gammopathy and acute or chronic uveitis [25]. Moreover accumulation of monoclonal immunoglobulin crystals (kappa light chain type) in orbital fat and extraocular muscles, causing invasive masses (crystal storage histiocytosis) have been reported. Palpebral ecchymoses can occur due to vascular fragility secondary to amyloid. Munteanu et al. suggested a connection between Doyme's retinal dystrophy, benign monoclonal gammopathy, and the presence of corneal deposits [29]. Nevertheless, none of these entities were verified in our subjects, referring to the heterogeneity of diseases with monoclonal gammopathy, also concerning ocular signs and ocular comorbidities.

In summary, ocular surface disease and cataract are more common and BCVA is worse in patients with monoclonal gammopathy than in age-matched controls. Therefore, and due to the potential ocular signs and comorbidities of monoclonal gammopathy, we suggest a regular, yearly ophthalmic checkup of these patients to improve their quality of life.

#### ***4.2 Corneal densitometry and in vivo confocal microscopy in monoclonal gammopathy***

Paraproteinemic keratopathy is a relative rare ocular sign of monoclonal gammopathy. Most ophthalmologists do not recognize paraproteinaemic keratopathy and do not send symptomatic subjects to hematological examination. Garibaldi et al summarized previous case reports and case series from the literature in 2005 [33]. Using slitlamp biomicroscopy, Bourne et al. [78] described corneal opacities in 1 of 100 monoclonal gammopathy subjects. Arson and Shaw [79] could not verify corneal involvement in 13 subjects with multiple myeloma using a slitlamp. In our present study, we observed paraproteinemic keratopathy in 12 (9.23%) eyes using a slitlamp and analyzing a larger cohort of 130 eyes of patients with monoclonal gammopathy. This higher percentage of subjects with corneal involvement could be explained through the longer standing (in most of the cases 5-10 years) hematological disease of the patients. Nevertheless, paraproteinemic keratopathy did not influence keratometric values, corneal astigmatism and central corneal thickness in patients of the present study.

Using Pentacam, corneal light scattering was significantly higher in the anterior, central and posterior stromal layers of the cornea in the central, intermediate and peripheral annular corneal zones (all together 0–10 mm centrally) of monoclonal gammopathy patients, than in healthy controls. None of the patients had corneal pathologies or previous corneal surgeries which may have resulted in an increased corneal light scattering. An increased corneal thickness may also result in increased corneal light scattering. Nevertheless, as corneal thickness (apex pachymetry) did not differ between MG subjects and controls (**Table 6**), the increased corneal light scattering could not be related to this factor.

Busch and Ichii [50, 51] also reported a significantly higher corneal light scattering at the central 6 mm diameter corneal area in the anterior and central stroma of patients with monoclonal gammopathy, analyzing 10 and 30 MG subjects. Enders et al. [49] found a significantly increased corneal light scattering in the central 10 mm corneal zone along the total corneal thickness (anterior, central and posterior stroma), in five patients with monoclonal gammopathy. Our study provides additional strength to previous studies showing increased corneal light scattering in 130 eyes with monoclonal gammopathy—in a larger cohort of subjects (**Table 8**). Therefore, in case other listed corneal pathologies

may be excluded, an increased central corneal light scattering (0–10 mm central corneal zone) may arise suspicion of corneal changes due to monoclonal gammopathy.

Nevertheless, there may be several changes in the corneal stroma of MG subjects over time. With increasing disease length, corneal stromal deposition may increase, although, this may also decrease again in case of systemic treatment of the hematological disease. These processes may all bear an impact on corneal light scattering over time. In our opinion, an increased corneal light scattering may be an important sign of monoclonal gammopathy, nevertheless, describing the course of the disease, it may be more appropriate to describe an impaired light scattering in MG, as it has also been described in the publication of Ichii et al. [51]. Corneal light scattering changes in the course of diseases with monoclonal gammopathy need further analysis.

The origin of the corneal deposits in monoclonal gammopathy is still not well understood. Some authors suggest that these may be delivered from the limbal vessels to the cornea [80] or may be transported from the tear film (immunoglobulins), or from the aqueous humor [26,33]. Some authors also suggested that these deposits may be locally synthesized through stromal keratocytes [33]. Based on the results of our densitometric analysis, direct immunoglobulin transport from the limbal vessels is less likely, as we did not find an increased corneal light scattering at the corneal limbal zone of MG subjects, compared to controls. We also could not find a predominantly anterior or posterior stromal increase of corneal light scattering in MG corneas, referring to a potential anterior or posterior origin of corneal deposits from the tear film (anteriorly) or from the aqueous humor (posteriorly).

*In vivo* confocal microscopy is a noninvasive device to imagine the cornea at the cellular and microstructural level. Its application has expanded over the past decades. Nevertheless, using IVCN, several corneal pathologies should be recognized or excluded, in order to avoid misinterpretation of the images.

With IVCN, the number of stromal hyperreflective keratocytes and hyperreflective spikes per micrograph was significantly higher in anterior, middle and posterior stromal layers of subjects with monoclonal gammopathy, than in controls ( $p \leq 0.012$ ). In contrast, Aragona et al. [62] described a significantly decreased keratocyte density in subjects with MG, examining 31 patients with MG, in Messina, Italy. Keratocyte density may be increased in keratitis [81-85], in autoimmune diseases [86], in some corneal dystrophies

[81,87-91], or following corneal surgeries such as crosslinking or corneal transplantation [92-97]. Nevertheless, keratocyte density decreases in ectatic corneal diseases [98-102] and congenital glaucoma [103]. None of the analyzed subjects had any of these diagnoses in the present study. Therefore, we speculate that the increased keratocyte density is rather related to the hematological disease of the patients. Corneal stromal cells may behave similarly to hematopoietic stem cells [104]. The phenomenon, that these may undergo myofibroblastic transformation is well known [105]. In addition, these may have a very similar gene expression profile to bone marrow cells [106]. Therefore, it is possible, that the keratocyte activation in these patients show parallel features to bone marrow changes/activity of the MG subjects. This needs further analysis.

Beside one case report [107], no previous study described the appearance of hyperreflective spikes in the corneal stroma of monoclonal gammopathy subjects. Generally, as an example, amyloid, chloroquine, ciprofloxacin, gold and iron may all cause stromal deposition [81, 107-109]. On the other hand, these do not result in hyperreflective stromal spikes in confocal microscopy [24,33,110].

Subepithelial nerves may be falsely interpreted as hyperreflective spikes using IVCN. Nevertheless, these are not present in an increased density in the deeper corneal stromal layers, which therefore helps in an appropriate interpretation of IVCN images. To our knowledge, an increased nerve density in the middle and posterior corneal stromal layers of monoclonal gammopathy subjects has not yet been described. We suggest that the detected hyperreflective stromal spikes may either show corneal stromal immunoglobulin deposition (invisible with the slit lamp but detectable using IVCN) or may be present due to stromal drug deposition (systemic treatment of the hematological disease). These also need further clarification.

In summary, our study confirms that increased corneal light scattering in the central 10 mm annular zone and increased keratocyte hyperreflectivity may give rise to suspicion of monoclonal gammopathy. As corneal light scattering is not increased at the limbal 10–12 mm annular zone of monoclonal gammopathy subjects, our spatial analysis provides evidence against the limbal origin of corneal paraprotein deposits. Using IVCN, stromal hyperreflective spikes may represent specific signs of monoclonal gammopathy, independent of the depth of their stromal localization. Nevertheless, during follow-up of



a hematological disease, corneal stromal changes must be further analyzed to obtain better insight into their pathophysiology and in corneal symptoms of monoclonal gammopathy.

## 5. Conclusions

Our studies aimed to analyse ocular signs and ocular comorbidities in monoclonal gammopathy. Following analysis of 130 eyes of 65 patients with monoclonal gammopathy, we had the following conclusions:

**5.1** Ocular surface disease and cataract are more common and BCVA is worse in patients with monoclonal gammopathy than in age-matched controls. Therefore, and due to the potential ocular signs and comorbidities of monoclonal gammopathy, we suggest a regular, yearly ophthalmic checkup of these patients to improve their quality of life.

**5.2** Our study confirms that increased corneal light scattering in the central 10 mm annular zone and increased keratocyte hyperreflectivity may give rise to suspicion of monoclonal gammopathy. As corneal light scattering is not increased at the limbal 10–12 mm annular zone of monoclonal gammopathy subjects, our spatial analysis provides evidence against the limbal origin of corneal paraprotein deposits. Using IVCN, stromal hyperreflective spikes may represent specific signs of monoclonal gammopathy, independent of the depth of their stromal localization. Nevertheless, during follow-up of a hematological disease, corneal stromal changes must be further analyzed to obtain better insight into their pathophysiology and in corneal symptoms of monoclonal gammopathy.

## 6. Summary

Studies on ocular signs and ocular comorbidities in subjects with monoclonal gammopathy are limited. First, we aimed to examine the ocular signs of monoclonal gammopathy and to evaluate ocular comorbidities in subjects with monoclonal gammopathy. Second, our purpose was to analyze corneal stromal properties using Pentacam and *in vivo* confocal cornea microscopy (IVCM) in subjects with monoclonal gammopathy.

In the first study, we analyzed patients from two large referral hematology centers in Budapest, diagnosed and/or treated with monoclonal gammopathy between 1997-2020. As a control group, randomly selected individuals of the same age group, without haematological disease have been included. There were 160 eyes of 80 patients (38.75% males; age  $67.61 \pm 10.48$  (range 38-85) years) with monoclonal gammopathy and 86 eyes of 43 control subjects (32.56% males; age  $62.44 \pm 11.89$  (range 37-86) years). The hematological diagnosis was MGUS in 9 (11.25%), multiple myeloma in 61 (76.25%), smoldering myeloma in 6 (7.50%), and amyloidosis or Waldenström macroglobulinemia in 2-2 cases (2.50%-2.50%). Before detailed ophthalmic examination with fundoscopy, 42 subjects with gammopathy (52.50%) and all controls filled the Ocular Surface Disease Index (OSDI) questionnaire.

In the second study, patients with monoclonal gammopathy (130 eyes of 65 patients (40.0% males; age  $67.65 \pm 9.74$  years) and randomly selected individuals of the same age group, without haematological disease (100 eyes of 50 control subjects (40.0% males; age  $60.67 \pm 15.06$  years) have been included. Using Pentacam (Pentacam HR; Oculus GmbH, Wetzlar, Germany), corneal stromal light scattering values were obtained 1) centrally 0-2 mm zone; 2) 2-6 mm zone; 3) 6-10 mm zone; 4) 10-12 mm zone. Using IVCM with Heidelberg Retina Tomograph with Rostock Cornea Module (Heidelberg Engineering, Heidelberg, Germany), the density of hyperreflective keratocytes and the number of hyperreflective spikes per image have been manually analyzed in the stroma. In the first study the OSDI score and best-corrected visual acuity (BCVA) were significantly worse in subjects with monoclonal gammopathy than in controls ( $p=0.02$ ;  $p=0.0005$ ). Among gammopathy subjects, we observed potential corneal

immunoglobulin deposition in 6 eyes of 4 (3.75%) patients. Ocular surface disease ( $p=0.0001$ ), posterior cortical cataract ( $p=0.01$ ), and cataract ( $p=0.0001$ ) were significantly more common among gammopathy subjects than in controls ( $\chi^2$  test).

We found in our second study that in the first, second and third annular zone, light scattering was significantly higher in monoclonal gammopathy subjects, than in controls ( $p\leq 0.04$ ). The number of hyperreflective keratocytes and hyperreflective spikes per image was significantly higher in stroma of subjects with monoclonal gammopathy ( $p\leq 0.012$ ).

In summary, ocular surface disease and cataract are more common and BCVA is worse in patients with monoclonal gammopathy than in age-matched controls. Therefore, and due to the potential ocular signs and comorbidities of monoclonal gammopathy, we suggest a regular, yearly ophthalmic checkup of these patients to improve their quality of life. Increased corneal light scattering in the central 10 mm annular zone and increased keratocyte hyperreflectivity may give rise to suspicion of monoclonal gammopathy. As corneal light scattering is not increased at the limbal 10–12 mm annular zone of monoclonal gammopathy subjects, our spatial analysis provides evidence against the limbal origin of corneal paraprotein deposits. Using IVCN, stromal hyperreflective spikes may be specific signs of monoclonal gammopathy, independent of the depth of their stromal localization.

## 7. References

1. International Myeloma Working Group. (2003) Criteria for the classification of monoclonal gammopathies, multiple myeloma and related disorders: a report of the International Myeloma Working Group. *Br J Haematol*, 121: 749-757.
2. Ho M, Patel A, Goh CY, Moscovin M, Zhang L, Bianchi G. (2020) Changing paradigms in diagnosis and treatment of monoclonal gammopathy of undetermined significance (MGUS) and smouldering multiple myeloma (SMM). *Leukemia*, 34: 3111-31225.
3. Nagy Z. (2016) Multiple myeloma and other plasma cell dyscrasias. [Mielóma multiplex és egyéb plazmasejtes diszkráziák.] *Magy Onkol*, 60: 154–163.
4. Brigden M, Venner C. (2014) Monoclonal gammopathy and primary care. *British Columbia Medical Journal* 2014: 56; 15-22.
5. Caers J, Paiva B, Zamagni E. et al. (2018). Diagnosis, treatment, and response assessment in solitary plasmacytoma: updated recommendations from a European Expert Panel. *J Hematol Oncol*, 11, 10.
6. Albarracin F, Fonseca R. (2011) Plasma cell leukemia. *Blood Rev*, 25(3): 107-112.
7. Szemlaky Z, Mikala G. (2017) Waldenström's macroglobulinemia and its individualized therapy options. [A Waldenström-macroglobulinaemia és betegségére szabott kezelése.] *Orvosi Hetilap*, 158: 1604–1614.
8. Németh O, Tapasztó B, Tar S, Szabó V, Nagy ZZ, Tóth J, Hamed A, Mikala G, Szentmáry N. (2018) Corneal deposits in monoclonal gammopathy of undetermined significance. Review of the literature and case report. [Szaruhártya-lerakódások bizonytalan jelentőségű monoklonális gammopathiában. Irodalmi áttekintés és esetbemutató.] *Orvosi Hetilap*, 159: 1575–1583.
9. Rajkumar SV. (2015) Evolving diagnostic criteria for multiple myeloma. *Hematology Am Soc Hematol Educ Program*, 2015: 272– 278.
10. Landgren O, Kyle RA, Pfeiffer RM, Katzmann JA, Caporaso NE, Hayes RB, Dispenzieri A, Kumar S, Clark RJ, Baris D, Hoover R, Rajkumar SV. (2009) Monoclonal gammopathy of undetermined significance (MGUS) consistently precedes multiple myeloma: a prospective study. *Blood*, 113: 5412–5417.

11. Kyle RA, Therneau TM, Rajkumar SV, Larson DR, Plevak MF, Offord JR, Dispenzieri A, Katzmann JA, Melton LJ 3rd. (2016) Prevalence of monoclonal gammopathy of undetermined significance. *N Engl J Med*, 354: 1362–1369.
12. Nasr SH, Valeri AM, Cornell LD, Fidler ME, Sethi S, D’Agati VD, Leung N. (2012) Renal monoclonal immunoglobulin deposition disease: A report of 64 patients from a single institution. *Clin J Am Soc Nephrol*, 7: 231-239
13. Sathick IJ, Drosou ME, Leung N. (2019) Myeloma light chain cast nephropathy, a review. *J Nephrol*, 32: 189-198.
14. Steiner N, Schwarzler A, Göbel G, Loscher W, Wanschitz J, Gunsilius E. (2017) Are neurological complications of monoclonal gammopathy of undetermined significance underestimated? *Oncotarget*, 8: 5081-5091.
15. Mathis S, Franques J, Richard L, Vallat JM. (2016) Monoclonal gammopathy of undetermined significance and endoneurial IgG deposition: a case report. *Medicine (Baltimore)*, 95: e4807.
16. Ramchandren S, Lewis RA. (2012) An update on monoclonal gammopathy and neuropathy. *Curr Neurol Neurosci Rep*, 12: 102-110.
17. Lictman M, Balderman SR. (2015) Unusual manifestations of essential monoclonal gammopathy. II simulation of the insulin autoimmune syndrome. *Rambam Maimonides Med. J*, 6: e0027
18. Buxbaum JN, Genega EM, Lazowski P, Kumar A, Tunick PA, Kronzon I, Gallo GR. (2000) Infiltrative nonamyloidotic monoclonal immunoglobulin light chain cardiomyopathy: an underappreciated manifestation of plasma cell dyscrasias. *Cardiology*, 93: 220-228.
19. Erciyestepe M, Tiryaki TO, Hindilerden IY, Yegen GI, Nalcaci M. (2020) A case with hepatic involvement mimicking metastatic disease in multiple myeloma. *Case Rep Hematol*, 17: 5738319.
20. Daoud MS, Lust JA, Kyle RA, Pittelkow MR. (1999) Monoclonal gammopathies and associated skin disorders. *J Am Acad Dermatology*, 40: 507-535.
21. Dispenzieri A. (2020) Monoclonal gammopathies of clinical significance. *Hematology Am Soc Hematol Educ Program*, 2020 (1): 380-388.
22. Szentmáry N, Kormányos K, Kovács K, Németh O, Tóth G, Sándor GL, Csorba A, Czako CN, Langenbacher A, Nagy ZZ, Varga G, Gopcsa L, Mikala G. (2021)

- Szemészeti tünetek és szemészeti társbetegségek monoklonális gammopathiával járó kórképekben. [Ophthalmic symptoms and ocular comorbidities in diseases with monoclonal protein production] *Hematológia Transzfuziológia*, 54: 82-88.
23. Garderet L, Al Hariri M, Wasielica-Poslednik J, Munder M, Kormányos K, Pena C, Gozzetti A, Zhou X, Waszczuk-Gajda A, Rosinol L, Mikala G, Krzystanski M, Lisch W, Vesole D, Szentmáry N, Jurczyszyn A. (2021) Monoclonal gammopathy of ocular significance (MGOS) - a short survey of corneal manifestations and treatment outcomes. *Leuk Lymphoma*, 25:1-7.
  24. Milman T, Kao AA, Chu D, Gorski M, Steiner A, Simon CZ, Shih C, Aldave AJ, Eagle RC Jr, Jakobiec FA, Udell I. (2015) Paraproteinemic keratopathy. The expanding diversity of clinical and pathologic manifestations. *Ophthalmology*, 122: 1748–1756.
  25. Barr CC, Gelender H, Font RL. (1980) Corneal crystalline deposits associated with dysproteinemia. Report of two cases and review of the literature. *Arch Ophthalmol*, 98: 884–889.
  26. Ormerod LD, Collin HB, Dohlman CH, Craft JL, Desforges JF, Albert DM. (1988) Paraproteinemic crystalline keratopathy. *Ophthalmology*, 95: 202–212.
  27. Balderman SR, Lichtman MA. (2015) Unusual manifestations of monoclonal gammopathy: I. ocular disease. *Rambam Maimonides Med J*, 6: e0026.
  28. Smith SJ, Johnson MW, Ober MD, Comer GM, Smith BD. (2020) Maculopathy in patients with monoclonal gammopathy of undetermined significance. *Ophthalmol Retina*, 4: 300-309.
  29. Munteanu G. (1980) Doyne's macular heredodystrophy and benign monoclonal gammopathy. Genetic and pathogenetic correlations. [L'hérérodystrophie maculaire de Doyne et la gammopathie monoclonale benign. Corrélations génétiques et pathogéniques.] *J Fr Ophtalmol*, 3: 753–758.
  30. Agorogiannis EI, Kotamarthi V. (2015) Paraproteinemia and central retinal vein occlusion. *Hippokratia*, 19: 92.
  31. Nakazawa T, Yamaguchi K, Nakagawa Y et al. (2004) Two cases of orbital myositis with monoclonal gammopathy of undetermined significance. *Nippon Ganka Gakkai Zasshi*, 108: 110–117.

32. Meesmann A. (1934) Über eine eigenartige Hornhautdegeneration (?) (Ablagerung des Bence-Jones-schen Eiweisskörpers in der Hornhaut). *Ber Dtsch Ophthalmol Ges*, 50: 311–315.
33. Garibaldi DC, Gottsch J, de la Cruz Z, Haas M, Green WR. (2005) Immunotactoid keratopathy: a clinicopathologic case report and a review of reports of corneal involvement in systemic paraproteinemias. *Surv Ophthalmol*, 50: 61–80.
34. Lisch W, Saikia P, Pitz S, Pleyer U, Lisch C, Jaeger M, Rohrbach JM. (2012) Chameleon-like appearance of immunotactoid keratopathy. *Cornea*, 31: 55–58.
35. Lisch W, Wasielica-Poslednik J, Kivelä T, Schlötzer-Schrehardt U, Rohrbach JM, Sekundo W, Pleyer U, Lisch C, Desuki A, Rossmann H, Weiss JS. (2016) The hematologic definition of monoclonal gammopathy of undetermined significance in relation to paraproteinemic keratopathy (an american ophthalmological society thesis). *Trans Am Ophthalmol Soc*, 114: T7. Erratum in: *Trans Am Ophthalmol Soc*, 114: T7C1.
36. O'Donnell C, Wolffsohn JS. (2004) Grading of corneal transparency. *Cont Lens Anterior Eye*, 4:161-70.
37. Maurice DM. (1957) The structure and transparency of the cornea. *J Physiol*, 136 (2): 263-286.
38. Wegener A, Laser-Junga H. (2009) Photography of the anterior eye segment according to Scheimpflug's principle: options and limitations - a review. *Clin Exp Ophthalmol*, 37 (1): 144-154.
39. Lopes B, Ramos I, Ambrósio R Jr. (2014) Corneal densitometry in keratoconus. *Cornea* 33 (12): 1282-1286.
40. Çağlayan M, Öncül H, Alakus MF, Dag U. (2021) Corneal and lens densitometry with Pentacam HR in children with vernal keratoconjunctivitis. *Clin Exp Optom*, 104 (2): 156-161.
41. Kamiya K, Kobashi H, Igarashi A, Shoji N, Shimizu K. (2016) Effect of light scattering and higher-order aberrations on visual performance in eyes with granular corneal dystrophy. *Sci Rep*, 6: 24677.
42. Oie Y, Watanabe S, Nishida K. (2016) Evaluation of visual quality in patients with Fuchs endothelial corneal dystrophy. *Cornea*, 35 Suppl 1: S55-S58.



43. Otri AM, Fares U, Al-Aqaba MA, Dua HS. (2012) Corneal densitometry as an indicator of corneal health. *Ophthalmology*, 119 (3): 501-508.
44. Patel SV, McLaren JW, Hodge DO, Baratz KH. (2008) Scattered light and visual function in a randomized trial of deep lamellar endothelial keratoplasty and penetrating keratoplasty. *Am J Ophthalmol*, 145 (1): 97-105.
45. Rozema JJ, Trau R, Verbruggen KH, Tassignon MJ. (2011) Backscattered light from the cornea before and after laser-assisted subepithelial keratectomy for myopia. *J Cataract Refract Surg*, 37 (9): 1648-1654.
46. Greenstein SA, Fry KL, Bhatt J, Hersh PS. (2010) Natural history of corneal haze after collagen crosslinking for keratoconus and corneal ectasia: Scheimpflug and biomicroscopic analysis. *J Cataract Refract Surg*, 36 (12): 2105-2114.
47. Dong J, Zhang Y, Zhang H, Jia Z, Zhang S, Sun B, Han Y, Wang X. (2018) Corneal densitometry in high myopia. *BMC Ophthalmol*, 18 (1): 182.
48. Ramm L, Spoerl E, Pillunat LE, Terai N. (2020) Corneal densitometry in diabetes mellitus. *Cornea*, 39 (8): 968-974.
49. Enders P, Holtick U, Schaub F, Tuchscherer A, Hermann MM, Scheid C, Cursiefen C, Bachmann BO. (2017) Corneal densitometry for quantification of corneal deposits in monoclonal gammopathies. *Cornea*, 36 (4): 470-475.
50. Busch C, Koh S, Oie Y, Ichii M, Kanakura Y, Nishida K. (2017) Increased corneal densitometry as a subclinical corneal change associated with multiple myeloma. *Eye (Lond)*, 31 (12): 1745-1746.
51. Ichii M, Koh S, Maeno S, Busch C, Oie Y, Maeda T, Shibayama H, Nishida K, Kanakura Y. (2019) Noninvasive assessment of corneal alterations associated with monoclonal gammopathy. *Int J Hematol*, 110 (4): 500-505.
52. Paladini I, Pieretti G, Giuntoli M, Abbruzzese G, Menchini U, Mencucci R. (2013) Crystalline corneal deposits in monoclonal gammopathy: in-vivo confocal microscopy. *Semin Ophthalmol*, 28 (1): 37-40.
53. Spiegel P, Grossniklaus HE, Reinhart WJ, Thomas RH. (1990) Unusual presentation of paraproteinemic corneal infiltrates. *Cornea*, 9 (1): 81-85.
54. Stirling JW, Henderson DW, Rozenblds MA, Skinner JM, Filipic M. (1997) Crystalloidal paraprotein deposits in the cornea: an ultrastructural study of two

- new cases with tubular crystalloids that contain IgG kappa light chains and IgG gamma heavy chains. *Ultrastruct Pathol*, 21 (4): 337-344.
55. Møller HU, Ehlers N, Bojsen-Møller M, Ridgway AE. (1993) Differential diagnosis between granular corneal dystrophy Groenouw type I and paraproteinemic crystalline keratopathy. *Acta Ophthalmol (Copenh)*, 71 (4): 552-555.
  56. Yassa NH, Font RL, Fine BS, Koffler BH. (1987) Corneal immunoglobulin deposition in the posterior stroma. A case report including immunohistochemical and ultrastructural observations. *Arch Ophthalmol*, 105 (1): 99-103.
  57. Kleta R, Blair SC, Bernardini I, Kaiser-Kupfer MI, Gahl WA. (2004) Keratopathy of multiple myeloma masquerading as corneal crystals of ocular cystinosis. *Mayo Clin Proc*, 79 (3): 410-412.
  58. Buerk BM, Tu E. (2002) Confocal microscopy in multiple myeloma crystalline keratopathy. *Cornea*, 21 (6): 619-620.
  59. Houben N, Foets B. (2006) Confocal microscopy in multiple myeloma associated crystalline keratopathy: case report. *Bull Soc Belge Ophtalmol*, (300):13-17.
  60. Steinberg J, Eddy MT, Katz T, Matthiessen E, Fricke OH, Richard G, Linke SJ. (2011) Bilateral crystalline corneal deposits as first clinical manifestation of monoclonal gammopathy: a case report. *Case Rep Ophthalmol*, 2 (2): 222-227.
  61. Kocabeyoglu S, Mocan MC, Haznedaroglu IC, Uner A, Uzunosmanoglu E, Irkec M. (2014) In vivo confocal microscopic characteristics of crystalline keratopathy in patients with monoclonal gammopathy: report of two cases. *Indian J Ophthalmol*, 62 (9): 938-940.
  62. Aragona P, Allegra A, Postorino EI, Rania L, Innao V, Wylegala E, Nowinska A, Ieni A, Pisani A, Musolino C, Puzzolo D, Micali A. (2016) Corneal structural changes in nonneoplastic and neoplastic monoclonal gammopathies. *Invest Ophthalmol Vis Sci*, 57 (6): 2657-2665.
  63. Kormányos K, Kovács K, Németh O, Tóth G, Sándor GL, Csorba A, Czakó CN, Langenbacher A, Nagy ZZ, Varga G, Gopcsa L, Mikala G, Szentmáry N. (2021) Ocular signs and ocular comorbidities in monoclonal gammopathy: Analysis of 80 subjects. *J Ophthalmol*. 9982875.

64. Kormányos K, Kovács K, Németh O, Tóth G, Sándor GL, Csorba A, Czakó CN, Langenbacher A, Nagy ZZ, Varga G, Gopcsa L, Mikala G, Szentmáry N. (2021) A monoklonális gammopathia szemészeti jelei és szövődményei: 42 beteg 84 szemének vizsgálata [Ocular signs and comorbidities in monoclonal gammopathy: Analysis of 84 eyes of 42 subjects]. *Orv Hetil*, 162 (38): 1533-1540.
65. Kormányos K, Kovács K, Németh O, Tóth G, Sándor GL, Csorba A, Czakó CN, Módis L Jr, Langenbacher A, Nagy ZZ, Varga G, Gopcsa L, Mikala G, Szentmáry N. (2022) Corneal densitometry and confocal microscopy in monoclonal gammopathy – analysis of 65 subjects. *Journal of Clin Med*; 11(7): 1848.
66. Varga G, Mikala G, Váróczy L, Illés Á. (2016) Management of multiple myeloma in Hungary in 2016. [A myeloma multiplex megközelítése Magyarországon 2016-ban.] *Orvosi Hetilap*, 157: 123–137.
67. The epidemiology of dry eye disease: report of the epidemiology subcommittee of the international dry eye workshop. (2007) *Ocular Surf*, 5: 93-107.
68. Dana R, Bradley JL, Guerin A, Pivneva I, Stillman IÖ, Evans AM, Schaumberg DA. (2019) Estimated prevalence and incidence of dry eye disease based on coding analysis of a large, all-age United States Health Care System. *Am J Ophthalmol*, 202: 47-54.
69. Kunkler AL, Binkley EM, Mantopoulos D, Hendershot AJ, Ohr MP, Kendra KL, Davidorf FH, Cebulla CM. (2019) Known and novel ocular toxicities of biologics, targeted agents, and traditional chemotherapeutics. *Graefes Arch Clin Exp Ophthalmol*, 257: 1771-1781.
70. Fel A, Aslangul E, Le Jeune C. (2012) Eye and corticosteroid's use. *Presse Med*, 41: 414-421.
71. Xing C, Dan-Ying Z, Jian S, Yan-Bing W, Qing-Zhu S, Jian-Min D, Jian-Chun Y. (2020) Prevalence and risk factors on age-related cataract and surgery in adults over 50 years old in Binhu District, Wuxi, China. *Int J Ophthalmol*, 13: 445-451.
72. Rim TH, Kang MJ, Choi M, Seo KY, Kim SS. (2017) Ten-year incidence and prevalence of clinically diagnosed blepharitis in South Korea: a nationwide population-based cohort study. *Clin Exp Ophthalmol*, 45: 448-454.

73. Gao JG, Chen J, Tang Y, Chen DN. (2020) Prevalence of meibomian gland dysfunction in staffs and faculty members of a Chinese university. *Int J Ophthalmol*, 13: 1667-1670.
74. Liisborg C, Nielsen MK, Hasselbalch HC, Sørensen TL. (2020) Patients with myeloproliferative neoplasms and high levels of systemic inflammation develop age-related macular degeneration. *Clin Med*, 26: 100526.
75. Bertaud S, Aragno V, Baudouin C. (2019) Primary open-angle glaucoma. [Le glaucome primitif à angle ouvert]. *Rev Med Interne*, 40: 445-452.
76. Wright C, Tawfik MA, Waisbourd M, Katz LJ. (2016) Primary angle-closure glaucoma: an update. *Acta Ophthalmol*, 94: 217-225.
77. Kristinsson SY, Fears TR, Gridley G, Turesson I, Mellqvist UH, Björkholm M, Landgren O. (2008) Deep vein thrombosis after monoclonal gammopathy of undetermined significance and multiple myeloma. *Blood*, 112: 3582–3586.
78. Bourne WM, Kyle RA, Brubaker RF, Greipp PR. (1989) Incidence of corneal crystals in the monoclonal gammopathies. *Am J Ophthalmol*, 15; 107 (2): 192-3.
79. Aronson SB 2nd, Shaw R. (1959) Corneal crystals in multiple myeloma. *AMA Arch Ophthalmol*, 61 (4): 541-546.
80. Singh K. (2009) Immunotactoid microtubular corneal deposits in bilateral paraprotein crystalline keratopathy. *Cornea*, 28 (7): 829-831.
81. Chiou AG, Kaufman SC, Kaufman HE, Beuerman RW. (2006) Clinical corneal confocal microscopy. *Surv Ophthalmol*, 51 (5): 482-500.
82. Avunduk AM, Beuerman RW, Varnell ED, Kaufman HE. (2003) Confocal microscopy of *Aspergillus fumigatus* keratitis. *Br J Ophthalmol*, 87 (4): 409-410.
83. Chew SJ, Beuerman RW, Assouline M, Kaufman HE, Barron BA, Hill JM. (1992) Early diagnosis of infectious keratitis with in vivo real time confocal microscopy. *CLAO J*, 18 (3): 197-201.
84. Auran JD, Starr MB, Koester CJ, LaBombardi VJ. (1994) In vivo scanning slit confocal microscopy of *Acanthamoeba* keratitis. A case report. *Cornea*, 13 (2): 183-185.
85. Kaufman SC, Laird JA, Cooper R, Beuerman RW. (1996) Diagnosis of bacterial contact lens related keratitis with the white-light confocal microscope. *CLAO J*, 22 (4): 274-277.

86. Szalai E, Deák E, Módis L Jr, Németh G, Berta A, Nagy A, Felszeghy E, Káposzta R, Malik RA, Csutak A. (2016) Early corneal cellular and nerve fiber pathology in young patients with type 1 diabetes mellitus identified using corneal confocal microscopy. *Invest Ophthalmol Vis Sci*, 57 (3): 853-858.
87. Chiou AG, Beuerman RW, Kaufman SC, Kaufman HE. (1999) Confocal microscopy in lattice corneal dystrophy. *Graefes Arch Clin Exp Ophthalmol*, 237 (8): 697-701.
88. Ciancaglini M, Carpineto P, Doronzo E, Nubile M, Zuppardi E, Mastropasqua L. (2001) Morphological evaluation of Schnyder's central crystalline dystrophy by confocal microscopy before and after phototherapeutic keratectomy. *J Cataract Refract Surg*, 27 (11): 1892-1895.
89. Kobayashi A, Sugiyama K, Huang AJ. (2004) In vivo confocal microscopy in patients with central cloudy dystrophy of François. *Arch Ophthalmol*, 122 (11): 1676-1679.
90. Vesaluoma MH, Linna TU, Sankila EM, Weiss JS, Tervo TM. (1999) In vivo confocal microscopy of a family with Schnyder crystalline corneal dystrophy. *Ophthalmology*, 106 (5): 944-951.
91. Werner LP, Werner L, Dighiero P, Legeais JM, Renard G. (1999) Confocal microscopy in Bowman and stromal corneal dystrophies. *Ophthalmology*, 106 (9): 1697-1704.
92. Vesaluoma MH, Petroll WM, Pérez-Santonja JJ, Valle TU, Alió JL, Tervo TM. (2000) Laser in situ keratomileusis flap margin: wound healing and complications imaged by in vivo confocal microscopy. *Am J Ophthalmol*, 130 (5): 564-573.
93. Zhou Y, Liu M, Zhang T, Zheng H, Sun Y, Yang X, Weng S, Lin H, Liu Q. (2018) In vivo confocal laser microscopy of morphologic changes after small incision lenticule extraction with accelerated cross-linking (SMILE Xtra) in patients with thin corneas and high myopia. *Graefes Arch Clin Exp Ophthalmol*, 256 (1): 199-207.
94. Dawson DG, Edelhauser HF, Grossniklaus HE. (2005) Long-term histopathologic findings in human corneal wounds after refractive surgical procedures. *Am J Ophthalmol*, 139 (1): 168-178.

95. Leung DY, Yeung EF, Law RW, Young AL, Lam DS. (2004) In vivo confocal microscopy of epithelial inclusions from aberrant wound healing after astigmatic keratotomy. *Cornea*, 23 (3): 299-301.
96. Erie JC. (2003) Corneal wound healing after photorefractive keratectomy: a 3-year confocal microscopy study. *Trans Am Ophthalmol Soc*, 101: 293-333.
97. Erie JC, Patel SV, McLaren JW, Maguire LJ, Ramirez M, Bourne WM. (1999) Keratocyte density in vivo after photorefractive keratectomy in humans. *Trans Am Ophthalmol Soc*, 97:221-36; discussion 236-240.
98. Weed KH, MacEwen CJ, Cox A, McGhee CN. (2007) Quantitative analysis of corneal microstructure in keratoconus utilising in vivo confocal microscopy. *Eye (Lond)*, 21 (5): 614-623.
99. Erie JC, Patel SV, McLaren JW, Nau CB, Hodge DO, Bourne WM. (2002) Keratocyte density in keratoconus. A confocal microscopy study (a). *Am J Ophthalmol*, 134 (5): 689-695.
100. Hollingsworth JG, Efron N, Tullo AB. (2005) In vivo corneal confocal microscopy in keratoconus. *Ophthalmic Physiol Opt*, 25 (3): 254-260.
101. Ozgurhan EB, Kara N, Yildirim A, Bozkurt E, Uslu H, Demirok A. (2013) Evaluation of corneal microstructure in keratoconus: a confocal microscopy study. *Am J Ophthalmol*, 156 (5): 885-893.e2.
102. Ku JY, Grupcheva CN, Fisk MJ, McGhee CN. (2004) Keratoglobus and posterior subcapsular cataract: surgical considerations and in vivo microstructural analysis. *J Cataract Refract Surg*, 30 (1): 237-242.
103. Mastropasqua L, Carpineto P, Ciancaglini M, Nubile M, Doronzo E. (2002) In vivo confocal microscopy in primary congenital glaucoma with megalocornea. *J Glaucoma*, 11 (2): 83-89.
104. Szentmáry N, Wang J, Stachon T, Goebels S, Seitz B. (2013) [CD34 and alpha-smooth muscle actin expression of keratocytes following photodynamic inactivation (PDI)]. *Klin Monbl Augenheilkd*, 230 (6): 570-574.
105. Wilson SE, Mohan RR, Hutcheon AE, Mohan RR, Ambrósio R, Zieske JD, Hong J, Lee J. (2003) Effect of ectopic epithelial tissue within the stroma on keratocyte apoptosis, mitosis, and myofibroblast transformation. *Exp Eye Res*, 76 (2): 193-201.

106. Singh V, Agrawal V, Santhiago MR, Wilson SE. (2012) Stromal fibroblast-bone marrow-derived cell interactions: implications for myofibroblast development in the cornea. *Exp Eye Res*, 98 (1): 1-8.
107. Mazzotta C, Caragiuli S, Caporossi A. (2014) Confocal microscopy in a case of crystalline keratopathy in a patient with smouldering multiple myeloma. *Int, Ophthalmol*. 34, 651–654.
108. Raizman MB, Hamrah P, Holland EJ, Kim T, Mah FS, Rapuano CJ, Ulrich RG. (2017) Drug-induced corneal epithelial changes. *Surv Ophthalmol*, 62 (3): 286-301.
109. Hollander DA, Aldave AJ. (2004) Drug-induced corneal complications. *Curr Opin Ophthalmol*, 15 (6): 541-548.
110. Skalicka P, Dudakova L, Palos M, Huna LJ, Evans CJ, Mahelkova G, Meliska M, Stopka T, Tuft S, Liskova P. (2019) Paraproteinemic keratopathy associated with monoclonal gammopathy of undetermined significance (MGUS): clinical findings in twelve patients including recurrence after keratoplasty. *Acta Ophthalmol*97(7):e987-e992.

## 8. Bibliography of the candidate's publications

### Thesis related publications

1. **Kormányos K**, Kovács K, Németh O, Tóth G, Sándor GL, Csorba A, Czakó CN, Langenbacher A, Nagy ZZ, Varga G, Gopcsa L, Mikala G, Szentmáry N. (2021) Ocular signs and ocular comorbidities in monoclonal gammopathy: Analysis of 80 subjects. J Ophthalmol. 9982875. **IF: 1.909**
2. **Kormányos K**, Kovács K, Németh O, Tóth G, Sándor GL, Csorba A, Czakó CN, Langenbacher A, Nagy ZZ, Varga G, Gopcsa L, Mikala G, Szentmáry N. (2021) A monoklonális gammopathia szemészeti jelei és szövődményei: 42 beteg 84 szemének vizsgálata [Ocular signs and comorbidities in monoclonal gammopathy: Analysis of 84 eyes of 42 subjects]. Orv Hetil, 162 (38): 1533-1540. **IF: 0.540**
3. **Kormányos K**, Kovács K, Németh O, Tóth G, Sándor GL, Csorba A, Czakó CN, Módos L Jr, Langenbacher A, Nagy ZZ, Varga G, Gopcsa L, Mikala G, Szentmáry N. (2022) Corneal densitometry and confocal microscopy in monoclonal gammopathy – analysis of 65 subjects. Journal of Clin Med, 11(7): 1848. **IF: 4.242**
4. Garderet L, Al Hariri M, Wasielica-Poslednik J, Munder M, **Kormányos K**, Pena C, Gozzetti A, Zhou X, Waszczuk-Gajda A, Rosinol L, Mikala G, Krzystanski M, Lisch W, Vesole D, Szentmáry N, Jurczyszyn A. (2021) Monoclonal gammopathy of ocular significance (MGOS) - a short survey of corneal manifestations and treatment outcomes. Leuk Lymphoma, 1-7. **IF: 3.280**
5. Szentmáry N, **Kormányos K**, Kovács K, Németh O, Tóth G, Sándor GL, Csorba A, Czakó CN, Langenbacher A, Nagy ZZ, Varga G, Gopcsa L, Mikala G. (2021) Szemészeti tünetek és szemészeti társbetegségek monoklonális gammopathiával járó kórképekben. Hematológia Transzfuziológia, 54: 82-88.



## 9. Acknowledgements

First and foremost, I wish to express my deepest gratitude to my supervisor and teacher, **Prof. Dr. Nóra Szentmáry**, for her years of continuous support and immense patience throughout this research. I would like to thank for the magnificent possibilities she has provided me to get this study done. She inspired and believed in me from the beginning. Without her guidance, enthusiastic encouragement, patience and motivation this Ph.D study would not have been possible.

I would like to extend my gratitude to **Dr. Gábor Mikala, Dr. Gergely Varga and Dr. László Gopcsa** for their professional help and support and for referring their patients to us, which made the study possible.

I am very grateful to **Prof. Dr. Achim Langenbacher** for the comprehensive statistical analysis of our huge database.

I owe my gratitude to **Prof. Dr. Zoltán Zsolt Nagy**, who supported me by enabling my research work at the Department of Ophthalmology of Semmelweis University and allowed me as Ophthalmology Program Co-ordinator, to study at Károly Rácz Clinical Medicine Doctoral School.

I am thankful for the support of all colleagues at the Department of Ophthalmology of Semmelweis University, for their support during my work.

My special thanks are extended to my former colleagues at the Military Hospital for their support and assistance at work.

I would like to thank to all the patients in the study who remained enthusiastic and participated in the study despite the pandemic. Without them, this study would not have been completed.

Last, but not least, I would like to express my gratitude to my fiancé and family, for the sincere encouragement and endless patience and love throughout the past years.