

**NEW PERSPECTIVES IN ALVEOLAR RIDGE
SPLITTING, GUIDED IMPLANT PLACEMENT AND
CUSTOM-MADE REMOVABLE APPLIANCE FOR
THE DECOMPRESSION OF ODONTOGENIC CYSTS**

PhD thesis

dr. Pénzes Dorottya

Károly Rácz Clinical Medicine Doctoral School

Semmelweis University



Supervisor:

Márton Kivovics DMD, Ph.D

Official reviewers:

László Simonffy, MD, DMD, Ph.D

Kristóf Boa, MD, Ph.D

Head of the Complex Examination Committee:

Gábor Gerber, DMD, Ph.D, med.habil

Members of the Complex Examination Committee:

Sándor Bogdán, MD, DMD, Ph.D,

Ákos Károly Nagy, DMD, Ph.D, med.habil

Budapest

2023

Table of contents

Table of contents	1
List of abbreviations	4
1 Introduction	5
1.1 The alveolar process	5
1.1.1 Characteristics of the alveolar process	5
1.1.2 Changes in alveolar process dimensions following tooth extraction	5
1.2 Rehabilitation of atrophic edentulous mandible with different types of graft materials.....	6
1.2.1 Augmentation strategies	7
1.3 Computer-assisted implant surgery (CAIS).....	8
1.4 Odontogenic cysts.....	11
2 Objectives.....	13
2.1 Objectives of Study I.	13
2.2 Objectives of Study II.	13
2.3 Objectives of Study III.....	14
3 Methods.....	15
3.1 Study I.....	15
3.1.1 Patient selection.....	15
3.1.2 Surgical procedure, bone biopsy harvesting.....	15
3.1.3 Clinical Measurement.....	17
3.2 Study II.	18
3.2.1 Patient selection.....	18
3.2.2 Preoperative and Postoperative Imaging.....	19
3.2.3 Preoperative planning and surgical procedure.....	19
3.2.4 Measurements, data selection.....	21

3.2.5	Statistical Analysis	22
3.3	Study III.	22
3.3.1	Patient selection.....	22
3.3.2	Planning and Fabrication of the Decompression Device.....	23
3.3.3	Surgical procedure.....	24
3.3.4	Data acquisition, statistical analyses	25
4	Results.....	26
4.1	Study I.....	26
4.1.1	Results of the Clinical measurements.....	27
4.2	Study II.	32
4.2.1	The Influence of Surgical Experience on the Accuracy of CAIS.....	32
4.2.2	The Influence of Bone Density on the Accuracy of CAIS	34
4.3	Study III.	34
5	Discussion	37
6	Conclusion.....	45
6.1	Study I.....	45
6.2	Study II.	45
6.3	Study III.	45
6.4	New results	46
6.4.1	Study I.	46
6.4.2	Study II.	46
6.4.3	Study III.....	46
7	Summary	47
8	References	48
9	Bibliography of the candidate's publications.....	58
9.1	Related Publications	58

9.1.1	Study I	58
9.1.2	Study II	58
9.1.3	Study III.....	58
9.2	Non-related Publications.....	59
10	Acknowledgements	60
10.1	Study I.....	60
10.2	Study II	60

List of abbreviations

AR - augmented reality

BV/TV - bone volume fraction

CAD/CAM - Computer-Aided Design and Computer-Aided Manufacturing

CAIS - computer-assisted implant surgery

CBCT - cone-beam computed tomography

dCAIS - dynamic computer-assisted implant surgery

FG - full guided

FOV – field of view

GBR - guided bone regeneration

HG – half guided

HU - Hounsfield Units

MSC - mesenchymal stem cells

mSUP – mucosa-supported

OC – odontogenic cyst

PG - pilot guided

sCAIS - static computer-assisted implant surgery

1 Introduction

1.1 The alveolar process

1.1.1 Characteristics of the alveolar process

The alveolar process is defined as the bone tissue that contains the sockets of the teeth in the jaw bones. The sockets are synonymous with alveoli. The alveolar process, also called the alveolar bone, surrounds and supports the teeth in the jaws. The alveolar process is a so called „tooth-dependent tissue” and it forms in conjunction with the eruption of the teeth. Alveolar bone formation, bone apposition or bone resorption is related to the eruption, movement, and loss of the teeth. The morphology of the alveolar process is determined by not only the site of tooth eruption, but also the number of the teeth, the size and the shape of the teeth and the position of the teeth (1) (2).

1.1.2 Changes in alveolar process dimensions following tooth extraction

After tooth extraction various dimensional changes may occur in the alveolar process. The jaws undergo a marked contraction in both vertical and horizontal directions. It is well established that tooth extraction is followed by a reduction of both the height and the width dimensions of the alveolar ridge at the edentulous site. Most changes occur during the first 30 days (3). Additional continuous atrophy is detected in the ridge over a long period (3). According to Schropp et al. the most significant reduction in the residual alveolar ridge, (up to 50% in width) may occur during the first year of healing (4).

Not only time is the determining factor in the alveolar atrophy. Different parts of the jaws show different amount and direction of bone reduction. There are notable differences observed in the rate and the degree of atrophy between the maxilla and the mandible. The mandible shows a higher degree of bone loss, compared to the maxilla. Tallgren et al. found that resorption areas measured in the cross section of the anterior region of lower jaw in the first 13 years was $58.59 \pm 36.89 \text{ mm}^2$ compared to $27.84 \pm 12.74 \text{ mm}^2$ in the upper jaw (5). The amount of the bone reduction significantly varies also in the anterior and in the posterior segments of the jaws (6). The ridge reduction is larger in the molar region (7). In the mandible initially after tooth extraction, the direction of the bone loss is mainly horizontal, while vertical resorption is more significant at a later stage (8).

1.2 Rehabilitation of atrophic edentulous mandible with different types of graft materials

There have been numerous graft materials and techniques described for augmenting the atrophic jaws. The graft materials could be classified by their contribution to osteogenesis into osteoconductive, osteoinductive, and osteogenic categories (9).

Osteoconduction means that bone grows on a specific surface, while a scaffold provides mechanical support. An osteoconductive material is one that permits bone cell growth on its surface. Every bone substitute material possesses osteoconductive properties (9).

Osteoinductivity means that mesenchymal stem cells (MSC) are stimulated to develop into preosteoblasts, to the bone-forming cell lineage (9). The stimulation is induced by growth factors. autogenous bone grafts, allografts, and some composite grafts, are characterized by potential osteoinductive properties (10).

Osteogenic properties of the biomaterials mean the facilitation of new bone formation process, by providing MSC, and osteoblast cells. In the dental surgical practice autogenous bone is characterized by osteoconduction, osteoinduction, and osteogenesis as well.

The graft materials could be classified also by their origin. The „gold standard” of bone augmentation materials is the autogenous bone graft. Autogenous bone combines osteoconductive, osteoinductive and osteogenic characteristics (11). The quality and the behavior of the bone graft depends on the donor site. The grafts vary from their embryology, histology, mechanical properties, and the harvestable amount. Furthermore, when choosing the donor site, the clinician must consider donor site morbidity or bone resorption rate as well (12).

A significant bone resorption at the recipient site has been identified as a disadvantage of bone harvested from extraoral donor regions (iliac crest, calvaria, distal femur or proximal tibia) (13-16). In most of the cases bone defects may be augmented using intraoral donor regions with limited available bone volume (17). Intraoral bone harvesting is a safe and predictable way to collect autogenous bone. Intraoral bone block commonly obtained from the mandibular symphysis, mandibular ramus, external oblique ridge, crista zygomaticoalveolaris, and the tuber maxillae (18, 19). The desmogenic bone harvested from intraoral donor regions has a lower rate of resorption during healing compared to the enchondral bone of extraoral donor regions (20).

In cases where bone augmentation of the premolar and molar region of the lower jaw is required prior to dental implant placement, the most easily accessible donor site is the mandibular ramus. In these cases, the donor site may be accessed from the same flap used to the recipient region and the clinician may expect less postoperative morbidity compared to using the mandibular symphysis as donor region. The bone block, harvested from the ramus mandible, contains both cortical and cancellous bone (19). According to the literature the mean volume of the bone block harvested from the retromolar region was $1.9 \pm 0.9 \text{ cm}^3$ (maximum 4.4 cm^3) (21). A cone-beam computed tomography (CBCT) scan examination showed the average length of harvestable bone in the retromolar region is approximately 15-34 mm, the width is 8 mm, and the height is 10 mm (22).

The disadvantage of the bone block harvested from intraoral donor regions may be the limited amount of bone available, and the associated postoperative morbidity, especially neurosensory disturbance, altered dental sensation, wound dehiscence and infections (23, 24).

For several augmentation strategies allograft, xenograft or synthetic graft materials could also be used.

1.2.1 Augmentation strategies

Unfavorable local morphology of the alveolar ridge due to atrophy, traumatic tooth extraction, local disease or trauma may result in insufficient vertical and/or horizontal bone dimensions for implant placement. In these cases, augmentation of the atrophic alveolar ridge is necessary prior to dental implant placement.

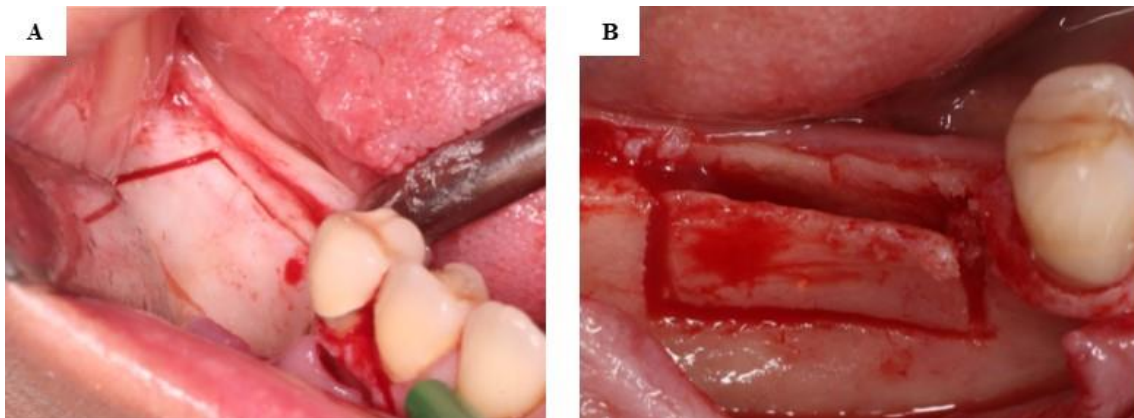
Numerous approaches for augmentation of the atrophic mandible is described in the literature, e.g. onlay grafting using bone blocks (25, 26), guided bone regeneration (GBR) (27), interpositional grafts (28) or alveolar ridge expansion.

1.2.1.1 Alveolar ridge expansion

Alveolar ridge splitting was first described by Tatum in 1984 (29). The aim of this surgical method is to create an intrabony defect in the alveolar ridge by creating a greenstick-fracture. The expanded defect created is suitable for the placement of graft materials or even the dental implants if the augmentation and implant placement is carried out simultaneously (30, 31).

1.2.1.2 *The surgical procedure of the ridge splitting technique*

At the edentulous site a full thickness flap elevation is performed after the crestal, and the vertical incisions were placed. When the bone surface is exposed, the osteotomies are carried out. Originally, osteotomies and corticotomies were performed using chisel and hammer. More recently rotating instruments, oscillating saws, and piezoelectric devices are applied (32-34). The first osteotomy is carried out at the center of the occlusal aspect of the ridge, extended in antero-posterior direction for the planned length. Two vertical osteotomies are performed on the proximal and distal ends of the crestal incision. Apically, the vertical osteotomies are connected horizontally with a superficial corticotomy. The buccal plate, demarcated with the osteotomies and corticotomies are expanded via a green-stick fracture to allow extensive mobilization of the buccal cortical. The created „box” is capable to accept graft materials or dental implants (Figure 1.).



*Figure 1. Clinical illustration of the buccal cortical wall mobilization to create the „box”.
The author's own work.*

1.3 *Computer-assisted implant surgery (CAIS)*

For the optimal function, ideal biomechanical loading of the implant supported prosthesis, and optimal esthetic results the amount of the hard tissues surrounding the implants are crucial. Moreover, the ideal positions of the implants placed is crucial. This, however, requires a prosthetically driven planning prior to implant placement and an accurate surgical procedure to enhance the longevity of the reconstruction (35). Poorly planned or poorly accomplished implant placement could be associated with increased marginal

bone loss and suboptimal morphology of the emergence profile, which may affect esthetic outcomes disadvantageously (36-38).

The introduction of CBCT in implant dentistry enables diagnostics of the dentomaxillofacial area in high resolution with low radiation dosage and supports implant planning in the optimal positions. The use of CBCT as an imaging modality had become widespread in dental surgeries (39).

In 1995, Fortin et al. described a new implant planning process, the so called computer-assisted implant surgery (CAIS) system (40). According to this study, the clinician could plan the ideal implant positions virtually using the CBCT as preoperative 3D imaging modality with the help of a designated implant planning software (Figure 2.). The number, dimensions, position, and inclination of dental implants placed should be determined with the virtual prosthetic plan.

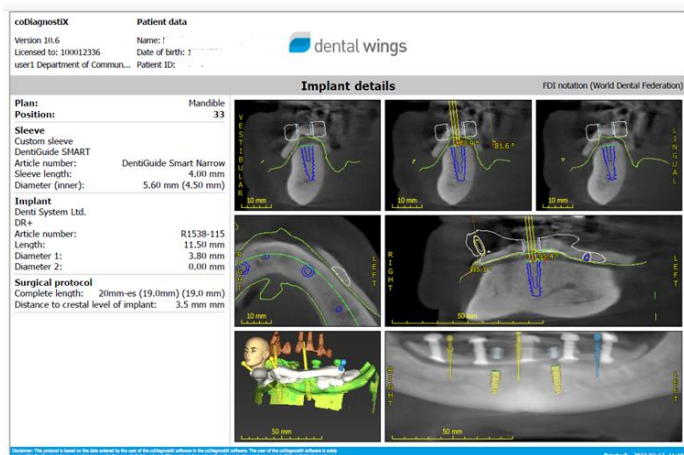


Figure 2. Virtual prosthetic plan of the dental implants. The author's own work.

Jung et al. differentiated two main methods of transferring the virtual surgical plan to the real surgical area: static and dynamic navigation (41). Static CAIS (sCAIS) is utilized to plan the drilling path of implant osteotomies and as a result, a so-called drill guide or surgical template is fabricated. Some of the CAIS systems employ sleeves to guide the drills of implant bed preparation and implant placement and to accommodate the sleeves. According to which steps of the implant placement are performed guided by the surgical template, three protocols of sCAIS are differentiated. In the pilot guided (PG) protocol, the template guides only the pilot drill, the finalization of the osteotomy and implant placement is completed free hand. In the half guided (HG) protocol a part of the drilling sequence is carried out through the template, whereas implant placement is implemented

free handed. Using the full guided (FG) protocol drilling, tapping, and the implant placement is accomplished through the surgical guide (42). Implant placement using sCAIS protocols, results in the decrease of postoperative pain, discomfort, and intraoperative complications, compared to conventional, free hand implant surgery (43). sCAIS significantly reduce the length of surgery, and ensures that the implant positions achieved are closer to the prosthetically ideal, planned implant positions compared to those achieved by free hand surgery (44) (45-48). FG surgery further decreases the length of intervention by guiding every step of implant placement and further decreases postoperative morbidity by promoting flapless surgery (46, 47, 49-51). In contrast, during HG surgery, the template is removed for the finalization of the implant bed and does not inhibit the cooling of the drills (52, 53). Furthermore, HG surgery provides the possibility of raising a flap which allows the surgeon to correct an implant position in case of inaccuracies and preserve the keratinized mucosa, which would be sacrificed by tissue punches in the case of a FG approach (47). These advantages of the HG approach are relevant in edentulous jaws where alveolar atrophy is combined with the narrowing of keratinized mucosa (44-47, 54).

The literature differentiates mucosa-, bone-, tooth- and implant-supported templates. According to the literature, tooth- or mucosa-supported (mSUP) templates are more accurate than bone-supported templates. Another, more accurate approach than mSUP templates that may be used in case of an edentulous jaw is an implant-supported template. However, this requires an additional surgical procedure to insert temporary implants, which increases patient discomfort and costs (45-47, 54).

Several in vitro studies investigated the role of the surgeon's experience (55-57). Based on the results of these studies this factor might affect the accuracy of static guided implant placement. According to the clinical studies, which analyzed the accuracy of implant placement with surgical templates executed by experienced or novice surgeons, the surgical experience had a limited influence on accuracy (58, 59). However, according to Marei et al. the level of the surgeon's experience may affect the accuracy of implant placement using a surgical guide (60). According to a systematic review, not only the experience of the surgeon is the main factor which affects the accuracy, but also the bone density, the mucosal thickness, the surgical techniques or the type of jaws are crucial (61).

Seo et al. concluded that further clinical studies are required in order to examine the role of the mentioned factors in the accuracy of sCAIS (61).

1.4 Odontogenic cysts

Management of cystic lesions in the maxillofacial region is a challenge for the clinician in the daily dental practice. Cysts are epithelial-lined pathologic cavities, surrounded by fibrous connective tissue, originating from odontogenic or non-odontogenic tissues. Cystic lesions are classified by the World Health Organization into odontogenic cysts (OC), non-odontogenic cysts, and pseudocysts (62). Unlike pseudocysts, true cysts are lined by epithelium. The OC represent the majority of cases in the maxillofacial region. Although OC are considered benign lesions, they may cause extensive bone destruction in the jaws. These bone defects may lead to pathological bone fracture. In addition, cysts may cause infection, resorption and displacement or finally loss of adjacent teeth (Figure 3.) among other complications (63).

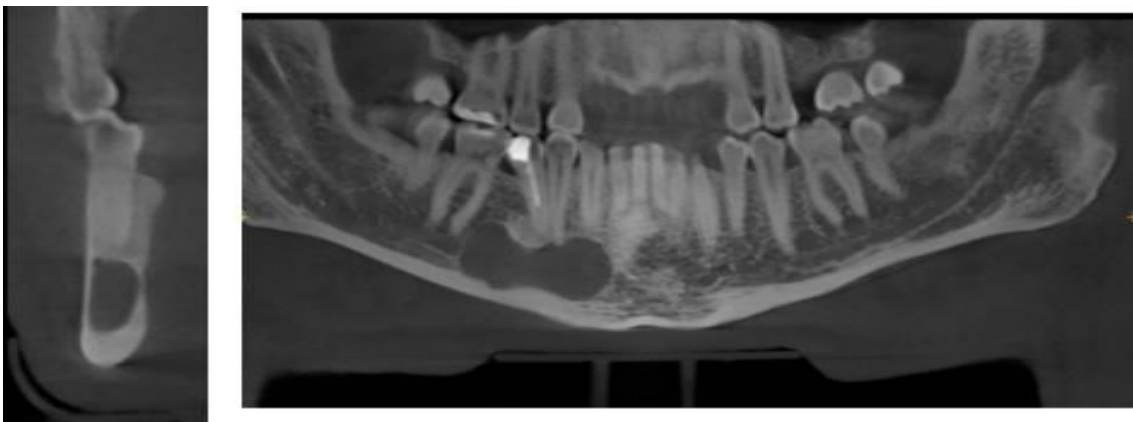

Figure 3. Radiological illustration of a cyst. The author's own work.

Cysts are managed with enucleation, decompression, or marsupialization procedures. The two main surgical options: cystectomy or cystostomy. During cystectomy, the whole cyst lining is removed, and spontaneous bone healing repairs the bone defect. Compared to cystectomy, the cystostomy is a less invasive treatment and may be carried out with complete or partial removal of the cyst lining. Decompression allows the outlet of the fluids secreted by the cyst lining decreasing the pressure within the cyst, allowing bone

regeneration. Using cystostomy and decompression or marsupialization the prevalence of complications to the anatomical landmarks (the maxillary sinus, the nasal cavity, nerves, blood vessels, and roots of neighboring teeth) may be decreased.

Various devices have been described in the literature for the decompression of OC. Marker et al. described a polyethylene tube modified by heat to produce a shape that allows retention in the soft tissues (64). Swantek et al. use a similar tube which is anchored to the bone with fixation screws (65, 66), or sutured to the adjacent soft tissues (67). Kolokythas et al. anchored the tube to neighboring teeth using a wire-ligature (68). Orthodontic brackets are also useful to attach the tube to the neighboring teeth. Castro-Núñez et al. apply negative pressure for the decompression (69). Urethral catheters, intravenous (IV) administration set, nasogastric tubes, a Luer syringes, dual nasal trumpet stents, or saline cuffs may all be modified for decompression methods (65, 70-74).

Removable appliances used for decompression have several advantages over these methods. A removable device allows the patient to clean and rinse the cavity of the cyst, and to properly clean the device. Nevertheless, removable devices allow substitution of the missing teeth. Higher costs, clinical skills required, and the need for the dental laboratory may be disadvantages of the fabrication of removable decompression devices. Using the traditional, analogue workflow, several visits are necessary to manufacture the appliance. Between the visits packing of the surgical entry wound is necessary, which may cause additional discomfort to the patient.

Advances in the field of digital dentistry include registration of the reconstruction of three-dimensional imaging modalities and digital impressions originally for the purpose of virtual implant planning, designing removable prostheses in the virtual space, and rapid prototyping of removable dentures. These procedures enable the clinician to fabricate a removable decompression device using a digital workflow (Figure 4.).

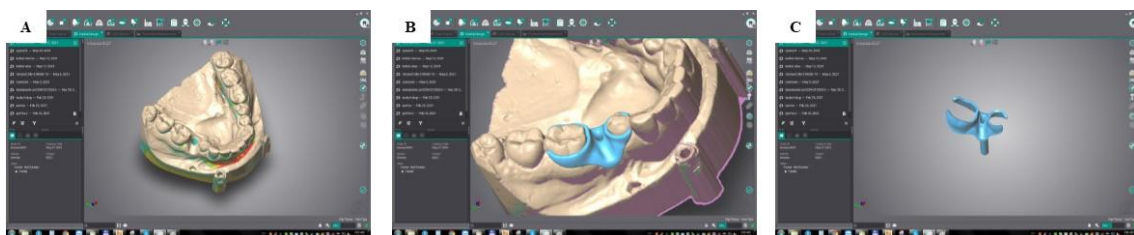


Figure 4. Fabrication of the custom-made removable appliance using digital workflow. The author's own work.

2 Objectives

The research summarized in this PhD dissertation deals with bone augmentation of knife edge ridges. This treatment modality play an important role in oral rehabilitation with dental implants. Ridge expansion enables the clinician to re-establish sufficient width of alveolar bone for dental implant placement. Guided implant placement assists the surgeon in placing implants in prosthetically correct position, while improving patient reported outcomes. However, several factors influence the implant positioning accuracy that may be achieved by sCAIS. The other aim of this PhD dissertaion is to describe a novel method for marsupialization of OC with digital workflow.

2.1 Objectives of Study I.

A Modified Ridge Splitting Technique Using Autogenous Bone Blocks - A Case Series

1. The aim of these prospective case series was to present a modified treatment approach to ridge expansion using only autogenous bone blocks.
2. The secondary purpose of this study was to report clinical outcomes (ridge width gain) using the modified approach presented.

2.2 Objectives of Study II.

The Influence of Surgical Experience and Bone Density on the Accuracy of Static Computer-Assisted Implant Surgery in Edentulous Jaws Using a Mucosa-Supported Surgical Template with a Half-Guided Implant Placement Protocol - A Randomized Clinical Study

In this randomized clinical study PG sCAIS was performed using a mSUP, pin-anchored template in edentulous jaws.

1. The aim of our study was to evaluate the influence of experience on implant placement accuracy.
2. The secondary purpose of our study was to evaluate the influence of bone density at the surgical sites on the accuracy of dental implant placement.

2.3 *Objectives of Study III.*

A custom-made removable appliance for the decompression of odontogenic cysts fabricated using a digital workflow

The aim of this case series was to present clinical results with cystostomy, decompression and final enucleation of OC using a decompression device fabricated with a digital workflow and delivered on the day of cystostomy. The secondary aim of our study was to examine the volumetric changes of the OC treated by the approach presented.

- 1) The aim of this study was to assess the feasibility of a custom-made removable appliance for the decompression of odontogenic cysts fabricated using a digital workflow.
- 2) The secondary purpose of our study was to evaluate the amount of OC volume reduction that may be achieved using the appliance.

3 *Methods*

3.1 *Study I.*

3.1.1 *Patient selection*

Patients of the Department of Community Dentistry, Semmelweis University, who needed implant borne prostheses for their oral rehabilitation were included in the study. Periodontally healthy patients with Kennedy Class I. and II. mandible with insufficient bone width for implant placement, who were more than 18 years of age were included in our study. Anatomical inclusion criteria were

- mandibular ridge width of at least 3 mm,
- ridge height of at least 11 mm,
- spongiosa between the two cortical plates at least 1 mm in width. (75)

Exclusion criteria were uncontrolled medical disorders, history of systemic diseases or medication that alter bone metabolism, poor oral hygiene, pregnancy, and smoking.

The study was approved by the Regional and Institutional Committee of Science and Research Ethics (52158-2/2015/EKU [0425/15]) and The Office of the Chief Medical Officer of The National Public Health and Medical Officer Service (IF-14561-10/2015). All investigations reported have been carried out in accordance with the Helsinki Declaration (76). Surgical interventions and methods were thoroughly explained to the patients enrolled; patients signed the necessary consent forms prior to treatment.

3.1.2 *Surgical procedure, bone biopsy harvesting*

All patients rinsed with a 0.2% chlorhexidine solution for 1 min before surgery. Under local anesthesia, after full-thickness flap preparation a midcrestal osteotomy was performed (Figure 5.A). At the mesial and distal ends of the mid-crestal osteotomy the osteotomy was expanded with two vertical releasing osteotomies. Furthermore, at the apical site the vertical osteotomies were connected horizontally with a superficial corticotomy. We applied a piezoelectronic device (NSK Variosurg3 Ultrasonic Bone Surgery System, NSK Europe GmbH, Eschborn, Germany) for preparation of the osteotomies and corticotomies. These osteotomies enabled green-stick fracture of the buccal cortical. With this mobilization of the buccal cortical, we developed the recipient site for the bone block between the buccal and lingual cortical plates. The autogenous

bone was harvested from the retromolar area from the same flap used to access the recipient site. The bone block was immobilized using osteosynthesis screws (Meisinger Screw System, Hager and Meisinger GmbH, Neuss, Germany) (Figure 5.B). Both lingual and buccal flaps were mobilized to allow tension-free primary closure. The flap was closed in two layers with horizontal mattress sutures, and single interrupted sutures on the edges of the flaps. Suture removal took place after 14 days. Antibiotics (amoxicillin and clavulanate) two times a day for 5 days (Aktil Duo 875 mg/125 mg, Sandoz Hungária Kft., Budapest, Hungary), in case of amoxicillin allergy, clindamycin 4 times a day for 4 days (Dalacin 300 mg, Pfizer Inc., New York, NY, USA), a non-steroid anti-inflammatory drug, diclofenac 3 times a day for 3 days (Cataflam 50 mg, Novartis Hungária Kft., Budapest, Hungary), and 0.2% chlorhexidine mouth rinse, two times a day (Corsodyl, GlaxoSmithKline Consumer Healthcare GmbH & Co. KG, München, Germany) were prescribed to the patients. During the healing period, patients did not wear temporary prostheses.

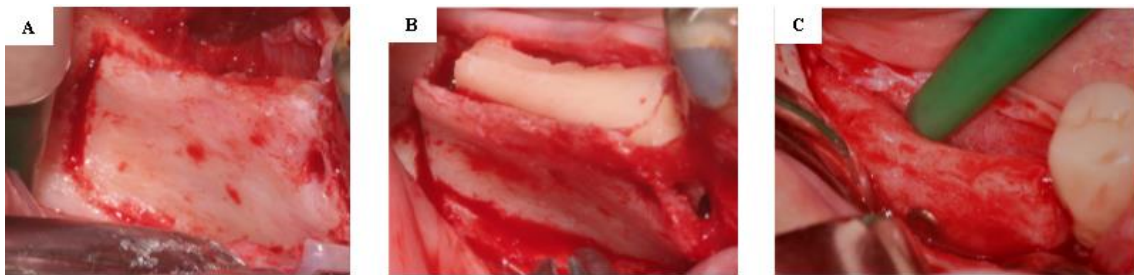

Figure 5. Clinical illustration of the surgical procedure of the modified ridge splitting. (A) Preoperative view of the atrophied alveolar ridge. (B) Coronal view of the augmented alveolar ridge. (C) Coronal view of the alveolar ridge after the 3-month healing time. The author's own work.

After 3 months of healing (Figure 5.C) dental implants were inserted under local anesthesia from a full thickness flap. Bone core biopsy samples were harvested with rotatory instruments powered by a surgical micromotor (MasterSurg Surgical Systems, KaVo Dental Systems Japan, Co., Ltd., Tokyo, Japan). A trephine drill (external diameter of 3.0 mm and an internal diameter of 2.0 mm (330 205 486 001 020 Hager and Meisinger GmbH, Neuss, Germany) with external cooling at a drill rotation speed of 800 rpm to the depth of 8 mm was used for the purpose of bone core biopsy (Figure 6).

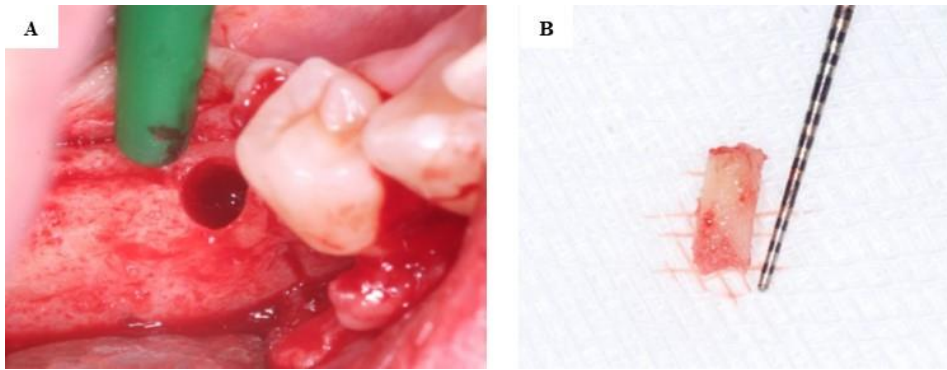


Figure 6. Harvesting of the bone core biopsy sample. The author's own work.

Implant beds were finalized according to the instructions of the implant manufacturer. Dental implants (Nobel Replace Conical Connection, Nobel Biocare AG, Kloten, Switzerland) were placed submerged in the augmented bone (Figure 7.). Implant uncovering procedure took place 3 months after implant placement. All surgical interventions were carried out by the same surgeon (DP).

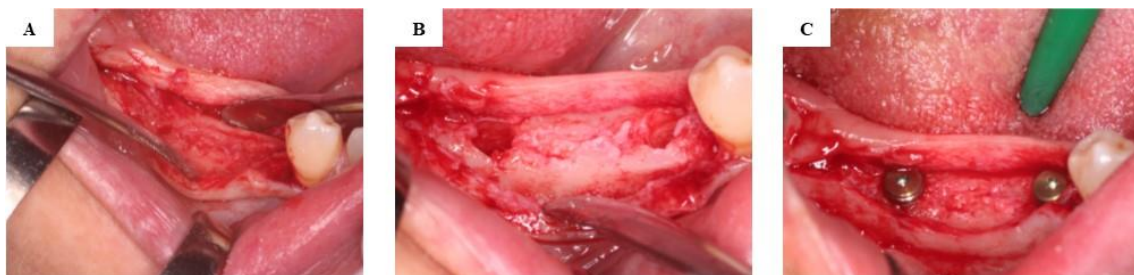


Figure 7. Clinical illustration of the surgical site after 3 months of healing. (A) Preoperative view of the augmented alveolar ridge. (B) Prepared implant beds. (C) Submerged placed dental implants. The author's own work.

3.1.3 Clinical Measurement

The first clinical measurement took place during the first surgery, prior the augmentation after the full thickness flap preparation. The second examination was at reentry, after the 3-month healing period, prior to implant placement. The clinical measurements were carried out using a Williams probe (Karl Hammacher GmbH, Solingen, Germany). The width of the alveolar ridges was measured at different distances from the reference point, which was the distal marginal bone of the last tooth of the quadrant. To ensure that preoperative and postoperative measurement sites corresponded, we placed the tip of the

Williams probe on the reference point described to assess the measurements point at 3, 10, 15 mm. The markings of the probe lied at the highest ridge of the lingual cortical.

3.2 *Study II.*

3.2.1 *Patient selection*

Patients of the Department of Community Dentistry, Semmelweis University, presenting an edentulous lower and/or upper jaw, who needed implant supported prostheses for their oral rehabilitation were included in the study. Patients, who were more than 18 years of age were included in our study.

Anatomical inclusion criteria were

- clinically and radiologically healthy alveolar ridges,
- a horizontal dimension of at least 7 mm,
- vertical dimension of at least 10 mm from the vital anatomical landmarks.

Exclusion criteria were uncontrolled medical disorders, history of systemic diseases or medication that alter bone metabolism, history of tumors or irradiation therapy in the head and neck region, poor oral hygiene, pregnancy, smoking and the unwillingness to return for follow-up appointments.

The study was approved by the Semmelweis University's Regional, Institutional Scientific and Research Ethics Committee (109/2020). All investigations reported have been carried out in accordance with the Helsinki Declaration (76). Surgical interventions and methods were thoroughly explained to the patients enrolled; patients signed the necessary consent forms prior to treatment.

Simple randomization was carried out to determine whether patients would be included in the test or control group. For this randomization the random number generator function of Excel (Microsoft, Redmond, WA, USA) was used. Three novice surgeons took part in the test group. Novice surgeon was defined as someone, who had completed theoretical training in implant dentistry, had placed less than 20 dental implants and had carried out only free-hand implant placements previous to the study. two experienced surgeons were recruited for the interventions in the control group, who had placed more than 100 implants in the year before the study. They had practice in autonomously performing both conventional and guided implant placement.

Primary outcome variables used to determine the accuracy of implant placement were angular deviation, coronal global deviation and apical global deviation. The level of surgical experience, grey level measurements in Hounsfield Units (HU) and bone volume fraction (BV/TV), the relative volume of calcified tissue in the selected volume of interest were detected as the independent variables.

3.2.2 Preoperative and Postoperative Imaging

Three optical scans of the study cast were captured: one scan from the original study cast to record the soft tissues; and another scan was carried out using five gutta-percha markers (Diadent Group International, Chungcheongbuk-do, Korea) fixed on the alveolar ridge of the study cast (gutta-percha cast) to determine the position of the cast compared to the CBCT scanning. The third optical scan was carried out with the diagnostic wax-up placed on the original study cast. Dental laboratory desktop scanner (3Series, Dental Wings, Montreal, CA, USA) was used for the optical scanning, to create the three Standard Tessellation Language (STL) files. Those files were later applied for planning the surgical guide.

To register the centric occlusion position of the jaws during the CBCT scanning a bite registration was fabricated with the gutta-percha markers incorporated in wax and an acrylic base according to the gutta-percha cast. CBCT imaging (PaX-Reve3D, Vatech, Hwaseong, Korea) was carried out preoperative in the planning stage with the bite registration in place (preoperative CBCT). 6 months after dental implant placement postoperative CBCT was carried out. The scanning conditions were constant at 250 mikrometer isotropic voxel size with 360° rotation, 89 kV tube voltage, 4.9 mA tube current and 24 s exposure time for all specimens with a 15 * 15 cm field of view (FOV).

3.2.3 Preoperative planning and surgical procedure

Implant-borne overdentures anchored and supported by 2–4 implants, and fixed prostheses supported by 4–6 implants were planned on the edentulous jaws in the present study.

All surgical plans were designed by the same surgeon. This surgeon supervised all surgical procedures. Surgical planning was carried out using coDiagnostiX software, version 10.2 (Dental Wings, Montreal, CA, USA). The STL file of the study cast with and without the gutta-percha markers in place, and the study cast with the diagnostic wax-

up was registered with the Digital Imaging and Communications in Medicine (DICOM) data of the preoperative CBCT reconstruction.

PG implant placement was planned using surgical guides manufactured by stereolithography.

All patients rinsed with a 0.2% chlorhexidine solution for 1 min before surgery. Under local anesthesia the surgical guide was fixed using template fixation pins (Straumann Template Fixation Pin, Article number 034.282, Straumann GMBH, Basel, Switzerland). Pilot osteotomies were performed using a pilot drill 2 mm in diameter (Article number HN011, Hager & Meisinger GmbH, Neuss, Germany). After removing the fixation pins and the surgical guide, a full-thickness flap was elevated. Implant osteotomies were finalized with external cooling at a drill rotation speed of 800 rpm according to the implant manufacturer's instructions. Dental implants (Denti Root Form Plus, Denti-Systems Ltd., Szentes, Hungary) were placed non-submerged. Single interrupted sutures were used to stabilize the wound margins (Figure 8.).

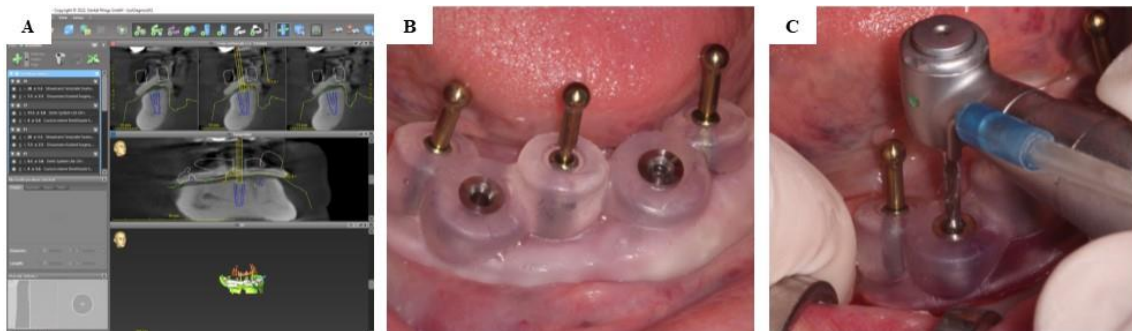


Figure 8. Implant insertion using mSUP template designed with coDiagnostiX software. The author's own work.

Suture removal took place after 7 days. Antibiotics (amoxicillin and clavulanate) two times a day for 5 days (Aktil Duo 875 mg/125 mg, Sandoz Hungária Kft., Budapest, Hungary), in case of amoxicillin allergy, clindamycin 4 times a day for 4 days (Dalacin 300 mg, Pfizer Inc., New York, NY, USA), a non-steroid anti-inflammatory drug, diclofenac 3 times a day for 3 days (Cataflam 50 mg, Novartis Hungária Kft., Budapest, Hungary), and 0.2% chlorhexidine mouth rinse, two times a day (Corsodyl, GlaxoSmithKline Consumer Healthcare GmbH & Co. KG, München, Germany) were

prescribed to the patients. During the healing period, patients wore temporary prostheses, which were modified to accommodate the healing abutments.

3.2.4 Measurements, data selection

Using the DICOM data of the pre- and postoperative CBCT reconstructions, CoDiagnostiX software, version 10.2 (Dental Wings, Montreal, CA, USA) was used to measure the angular deviation, coronal global deviation and apical global deviation for all inserted implants (Figure 9.). This primary outcome variables were calculated using the treatment evaluation plug-in of the software by an investigator blinded to the grouping factor.

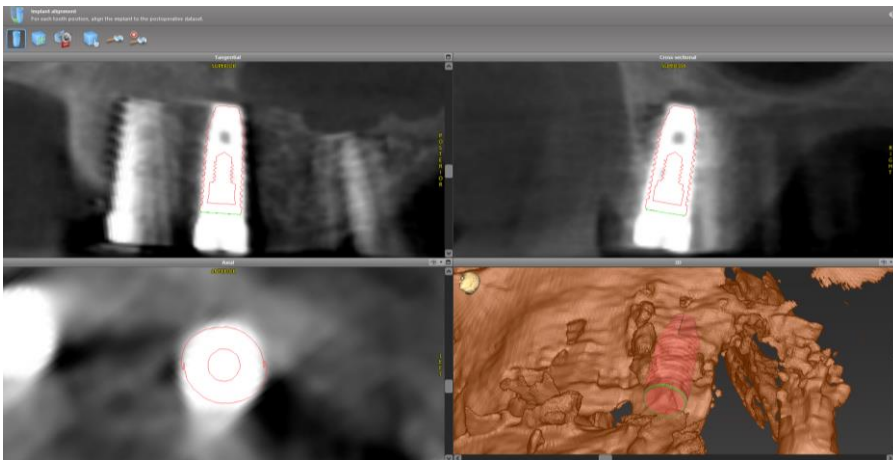


Figure 9. Data acquisition. Calculation of angular deviation, coronal global deviation, and apical global deviation using the treatment evaluation plug-in of the software. The author's own work.

Grey level measurements at implant recipient sites in HU and assessment of the width and height of the alveolar ridge measurements were performed using the coDiagnostiX software. Also the were. The width of the ridge was measured at the platform level of the implants planned. The ridge height was measured from the closest anatomical landmark to the center of the implant platform along the axis of the planned implant position.

3DSlicer 4.10.2 software (The Brigham and Women's Hospital, Inc., Boston, MA, USA) was used to register pre- and postoperative volume datasets and positions of implant placement was determined on the preoperative CBCT reconstructions. Using the BoneTexture Extension of 3DSlicer 4.10.2 BV/TV for each implant recipient site was calculated.

3.2.5 *Statistical Analysis*

To determine whether the angular deviation, coronal global deviation and apical global deviation of the dental implants placed by novice and experienced surgeons were distributed approximately normally a Shapiro–Wilk’s test ($p < 0.05$) and visual inspection of the histograms, normal Q–Q plots and box plots were carried out. The coronal and apical global deviation values showed a normal distribution. The angular deviation values for both experience levels did not show a normal distribution. One-way ANOVA test was carried out to compare the coronal and apical global deviation of implants placed by experienced and novice surgeons and Mann–Whitney’s U test was carried out to compare the angular deviation data of implants placed by the two groups. Spearman’s test (two-tailed) was carried out to correlate the angular deviation and coronal and apical global deviation data to the BV/TV and grey level data.

Values of $p < 0.05$ were considered statistically significant.

3.3 *Study III.*

3.3.1 *Patient selection*

Patients of the Department of Community Dentistry, Semmelweis University, who presenting with a lesion that was initially diagnosed as an odontogenic cyst of the jaw through routine radiologic and clinical examination were included in the study. Anatomical inclusion criteria was, that the cyst involved anatomical landmarks according to preoperative CBCT. Initial diagnosis was confirmed by histopathological examination postoperatively.

Exclusion criteria were:

- Patients under the age of 5 years.
- History of tumors or irradiation therapy in the head and neck region.
- History of uncontrolled medical or psychiatric disorders.
- Unwillingness to return for follow-up appointments.
- Insufficient dentition for the attachment of a removable decompression.

The study was approved by Semmelweis University’s Regional Research Ethics Committee (109/2020). All investigations reported have been carried out in accordance with the Helsinki Declaration (76). The clinical trial was registered at ClinicalTrials.gov Protocol Registration and Results System (PRS) (Clinical trial registration number:

NCT05253261). Surgical interventions and methods were thoroughly explained to the patients enrolled; patients signed the necessary consent forms prior to treatment.

3.3.2 *Planning and Fabrication of the Decompression Device*

Two-stage impression of the dentition was obtained using silicone impression material (Elite HD+ Monophase, Elite HD+ Putty Soft, Zhermack, Badia Polesine, Italy) resulted in a dental cast. After the digitalization of this dental cast, the teeth with a hopeless prognosis were removed from the cast using burs. The casts were digitized using a dental laboratory desktop scanner (3Series, Dental Wings, Montreal, CA, USA) resulted in two STL files.

Before cystostomies CBCT scans (Green X, Vatech, Hwaseong, Korea) were performed. The scanning conditions were constant at 200 μm isotropic voxel size with 360° rotation, 94 kV tube voltage, 7.2 mA tube current, and 9 s exposure time with a field of view of 15 \times 8 cm. Postoperative CBCT was performed using the same scanning conditions as those used for the pre-operative CBCT.

The master cast STL file, DICOM data of the pre-operative CBCT reconstruction, and the scan of the expected intraoperative dentition were registered in the coDiagnostiX software version 10.4 (Dental Wings, Montreal, CA, USA) by a clinician. A custom-designed dental implant with a 5.0 mm diameter and length suitable for cyst volume was planned to represent the tube to be used for decompression. This plan was exported using the Virtual Planning Export option of the coDiagnostiX version 10.4 software in STL format.

Based on this plan, the decompression appliance was planned by a laboratory technician using Dental Wings DWOS software (Dental Wings, Montreal, CA, USA). Rapid prototyping (3D printing) of the appliances was carried out using RapidShape S30 hardware (RapidShape GmbH, Heimsheim, Germany) from SHERAprint-ortho material (SHERA Werkstoff-Technologie GmbH, Lemförde, Germany). The tube of the decompression device was perforated using round burs. In cases where the appliances substituted teeth, acrylic denture teeth (VITAPAN, VITA Zahnfabrik H. Rauter GmbH & Co. K, Bad Säckingen, Germany) were added using the conventional workflow of chemical curing (Figure 10.).

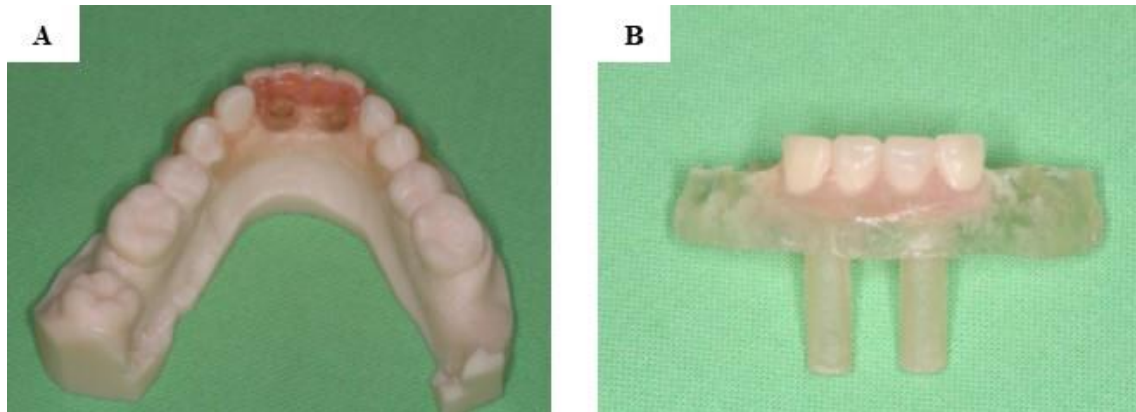


Figure 10. Removable decompression appliance. The author's own work.

3.3.3 Surgical procedure

All patients rinsed with a 0.2% chlorhexidine solution for 1 min before surgery. Under local anesthesia, after full-thickness flap preparation the teeth deemed for extraction were removed atraumatically. Osteotomies were performed using round burs with a surgical handpiece (SURGmatic S11 L Pro, Kavo Dental, Brea, California, United States) and motor (MASTERsur LUX, Kavo Dental, Brea, California, United States) to create a bony window to the cyst, in cases where the cyst could not be accessed from the sockets of the removed teeth. From the cyst lining histological samples were collected. Wound margins were stabilized using single interrupted sutures. A decompression appliance was delivered immediately after the cystostomy (Figure 11.). The tissue sample harvested from the cystic lining was submitted to histopathological examination to confirm the initial diagnosis.

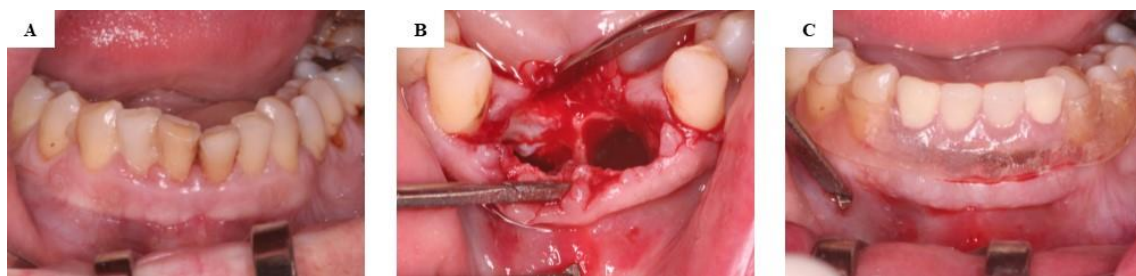


Figure 11. Clinical illustration of the surgical procedure. (A) photo of the initial clinical case (B) surgical procedure (C) removable decompression appliance. The author's own work.

Suture removal took place after 7 days. Antibiotics (amoxicillin and clavulanate) two times a day for 5 days (Aktil Duo 875 mg/125 mg, Sandoz Hungária Kft., Budapest,

Hungary), in case of amoxicillin allergy, clindamycin 4 times a day for 4 days (Dalacin 300 mg, Pfizer Inc., New York, NY, USA), a non-steroid anti-inflammatory drug, diclofenac 3 times a day for 3 days (Cataflam 50 mg, Novartis Hungária Kft., Budapest, Hungary), and 0.2% chlorhexidine mouth rinse, two times a day (Corsodyl, GlaxoSmithKline Consumer Healthcare GmbH & Co. KG, München, Germany) were prescribed to the patients.

During the decompression period, patients wore the appliance to keep the orifice of the cyst open. Patients were instructed to clean the appliance twice a day. Patients were recalled for controls monthly. During the decompression period, the tube was gradually shortened to allow for bone regeneration.

Following the decompression period, when the cyst volume was sufficiently reduced, the remaining cyst was enucleated under local anesthesia. The residual tissue of the cyst was submitted to histopathological examination.

3.3.4 Data acquisition, statistical analyses

To determine the effectiveness of the decompression device the volume reduction of the cyst was examined. Volume reduction was calculated by subtracting the post-operative volume from the pre-operative volume. The percentage of volume reduction was calculated as follows: $\text{volume reduction} / \text{pre-operative volume} \times 100$.

The volume of the odontogenic cysts were assessed by manual segmentation. The segment editor and segment statistics plug-in of the 3DSlicer 4.10.2 (The Brigham and Women's Hospital, Inc., Boston, MA, USA) software was used to determine the volume of the cyst using slice-by-slice boundary drawing with a scissors tool. Annotations were inspected slice-by-slice in all three orthogonal views to determine the volume of the cyst.

Shapiro–Wilk's test ($p < 0.05$) and visual inspection of the histograms, normal Q–Q plots and box plots were carried out to determine whether pre-operative volume, postoperative volume, and percentage of volume reduction were distributed approximately normally. Levene's test was carried out to examine the homogeneity of the data, paired samples t-test was carried out to compare the pre- and post-operative cyst volume.

Values of $p < 0.05$ were considered as statistically significant.

4 Results

4.1 Study I.

Altogether, 11 patients were treated using the modified alveolar ridge expansion technique described in study I. One patient was excluded from the participation of our study, because he did not attend on regular recalls. As a result, 10 (2 male, 8 female, age $54,90 \pm 11,60$ years) patients a total of 11 ridge split procedures were included. A total of 21 dental implants were inserted in the augmented sites.

The patients were recalled every 6 months for a clinical and radiological examination. All patients were followed up until September 2022. During the follow-up period one dental implant was lost due to periimplantitis. Patients' demography is summarized in Table 1.

Table 1. Patients' demography and the characteristics of the inserted implants (M - male, F- female)

Patients	Age (years)	Male (M/F)	Augmented site of the mandible	Position of the inserted dental implant	Inserted dental implant (diameter*length) (mm)
<i>Patient 1</i>	56	M	both sides	36	3.5*10
				37	4.3*10
				44	3.5*10
				46	3.5*8
<i>Patient 2</i>	77	F	right	45	3.5*10
				46	3.5*10
<i>Patient 3</i>	44	F	right	45	3.5*10
				46	4.3*10
<i>Patient 4</i>	57	F	left	36	4.3*8
<i>Patient 5</i>	70	F	right	45	3.5*8
				46	3.5*8
<i>Patient 6</i>	42	F	right	44	4.3*11.5
				46	4.3*11.5
<i>Patient 7</i>	51	F	right	45	3.5*11.5
				46	4.3*10
<i>Patient 8</i>	49	M	left	35	3.5*11.5
				37	4.3*10
<i>Patient 9</i>	63	F	right	45	3.5*10
				46	3.5*11.5
<i>Patient 10</i>	40	F	right	46	3.5*10
				47	3.5*10

All sites healed uneventfully. The borders of the bone blocks were observed, and satisfactory ossification of the osteotomies were found. Clinically the coronal part of the augmented area consisted of cortical bone. Upon reentry, excellent bone integration was observed in all cases, except for one case, where a secondary bone augmentation was needed.

At the time of the implant bed preparation, the density and the volume of all augmented site was adequate. The bone quality and quantity permitted the placement of dental implants prosthetically driven in all cases.

4.1.1 Results of the Clinical measurements

Hard tissue dimension changes were calculated with subtraction: preoperative values were subtracted from postoperative values. The horizontal hard tissue dimension changes were observed 3, 10 and 15 mm distally from the reference point. At 3 mm and 15 mm the values of the clinical measurements showed an approximately normal distribution. However at 10 mm the normal distribution of the clinical measurements was not

observed. According to the measurements ridge width gain was 2.09 ± 1.38 mm at 3 mm, 2.73 ± 1.56 mm observed at 15 mm respectively. The a ridge width gain was 3.00 mm (2.00 – 5.00 mm range) at 10 mm.

Pre- and postoperative dimensions and dimension changes are presented in Table 2.

Table 2. Pre- and postoperative measurements of the alveolar ridges

Patients	Preoperative alveolar ridge width (mm)			Augmented alveolar ridge width (mm)			Alveolar ridge width gain (mm)		
	at 3 mm	at 10 mm	at 15 mm	at 3 mm	at 10 mm	at 15 mm	at 3 mm	at 10 mm	at 15 mm
<i>Patient 1 (left side)</i>	5	4	5	5	8	6	0	4	1
<i>Patient 1 (right side)</i>	5	3	4	6	5	5	1	2	1
<i>Patient 2</i>	7	4	5	9	9	9	2	5	4
<i>Patient 3</i>	5	5	7	6	8	9	1	3	2
<i>Patient 4</i>	4	7	6	8	9	7	4	2	1
<i>Patient 5</i>	4	4	4	5	6	7	1	2	3
<i>Patient 6</i>	4	6	5	7	8	8	3	2	3
<i>Patient 7</i>	4	5	10	8	10	12	4	5	2
<i>Patient 8</i>	4	5	5	7	9	9	3	4	4
<i>Patient 9</i>	4	4	5	7	9	11	3	5	6
<i>Patient 10</i>	5	5	6	6	8	9	1	3	3

The width of the alveolar ridge at 3 mm was generally adequate for implant insertion. At this distance moderate ridge width gain was observed as presented in Figure 12.

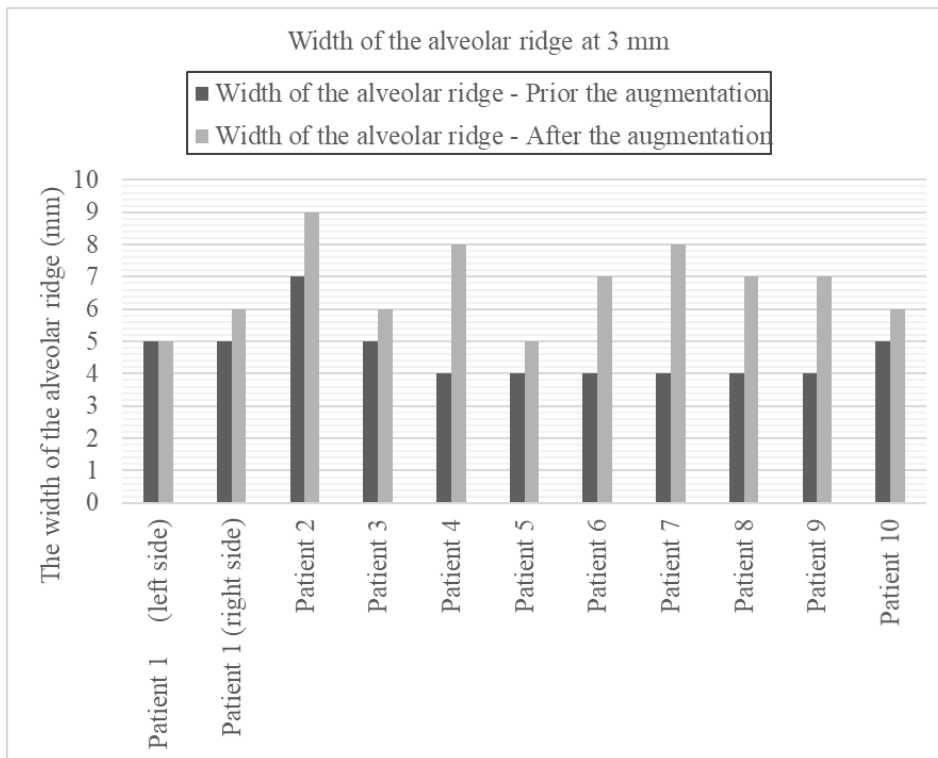


Figure 12. Width of the alveolar ridge at 3 mm. The author's own work.

At 10 and 15 mm from the reference point significant ridge width gain was observed. At 10 mm at least 2 mm alveolar ridge width gain was observed in all cases. Figure 13. and 14. present ridge width gain at these measurement points.

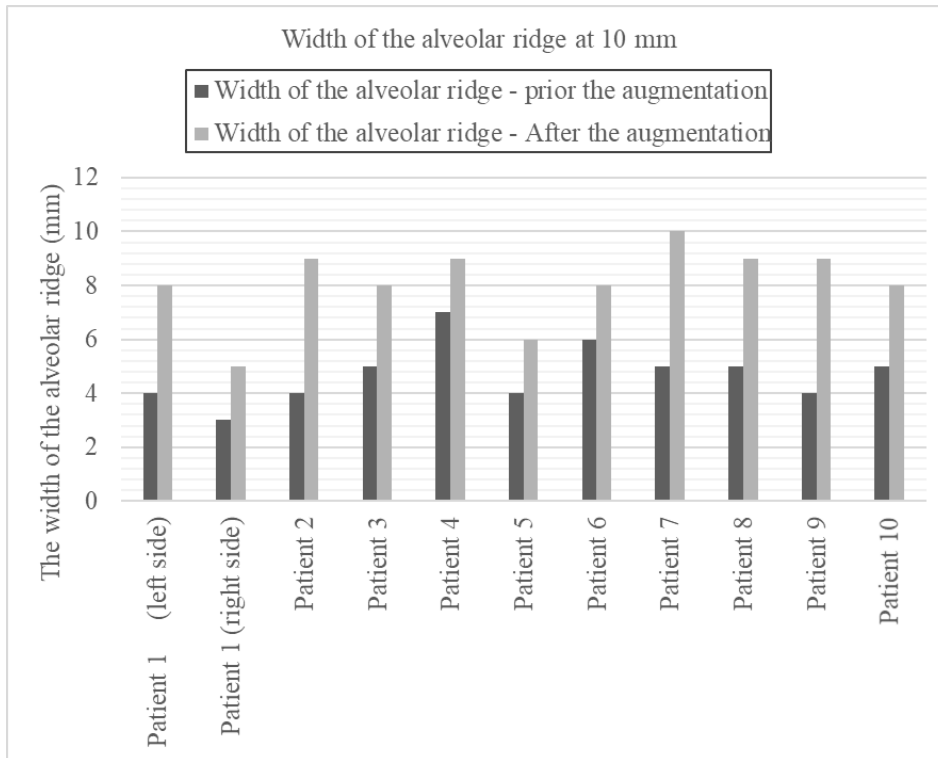


Figure 13. Width of the alveolar ridge at 10 mm. The author's own work.

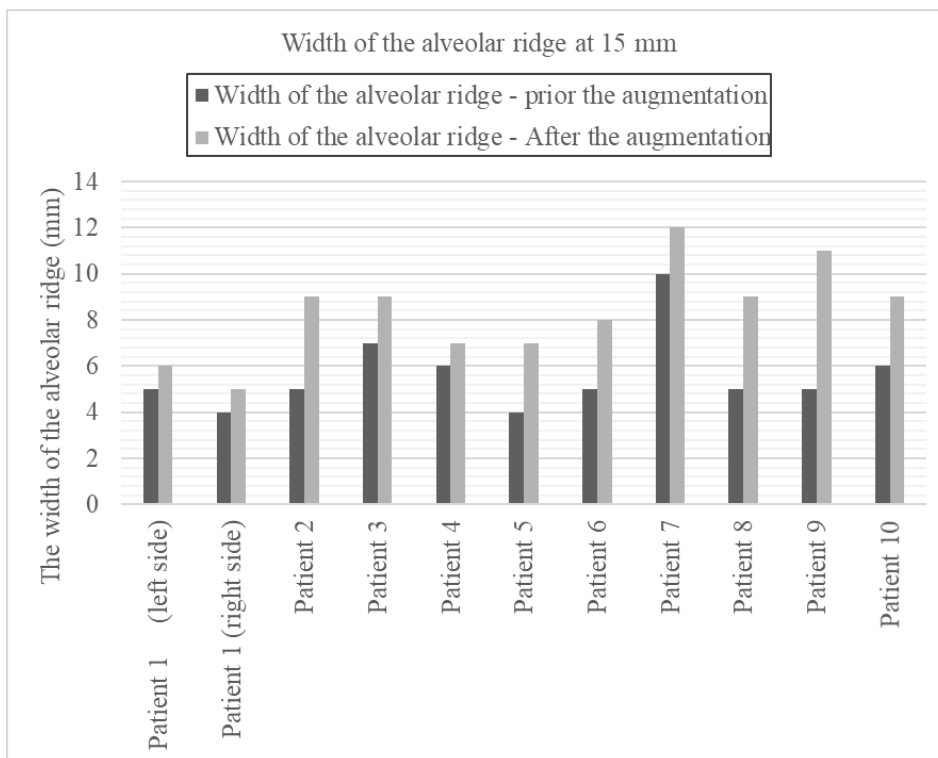


Figure 14. Width of the alveolar ridge at 15 mm. The author's own work.

Figure 15. presents the average alveolar width of the ridge prior the augmentation and after the healing period.

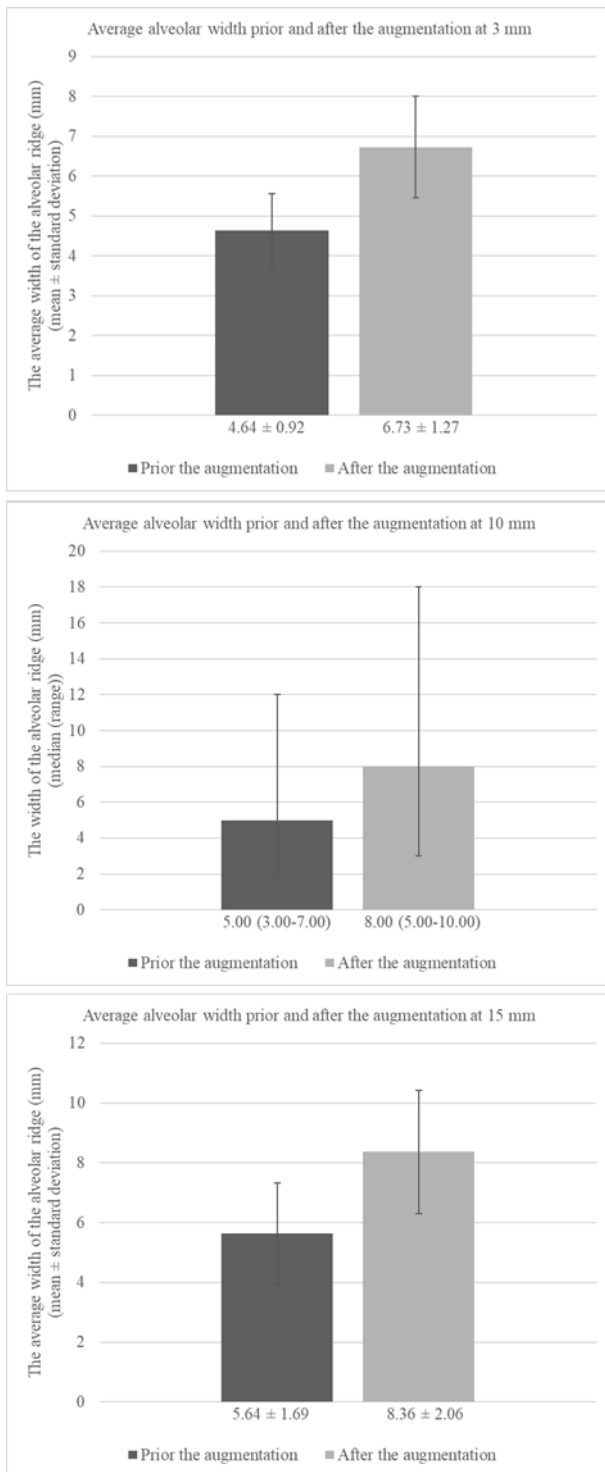


Figure 15. Average alveolar width prior and after the augmentation at 3, 10 and 15 mm. The author's own work.

4.2 Study II.

4.2.1 *The Influence of Surgical Experience on the Accuracy of CAIS*

A total of 40 dental implants were inserted in 13 patients. In the test group novice surgeons inserted 18 implants in 6 patients (4 male), age 71 ± 10.1 years; in the control group, experienced surgeons placed 22 implants in 7 patients (4 male), age 69.2 ± 4.55 years. The grey level was 613.4 ± 304.7 HU (663.7 ± 294.5 HU and 576.8 ± 313.5 HU for novice and experienced surgeons respectively and BV/TV was 0.6761 ± 0.3644 (0.7294 ± 0.3392 and 0.6373 ± 0.3847 for novice and experienced surgeons respectively) calculated at the sites of implant placement.

The width of the alveolar ridges at the site of implant placement was 7.688 ± 1.094 mm (7.567 ± 0.7300 mm and 7.786 ± 1.329 mm for novice and experienced surgeons respectively). At the sites of implant placement, the height of the alveolar ridges was 15.89 ± 4.011 mm (16.02 ± 4.624 mm and 15.78 ± 3.542 mm for novice and experienced groups, respectively).

The primary outcome variables were angular deviation, coronal, and apical global deviation.

Between the two groups no statistically significant differences were observed in the primary outcome variables. The angular deviations were 6.544 ± 5.393 ° and 7.177 ± 4.214 ° for the test and control groups, respectively. The coronal global deviation was 1.987 ± 0.7049 mm for the novice group and 1.879 ± 0.7893 mm for the experienced group. The apical global deviations were 1.954 ± 0.6853 mm and 2.124 ± 0.8373 mm for the test and control groups, respectively. Figure 16. presents the descriptive and comparative statistics of the primary outcome variables between the two study groups.

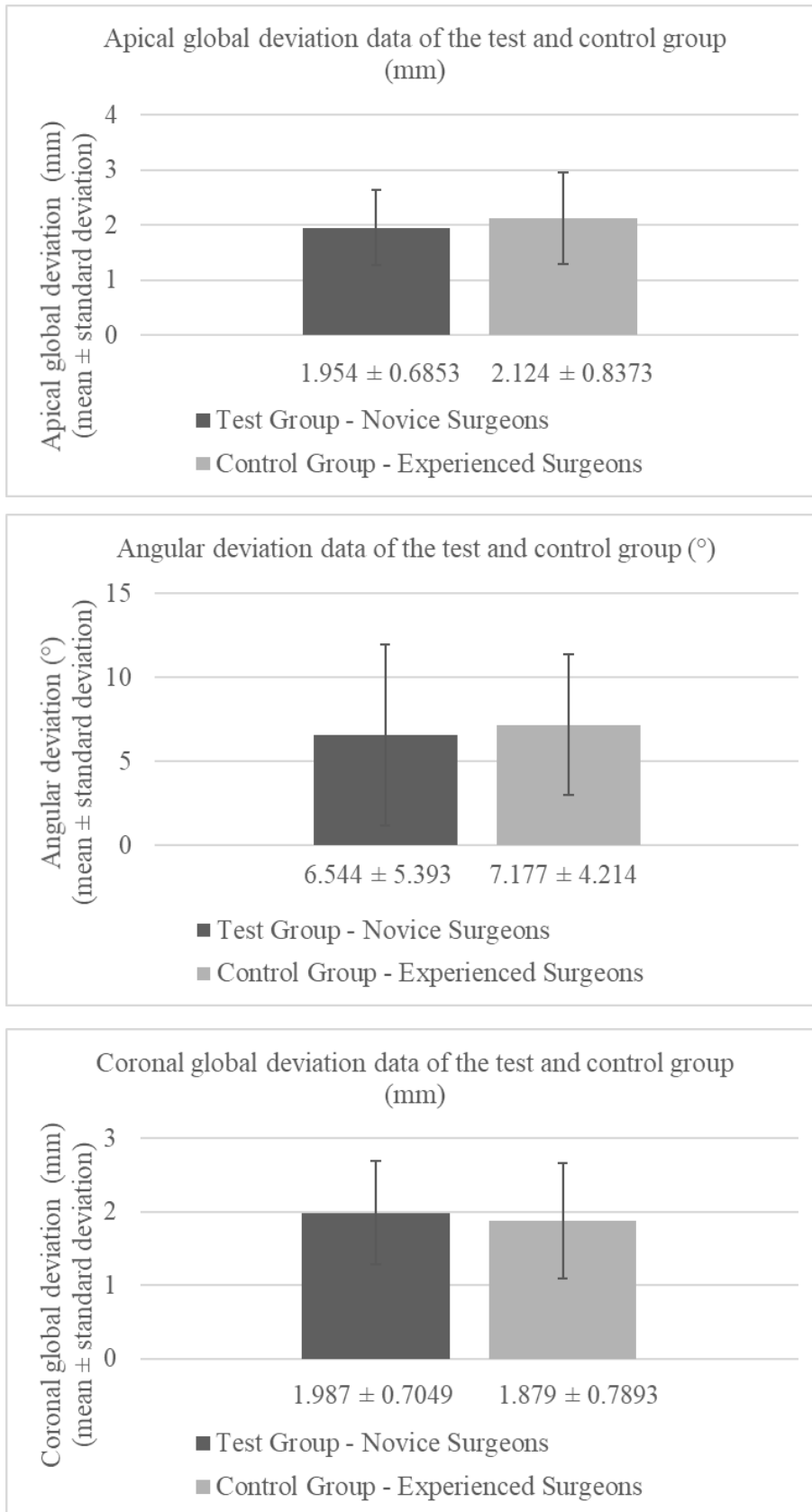


Figure 16. Bar graphs representing the angular deviation, apical global deviation, and coronal three-global deviation data. The author's own work.

4.2.2 The Influence of Bone Density on the Accuracy of CAIS

Statistically significant negative correlation was detected between the angular deviation of the implants and both grey level measurements (R-value: -0.331, $p < 0.05$) and BV/TV (R-value: -0.377, $p < 0.05$). Between either of the global deviation datasets and the grey level measurements or BV/TV the correlation was not statistically significant. Table 3. presents the correlation statistics between the datasets dealing with the accuracy of implant placement and the bone density datasets.

Table 3. The correlation statistics between the datasets dealing with the accuracy of implant placement and the bone density datasets

Correlation between Parameters		R Value	Level of Significance (p Value)
Grey level measurements (HU)	Angular deviation	-0.331*	0.037*
	Coronal global deviation	-0.027	0.869
	Apical global deviation	-0.090	0.580
Bone volume fraction (BV/TV)	Angular deviation	-0.377*	0.020*
	Coronal global deviation	-0.049	0.771
	Apical global deviation	-0.189	0.255

Spearman's test was carried out to analyze the correlations between grey level measurements in HU, BV/TV data and primary outcome variables. * $p < 0.05$.

4.3 Study III.

Computer-Aided Design and Computer-Aided Manufacturing (CAD/CAM) technology enables the clinician to manufacture a removable decompression device and its delivery on the day of the cystostomy procedure. In our study 3D printing was used to fabricate the prosthesis. Implant planning software enable the clinician to plan and control the position of the tube intended for decompression and to create a digital master cast on which the device may be planned.

Five male and one female patient were treated with six large cysts (5 radicular and 1 dentigerous cysts) using the decompression devices fabricated using the digital workflow. Preoperative volume of the cysts was $5597 \pm 3983 \text{ mm}^3$, and the postoperative cyst volume was $2330 \pm 1860 \text{ mm}^3$. The Figure 17. presents the amount of the reduction of the cyst volume.

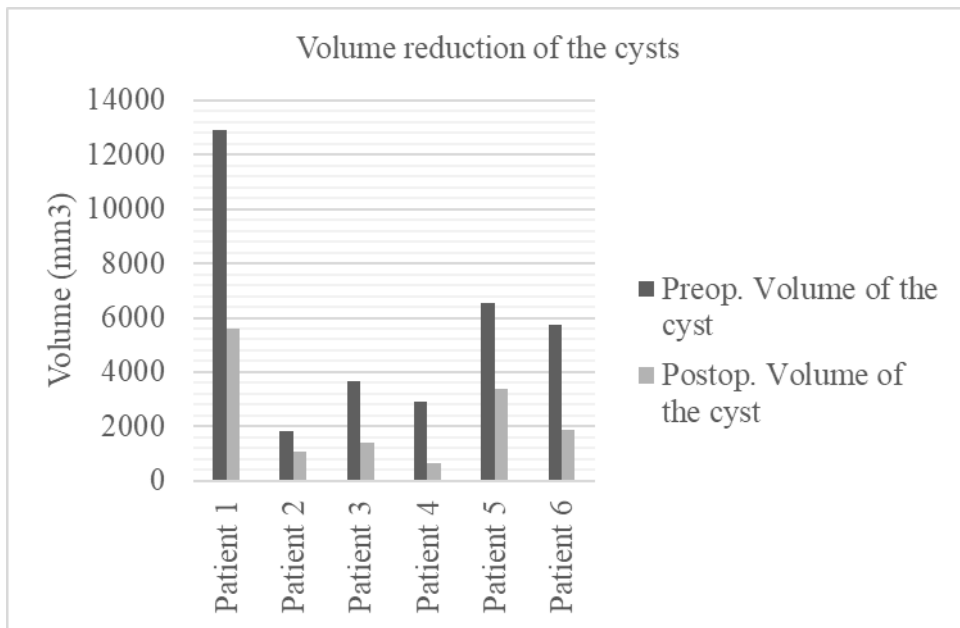


Figure 17. The results of the volumetric analysis of the cyst reduction. The author's own work.

58.84 ± 13.22 % percentage of volume reduction was detected after a 6-month long cystostomy period. Median age of the patients was 40 years (range: 15-49 years.) Demographic data of the treated patients, and the results of the volumetric analysis are presented in Table 4.

Table 4. The demographic data of patients treated and the results of the volumetric analysis

Patient Number	Sex (male/ female)	Age (years)	Position of the cyst Lower/Upper jaw	Histopathological Diagnosis	Volume Reduction	Percentage of Volume Reduction
					mm ³	%
1	m	49	l	radicular cyst	7296	56.57
2	m	37	l	radicular cyst	762	41.50
3	m	33	l	dentigerous cyst	2235	61.22
4	f	43	u	radicular cyst	3898	67.63
5	m	15	l	radicular cyst	2275	78.04
6	m	47	u	radicular cyst	3134	48.04

Biomechanical complications were observed in two cases. In one case the tube, and in the other case the clasps of the removable appliance broke off the denture. The tube fractured after 3 months of use, the clasps fractured after one month of use.

No further complications occurred during enucleation and the follow up period. None of the patients reported on excessive hemorrhage, symptoms of nerve damage. Loss of vitality of neighboring healthy teeth were not observed in any of the cases.

Following a 6-month long decompression period, in 5 out of 6 cases sufficient bone regeneration for enucleation were observed according to the postoperative CBCTs. In these

cases, successful enucleations were performed after 6 months. In the other case the second surgery was carried out after 12 months (Figure 18.).

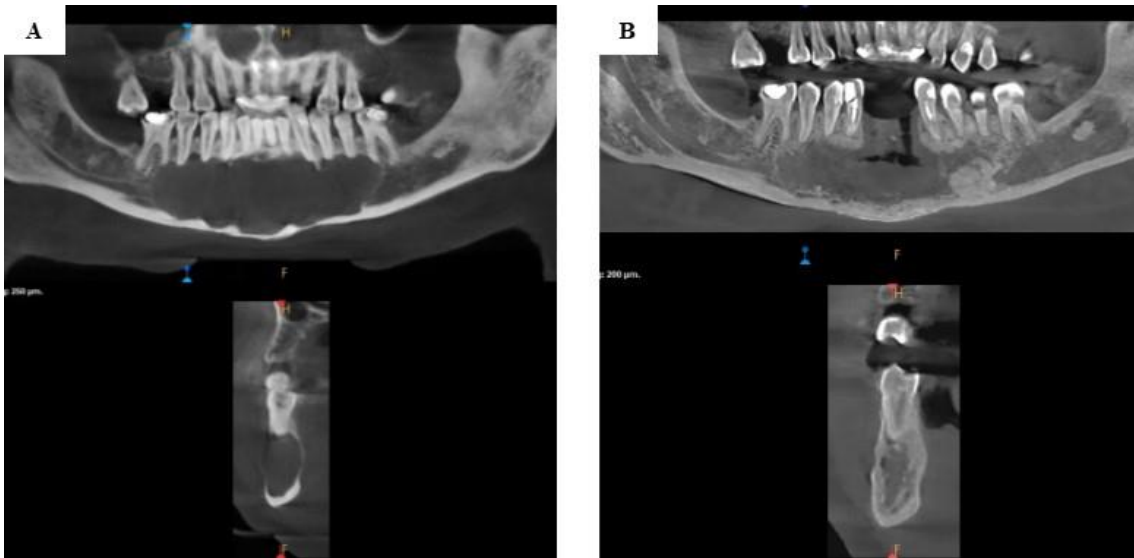


Figure 18. CBCT images before (A) and after (B) the cystostomy procedure. The author's own work.

5 Discussion

With the development of dentistry and oral surgery, the management of the various oral pathological lesions became more predictable. During surgical interventions the surgeons strive for minimal invasiveness to decrease postoperative morbidity. The aim of the research described was to describe effective, predictable and reliable surgical procedures for the successful treatment of alveolar bone atrophy, total edentulousness and odontogenic cysts.

In the last decade significant development could be observed in the field of bone management surgery. Previously the amount of the available bone limited the opportunity of the dental rehabilitation with dental implant borne prosthesis. Currently, large bone augmentations have become safe and predictable due to novel biomaterials and modified approaches to soft and hard tissue management. Albeit, certain cases, for example partially edentulous patients with severe horizontal atrophy in the mandible is still a clinical challenge. Several treatment options are available, among others alveolar ridge splitting.

Alveolar ridge splitting was first described by Tatum (29). The technique was later modified. The first modification was described by Simion et al. in 1992 (77) and Scipioni et al. in 1994 (78). In both modified techniques, implants were used as a spacer between the lingual and the buccal cortical plates. Simion et al. covered the implants and the defects with expanded polytetrafluoroethylene membranes (77). Scipioni et al. extended their study to a comprehensive study. They presented the clinical results of 170 edentulous ridge expansion procedures with an excellent success rate (78).

Within the limitations of our study, we have deduced that our modified ridge splitting technique also presents an excellent success rate. It is a reliable method to widen the knife edge alveolar ridge prior to implant placement. There was only one case, where the integration of the block was unsuccessful. At reentry, an intrabony defect was detected. Buccal and lingual cortical plates of the defect were stable, consequently the width of the ridge was augmented successfully. However, connective tissue was observed between the buccal and lingual cortical plates. The bone block carried out its purpose of maintaining space, however, probably due to the lack of vascularization connective tissue formation occurred. After debridement of the soft tissue, the implant bed was prepared in a prosthetically driven way. The apical part of the ridge was able to anchor the dental implant. Following implant placement the intrabony defect was filled with a combination of bovine bone mineral matrix graft (creos xenogain, Nobel Biocare AG, Kloten, Switzerland) and covered with a non-resorbable membrane (Permamem, Botiss

biomaterials GmbH, Zossen, Germany). After the secondary augmentation successful healing was observed.

Several modifications were described to alveolar ridge splitting. Probably the most controversial issue regarding the ridge splitting technique is the type of grafting materials used. Autografts, xenografts and alloplastic materials were applied successfully in ridge splitting. Coatoam et al. presented a modification of the ridge split procedure where allograft was used in the created defects (32). Similar successful procedure was reported by Holtzclaw et al. (79). The difference in surgical methodology of this study compared to Coatoam was the resorbable collagen membrane used to cover the surgical sites. Santagata et al. reported satisfactory clinical results using a xenograft material (80). Ella et al. reported a prospective study, using a synthetic bone substitute as filler during ridge expansion (75). There was a significant difference in ridge width gain between cases grafted by synthetic graft material, and those cases where no graft materials were used, and dental implants were inserted in the splitted sites. After expansion the grafted group showed no bone resorption. According to González-García et al. predictable results in terms of formation of new bone was observed with autogenous bone graft and bovine particulated bone graft (81). Various studies report the successful use of combination of different biomaterials (31).

Alveolar ridge splitting may be performed graftless (82). In studies where ridge splitting was accomplished graftless, dental implants were inserted simultaneously. In these cases the dental implants functional as a spacer to avoid the collapse of the bone defect (82-84). In graftless surgical methods for ridge splitting the expanded site is left empty, because it may be considered a self-containing defect, a four-wall intrabony box, with four cortical walls. This defect configuration facilitates complete bony regeneration (30). Scipioni et al. examined the micromorphology of the graftless ridge splitting sites using histological methods (85). After the healing period, which was 16 months long, mature, regenerated bone was observed (85).

The success of ridge expansion is not only dependent on the graft material used, but also on the surgical procedure. Several modifications of ridge splitting surgery have been described in the literature. The most crucial part of the surgical procedure is the appropriate green-stick fracture to preserve integrity of the buccal cortical plate. To prevent the complete fracture of the split ridge and to reduce bone resorption Santagata et al. reported a novel approach to ridge splitting (80). A partial-thickness flap was elevated to expose the alveolar crest, and to preserve the attachment of the periosteum to the bone in order to reduce the risk of bone resorption (80, 82). However, maintaining the periosteal layer attached to the bone precludes surgical access to the more apical regions. Thus, the clinician is unable to carry out corticotomy, which could

hinder their ability to induce a green-stick fracture. This may be a disadvantage of this method in the molar region of the mandible where a thick cortical bone may be anticipated. With this modification of the surgical method Santagata et al. have found less postoperative complications (80). However, in their study only the molar region of the maxilla was examined, where the bone is generally less dense compared to the posterior segments of the mandible.

The success of the surgical technique also depends on the surgical instrumentation. The original surgical method was carried out with chisel and hammer (32, 77). With the development of the surgical devices rotating (32) and oscillating instruments (86) were introduced for ridge splitting. Rotating instruments decreased the patients' discomfort, stress level. The main disadvantage of the use of rotating instruments is the weakened cortical bone plates. The rotating burs are characterized by a relatively wide diameter, which may erode valuable bone. The application of the piezosurgical devices (31) allow sparing management of bone. Their thin tips enable the preparation of curved osteotomies, decrease patient discomfort. Furthermore, the piezosurgical devices minimize the risk of soft tissue or nerve injury.

In our study, an autogenous bone block was applied as a spacer in the splitted area. Autogenous bone is considered the gold standard of bone graft materials due to its osteogenic, osteoinductive, and osteoconductive properties. The use of autogenous bone is limited due to the donor site morbidity. However, to decrease the morbidity, in our method, donor and recipient sites are accessed from the same flap, which may decrease the postoperative discomfort of the patient.

The limitations of the study are that it was carried out with a small sample size and that alveolar ridge width gain was observed only with clinical measurement.

Within these limitations of the present study, we have concluded that the modified ridge splitting technique using autogenous bone block grafts is an effective method to restore the width of the alveolar ridge prior to implant placement.

Not only augmentation strategies went through significant improvement since their introduction, but also the implant insertion techniques. Digital dental solutions provide the opportunity to insert dental implants close to the prosthetically ideal positions. Digital implant dentistry enables virtual planning followed by CAIS. According to the literature sCAIS is a safe and predictable method. The accuracy of the sCAIS method depends on the support of the surgical guide (mucosa, teeth or bone supported) and depends on the extent of guidance (PG, HG, FG) (45, 54, 87).

Overall, sCAIS decreases operation time, and postoperative morbidity compared to free hand surgery. Otherwise, there are some disadvantages, such as the cooling of the drills may be decreased. During drilling, surgical templates impede the cooling fluid to access the osteotomy. Increased bone temperature may compromise the healing (52). Also, higher costs associated with this system and the increased preoperative planning time and degree of mouth opening, may limit the application of sCAIS.

Several studies examined the accuracy of dental implant positions using CAIS. In the literature, significantly better accuracy was detected in the coronal global deviation or apical global deviation using CAIS, than the free hand method. According to the literature, mean deviations of 0.9 mm at the coronal level, 1.3 mm at the apex and 3.5° angular deviation from the planned implant positions may be expected, using sCAIS (88). The HG approach enables less accurate implant placement compared to the FG approach (44, 47, 89-91).

This overall error is a cumulative error of inaccuracy in imaging, transformation of the virtual plan to a surgical template, fabrication of the template, positioning of the template before surgery and errors observed during the surgery itself (44, 45, 88). The accuracy of implant placement depends on the support of the surgical templates and the flap elevated during surgery. According to the literature, tooth-supported surgical templates are more accurate than mSUP templates. Bone-supported templates are less accurate compared to either tooth-, or mSUP (49, 54, 91). According to Ku et al., using tooth-supported surgical templates, flapless sCAIS is more accurate than a procedure that involves flap elevation (92).

The 4th European Association for Osseointegration Consensus Conference 2015 examined the accuracy of dental implant insertion in the lower and upper jaws (88). According to this consensus conference there is no difference in the upper or in the lower jaws in insertion accuracy. Not only the role of the jaws was examined in implant insertion accuracy, but the role of the surgeons. According to the literature, the accuracy of static guided implant placement depends on the experience of the surgeons. Several in vitro studies (55-57, 83, 84, 93) confirm this finding. However, only few clinical studies are investigated the influence of experience (58-60). Cheongbeom et al. concluded that further randomized controlled clinical studies are required to determine whether surgical experience influences the accuracy of implant placement (61).

Few cadaver (94) and clinical (95-99) studies have examined the role of recipient bone structure on the accuracy using sCAIS. These studies were conducted with differing methodology; the correlation of cortical bone thickness, bone quality according to Zarb et al. (100) or bone density and accuracy of guided implant placement were assessed.

In our study, PG sCAIS with a mSUP template fixed by pins was applied to insert dental implants.

MSUP template fixed by pins has some advantages over free hand or FG dental implant insertion. The main advantage of this method is the opportunity of raising a flap, which allows the surgeon, to correct a possible inaccurate implant position if necessary. Furthermore, by raising a flap, it is possible to preserve the keratinized mucosa, which supports the long term success of the implants. The main disadvantages of using flapless FG implant placement are insufficient cooling and the loss of keratinized mucosa due to the tissue punches used. Using HG surgery it can facilitate cooling of the drills, because the template is removed for the final implant bed preparation (52) (53). These characteristics are important to make the HG mSUP template for the training of implant surgeons to get experience.

There is no consensus in the literature, regarding whether experience level of the surgeon affects the accuracy of implant placement using sCAIS. According to Hinckfuss et al. and Fernandez-Gil et al. experienced surgeons achieved more accurate implant placement using guided surgery in both partially (55, 93) and fully edentulous jaws (83), using both FG (55, 83, 93) and HG (93) approaches. Controversially, according to some other studies less accurate implant placement was detected (56, 84). In a cohort study Van de Wiele et al. examined a similar clinical situation to the situation in our study: implants were also inserted in edentulous jaws using a mSUP template. The template was anchored by pins. According to Van de Wiele's study, statistically significant difference in the accuracy of implant insertion could not be observed between the different experience levels of the surgeons (58). According to Marei et al., in their randomized clinical study, the experience of the surgeons achieved more accurate implant placement with a HG method on partially edentulous jaws using a tooth-supported template compared to novice surgeons (60). In the pilot study of Cassetta et al., the role of the experience did not impact the accuracy of implant placement using FG sCAIS with a bone-supported template anchored by pins. No statistically significant difference was detected between the implant placement accuracy of inexperienced and experienced surgeons (59). Wang et al. examined the learning curve of sCAIS. They concluded that implant placement in *in vitro* settings sCAIS is accurate regardless of the surgeons' level of experience (101).

In our study, there was no significant difference in the primary outcome variables (angular deviation, coronal global deviation, and apical global deviation of the implants placed) between the experienced and novice surgeon groups. Our null hypothesis was not rejected: surgical experience did not seem to influence the accuracy of PG sCAIS with a mSUP template anchored by pins in the edentulous jaw.

According to the literature, the role of the bone density in the accuracy of sCAIS is also controversial. According to some studies the higher the bone density, the lower the accuracy of CAIS has been detected (97, 98). However, according to other studies, no statistically significant correlation (94, 99) was detected between bone density and the accuracy of CAIS. Some other studies observed statistically significant positive correlation between bone density and the accuracy of CAIS (95). In a clinical study Ochi et al. carried out surgeries with mSUP, pin-anchored templates in edentulous jaws performing FG surgery. They determined the correlation between bone density and depths of implant insertion in the bone. They concluded that at sites with lower bone density the implants were placed deeper than planned (96). Putra et al. examined the role of bone density in accuracy of implant placement using HG templates (98). They concluded that a statistically significant negative correlation exists between bone density and the accuracy of implant insertion. Ozan et al. found similar results when performing HG sCAIS with mSUP templates (97). Jones et al. (99) and Noharet et al. (94) could not find a statistically significant correlation between bone density and the accuracy of guided implant placement. Cassetta et al. (95) and Chen et al. achieved similar results, in their studies. They found that lower bone density led to decreased implant deviation (102). In our study, implant sites were determined by the registration of pre- and postoperative CBCT data to perform BV/TV measurements. According to the literature, micro-morphometric parameters calculated from CBCT data may be reliable to predict the bone quality (103-109).

According to our study, there is a statistically significant negative correlation between bone density (presented in both grey level measurements and bone volume fraction) and angular deviation. Our null hypothesis was rejected. The lower the bone density at the sites of implant placement, the lower the accuracy of sCAIS in edentulous jaws with a mSUP PG template anchored by pins.

Weak correlation between bone density and the accuracy of CAIS was reported in the literature (96, 98) and in the present study as well. However, in a more complex clinical environment, numerous factors may influence the accuracy of CAIS. To control these risk factors, further *in vitro* and *in vivo* studies may be required to assess the role of bone density and other factors in the accuracy of CAIS.

Digital dental technologies used in the field of dental implant surgery may be applied to the treatment of different pathologies in the dento-maxillofacial region to decrease postoperative morbidity, treatment time, and enhance patient reported outcomes.

Several studies are dedicated to the measurement of volumetric reduction of OC managed by decompression. According to Kwon et al. the mean reduction rate was 54.68 % after 3 months to a maximum of 27 month-long decompression period (110). Long treatment duration increases the effectiveness of the decompression. Jeong et al. examined the effect of the decompression time on the volumetric changes. The percentage of volume reduction was 57.5 ± 21.5 % for OC which underwent decompression for more than 6 months and 58.8 ± 14.5 % for cysts which underwent decompression for less than 6 months. Bonavolonta et al. reported similar results, the reduction in cystic volume ranged from 38.2 % to a maximum of 54.4 % following 6-9 months of decompression of OC.

According to our study, percentage of volume reduction was 58.84 ± 13.22 % following 6 months long decompression period, which was similar to the results of previous studies.

In our study, no complications to the anatomical landmarks were observed. Compared to cystectomy, decompression of large cysts is a minimally invasive approach, that decreases the complications (loss of vitality of neighboring healthy teeth, oroantral communication or fistula, nerve damage). However, cystostomy may take more than 6 months and require two surgical interventions- albeit less invasive than a cystectomy of first intention-, the cystostomy and the final enucleation.

In the literature, various devices have been described for decompression. The removable decompression appliances allow to replace the missing teeth for the period of decompression which greatly improves the quality of life for the patients. For the uneventful decompression period the removable appliances enable the patient to properly clean adjacent teeth and rinse the cavity of the cyst. The patients psychosocial need for a fixed prosthesis may be disadvantages of such a method.

The staged and lengthy conventional workflow to fabricate the removable appliance may be substituted with a digital workflow. It enables the clinician to perform cystostomy, remove teeth of hopeless prognosis, and deliver the decompression appliance in the same sitting. The digital impressions performed using an intraoral scanner is a reliable method, direct with adequate accuracy for the digitization of the dentition and soft tissues for the manufacturing of removable prostheses. However, the digital workflow requires higher cost, which may be a disadvantage of the method presented in this case series. Furthermore, the digital workflow requires clinicians and laboratory technicians who are skilled in digital technology. The other limitation of the study is the measurement of the cystic volumes using manual segmentation, which is inherently operator dependent. The other limitation of using this decompression appliance is that it

requires the remaining dentition to be sufficient for the attachment of the device. The final limitations of the study are that it was carried out using a small sample size.

6 Conclusion

6.1 Study I.

According to our results the modified ridge splitting technique is a feasible intervention for the augmentation of the horizontally atrophic mandible.

According to the clinical measurements all sites showed improved ridge width. At 3 mm an average 1.89 ± 1.08 mm hard tissue gain was detected, at 10 mm 3.17 ± 1.15 mm, at 15 mm 3.60 ± 1.53 mm. Implant placement could be performed at all atrophic sites following the intervention.

- 1) According to our study the modified ridge splitting technique using autogenous bone block grafts harvested from ramus mandible is an effective and predictable method to restore the width of the mandible alveolar ridge.

6.2 Study II.

In this randomized clinical study, PG sCAIS with a mSUP, pin-anchored template was carried out to place implants in edentulous jaws.

- 1) The experience level of the surgeon did not influence significantly the accuracy of implant placement.
- 2) We have concluded that the higher the bone density at the sites of implant placement, the higher the accuracy of sCAIS.

6.3 Study III.

- 1) The digital workflow described in this prospective case series enables the delivery of the decompression appliance and cystostomy in the same time.
- 2) The digital workflow described in this prospective case series allows effective volume reduction of OC.

6.4 *New results*

6.4.1 *Study I.*

1. According to our study the modified ridge splitting technique using autogenous bone block grafts harvested from ramus mandible is an effective and predictable method to restore the width of the alveolar ridge.

6.4.2 *Study II.*

2. The experience level of the surgeon did not influence the accuracy of implant placement in edentulous jaws using a PG sCAIS approach, with a mSUP, pin-anchored template.
3. We have concluded that there is a weak, statistically significant negative correlation between bone density (presented in both grey level measurements and bone volume fraction (BV/TV) and angular deviation. The higher the bone density at the sites of implant placement, the higher the accuracy of sCAIS.

6.4.3 *Study III.*

4. The digital workflow described enables the delivery of the decompression appliance and cystostomy in the same time.
5. The digital workflow described allows effective volume reduction of OC for second stage surgical removal.

7 *Summary*

In Study I. a novel ridge augmentation procedure, the alveolar ridge expansion technique using only autogenous bone block harvested from mandible was described to widen the horizontally atrophic jaws. With this technique the thin alveolar ridge can be regenerated prior to implant placement. After a 3-month healing procedure, in most of the cases dental implants can be inserted in the prosthetically adequate positions.

In Study II, our randomized clinical study, we have analyzed the influence of surgical experience and bone density on the accuracy of sCAIS in edentulous jaws using a mSUP surgical template with a PG implant placement protocol. We have evaluated the angular deviation, the coronal global deviation and the apical global deviation and grey level measurements by registering the preoperative plan with postoperative CBCT data. The experience level of the surgeon did not influence the accuracy of implant placement; The novice surgeons could reach similar results in terms of of implant placement accuracy as their more experienced counterparts. We have concluded that the higher the bone density at the sites of implant placement, the higher the accuracy of sCAIS.

In Study III. we described a digital workflow that enables the clinician to deliver the decompression appliances at the time of cystostomy, effectively reducing the volume of OC. With this approach complications to neighbouring anatomical landmarks may be avoided during enucleation surgery owing to the bone formation, that established a safe zone around these anatomical landmarks.

8 References

1. Araújo MG, Silva CO, Misawa M, Sukekava F. Alveolar socket healing: what can we learn? *Periodontology* 2000. 2015;68(1):122-34.
2. Schroeder HE. Development, Structure, and Function of Periodontal Tissues. In: Schroeder HE, editor. *The Periodontium*. Berlin, Heidelberg: Springer Berlin Heidelberg; 1986. p. 23-323.
3. Johnson K. A study of the dimensional changes occurring in the maxilla following tooth extraction. *Australian dental journal*. 1969;14(4):241-4.
4. Schropp L, Wenzel A, Kostopoulos L, Karring T. Bone healing and soft tissue contour changes following single-tooth extraction: a clinical and radiographic 12-month prospective study. *The International journal of periodontics & restorative dentistry*. 2003;23(4):313-23.
5. Tallgren A. The continuing reduction of the residual alveolar ridges in complete denture wearers: a mixed-longitudinal study covering 25 years. *The Journal of prosthetic dentistry*. 1972;27(2):120-32.
6. Ulm C, Tepper G, Blahout R, Rausch-Fan X, Hienz S, Matejka M. Characteristic features of trabecular bone in edentulous mandibles. *Clinical oral implants research*. 2009;20(6):594-600.
7. Pietrokovski J, Massler M. Alveolar ridge resorption following tooth extraction. *The Journal of prosthetic dentistry*. 1967;17(1):21-7.
8. Reich KM, Huber CD, Lippnig WR, Ulm C, Watzek G, Tangl S. Atrophy of the residual alveolar ridge following tooth loss in an historical population. *Oral diseases*. 2011;17(1):33-44.
9. Albrektsson T, Johansson C. Osteoinduction, osteoconduction and osseointegration. *European spine journal : official publication of the European Spine Society, the European Spinal Deformity Society, and the European Section of the Cervical Spine Research Society*. 2001;10 Suppl 2(Suppl 2):S96-101.
10. Bucholz RW. Nonallograft osteoconductive bone graft substitutes. *Clinical orthopaedics and related research*. 2002(395):44-52.
11. Galindo-Moreno P, Avila G, Fernández-Barbero JE, Mesa F, O'Valle-Ravassa F, Wang HL. Clinical and histologic comparison of two different composite grafts for sinus augmentation: a pilot clinical trial. *Clinical oral implants research*. 2008;19(8):755-9.
12. Nkenke E, Neukam FW. Autogenous bone harvesting and grafting in advanced jaw resorption: morbidity, resorption and implant survival. *European journal of oral implantology*. 2014;7 Suppl 2:S203-17.

13. Schwartz-Arad D, Dori S. [Intraoral autogenous onlay block bone grafting for implant dentistry]. *Refu'at ha-peh ve ha-shinayim* (1993). 2002;19(2):35-9, 77.
14. Maiorana C, Poli PP, Mascellaro A, Ferrario S, Beretta M. Dental implants placed in resorbed alveolar ridges reconstructed with iliac crest autogenous onlay grafts: A 26-year median follow-up retrospective study. *Journal of cranio-maxillo-facial surgery : official publication of the European Association for Cranio-Maxillo-Facial Surgery*. 2019;47(5):805-14.
15. Tetè S, Vinci R, Zizzari VL, Zara S, La Scala V, Cataldi A, Gherlone E, Piattelli A. Maxillary sinus augmentation procedures through equine-derived biomaterial or calvaria autologous bone: immunohistochemical evaluation of OPG/RANKL in humans. *European journal of histochemistry : EJH*. 2013;57(1):1-10.
16. Laurencin C, Khan Y, El-Amin SF. Bone graft substitutes. *Expert review of medical devices*. 2006;3(1):49-57.
17. Misch CM. Ridge augmentation using mandibular ramus bone grafts for the placement of dental implants: presentation of a technique. *Practical periodontics and aesthetic dentistry : PPAD*. 1996;8(2):127-35.
18. Zhao R, Yang R, Cooper PR, Khurshid Z, Shavandi A, Ratnayake J. Bone Grafts and Substitutes in Dentistry: A Review of Current Trends and Developments. *Molecules (Basel, Switzerland)*. 2021;26(10).
19. Andersson L, Kahnberg K-E, Ma P. *Oral and Maxillofacial Surgery*. Oxford: Wiley-Blackwell; 2010. 383-404 p.
20. Zouhary KJ. Bone graft harvesting from distant sites: concepts and techniques. *Oral and maxillofacial surgery clinics of North America*. 2010;22(3):301-316.
21. Khoury F, Hanser T. Mandibular bone block harvesting from the retromolar region: a 10-year prospective clinical study. *The International journal of oral & maxillofacial implants*. 2015;30(3):688-97.
22. Zeltner M, Flückiger LB, Hämmerle CH, Hüsler J, Benic GI. Volumetric analysis of chin and mandibular retromolar region as donor sites for cortico-cancellous bone blocks. *Clinical oral implants research*. 2016;27(8):999-1004.
23. Pistilli R, Signorini L, Pisacane A, Lizio G, Felice P. Case of severe bone atrophy of the posterior maxilla rehabilitated with blocks of equine origin bone: histological results. *Implant dentistry*. 2013;22(1):8-15.
24. Thoma DS, Payer M, Jakse N, Bienz SP, Hüsler J, Schmidlin PR, et al. Randomized, controlled clinical two-centre study using xenogeneic block grafts loaded with recombinant

human bone morphogenetic protein-2 or autogenous bone blocks for lateral ridge augmentation. *Journal of clinical periodontology*. 2018;45(2):265-76.

25. Aloy-Prósper A, Peñarrocha-Oltra D, Peñarrocha-Diago M, Peñarrocha-Diago M. The outcome of intraoral onlay block bone grafts on alveolar ridge augmentations: a systematic review. *Medicina oral, patología oral y cirugía bucal*. 2015;20(2):e251-8.
26. Chappuis V, Cavusoglu Y, Buser D, von Arx T. Lateral Ridge Augmentation Using Autogenous Block Grafts and Guided Bone Regeneration: A 10-Year Prospective Case Series Study. *Clinical implant dentistry and related research*. 2017;19(1):85-96.
27. Wang RE, Lang NP. Ridge preservation after tooth extraction. *Clinical oral implants research*. 2012;23 Suppl 6:147-56.
28. Starch-Jensen T, Nielsen HB. Sandwich osteotomy of the atrophic posterior mandible with interpositional autogenous bone block graft compared with bone substitute material: a systematic review and meta-analysis. *The British journal of oral & maxillofacial surgery*. 2020;58(10):e237-e47.
29. Tatum OH, Hardin J. The omni implant system. *Clarke's Clinical Dentistry*. 1984;5:126-7.
30. Blus C, Szmukler-Moncler S. Split-crest and immediate implant placement with ultrasonic bone surgery: a 3-year life-table analysis with 230 treated sites. *Clinical oral implants research*. 2006;17(6):700-7.
31. Moro A, Gasparini G, Foresta E, Saponaro G, Falchi M, Cardarelli L, et al. Alveolar Ridge Split Technique Using Piezosurgery with Specially Designed Tips. *BioMed research international*. 2017;2017:4530378.
32. Coatoam GW, Mariotti A. The segmental ridge-split procedure. *Journal of periodontology*. 2003;74(5):757-70.
33. Basa S, Varol A, Turker N. Alternative bone expansion technique for immediate placement of implants in the edentulous posterior mandibular ridge: a clinical report. *The International journal of oral & maxillofacial implants*. 2004;19(4):554-8.
34. Diniz JG, Gregori C. [Indications and contraindications for periapical surgery. Critical study]. *Revista da Associacao Paulista de Cirurgioes Dentistas*. 1974;28(2):88-94.
35. Cassetta M, Giansanti M, Di Mambro A, Stefanelli LV. Accuracy of positioning of implants inserted using a mucosa-supported stereolithographic surgical guide in the edentulous maxilla and mandible. *The International journal of oral & maxillofacial implants*. 2014;29(5):1071-8.

36. Belser UC, Mericske-Stern R, Bernard JP, Taylor TD. Prosthetic management of the partially dentate patient with fixed implant restorations. *Clinical oral implants research*. 2000;11 Suppl 1:126-45.
37. Ramaglia L, Toti P, Sbordone C, Guidetti F, Martuscelli R, Sbordone L. Implant angulation: 2-year retrospective analysis on the influence of dental implant angle insertion on marginal bone resorption in maxillary and mandibular osseous onlay grafts. *Clinical oral investigations*. 2015;19(4):769-79.
38. Abduo J, Lau D. Accuracy of static computer-assisted implant placement in anterior and posterior sites by clinicians new to implant dentistry: in vitro comparison of fully guided, pilot-guided, and freehand protocols. *International journal of implant dentistry*. 2020;6(1):1-13.
39. Jacobs R, Salmon B, Codari M, Hassan B, Bornstein MM. Cone beam computed tomography in implant dentistry: recommendations for clinical use. *BMC oral health*. 2018;18(1):1-16.
40. Fortin T, Coudert JL, Champlébourg G, Sautot P, Lavallée S. Computer-assisted dental implant surgery using computed tomography. *Journal of image guided surgery*. 1995;1(1):53-8.
41. Jung RE, Schneider D, Ganeles J, Wismeijer D, Zwahlen M, Hämmerle CH, et al. Computer technology applications in surgical implant dentistry: a systematic review. *The International journal of oral & maxillofacial implants*. 2009;24 Suppl:92-109.
42. Schulz MC, Hofmann F, Range U, Lauer G, Haim D. Pilot-drill guided vs. full-guided implant insertion in artificial mandibles-a prospective laboratory study in fifth-year dental students. *International journal of implant dentistry*. 2019;5(1):1-10.
43. Wismeijer D, Joda T, Flügge T, Fokas G, Tahmaseb A, Bechelli D, et al. Group 5 ITI Consensus Report: Digital technologies. *Clinical oral implants research*. 2018;29 Suppl 16:436-42.
44. Vercruyssen M, Laleman I, Jacobs R, Quirynen M. Computer-supported implant planning and guided surgery: a narrative review. *Clinical oral implants research*. 2015;26 Suppl 11:69-76.
45. Vercruyssen M, Fortin T, Widmann G, Jacobs R, Quirynen M. Different techniques of static/dynamic guided implant surgery: modalities and indications. *Periodontology 2000*. 2014;66(1):214-27.
46. Colombo M, Mangano C, Mijiritsky E, Krebs M, Hauschild U, Fortin T. Clinical applications and effectiveness of guided implant surgery: a critical review based on randomized controlled trials. *BMC oral health*. 2017;17(1):150.

47. Gargallo-Albiol J, Barootchi S, Salomó-Coll O, Wang HL. Advantages and disadvantages of implant navigation surgery. A systematic review. *Annals of anatomy = Anatomischer Anzeiger : official organ of the Anatomische Gesellschaft*. 2019;225:1-10.
48. Varga E, Jr., Antal M, Major L, Kiscsatári R, Braunitzer G, Piffkó J. Guidance means accuracy: A randomized clinical trial on freehand versus guided dental implantation. *Clinical oral implants research*. 2020;31(5):417-30.
49. Arisan V, Karabuda CZ, Ozdemir T. Implant surgery using bone- and mucosa-supported stereolithographic guides in totally edentulous jaws: surgical and post-operative outcomes of computer-aided vs. standard techniques. *Clinical oral implants research*. 2010;21(9):980-8.
50. Fortin T, Bosson JL, Isidori M, Blanchet E. Effect of flapless surgery on pain experienced in implant placement using an image-guided system. *The International journal of oral & maxillofacial implants*. 2006;21(2):298-304.
51. Pozzi A, Tallarico M, Marchetti M, Scarfò B, Esposito M. Computer-guided versus free-hand placement of immediately loaded dental implants: 1-year post-loading results of a multicentre randomised controlled trial. *European journal of oral implantology*. 2014;7(3):229-42.
52. Boa K, Barrak I, Varga E, Jr., Joob-Fancsaly A, Varga E, Piffko J. Intraosseous generation of heat during guided surgical drilling: an ex vivo study of the effect of the temperature of the irrigating fluid. *The British journal of oral & maxillofacial surgery*. 2016;54(8):904-8.
53. Liu YF, Wu JL, Zhang JX, Peng W, Liao WQ. Numerical and Experimental Analyses on the Temperature Distribution in the Dental Implant Preparation Area when Using a Surgical Guide. *Journal of prosthodontics : official journal of the American College of Prosthodontists*. 2018;27(1):42-51.
54. Tahmaseb A, Wismeijer D, Coucke W, Derksen W. Computer technology applications in surgical implant dentistry: a systematic review. *The International journal of oral & maxillofacial implants*. 2014;29 Suppl:25-42.
55. Fernández-Gil Á, Gil HS, Velasco MG, Moreno Vázquez JC. An In Vitro Model to Evaluate the Accuracy of Guided Implant Placement Based on the Surgeon's Experience. *The International journal of oral & maxillofacial implants*. 2017;32(3):151-4.
56. Rungcharassaeng K, Caruso JM, Kan JY, Schutyser F, Boumans T. Accuracy of computer-guided surgery: A comparison of operator experience. *The Journal of prosthetic dentistry*. 2015;114(3):407-13.

57. Toyoshima T, Tanaka H, Sasaki M, Ichimaru E, Naito Y, Matsushita Y, et al. Accuracy of implant surgery with surgical guide by inexperienced clinicians: an in vitro study. *Clinical and experimental dental research*. 2015;1(1):10-7.
58. Van de Wiele G, Teughels W, Vercruyssen M, Coucke W, Temmerman A, Quirynen M. The accuracy of guided surgery via mucosa-supported stereolithographic surgical templates in the hands of surgeons with little experience. *Clinical oral implants research*. 2015;26(12):1489-94.
59. Cassetta M, Bellardini M. How much does experience in guided implant surgery play a role in accuracy? A randomized controlled pilot study. *International journal of oral and maxillofacial surgery*. 2017;46(7):922-30.
60. Marei HF, Abdel-Hady A, Al-Khalifa K, Al-Mahalawy H. Influence of surgeon experience on the accuracy of implant placement via a partially computer-guided surgical protocol. *The International journal of oral & maxillofacial implants*. 2019;34(5):1177–83.
61. Seo C, Juodzbaly G. Accuracy of Guided Surgery via Stereolithographic Mucosa-Supported Surgical Guide in Implant Surgery for Edentulous Patient: a Systematic Review. *Journal of oral & maxillofacial research*. 2018;9(1):e1.
62. Wright JM, Vered M. Update from the 4th Edition of the World Health Organization Classification of Head and Neck Tumours: Odontogenic and Maxillofacial Bone Tumors. *Head and neck pathology*. 2017;11(1):68-77.
63. Castro-Núñez J. Decompression of Odontogenic Cystic Lesions: Past, Present, and Future. *Journal of oral and maxillofacial surgery : official journal of the American Association of Oral and Maxillofacial Surgeons*. 2016;74(1):104.e1-9.
64. Delbem AC, Cunha RF, Vieira AE, Pugliesi DM. Conservative treatment of a radicular cyst in a 5-year-old child: a case report. *International journal of paediatric dentistry*. 2003;13(6):447-50.
65. Swantek JJ, Reyes MI, Grannum RI, Ogle OE. A technique for long term decompression of large mandibular cysts. *Journal of oral and maxillofacial surgery : official journal of the American Association of Oral and Maxillofacial Surgeons*. 2012;70(4):856-9.
66. Gao L, Wang XL, Li SM, Liu CY, Chen C, Li JW, et al. Decompression as a treatment for odontogenic cystic lesions of the jaw. *Journal of oral and maxillofacial surgery : official journal of the American Association of Oral and Maxillofacial Surgeons*. 2014;72(2):327-33.
67. Garde JB, Kulkarni AU, Dadhe DP, Deshmukh VB. Use of decompression tubes in the management of excessively large odontogenic keratocyst. *BMJ case reports*. 2012;2012.

68. Gunraj MN. Decompression of a large periapical lesion utilizing an improved drainage device. *Journal of endodontics*. 1990;16(3):140-3.
69. Morankar R, Bhatia SK, Goyal A, Gulia P. Conservative management of keratocystic odontogenic tumour in a young child with decompression and an intraoral appliance: 5-year follow-up. *BMJ case reports*. 2018;2018.
70. Enislidis G, Fock N, Sulzbacher I, Ewers R. Conservative treatment of large cystic lesions of the mandible: a prospective study of the effect of decompression. *The British journal of oral & maxillofacial surgery*. 2004;42(6):546-50.
71. Kolokythas A, Schlieve T, Miloro M. Simple method for securing a decompression tube for odontogenic cysts and tumors: a technical note. *Journal of oral and maxillofacial surgery : official journal of the American Association of Oral and Maxillofacial Surgeons*. 2011;69(9):2392-5.
72. Marker P, Brøndum N, Clausen PP, Bastian HL. Treatment of large odontogenic keratocysts by decompression and later cystectomy: a long-term follow-up and a histologic study of 23 cases. *Oral surgery, oral medicine, oral pathology, oral radiology, and endodontics*. 1996;82(2):122-31.
73. Ozturk G, Dogan S, Gumus H, Soylu E, Sezer AB, Yilmaz S. Consequences of Decompression Treatment With a Special-Made Appliance of Nonsyndromic Odontogenic Cysts in Children. *Journal of oral and maxillofacial surgery : official journal of the American Association of Oral and Maxillofacial Surgeons*. 2022;80(7):1223-37.
74. Ugurlu F, Akyuz S, Menten A. Outcome of Mandibular Dentigerous Cysts 1 to 10 Years After Decompression Using a Custom-Made Appliance. *Journal of oral and maxillofacial surgery : official journal of the American Association of Oral and Maxillofacial Surgeons*. 2021;79(1):152-63.
75. Ella B, Laurentjoye M, Sedarat C, Coutant JC, Masson E, Rouas A. Mandibular ridge expansion using a horizontal bone-splitting technique and synthetic bone substitute: an alternative to bone block grafting? *The International journal of oral & maxillofacial implants*. 2014;29(1):135-40.
76. World Medical Association Declaration of Helsinki: ethical principles for medical research involving human subjects. *Jama*. 2013;310(20):2191-4.
77. Simion M, Baldoni M, Zaffe D. Jawbone enlargement using immediate implant placement associated with a split-crest technique and guided tissue regeneration. *The International journal of periodontics & restorative dentistry*. 1992;12(6):462-73.

78. Scipioni A, Bruschi GB, Calesini G. The edentulous ridge expansion technique: a five-year study. *The International journal of periodontics & restorative dentistry*. 1994;14(5):451-9.
79. Holtzclaw DJ, Toscano NJ, Rosen PS. Reconstruction of posterior mandibular alveolar ridge deficiencies with the piezoelectric hinge-assisted ridge split technique: a retrospective observational report. *Journal of periodontology*. 2010;81(11):1580-6.
80. Santagata M, Guariniello L, D'Andrea A, Tartaro G. A modified crestal ridge expansion technique for immediate placement of implants: a report of three cases. *The Journal of oral implantology*. 2008;34(6):319-24.
81. González-García R, Monje F, Moreno C. Alveolar split osteotomy for the treatment of the severe narrow ridge maxillary atrophy: a modified technique. *International journal of oral and maxillofacial surgery*. 2011;40(1):57-64.
82. Tang YL, Yuan J, Song YL, Ma W, Chao X, Li DH. Ridge expansion alone or in combination with guided bone regeneration to facilitate implant placement in narrow alveolar ridges: a retrospective study. *Clinical oral implants research*. 2015;26(2):204-11.
83. Cushen SE, Turkyilmaz I. Impact of operator experience on the accuracy of implant placement with stereolithographic surgical templates: an in vitro study. *The Journal of prosthetic dentistry*. 2013;109(4):248-54.
84. Park SJ, Leesungbok R, Cui T, Lee SW, Ahn SJ. Reliability of a CAD/CAM Surgical Guide for Implant Placement: An In Vitro Comparison of Surgeons' Experience Levels and Implant Sites. *The International journal of prosthodontics*. 2017;30(4):367-169.
85. Scipioni A, Bruschi GB, Calesini G, Bruschi E, De Martino C. Bone regeneration in the edentulous ridge expansion technique: histologic and ultrastructural study of 20 clinical cases. *The International journal of periodontics & restorative dentistry*. 1999;19(3):269-77.
86. Khoury F, Happe A. Soft tissue management in oral implantology: a review of surgical techniques for shaping an esthetic and functional peri-implant soft tissue structure. *Quintessence international (Berlin, Germany : 1985)*. 2000;31(7):483-99.
87. Van Assche N, Vercruyssen M, Coucke W, Teughels W, Jacobs R, Quirynen M. Accuracy of computer-aided implant placement. *Clinical oral implants research*. 2012;23 Suppl 6:112-23.
88. Hämmerle CH, Cordaro L, van Assche N, Benic GI, Bornstein M, Gamper F, et al. Digital technologies to support planning, treatment, and fabrication processes and outcome assessments in implant dentistry. Summary and consensus statements. The 4th EAO consensus conference 2015. *Clinical oral implants research*. 2015;26 Suppl 11:97-101.

89. Vercruyssen M, Cox C, Coucke W, Naert I, Jacobs R, Quirynen M. A randomized clinical trial comparing guided implant surgery (bone- or mucosa-supported) with mental navigation or the use of a pilot-drill template. *Journal of clinical periodontology*. 2014;41(7):717-23.
90. Younes F, Cosyn J, De Bruyckere T, Cleymaet R, Bouckaert E, Eghbali A. A randomized controlled study on the accuracy of free-handed, pilot-drill guided and fully guided implant surgery in partially edentulous patients. *Journal of clinical periodontology*. 2018;45(6):721-32.
91. Vercruyssen M, Coucke W, Naert I, Jacobs R, Teughels W, Quirynen M. Depth and lateral deviations in guided implant surgery: an RCT comparing guided surgery with mental navigation or the use of a pilot-drill template. *Clinical oral implants research*. 2015;26(11):1315-20.
92. Ku JK, Lee J, Lee HJ, Yun PY, Kim YK. Accuracy of dental implant placement with computer-guided surgery: a retrospective cohort study. *BMC oral health*. 2022;22(1):8.
93. Hinckfuss S, Conrad HJ, Lin L, Lunos S, Seong WJ. Effect of surgical guide design and surgeon's experience on the accuracy of implant placement. *The Journal of oral implantology*. 2012;38(4):311-23.
94. Noharet R, Pettersson A, Bourgeois D. Accuracy of implant placement in the posterior maxilla as related to 2 types of surgical guides: a pilot study in the human cadaver. *The Journal of prosthetic dentistry*. 2014;112(3):526-32.
95. Cassetta M, Di Mambro A, Giansanti M, Stefanelli LV, Cavallini C. The intrinsic error of a stereolithographic surgical template in implant guided surgery. *International journal of oral and maxillofacial surgery*. 2013;42(2):264-75.
96. Ochi M, Kanazawa M, Sato D, Kasugai S, Hirano S, Minakuchi S. Factors affecting accuracy of implant placement with mucosa-supported stereolithographic surgical guides in edentulous mandibles. *Computers in biology and medicine*. 2013;43(11):1653-60.
97. Ozan O, Orhan K, Turkyilmaz I. Correlation between bone density and angular deviation of implants placed using CT-generated surgical guides. *The Journal of craniofacial surgery*. 2011;22(5):1755-61.
98. Putra RH, Yoda N, Iikubo M, Kataoka Y, Yamauchi K, Koyama S, et al. Influence of bone condition on implant placement accuracy with computer-guided surgery. *International journal of implant dentistry*. 2020;6(1):62.
99. Jones A. Accuracy of mucosa supported guided dental implant surgery. *Clinical case reports*. 2018;6(11):2131-9.

100. Zarb GA, Albrektsson T. Tissue-integrated prostheses: osseointegration in clinical dentistry: Quintessence Publishing Company; 1985.
101. Wang W, Zhuang M, Li S, Shen Y, Lan R, Wu Y, et al. Exploring training dental implant placement using static or dynamic devices among dental students. *European journal of dental education : official journal of the Association for Dental Education in Europe*. 2022.
102. Chen Z, Liu Y, Xie X, Deng F. Influence of bone density on the accuracy of artificial intelligence-guided implant surgery: An in vitro study. *The Journal of prosthetic dentistry*. 2022.
103. Van Dessel J, Nicolielo LF, Huang Y, Coudyzer W, Salmon B, Lambrichts I, et al. Accuracy and reliability of different cone beam computed tomography (CBCT) devices for structural analysis of alveolar bone in comparison with multislice CT and micro-CT. *European journal of oral implantology*. 2017;10(1):95-105.
104. Kivovics M, Szabó BT, Németh O, Iványi D, Trimmel B, Szmirnova I, et al. Comparison between Micro-Computed Tomography and Cone-Beam Computed Tomography in the Assessment of Bone Quality and a Long-Term Volumetric Study of the Augmented Sinus Grafted with an Albumin Impregnated Allograft. *Journal of clinical medicine*. 2020;9(2).
105. González-García R, Monje F. The reliability of cone-beam computed tomography to assess bone density at dental implant recipient sites: a histomorphometric analysis by micro-CT. *Clinical oral implants research*. 2013;24(8):871-9.
106. Hua Y, Nackaerts O, Duyck J, Maes F, Jacobs R. Bone quality assessment based on cone beam computed tomography imaging. *Clinical oral implants research*. 2009;20(8):767-71.
107. Ibrahim N, Parsa A, Hassan B, van der Stelt P, Aartman IH, Wismeijer D. Accuracy of trabecular bone microstructural measurement at planned dental implant sites using cone-beam CT datasets. *Clinical oral implants research*. 2014;25(8):941-5.
108. Monje A, Monje F, González-García R, Galindo-Moreno P, Rodriguez-Salvanes F, Wang HL. Comparison between microcomputed tomography and cone-beam computed tomography radiologic bone to assess atrophic posterior maxilla density and microarchitecture. *Clinical oral implants research*. 2014;25(6):723-8.
109. Parsa A, Ibrahim N, Hassan B, van der Stelt P, Wismeijer D. Bone quality evaluation at dental implant site using multislice CT, micro-CT, and cone beam CT. *Clinical oral implants research*. 2015;26(1):e1-7.
110. Kwon HB, Park YS, Han JS. Augmented reality in dentistry: a current perspective. *Acta odontologica Scandinavica*. 2018;76(7):497-503.

9 *Bibliography of the candidate's publications*

9.1 *Related Publications*

9.1.1 *Study I*

Pénzes Dorottya, Simon Fanni, Mijiritsky Eitan, Németh Orsolya , Kivovics Márton
A Modified Ridge Splitting Technique Using Autogenous Bone Blocks - A Case Series
MATERIALS 13 : 18 Paper: 4036 , 10 p. (2020)

Szaccikk (Folyóiratcikk) | Tudományos

Scopus Condensed Matter Physics SJR indikátor: Q2

Scopus Materials Science (miscellaneous) SJR indikátor: Q2

IF: 3,623

Pénzes Dorottya, Simon Fanni, Mijiritsky Eitan, Németh Orsolya, Kivovics Márton
Horizontálisan atrófizált állcsontgerinc rehabilitációja tágításos oszteotómiával
FOGORVOSI SZEMLE

115 : 2 pp. 94 98. (2022)

Szaccikk (Folyóiratcikk) | Tudományos

9.1.2 *Study II*

Kivovics Márton, **Pénzes Dorottya**, Németh Orsolya, Mijiritsky Eitan
The Influence of Surgical Experience and Bone Density on the Accuracy of Static Computer Assisted Implant Surgery in Edentulous Jaws Using a Mucosa Supported Surgical Template with a Half Guided Implant Placement Protocol A Randomized Clinical Study

MATERIALS 13 : 24 Paper: 5759 , 12 p. (2020)

Szaccikk (Folyóiratcikk) | Tudományos

Scopus Condensed Matter Physics SJR indikátor: Q2

Scopus Materials Science (miscellaneous) SJR indikátor : Q2

IF: 3,623

9.1.3 *Study III*

Kivovics Márton, **Pénzes Dorottya**, Moldvai Júlia, Mijiritsky Eitan, Németh Orsolya
A custom made removable appliance for the decompression of odontogenic cysts fabricated using a digital workflow

JOURNAL OF DENTISTRY 126 Paper: 104295 , 6 p. (2022)

Szakcikk (Folyóiratcikk) | Tudományos

Scopus Dentistry (miscellaneous) SJR indikátor: D1

IF:4,991 (várható IF érték)

9.2 *Non-related Publications*

Kivovics Márton, Takács Anna, **Pénzes Dorottya**, Németh Orsolya, Mijiritsky Eitan
Accuracy of dental implant placement using augmented reality based navigation, static
computer assisted implant surgery, and the free hand method: An in vitro study

JOURNAL OF DENTISTRY

119 Paper: 104070 , 7 p. (2022)

Szakcikk (Folyóiratcikk) | Tudományos

IF: 4,991

Pénzes D, Kivovics M

A fogeltávolítás során megnyílt arcüreg ellátása: Lebennyel történő zárás 2. rész

MAGYAR FOGORVOS: A MAGYAR ORVOSI KAMARA FOGORVOSI

TAGOZATÁNAK LAPJA 28 : 2 pp. 84 88. (2019)

Összefoglaló cikk (Folyóiratcikk) | Tudományos

Pénzes D, Kivovics M

A fogeltávolítás során megnyílt arcüreg ellátása: Dentális eredetű krónikus
sinusitis ellátása 1. rész

MAGYAR FOGORVOS: A MAGYAR ORVOSI KAMARA FOGORVOSI

TAGOZATÁNAK LAPJA 28 : 1 pp. 14 17. (2019)

Összefoglaló cikk (Folyóiratcikk) | Tudományos

10 Acknowledgements

I would like to thank the guidance received from my tutor, Marton Kivovics, who has inspired and supported me since I was admitted for specialist training at the Department of Community Dentistry.

I would like to thank the support to my Head of Department, Orsolya Németh for her support and help as a co-author. I would like to express my gratitude to my previous Head of Department, Peter Kivovics for his support and help in patient recruitment.

I would like to thank my co-authors for their work in the studies presented.

I would like to express my gratitude to my co-workers at the Department of Community Dentistry for all their help in managing the patients in the studies presented.

Last, but not least, I would like to thank my wonderful Family for their great advice, support, and encouragement that were crucial during my studies.

10.1 Study I

This study was supported by the NSK Europe GmbH and Hungarian Dental Association. These two institutes provided the piezoelectronic device (NSK Variosurg3 Ultrasonic Bone Surgery System) used in the study.

10.2 Study II

The authors would like to thank Innoimplant Ltd, Budapest, Hungary for making the AR based dynamic navigation system, Innooral System available for preclinical testing. The authors thank György Haraszti, Sándor Fazekas and Dávid Orcsik for their support throughout the research project. The authors thank Callus Implant Solutions GmbH, Hamburg, Germany for the implants used in the present study.