

SEMMELWEIS EGYETEM  
DOKTORI ISKOLA

**Ph.D. értekezések**

**2978.**

**VINGENDER SZONJA**

**Fogorvostudományi kutatások**  
című program

Programvezető: Dr. Varga Gábor, egyetemi tanár


Témavezető: Dr. Vaszilko Mihály, egyetemi docens

# MINIMALLY INVASIVE TREATMENT METHODS FOR INTERNAL DERANGEMENT OF THE TEMPOROMANDIBULAR JOINT

**PhD thesis**

**Szonja Vingender, DMD**

Doctoral School, Dental Research Division  
Semmelweis University



Supervisor: Mihály Vaszilkó, MD, DMD, PhD

Official reviewers: Csaba Dobó-Nagy, DMD, PhD  
Márk Antal, DMD, PhD

Head of the Complex Examination Committee: Gábor Gerber, DMD, CSc.

Members of the Complex Examination Committee: István Gera, DMD, CSc.  
Ákos Nagy, DMD, PhD

Budapest  
2023

## Table of Contents

LIST OF ABBREVIATIONS .....	4
1. INTRODUCTION.....	5
1.2 Historical background and nomenclature .....	7
1.3 Classification of TMD .....	8
1.3.1 Research Diagnostic Criteria for TMD (RDC/TMD).....	8
1.3.2 Hungarian Health Professional Guideline.....	9
1.3.3 Wilkes classification .....	11
1.4 Symptoms .....	12
1.4.1 Pain.....	12
1.4.2 Mandible dysfunction .....	13
1.4.3 Sound phenomena.....	13
1.5 Diagnosis .....	14
1.5.1 Medical history .....	14
1.5.1.1 Visual Analogue Scale (VAS).....	14
1.5.1.2 Fonseca Anamnestic Index .....	15
1.5.2 Physical examination .....	16
1.5.3 Diagnostic imaging.....	17
1.6 Epidemiology of TMD .....	17
1.7 Etiology of TMD .....	19
1.8 Treatment modalities .....	20
1.8.1 Non-invasive treatment methods .....	21
1.8.1.1 Behavioral therapy.....	21
1.8.1.2 Drug therapy .....	21
1.8.1.3 Bite splints .....	22
1.8.1.4 Physiotherapy .....	23

1.8.2	Invasive treatment methods.....	24
1.8.2.1	Minimally invasive treatment methods .....	24
1.8.2.1.1	Arthrocentesis .....	24
1.8.2.1.2	Arthroscopy.....	24
1.8.2.1.3	Intraarticular injection treatment.....	25
1.8.2.1.3.1	Corticosteroids (CO).....	25
1.8.2.1.3.2	Hyaluronic acid (HA) .....	26
1.8.2.1.3.3	Platelet-rich plasma (PRP).....	27
1.8.2.1.3.4	Injectable platelet-rich fibrin (I-PRF).....	29
1.8.2.2	Open TMJ surgery .....	29
2.	OBJECTIVES .....	31
3.	METHODS.....	32
3.1	Patients .....	32
3.2	Pre- and postoperative measures and follow-ups .....	33
3.3	Treatment protocols.....	34
3.4	Statistical analysis .....	36
4.	RESULTS.....	37
4.1	Fonseca’s grade .....	37
4.2	Maximal mouth opening.....	38
4.2.1	Changes in different treatment groups .....	39
4.2.2	Difference between the efficacy of the treatment groups.....	40
4.2.3	Changes in MMO in different molecular weight hyaluronic acid groups .....	41
4.2.4	Difference between the efficacy of the two different molecular weight hyaluronic acid treatment groups .....	42
4.2.5	Assessment of the relapse.....	42
4.3	Visual Analog Scale .....	43
4.3.1	Changes in different treatment groups .....	44
4.3.2	Difference between the efficacy of the treatment groups.....	45
4.3.3	Changes in VAS in different molecular weight hyaluronic acid groups.....	46

4.3.4	Difference between the efficacy of the two different molecular weight HA treatment groups .....	47
4.3.5	Changes in VAS 1 week after each injection of consecutive HA treatment.....	48
4.3.6	Range of relapse related to VAS Values .....	49
4.4	Differences between short-term and long-term results.....	49
5.	DISCUSSION .....	50
5.1	The age and sex ratio .....	50
5.2	Fonseca’s grading system.....	51
5.3	The effect of substances on pain level and mouth opening.....	52
5.4	The different forms of hyaluronic acid.....	55
5.5	Relapse or further improvement in the disease and complications .....	56
5.6	Limitations and further considerations .....	57
6.	CONCLUSION .....	60
7.	SUMMARY .....	62
8.	REFERENCES.....	63
9.	BIBLIOGRAPHY OF THE CANDIDATE’S PUBLICATIONS .....	82
10.	ACKNOWLEDGEMENTS .....	84
11.	LIST OF FIGURES AND TABLES .....	85

## List of abbreviations

ASTJS:	American Society of Temporomandibular Joint Surgeons
CEP:	Clinical examination protocol
CO:	corticosteroids
ESZK:	Egészségügyi Szakmai Kollégium, Egészségügyért Felelős Államtitkárság (Health Professional College, State Secretariat for Healthcare Hungary)
HA:	hyaluronic acid
HA <sub>H</sub> :	high-molecular-weight hyaluronic acid
HA <sub>L</sub> :	low-molecular-weight hyaluronic acid
ID:	internal derangement
I-PRF:	injectable platelet-rich fibrin
MMO:	maximum mouth opening
NSAIDs:	non-steroidal anti-inflammatory drugs
PRP:	platelet-rich plasma
RDC/TMD:	Research diagnostic criteria for temporomandibular diseases
SSNRIs:	selective serotonin-norepinephrine reuptake inhibitors
SSRIs:	selective serotonin reuptake inhibitors
TENS:	transcutaneous electrical nerve stimulation
TMD:	temporomandibular joint disorders
TMJ:	temporomandibular joint
VAS:	Visual Analog Scale

# 1. Introduction

The temporomandibular joint is the only paired joint in our body that works in a coordinated, interconnected way (Gallatz, 2006). Generally speaking, when one side is affected pathologically in paired joints, the load on the other side is increased. In the case of the temporomandibular joint, our experience has shown that this fact is even more valid; that is why it is essential to identify and treat disorders affecting the temporomandibular joint as early as possible. Unfortunately, adequate diagnosis of temporomandibular joint lesions and initiation of the therapeutic process still mean challenges today among general practitioners and dentists. Patients often prefer to consult an ear, nose, and throat specialist or an orthopedic specialist due to the primarily extraoral localization of their symptoms, with less thought given to the presence of a dental background. In addition, the variety of symptoms and uncertain signs complicate the differential diagnosis. Consequently, patients often take months or years to receive appropriate care. This timeframe can have long-term deteriorative consequences. In addition to the diagnostic difficulties, there is no uniform protocol for therapy. Using various materials and applying different methods have led to decades of divergent opinions in the literature (Li & Leung, 2021).

Although it is challenging to provide epidemiological data, the prevalence of TMD in the adult population is between 10% and 70%, and its incidence increases yearly (Klatkiewicz et al., 2018; Li et al., 2012). Furthermore, according to the latest Hungarian Health Professional Guideline, TMD occurs with a lower but similar frequency to low back pain (ESZK, 2020). Therefore, it can be concluded that chronic TMD is a growing social problem. Medical costs, including painkillers and surgical fees, missing from work, and deteriorating quality of life contribute to a social burden.

Furthermore, contrary to other degenerative joint diseases, the disorder does not only affect the elderly; it also affects up to one-third of the working younger people (Mountziaris et al., 2009). For these reasons, seeking a rapid, simple, and less harmful solution for this disease is crucial to achieving a painless, functional condition as long as possible.

As more and more knowledge has been acquired about the disease and its importance, several professional developments have taken place in Hungary in the last ten years: a Gnathology textbook has been published and introduced into undergraduate education, a professional guideline of gnathology has been published, and a Hungarian Gnathology Society has been established. These efforts aim to ensure that the recognition and treatment of this previously poorly known disease are more widely and uniformly available and that patients receive appropriate care as quickly as possible. In many cases, monotherapy cannot achieve a successful outcome; thus, working with other professionals is essential. Furthermore, minimally invasive and invasive techniques in oral surgery are increasingly becoming an unavoidable part of interdisciplinary therapy and are, therefore, subjects of many research projects internationally (Li & Leung, 2021).

Our research aims to investigate intra-articular treatment methods and to select the material and protocol with the best results for achieving long-term therapeutic efficacy in our patients. To this end, we compared the pre-and postoperative pain and mouth-opening scores for different materials in intraarticular treatment and considered lesion severity to assess the therapeutic efficacy.

This chapter will introduce our research by discussing the background of temporomandibular disorders, then focusing on the research problem, and finally, the topic's significance.



## 1.2 Historical background and nomenclature

Temporomandibular joint disorder (TMD) is a broad umbrella term for disorders of the orofacial region that affect the joint, the surrounding muscles, and soft tissues (Warburton, 2021). We know from archaeological evidence that recognizing and treating certain joint disorders, especially pathological conditions of the temporomandibular joint, goes back thousands of years (Vasconcellos & Vasconcellos, 2006). However, due to its complexity, the subject of the present research, the internal derangement of the TMJ, was first studied and described only in the 20th century (Uyanik & Murphy, 2003). There are many terms for this condition of the TMJ in the literature. The first accurate descriptor of temporomandibular dysfunction was James B. Costen, an otolaryngologist, who described a syndrome of pain around the head and temporomandibular joints, trismus, ear symptoms, such as tinnitus, and impaired hearing in 1934 (Costen, 1934). Thus, this type of facial pain was named Costen syndrome after him. Although much more detailed information about the disorder has been published since then, the term Costen syndrome is still used today because of his significant findings. The relationship between occlusion and facial pain became the focus of attention. Based on Costen's observations, the primary treatment modality was considered to be the restoration of the bite, as occlusal discrepancies were found to be the primary etiological factors (List & Jensen, 2017; Rani et al., 2017).

Later, several other names were given, among others: 'functional temporomandibular disturbances,' 'temporomandibular pain-dysfunction syndrome,' 'myofascial pain-dysfunction syndrome' (Ramfjord & Ash, 1971; Schwartz, 1959; Laskin, 1969). Laskin changed the approach to the etiology of dysfunction since he observed the role of chronic oral habits and emotional stress (Laskin, 1969). Therefore, stress became the main etiological contributor to muscle spasms, fatigue, and pain (Uyanik & Murphy, 2003; Rani et al., 2017).

In the 1970s, Farrar, Wilkes, and McCarty studied intra-articular lesions, investigating the condyle-disc relationship (McCarty & Farrar, 1979; Uyanik & Murphy, 2003). Meanwhile, Rugh and Solberg continued to study the phenomenon of stress-induced muscle spasms (Rugh & Solberg, 1976). Finally, in 1980, McNeill proposed the term 'craniomandibular disorders', which goes beyond the anatomical boundaries of the joint (McNeill et al., 1990). The term 'temporomandibular disorders,' adopted by the American

Dental Association in 1983 and still widely used today, was first used by Bell (Okeson & Bell, 1995).

The theory of internal derangement was formulated in 1953; however, it was only accepted in the 1970s when various imaging techniques, such as arthrography, became widespread in the diagnostic processes of the temporomandibular joint (Uyanik & Murphy, 2003).

### **1.3 Classification of TMD**

TMD can cover a wide range of joint lesions, and the classification is also diverse in the literature; several classifications have been described over the years. In the past, classifications that attempt to categorize temporomandibular joint pathologies have been published. However, due to the need for uniformized diagnostic criteria and different terms related to TMD, it took much effort to distinguish the symptoms and the causes of the lesions from each other (Li & Leung, 2021).

One of the most commonly used diagnostic systems was the Helkimo index, which consisted of 3 indexes: anamnestic, clinical dysfunction, and occlusion (Helkimo, 1974). It was the first index to assess the severity and pain in TMD; however, it was still not quite sensitive and did not differentiate between muscle and joint lesions. The more recent classifications became symptom- and function-specific.

Modern classifications agree in distinguishing between muscular and intra-articular lesions (Poveda et al., 2008). In contrast to Bell's classification, which is referred to by many authors but didn't include the myofascial pain diagnosis, further developments by Okeson, Kaplan, and the American Academy of Orofacial Pain described myofascial pain as a separate condition (Poveda et al., 2008; Okeson, 1996). In Hungary, Angyal presented his classification of muscle and articular-related lesions separately, and subgroups were distinguished according to their clinical characteristics (Angyal, 2002).

#### ***1.3.1 Research Diagnostic Criteria for TMD (RDC/TMD)***

The 'Research Diagnostic Criteria for TMD (RDC/TMD),' published by LeResche and Dworkin in 1992, was a milestone in the diagnosis of TMD (Dworkin & LeResche,

1992). It has been the most widely applied diagnostic protocol for TMD research and clinical practice, with the benefit of separating the subtypes of chronic TMD lesions (Schiffman et al., 2014). Over the next two decades, this diagnostic scheme provided a reasonable basis for international scientific publications (Ohrbach & Dworkin, 2016).

The RDC/TMD represents temporomandibular diseases in a biaxial system. Physical factors are represented on Axis I, while psychosocial factors are represented on Axis II. According to Axis I, the diagnosis of TMD can be divided into three groups: myofascial pain with and without mouth opening restriction, reversible and irreversible disc dislocation, and arthralgia, osteoarthritis, and osteoarthrosis (Table 1).

A simplified version of the RDC/TMD, the Clinical examination protocol (CEP), has been developed by a research team at Newcastle University and is now a symptom and even more function-specific classification. This system is less complicated and can be performed in a shorter time (Schiffman et al., 2014).

**Table 1.** Classification of RDC/TMD, Axis I. (Dworkin & LeResche, 1992)

<p><b>Group I: Muscle disorders</b>  I.a. Myofascial pain  I.b. Myofascial pain with limitations in aperture</p> <p><b>Group II: Disc displacement</b>  II.a. Disc displacement with reduction  II.b. Disc displacement without reduction and no limitations in opening  II.c. Disc displacement without reduction with limitations in opening</p> <p><b>Group III: Arthralgia, arthritis, arthrosis</b>  III.a. Arthralgia  III.b. Osteoarthritis of the TMJ  III.c. Osteoarthrosis of the TMJ</p>
---

### **1.3.2 Hungarian Health Professional Guideline**

The classification, accepted by the Hungarian Egészségügyi Szakmai Kollégium (ESZK), distinguishes three main groups related to the joint, the masticatory muscles, and headache. It describes several subgroups seen in Table 2 (ESZK, 2020).

**Table 2.** Classification scheme of temporomandibular diseases (ESZK, 2020)

<p><b>1. Lesions affecting the joints</b></p> <p>Painful joint disorders</p> <ul style="list-style-type: none"> <li>Arthralgia</li> <li>Arthritis</li> </ul> <p>Joint dysfunctions:</p> <ul style="list-style-type: none"> <li>Disc displacement with or without reduction</li> <li>Hypomobility or hypermobility</li> <li>Adhesion</li> <li>Fibrotic ankylosis</li> <li>Bony ankylosis</li> <li>Coronoid process hyperplasia</li> <li>Subluxation or luxation of the temporomandibular joint</li> </ul> <p>Fractures</p> <ul style="list-style-type: none"> <li>Condylar or subcondylar, closed or open fracture</li> </ul> <p>Congenital and developmental anomalies</p> <ul style="list-style-type: none"> <li>Aplasia</li> <li>Hypoplasia</li> <li>Hyperplasia</li> </ul> <p><b>2. Abnormalities affecting the masticatory muscles</b></p> <p>Muscle pain in the orofacial region</p> <ul style="list-style-type: none"> <li>Myalgia</li> <li>Tendonitis</li> <li>Myositis</li> <li>Spasm</li> <li>Contracture</li> <li>Hypertrophy</li> <li>Neoplasm</li> </ul> <p>Movement disorders</p> <ul style="list-style-type: none"> <li>Orofacial dyskinesia</li> <li>Oromandibular dystonia</li> </ul> <p>Chewing muscle pain associated with systemic diseases</p> <ul style="list-style-type: none"> <li>Fibromyalgia</li> <li>Centrally mediated myalgia</li> </ul> <p><b>3. TMD-related headache</b></p> <p>One of the new categories developed by the International Network for Orofacial Pain and Related Disorders Methodology (INfORM) research group refers to headaches associated with myalgia or arthralgia (Schiffman et al., 2014).</p>
--

### ***1.3.3 Wilkes classification***

Our study investigated intra-articular lesions that gnathological methods cannot regenerate. Internal derangement (ID) refers to an altered, pathological relationship between the disc and the condyle, a concept adopted from orthopedics (Warburton, 2021). In the 1970s and 80s, mechanical causes, and thus disc displacement, were considered the leading cause of ID and consequent joint degeneration (Anderson et al., 1991; Warburton, 2021). The condition was treated accordingly, with surgical reconstruction of the disc position (Warburton, 2021). However, it was later realized that disc abnormalities are not closely related to the symptoms of ID patients. Many individuals have an abnormal disc position but still have no complaints because the body has adapted to the abnormal position (Warburton, 2021).

Wilkes classification, described by Wilkes in 1989, provides a classification system for determining the degree of the ID of the joint. This system's stages range from one to five and severity from early to late (Wilkes, 1989). Wilkes concluded from his studies that the degree of degenerative joint lesions and the clinical picture are closely related to radiological and surgical findings. Classification into stages is also an indication of the prognosis of the disease (Wilkes, 1989).

The first, early stage, is clinically defined as painless clicking, no other physical symptoms, and no pain. Imaging shows intact disc contours, possibly with slight displacement, but also with normal morphology (Wilkes, 1989).

In the second, early-to-moderate stage, occasional painful clicking, headaches, and intermittent mouth closure may occur. The disc shows mild deformity, and the bone contours show physiological structure (Wilkes, 1989).

In the third, moderate stage, pain and joint tenderness become frequent, joint movement is reduced, and there is pain during function and chewing. Finally, the disc shows mild to moderate deformity with no bony lesions (Wilkes, 1989).

Chronic pain, headaches, and limited mobility characterize the fourth, moderate-late stage. The disc and bone are also significantly affected, with degenerative lesions, adhesions, and osteophytes (Wilkes, 1989).

The fifth, or late stage, is characterized by chronic pain and loss of function, which may be associated with disc perforation and severe degenerative changes (Wilkes, 1989).

## **1.4 Symptoms**

The signs and symptoms of TMD may be objective and subjective.

Three major symptoms are distinguished, of which the presence of at least one is required for a clinical diagnosis; these symptoms are pain, mandibular dysfunction, and sound phenomena listed below (Szentpétery et al., 1987).

Minor symptoms that may predict the disease include headache, ear complaints (tinnitus), tooth wear, neck and shoulder pain, or even waist, hip, or knee joint dysfunction (Jász & Schmidt, 2018).

### ***1.4.1 Pain***

According to some authors, the most common symptom of TMD reported by patients is unilateral facial pain, which may radiate to different parts of the orofacial area, including the temporal or periorbital region, the mandibular angle, or even to the back of the neck (Conti et al., 2012, Scrivani et al., 2008). The pain is usually dull and can get worse at certain times of the day. Mandibular movements may trigger sharp, more severe pain. Pain may be continuous, or it might occur periodically. Usually, there are pain-free intervals as well (Scrivani et al., 2008).

Pain may arise from the joint, which is called arthralgia, or from the masticatory muscles, and it is important to separate them. Arthralgia originates in the nociceptive receptors of the joint capsule, ligaments, and bilaminar zone. The pain mainly felt during joint movements is localized precisely and can be triggered by pressure. In the case of chronic dysfunction, pain also occurs at rest due to inflammatory mediators associated with synovitis and capsulitis (Jász & Schmidt, 2018).

Myalgia is pain arising from the masticatory muscles, caused by local spasms due to the increased loading of the muscles, and the factors related to the central nervous system can also be in the background. It can be less localized but also can be provoked. Myofascial pain disorder is the most common of all functional disorders regarding TMJ (Scrivani et al., 2008).

#### ***1.4.2 Mandible dysfunction***

Abnormalities of mandibular movement include impaired and asymmetrical mouth opening and closing. In case of deviation, the midline deviates at the beginning of mouth opening and then returns at closing, usually accompanied by an audible click (Jász & Schmidt, 2018). In deflection, the midline is displaced during whole mouth opening, usually with limited mouth opening and severe pain (Jász & Schmidt, 2018).

Restricted mouth opening can be caused by muscle tension and intracapsular disorders, in which passive mouth opening is impossible. The international literature varies in defining the extent of normal mouth opening; according to Scrivani, the value ranges between 35-55 mm, with a mean of 40 to 43 mm (Scrivani et al., 2008).

#### ***1.4.3 Sound phenomena***

An essential consideration in assessing articular sounds and disc position is that an audible or palpable murmur alone, without pain or loss of function, does not necessarily represent a pathological process (Kircos et al., 1987). However, the term reciprocal clicking is a sound phenomenon that is important to recognize, because it is related to the changes in the position of the articular disc (Derwich et al., 2021a). In addition, disc displacements have been found to be associated with degenerative joint disorders (Derwich et al., 2021a). The articular disc is in front of the condyle in maximal mouth closure. In the initial part of the mouth opening, the affected lateral condyle cannot move forward. On palpation, the affected side does not follow the intact side, with the midline deviating towards the diseased side. During the middle third of the opening, there is usually an audible click (opening click); when the discus jumps into place, the midline returns to the median sagittal plane, and the rest of the opening proceeds normally. The closure process is similar. It starts regularly and in the terminal part of the process, accompanied by another click on the affected side (closing click). Thus, the lesion's main feature is the reciprocal click, which occurs in the middle third of each opening and the terminal phase of each closing.

## 1.5 Diagnosis

### 1.5.1 Medical history

As a first step in diagnosing temporomandibular joint dysfunction, it is essential to take a detailed medical history of the patient. The examining doctor or dentist must have an accurate picture of the onset of the dysfunction, subjective complaints, and previous temporomandibular joint treatments. It is also necessary to consider any psychological and physical trauma and any underlying psychological factors that may contribute to the diagnosis. During the history taking, the following questions are asked: intensity, location, and frequency of the pain experienced, triggers and alleviating factors, and other complaints (for instance, tinnitus or headache) (Warburton, 2021). A common complaint is restricted movement of the jaw joint, with the feeling of the joint getting "locked" when the mouth is open or closed. These symptoms are often more severe in the morning, especially for those who grind or squeeze at night during sleep (Scrivani et al., 2008). Investigating sleep patterns may also reveal the presence of initiating etiological factors and other parafunctions (Warburton, 2021; Scrivani et al., 2008).

#### 1.5.1.1 Visual Analogue Scale (VAS)



**Figure 1.** Visual Analog Scale (VAS).  
Patients need to mark their pain level on the scale (Hayes & Patterson, 1921)

The Visual Analogue Scale (VAS) is a commonly used pain rating scale described in 1921 by Hayes and Patterson (Hayes & Patterson, 1921). With that tool, the intensity or frequency of pain experienced by patients can be measured. The pain described can range from none ('0' value) to extreme pain ('10' value).

The pain score is in millimeters starting from the 0 value (Figure 1).



### 1.5.1.2 Fonseca Anamnestic Index

The Fonseca Anamnestic Index is a questionnaire introduced in 1994 that considers the patient's psychological background and objective symptoms (Fonseca et al., 1994). It is a 10-question questionnaire to grade the disorder: non-TMD, mild, moderate, or severe TMD (Fonseca et al., 1994; Stasiak et al., 2020), (Table 3). Its quick completion provides a fast and reliable indication of the TMJ disease and its extent (Campos et al., 2014; Bicaj et al., 2017). The questionnaire was translated into the Hungarian language. There were ten questions to answer: No, Sometimes, and Yes, and in the end, the total score gives the severity grade.

**Table 3.** Fonseca questionnaire. 0-15: no TMD, 20-40: mild TMD, 45-65: moderate TMD, 70-100: severe TMD (Fonseca et al., 1994)

	No	Sometimes	Yes	Score
<b>Do you have difficulty opening your mouth wide?</b>				
<b>Do you have difficulty moving your jaw to the side?</b>				
<b>Do you feel fatigued or have muscle pain when chewing?</b>				
<b>Do you have headaches?</b>				
<b>Do you have neck pain or a stiff neck?</b>				
<b>Do you have earaches or pain in that area (temporomandibular joint)?</b>				
<b>Have you ever noticed any noise in your temporomandibular joint while chewing or opening your mouth?</b>				
<b>Do you have any habits such as clenching or grinding your teeth?</b>				
<b>Do you feel that your teeth do not come together well?</b>				
<b>Do you consider yourself a tense (nervous) person?</b>				
<i>Total score</i>				

### 1.5.2 Physical examination

During the physical examination of the temporomandibular joint, inspection, palpation, and auscultation are performed simultaneously.

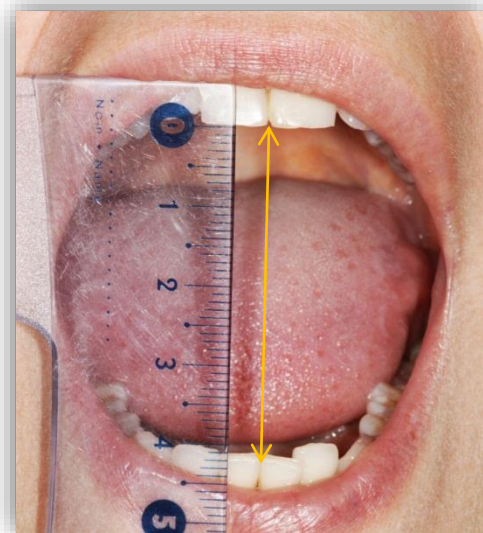
It is essential to inspect the patient, who often presents with lordosis of the back, kyphosis of the neck, dorsal displacement of the mandible, restricted jaw joint movements, and deviation or deflection when opening the mouth.

The extraoral examination reveals the tension and sensitivity of the muscles of mastication at rest and during function. In addition, the origin of the temporal muscle can be palpated, as well as the full extent of the medial pterygoid and masseter muscles. Inhomogeneous consistency, nodes, painful adhesions, and significant lateral deviation are signs of TMD. Palpation of the joint is performed on both sides in parallel, palpating the displaced condyles simultaneously. In normal conditions, the same displacement is palpated on both sides during symmetrical movements such as mouth opening and protrusion. At the same time, the midpoint between lower central incisors is displaced caudally or anteriorly, remaining in the median sagittal plane. Alterations from these may indicate a pathological lesion.

The physical examination also includes a provocation examination of the joint, revealing joint sensitivity in addition to the palpation examination.

The examination of joint resilience gives an approximate indication of the state of the articular disc.

The intraoral examination measures the maximum mouth opening in millimeters (Figure 2), the lateral range of motion in relation to the midline, and the degree of the protrusion. Also, we should note any abrasion of the teeth or chronic cheek or tongue biting to reveal habitual factors in the background.



**Figure 2.** MMO

Note. Photo of examination of maximal mouth opening. Own work.

### **1.5.3 Diagnostic imaging**

The spectrum of imaging studies for correctly visualizing the temporomandibular joint is limited.

Conventional X-rays and OPG images do not provide sufficient information on the condition of the soft tissues and the articular disc. Likewise, CT and CBCT imaging, although more sensitive methods and more detailed images can be obtained, still only show bone morphology (Scrivani et al., 2008).

The magnetic resonance imaging (MRI) technique has become popular in examining the temporomandibular joint due to its ability to prevent radiation exposure and highly accurate soft tissue-hard tissue junction imaging. In addition, the position and the structure of the articular disc can be observed even during movement, making it very useful for investigating dysfunction with 90% accuracy (Scrivani et al., 2008).

Arthroscopy has been used since the 1980s as a diagnostic and therapeutic method, which can be used to examine the joint surfaces, the disc, and intra-articular lesions, such as erosion, abrasion, and perforation (Murakami, 2013).

In addition, examining synovial fluid can provide an accurate picture of intra-articular inflammatory processes and joint destruction based on the mediators, cells, proteins, and detritus obtained by puncture (Matsumoto et al., 2006; Murakami, 2013).

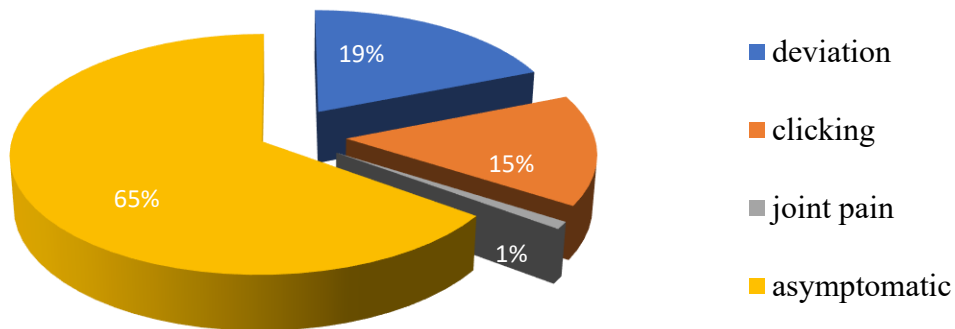
## **1.6 Epidemiology of TMD**

Temporomandibular joint disorders are considered the most common non-dental cause of orofacial pain (Li & Leung, 2021). However, data on the prevalence of this disease in the literature are different due to the diversity of diagnostic tools and pathology. Furthermore, the variety and severity of symptoms and the lack of a uniformized diagnostic system lead to many people not having access to appropriate care or not consulting their doctor about their symptoms. As a result, we find extreme data in the literature.

According to ESZK, in the international literature, the proportion of patients with TMD and headaches of TMD origin is 5 to 77.2% (ESZK, 2020). We can see that this rate is very extreme. Looking more closely at the problem, a systematic literature review

of the number of cases diagnosed according to the RDC/TMD criteria identified articular disc dysfunction in 16% of the population and arthralgia in 9% (ESZK 2020). A study from 2008 found that the proportion of people who require treatment is 16% (Al-Jundi et al., 2008).

There is also no current, accurate information on epidemiological data in Hungary. In a national study conducted in 2009, 19% of participants showed deviation in one direction, 15% complained of joint clicking, and 1% complained of joint pain (Figure 3). The study found that 1% of the population needs treatment (Jász et al., 2009).



**Figure 3.** Prevalence of TMD in Hungary (Jász et al., 2009)

Evaluating epidemiological data is also complicated because asymptomatic individuals may show radiologically proven temporomandibular disc abnormalities, which some data suggest may be as high as 35% of the population (ESZK, 2020).

In contrast to osteoarthritis of the large joints in old age, the disease most commonly affects young and middle-aged adults. According to some authors, it occurs most frequently between the ages of 20 and 40 (Manfredini & Guarda-Nardini, 2010); however, some studies reported an average age of over 40 (Sousa et al., 2020; González et al., 2021).

There are slight differences in the gender distribution of the disease in the literature. Still, the consistent finding is that women visit their doctors more often than men with complaints arising from their temporomandibular joints (Pihut & Gala, 2021; Poveda et al., 2007; Huber & Hall, 1990). The incidence of temporomandibular joint pain is suggested to be 9-15% in women and 3-10% in men (Sousa et al., 2020). The male-to-female ratio of patients consulting a doctor ranges from 1:3 to 1:9 (Jerolimov, 2009).

### **1.7 Etiology of TMD**

The etiology of TMD is also very diverse in the literature. There is no consensus on which etiological factor(s) may play a direct and verifiable role in the disorder's pathogenesis; therefore, it can be described as a lesion with a multifactorial background. It is known that the development of the ID is the end point of a degradation process in which certain biomechanical factors play a role (Warburton, 2021).

According to some classifications, trauma, anatomical factors (e.g., the inclination of the articular eminence, skeletal and dental occlusal abnormalities), general and local pathophysiological factors (previous oral surgery, rheumatologic, neurologic, pathophysiologic factors), and psychosocial factors (e.g., depression, anxiety, stress) play a significant role in the development of dysfunction (Schmidt, 2018).

Other authors have suggested that micro- and macro-trauma affect the joint and systemic arthropathies (Sjögren's, RA, psoriasis, etc.) play a primary role in the etiology of TMD (Warburton, 2021). Alternatively, overloading the intact joint by parafunction or trauma or normal loading of the abnormal joint, such as systemic joint lesions, can be considered an alternative classification. In addition, painful dysfunction seems to be more common in patients, primarily women, when macro trauma with parafunction is a contributing factor (Huang et al., 2002). Smoking has also been reported as a risk factor, as some research associated it with higher pain intensity, psychosocial disorders, and sleep problems (Sanders et al., 2012).

Occlusion was previously considered a primary cause; however, it is not a proven etiological factor (Poveda et al., 2007).

Among occlusal abnormalities, only the absence of a posterior support zone and unilateral crossbite are considered proven etiological factors in the development of TMD (Türp & Schindler, 2012).

In conclusion, the biopsychological aspect of this question is the most popular theory, which includes the biological, psychological, and social factors in the background of TMD (Conti et al., 2012).

### **1.8 Treatment modalities**

TMD is a multicausal condition that, unlike other joint disorders more common in older age, can affect adolescents and young adults in large numbers. However, effectively reducing pain and restoring dysfunction remains a complex task.

An essential element in managing TMD is the choice of an individualized approach that provides the most appropriate therapeutic outcome according to the disease process present. However, many types of treatment, conservative and surgical, are used, and therefore, we need strong evidence-based data to determine the most appropriate protocol.

Due to the multicausal nature of the disease, it, therefore, requires a complex treatment, which makes it the role and responsibility of every dentist to recognize the condition and pay attention to the symptoms.

In the 1970s and 1980s, open TMJ surgery became popular, but several severe surgical complications occurred. As a result, previously popular surgical procedures have been replaced by focusing on less invasive methods due to their lower morbidity and significantly higher reliability (Uyanik & Murphy, 2003; Li & Leung, 2021).

Most patients with TMD can be successfully treated conservatively, and only a minor proportion of cases require surgical intervention (ESZK, 2020).

In some terminology, the treatment of TMD is divided into surgical and non-surgical, while in Hungary, non-invasive/conservative and invasive terms are used (ASTJS, 2003; ESZK, 2020).

### ***1.8.1 Non-invasive treatment methods***

According to the recommendations of the American Society of Temporomandibular Joint Surgeons and the recent Hungarian guideline, non-surgical therapy includes behavioral therapy; a proper diet to avoid the strain of forced chewing; pharmacotherapy, such as painkillers, NSAIDs, muscle relaxants; dental treatments, such as replacing bad dental work and using a bite splint (ASTJS, 2003; ESZK, 2020). Physiotherapy mainly includes temporomandibular muscle training exercises, TENS, and soft-laser treatment. Therapy with these methods should be considered for all patients, and treatments alone may be effective for mild to moderate pain and dysfunction.

However, in cases where severe pain and dysfunction do not resolve within 2-3 weeks of conservative therapy, surgical consultation is indicated (ASTJS, 2003).

#### ***1.8.1.1 Behavioral therapy***

Diet means eating soft foods that allow the joint to rest and heal. Chewy, crunchy foods or large bites that cause the mouth to open too wide should be avoided.

The role of parafunctional activities in the development and maintenance of TMD is still subject to studies. However, it is a fact that the patient's engagement and compliance in therapy and the elimination of bad habits are unquestionable.

Behavior change can be targeted through cognitive behavioral therapy, stress management, lifestyle counseling, hypnosis, and biofeedback (ESZK, 2020).

#### ***1.8.1.2 Drug therapy***

Drug therapy can effectively relieve pain associated with temporomandibular joint disorders but can also lead to overdose and abuse (ESZK, 2020). The most commonly used drugs are analgesics, non-steroidal anti-inflammatory drugs, corticosteroids (only for acute pain), muscle relaxants, and low-dose antidepressants.

Non-steroidal anti-inflammatory drugs (NSAIDs) are effective in mild to moderate inflammatory conditions due to their analgesic and anti-inflammatory effects. Ibuprofen is recommended as the first-line agent of choice due to its mild side effects, but continuous monitoring of patients is recommended.

Systemic administration of corticosteroids is only advisable in severe acute arthritis, as long-term use may lead to severe joint destruction (ESZK, 2020).

Muscle relaxants are particularly effective when the individual is grinding or clenching. A commonly used muscle relaxant is Mydetone. Some studies explain its effect not by muscle relaxant property but rather by sedative effect. However, its efficacy in treating TMD has yet to be proven (ESZK, 2020).

Anti-anxiety drugs are known to be used in chronic pain, which is crucial because it is known that stress can contribute to the development and worsening of dysfunction. Although, the ESZK recommends that it can have the opposite effect, namely exacerbating depression and addiction (ESZK 2020).

Antidepressants act as analgesics in low doses (ASTJS, 2003). Research has shown that amitriptyline can significantly reduce chronic muscle pain and TMD symptoms (Calderon et al., 2011; Plesh et al., 2000). Selective serotonin reuptake inhibitors (SSRIs) and selective serotonin-norepinephrine reuptake inhibitors (SSNRIs) have also been shown to be effective in TMD therapy (Gebhardt et al., 2016).

### ***1.8.1.3 Bite splints***

The bite splints prevent the patient from grinding or clenching, placing the joint in a resting, unloaded position where it can relax with the muscles. Bruxism may be essential in developing dysfunction because it damages the joint and causes pathological changes through dental attrition and, consequently, malocclusion, myofascial tension, masticatory muscle fatigue or fibrosis, capsulitis, and adhesions in the joint space (Ingawalé & Goswami, 2009). Bite splints control bruxism and effectively reduce pain, but their usage is still controversial (Scrivani et al., 2008). Therefore, bite splints should only be used after a proper and careful diagnosis.

Several types of occlusal splints are available based on their function, dimensions, and material. By function, stabilization occlusal splints are made for the lower or upper arch. Studies have shown that wearing them at night effectively reduces muscle and intracapsular pain (Linde et al., 1995).

Repositioning splints guide the mandible into a new resting position. The main indication is reversible dislocation of the disc (ESZK, 2020).



Partial and complete arch splints have been developed, although there is limited available evidence on the benefits of partial splints. Their superiority over complete arch splints has yet to be proven, but the potential complications have been described (ESZK, 2020).

The hard acrylic stabilization splint is believed to be more effective in reducing bruxism than the soft splint. Soft splints are more difficult to adjust and may increase clenching behavior in some patients (Goldstein & Auclair Clark, 2017).

#### ***1.8.1.4 Physiotherapy***

The most commonly used branches of physiotherapy are kinesiotherapy, phototherapy, and electrotherapy.

There have been many studies on laser treatment, but the experience is very controversial. It can be assumed that soft laser treatment increases blood circulation and stimulates the immune system (Wilder-Smith, 1988). Soft laser irradiation of the joint's skin and painful muscle knots is recommended (Herpich et al., 2015).

In 1988, Bezuur, Habets, and Hansson observed an 80% reduction in pain intensity in laser-treated joints (Bezuur et al., 1988), and Hansson, in 1989, observed a rapid anti-inflammatory effect of the infra laser (Hansson, 1989). However, a meta-analysis found no efficacy of low-intensity laser therapy (Gam et al., 1993). Similar to the studies mentioned above, Conti found no significant difference between the placebo and laser group responses to treatment (Conti, 1997).

Transcutaneous electrical nerve stimulation (TENS) is the most widely used electrotherapeutic method. A study concluded that TENS is effective for mild pain with a slight reduction in function or muscle tension and tenderness; it might also be helpful as an adjunct treatment in more severe cases (Jász et al., 2009).

Movement therapy methods can only be carried out by a physiotherapist. However, relaxation-breathing therapy methods and movement exercises that, if practiced with patients who have identified any daily bad habits (such as grinding and clenching), will help them relax their joints and muscles in their everyday lives.

## ***1.8.2 Invasive treatment methods***

Minimally invasive and invasive methods have an essential role in the treatment of temporomandibular joint disorders. Although different surgical approaches are often proposed in the literature for the same conditions, knowing which method is the most effective when surgery is needed to treat dysfunction is necessary. The indication for surgical intervention depends on the severity of the disorder, the extent of the expected benefits, and the level of impairment of the patient's daily life (ESZK, 2020).

According to the Hungarian and the American Society of Temporomandibular Joint Surgeons guidelines, surgical therapy is only indicated when conservative treatments have failed to improve the condition (ASTJS, 2003; ESZK, 2020).

### ***1.8.2.1 Minimally invasive treatment methods***

#### ***1.8.2.1.1 Arthrocentesis***

Some authors consider arthrocentesis the simplest form of invasive surgery, the least risky surgical approach; it can also be performed under local anesthesia, even in outpatient care (Carvajal & Laskin, 2000). It consists of washing the affected joint area with a sterile fluid using needles to remove necrotic debris, blood, and inflammatory products (Barkin & Weinberg, 2000). Indications for arthrocentesis include internal joint derangement, disc displacement with or without reduction, trismus or limited mouth opening, and joint pain (Frost & Kendell, 1999; Nitzan et al., 1991).

#### ***1.8.2.1.2 Arthroscopy***

Arthroscopy is an explorative and less invasive endoscopic therapeutic modality. Ohnishi was the first who described temporomandibular joint arthroscopy in the 1970s. The method allows visual inspection of the joint space and provides information on the position of the disc, synovium, articular cartilage, and possible adhesions (Ohnishi, 1990).

In addition to diagnostics, it offers therapeutic options for internal derangement, degenerative diseases, synovitis, TMJ hyper-, and hypomobility (Tvrđy, 2007). During the procedure, a thin device carrying a lens and light is inserted into the affected area through a small incision in front of the ear to the upper compartment of the joint space,

so that the synovial area can be observed; it can be used to release small adhesions and rinse the joint, as well as for possible collection of samples.

#### ***1.8.2.1.3 Intraarticular injection treatment***

However, in the national terminology, intra-articular treatment is considered the first step of invasive therapy; it is a treatment method between non-invasive and invasive surgery. Intra-articular therapy is used for patients with unfavorable results with non-invasive methods (Sousa et al., 2020).

Minimally invasive intra-articular injection treatment combines the advantages of the abovementioned methods and eliminates the disadvantages. Compared to systemic administration, using locally administered medicines has many benefits, such as greater bioavailability, less systemic side effects, and cost-effectiveness.

We know from orthopedics that the prevalence of both single-joint and multi-joint chronic lesions (osteoarthritis, rheumatoid arthritis) is very high and that the aim of their treatment is long-term symptom-free condition. Therefore, successful local administration of drugs can be a huge step forward in maximizing efficacy and reducing drug costs (Evans et al., 2014).

Several different materials can be injected into the joint, in single or multiple sessions, as listed below.

##### ***1.8.2.1.3.1 Corticosteroids (CO)***

In most cases of temporomandibular joint disorders, a chronic inflammatory process of varying degrees is present due to abnormal movements, joint loads, and a damaged joint surface. The corticosteroid is a well-known anti-inflammatory agent with potent effects. One of the essential effects of corticosteroids in intra-articular therapy is the inhibition of both early and late manifestations of inflammation. In areas of acute inflammation, leukocyte migration and activity are reduced; in chronic inflammation, mononuclear cell activity is reduced, and vascular proliferation and fibrosis are moderated (Torres et al., 2020). In addition, they inhibit the accumulation of macrophages

and neutrophils in inflammation areas by suppressing the expression of endothelial adhesion molecules and the synthesis of plasminogen activators (Torres et al., 2020).

Corticosteroids have been used for joint injections since the 1950s (Horton, 1953). They can be used after arthrocentesis and arthroscopy to reduce edema and local pain. They are also used as injections alone in acute inflammatory cases or acute flare-ups of chronic inflammation (Vaszilkó, 2018).

The protocol for intra-articular corticosteroid therapy in the literature varies (Alpaslan & Alpaslan, 2001; Mountziaris et al., 2009). A single injection protocol is known (Toller, 1977; Stoustrup, 2015), and two injections 14 days apart (Bjørnland et al., 2007). Multiple injections are not recommended due to the potential for side effects, which can be the progression of the articular destruction (Toller, 1977). Proving this fact, studies have suggested that a single corticosteroid injection benefits patients with severe TMJ pain. In contrast, further injections do not have an additional pain-relieving effect but also may increase the risk of joint degeneration and other complications (Schindler et al., 2005).

In the intraarticular management of the temporomandibular disorder, the most commonly used corticosteroids are methylprednisolone, hydrocortisone, dexamethasone, betamethasone, prednisolone, and triamcinolone (Wernecke et al., 2015).

The efficacy of intra-articular corticosteroid injections can range from 3-4 weeks to half a year (Toller, 1977; Bjørnland et al., 2007; Stoustrup et al., 2008).

#### ***1.8.2.1.3.2 Hyaluronic acid (HA)***

Hyaluronic acid is a glycosaminoglycan polysaccharide produced by chondrocytes and synovial cells within the joints, and it is the synovial fluid's most important natural component (Duygu et al., 2011). Its mechanical action is based on the process of lubrication, i.e., moisturization; as a lubricant, it reduces the friction of the joint surfaces and bony structures, thus reducing their wear and secondary adhesions in the joint space (Duygu et al., 2011). Furthermore, among its metabolic properties, hyaluronic acid reduces the number of inflammatory mediators through its anti-inflammatory effect, thus contributing to the relief of joint pain and helping to nourish the disc and the avascular part of the cartilage through its metabolic regulatory role (Escoda-Francolí et al., 2010).

Although it plays a significant role in the lubrication and metabolic regulation of the joint, the exact mechanism still needs to be fully understood (Bjørnland et al., 2007).

Given that the lifetime of HA is relatively short, different theories have been proposed about its effects. Some believe the long-term effect is due to viscosupplementation, while others believe the short-term lubricating effect disrupts inflammatory and tissue-damaging processes (Hepguler et al., 2002; Yeung et al., 2006).

It has been suggested that hyaluronic acid can enhance chondrocyte proliferation and differentiation (Moreland, 2003). In addition, according to some research, it can also replace the naturally high molecular weight endogenous HA in the damaged joint (Ferreira et al., 2018; Cömert, 2021; Hosgor, 2020).

Two ways of using hyaluronic acid have emerged from previous studies: either alone for viscosupplementation or as an adjunct to surgical intervention (Alpaslan & Alpaslan, 2001). Both methods aim to alleviate pathological symptoms and reduce inflammation.

Several protocols are also known within the administration: single administration, 2-dose, 3-dose, and 5-dose with a 7-day interval (Guarda-Nardini et al., 2005; Basterzi et al., 2009; Manfredini et al., 2012).

Currently, there are products containing hyaluronic acid with different molecular weights. A higher molecular weight version has been developed to replace the low molecular weight form. The high molecular weight form is increasingly similar to the natural synovial one. Thus, it may have a more significant pain-relieving effect (Abate & Salini, 2012; Wobig et al., 1999).

#### ***1.8.2.1.3.3 Platelet-rich plasma (PRP)***

The PRP (platelet-rich plasma) was implemented in maxillofacial and plastic surgery in the 1990s, and it has been widely used for about 20 years in a wide range of medical practices (Hancı et al., 2015; Pihut et al., 2014; Sampson et al., 2008). PRP has been broadly applied in various fields of medicine. For instance, PRP has been clinically used in dental and maxillofacial surgery, plastic surgery, orthopedics, sports medicine,

neurosurgery, spinal surgery, and cardiology (Bose & Balzarini, 2002; Man et al., 2001; DelRossi et al., 1990; Sampson et al., 2008).

The own blood of the patient is administered into the damaged joint after a sequence of centrifugations and separations. The method of PRP injection into even small joints was developed in recent years. The clinical efficacy of the PRP comes from the platelet concentrate. Normal platelet concentration is 200,000 platelets/ul and related to PRP, a clinical efficiency expected with a minimum of four times higher amount of cells (Sampson et al., 2008).

Platelets contain more than 30 growth factors, such as PDGF, TGF, VEGF, IGF, FGF, and EGF (Anand, 2018). Platelets also contain proteins, which are responsible for cell adhesion and the stimulation of the tissue regeneration process. It has been reported that the increased concentration of platelets, thus growth factors, simulates the initial stage of the inflammatory response. That means an enhanced migration of neutrophils, monocytes, and macrophages (Pietrzak & Eppley, 2005).

In addition, they stimulate fibroblasts to produce structural proteins that form new collagen and support the remodeling, angiogenesis, and activation of mesenchymal stem cells (Pihut et al., 2014). PRP injection is known to have analgesic, anti-inflammatory, and antibiotic effects. In addition, it induces the production of glycosaminoglycans and can restore the level of endogenous hyaluronic acid (Civinini et al., 2011).

PRP may also have an inhibitory effect on specific pro-inflammatory cytokines, specifically through suppression of interleukin-1 release from activated macrophages that may be unfavorable in the initial stage of healing (Woodall et al., 2008).

In conclusion, PRP has a dual action of enhancing repair processes and decreasing tissue breakdown. These findings can prove its potential benefits for faster recovery (Taylor et al., 2011).

PRP is usually injected once for temporomandibular joint treatment but is also known to be administered twice two weeks apart (Pihut et al., 2014).

#### ***1.8.2.1.3.4 Injectable platelet-rich fibrin (I-PRF)***

According to several studies, the anticoagulants and agents administered to PRP have an inhibiting role in tissue regeneration and wound healing (Miron et al., 2017). The PRF is a novelty, second-generation platelet-rich plasma and is also available in a liquid form called I-PRF.

This form can stimulate regenerative processes in the joint without using additional substances (Anand, 2018). Furthermore, studies reported that I-PRF could release a higher level of growth factors and induce fibroblast migration compared to PRP (Miron et al., 2017). In addition, the quicker and easier preparation and the lack of aggregates offer a promising method.

Studies reported that I-PRF promotes collagen synthesis and releases pro-wound-healing growth factors, such as TGF- $\beta$ 1 and platelet-derived growth factors (Wang et al., 2017). In addition, it supports osteochondral formation and improves the regeneration of cartilaginous tissue (Abd El Raouf et al., 2019).

#### ***1.8.2.2 Open TMJ surgery***

In the classification given by the American Society of Temporomandibular Joint Surgeons, surgical methods for treating internal disorders and degenerative diseases after arthrocentesis and arthroscopy are arthrotomy, condylotomy, and other techniques such as coronoidotomy, coronoidectomy, and procedures for the treatment of recurrent dislocations (ASTJS, 2003).

The indications for open surgery, as defined by the Hungarian guideline, are bony or fibrotic ankylosis, removal of a tumor, severe and chronic dislocation, persistent and painful conditions related to the articular disc, and severe osteoarthritis that does not respond to conservative treatment (ESZK, 2020).

Surgical interventions for the disc include discoplasty and the repositioning or removing part or all of the articular disc (ESZK, 2020). Discoplasty and fixation of the disc with sutures (plication) are 80-90% effective in reducing pain and improving mouth opening (Anderson et al., 1991).

Endoprosthetic surgery involves the removal of very severely damaged parts of the joint and replacing the missing parts with prosthetic devices, which manufacture is done with 3D printing (ESZK, 2020). It cannot be emphasized enough that as long as possible, non-invasive therapy is preferred. Still, endoprosthetic surgery is the definitive therapy in severe cases, such as severe destruction of the condylar head and fossa and bony ankylosis of the joint (Tanaka et al., 2008; ESZK, 2020).

Despite the earlier published postoperative complications, such as adhesions, further bone destruction, and recurrent severe pain, due to developments in recent years, the longevity and success rate of alloplastic joint replacements are showing an improving trend again (Li & Leung, 2021).

In summary, we can see that understanding the nature of the temporomandibular joint and the recognition and description of its pathological processes go back a long way in the history of medicine. The methodology of some interventions has mostly stayed the same while treating other pathological lesions is still evolving in terms of the materials and methods used. However, despite the wide range of approaches, TMD may undoubtedly be the leading cause of jaw joint pain, causing a reduction in chewing, speech, and daily activity. It has been shown to affect the quality of life significantly, and its relatively high prevalence makes it a significant public health problem. Therefore, the uncertainty about the subject and the multiplicity and diversity of methods and ideologies make it so interesting.



## 2. Objectives

The research aimed to understand better the efficacy of intra-articular therapy based on the experience of orthopedic methods and to achieve the best results in treating patients with internal derangement of the temporomandibular joint using the ideal material. During the research, we examined the effects of the injections of corticosteroids, low and high-molecular-weight hyaluronic acid, platelet-rich plasma, and platelet-rich fibrin.

Research questions:

1. We investigated which of the abovementioned intraarticularly administered substances caused significant improvement in *maximal mouth opening* on the first and second checkups after treatment and which was the most effective material.
2. We examined which of the abovementioned intraarticularly administered substances caused significant improvement in *pain level* on the first and second checkups after treatment and which was the most effective material.
3. The two molecular weight hyaluronic acid forms related to maximal mouth opening and pain level were compared to assess the difference in their efficacy. Is there a significant difference between the efficiencies of low and high-molecular-weight forms?
4. We assessed which of these substances resulted in long-term improvements without regression.
5. We examined if there is any difference between the short-term (6 months) and long-term (12 months) efficiencies in different treatment groups.

## 3. Methods

### 3.1 Patients

This prospective clinical research was approved by the Scientific and Research Ethics Committee of the Scientific Council for Health (approval number: BPR/021/01566-2/2015). A total of 77 patients with 121 joints presented with temporomandibular joint disorders at the Department of Oro-Maxillofacial Surgery and Stomatology, Semmelweis University, between 2015 and 2020.

The study inclusion criteria were determined by the RDC/TMD criteria (Dworkin & LeResche, 1992). The patients previously had non-invasive treatment by the gnathologist care team at the Department of Prosthodontics, Semmelweis University. The non-invasive therapy, including mainly physiotherapy and bite splint therapy, lasted 2-5 months, depending on the severity of the cases and the patient's compliance (Vingender et al., 2023). Patients for whom painless and asymptomatic conditions could not be achieved with the methods mentioned above were included in this research.

Patients between 18 and 80 years were included, regardless of gender.

The study exclusion criteria were the following:

- Myofascial pain syndrome
- Coagulation disorders and current anticoagulant therapy
- Gravidity
- Non-cooperative patients

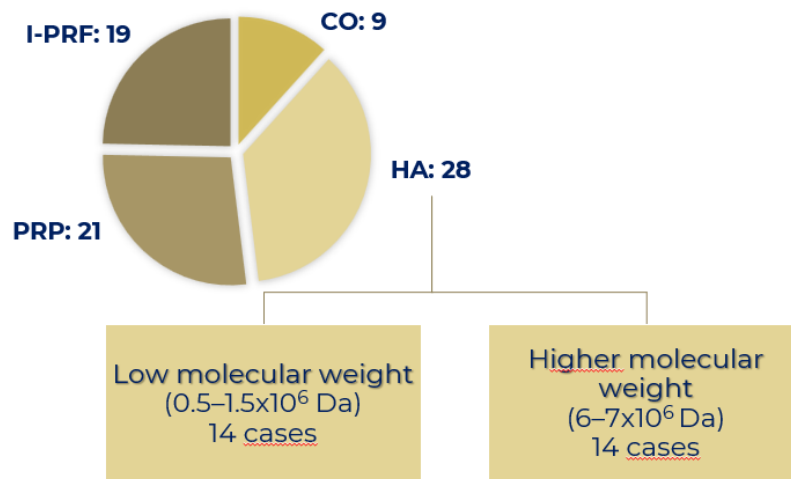
The patients were informed about the treatment process, the material used, and possible complications and signed the informed concern form accepted by the Scientific and Research Ethics Committee of the Scientific Council for Health (Vingender et al., 2023).

Minimally invasive intra-articular therapy with corticosteroids (CO), hyaluronic acid (HA), platelet-rich plasma (PRP), or platelet-rich fibrin (I-PRF) was performed to treat temporomandibular internal derangement. The treatment groups were selected in

sequential order. Patients were assigned to specific treatment groups according to the new methods available at the Department of Oro-Maxillofacial Surgery and Stomatology. Sample size in different treatment groups was maximized per 30 patients in each treatment category.

The results of a total of 77 patients were compared and evaluated. Intra-articular CO injection was given to 9 patients, HA treatment was performed in 28 cases, PRP was injected in 21 patients, and I-PRF was given to the 19 patients in the research.

Low molecular weight hyaluronic acid ( $0.5\text{--}1.5 \times 10^6$  Da) and a higher molecular weight variation ( $6\text{--}7 \times 10^6$  Da) were administered in 14-14 cases without selection basis (Figure 4).



**Figure 4.** The proportion of the different treatment groups. CO=corticosteroids, HA=hyaluronic acid, PRP=platelet-rich plasma, I-PRF=platelet-rich fibrin (Vingender et al., 2018; Vingender et al., 2023)

### 3.2 Pre- and postoperative measures and follow-ups

Conventional static and dynamic MRI scans were performed before the intervention to diagnose and evaluate the internal derangement of TMJ. The MRI examinations detected dislocation of the disc, subchondral degeneration, or damage of the cartilage.

We recognized that patients' subjective complaints do not always indicate a close correlation between the radiological image and the clinical lesions; we focused on the patient's subjective symptoms. A quick and easy way to assess the patients' pain level was to fill in the Fonseca questionnaire. With the help of this anamnestic tool, we could classify patients according to the severity of their subjective symptoms.

The range of mouth opening was measured in millimeters, as the distance between the incisal edge of the upper and lower central incisors. Patients with mouth openings of more than 35 mm had to be excluded from the statistical analysis of MMO since the stagnancy of a good physiological condition could provide false results during the evaluation.

The patient's self-report determined the subjective pain level on a Visual Analog Scale (VAS scale), where the marked point was measured millimeters from the scale's starting point. The starting point is a 0 score, meaning 'no pain,' and 10 means 'the worst pain.'

Checkups were scheduled for one week, six months, and 12 months after the treatment, and on the 6-month and 12-month follow-ups, the range of mouth opening was measured, and the pain level on the VAS scale was determined again. Pre- and postoperative results were compared based on the variables mentioned above.

### **3.3 Treatment protocols**

In every type of intra-articular treatment, the insertion point and surrounding area were disinfected with alcohol, and local anesthetics were aseptically injected. We injected substances into the superior joint space. The technique to find the proper insertion point was estimated as written by Nitzan, which defines it as a point located 10 mm in front of the tragus and 2 mm inferior to the line binding the lateral canthus of the eye and the tragus (Nitzan et al., 1991). However, the palpation method indicated the exact location of the joint space. With the opening and closing of the mouth, we could detect the joint space and lead the needle in a superior and slightly posterior direction (Vingender et al.,

2023). In certain cases, the method is hardly carried out, especially in narrowing joint space.

Except for CO therapy, the treatment protocol was only using the specific substance without previous arthrocentesis. After the intervention, a pressure bandage from sterile gauze was placed on the insertion point.

Both sides were injected simultaneously in patients with bilateral TMD, but the joints were evaluated separately during the preoperative and follow-up examinations. We assume these joints can be treated independently as unilateral ones due to differences in preoperative VAS values between the sides (Vingender et al., 2023).

The protocol for corticosteroid injection was based on Toller's research: lavage was performed, followed by injection of 1 ml of Diprophos solution (2.63 mg betamethasone sodium phosphate and 6.43 mg betamethasone dipropionate/1 ml) into the upper compartment of the joint.

1ml of the hyaluronic acid solution was injected three times, one week apart, following Basterzi's recommendation (Basterzi et al., 2009; Vingender et al., 2023).

The two molecular weight forms used were low molecular weight Hyalgan (Fidia Farmaceutici, S.p.A, Italy) and a higher molecular weight Euflexxa (Ferring Pharmaceuticals, U.S.) (Vingender et al., 2023).

For PRP preparation, peripheral blood was collected directly from the patient, and a GLO-PRP separation Kit (Glofinn Oy, Salo, Finland/GloTech Co Ltd, Korea) was used. The process of centrifugations and separations was performed according to the manufacturer's specifications (Vingender et al., 2023).

1 ml of I-PRF was prepared after the antecubital blood collection and centrifugation, according to the method reported by Choukroun (Dohan et al., 2006; Vingender et al., 2023).

Patients were asked to continue the conservative treatment (using the occlusal splints and exercising physiotherapy) after the intra-articular therapy. These modalities could also enhance pain relief and the improvements in jaw movement (Vingender et al., 2023).

### 3.4 Statistical analysis

The IBM SPSS Statistics 28.0 software was used to evaluate the data in our research.

The one-way ANOVA parametric test was used to compare several groups with tests for normality and homogeneity. The ANOVA test was conditional on a p-value greater than 0.05 for the last two tests. This test was used for preoperative comparison of treatment groups regarding mouth opening and pain scales.

The Wilcoxon, non-parametric, test was used if one of the samples was not normally distributed or if the number of cases was very small. For this test, we use the median value for two dependent samples.

The Mann-Whitney U, non-parametric test, was used to independently analyze two samples if neither sample was normally distributed. The method tests the equality of the medians of two independent samples.

The paired sample T-test was performed for normal distributions of samples. We searched for agreement between the expected values of two populations where the data are pairwise linked.

The Kruskal-Wallis non-parametric test was performed when the sample is not normally distributed (p-value is always less than 0.05) and more than two independent samples are compared along one variable, which may have either the same or a different number of elements. The test was used to compare improvements in various materials.

The significance level was set at  $p < 0.05$  for all statistical tests.

## 4. Results

Our results were published in 2018 in a Hungarian journal ‘Orvosi Hetilap’ (Vingender et al., 2018), and in 2023 in the ‘Journal of Cranio-Maxillofacial Surgery’ (Vingender et al., 2023).

In total, 121 joints were evaluated in 77 patients. The average age was 52 years ( $\pm 16$  years). 87% of the patients were female (67/77), and 13% were male (10/77).

### 4.1 Fonseca’s grade

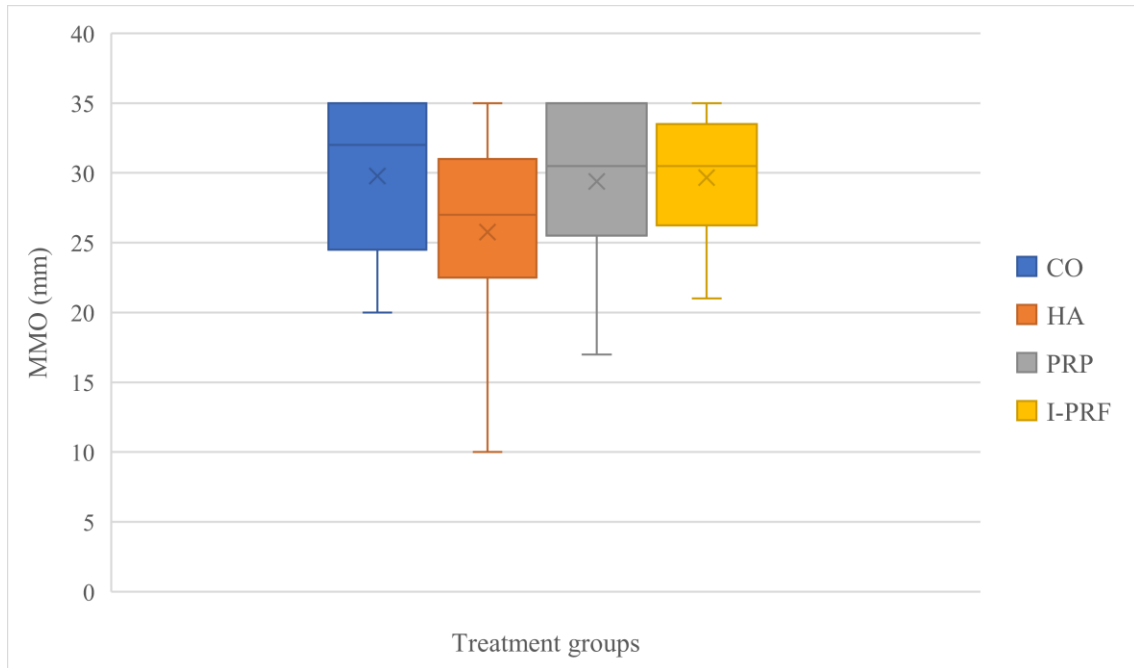
According to Fonseca’s questionnaire, the distribution of the patients was evaluated. Table 4 shows that the I-PRF treatment group contained the highest proportion of severe cases (36,8%). In contrast, the highest proportion of moderate cases occurred in the PRP group (57,1%), followed by the hyaluronic acid group with a slightly lower proportion. In the corticosteroid group, the severity groups were equally distributed.

**Table 4.** *Distribution of the cases within different treatment groups according to Fonseca's grading system.*  
*CO=corticosteroids, HA=hyaluronic acid, PRP=platelet-rich plasma, I-PRF=platelet-rich fibrin (Vingender et al., 2018; Vingender et al., 2023)*

Fonseca's grade	CO	HA	PRP	I-PRF
<b>Mild</b>	33,3%	26,0%	23,8%	21,1%
<b>Moderate</b>	33,3%	55,5%	57,1%	42,1%
<b>Severe</b>	33,3%	18,5%	19,0%	36,8%

## 4.2 Maximal mouth opening

The effects of CO, HA, PRP, and I-PRF on mouth opening were investigated. Using the ANOVA test, we did not find a significant difference between groups during the preoperative measurements ( $p=0.318$ ), (Figure 5).



**Figure 5.** Average preoperative MMO values in different treatment groups. MMO=maximal mouth opening, CO=corticosteroids, HA=hyaluronic acid, PRP=platelet-rich plasma, I-PRF=platelet-rich fibrin (Vingender et al., 2018; Vingender et al., 2023)

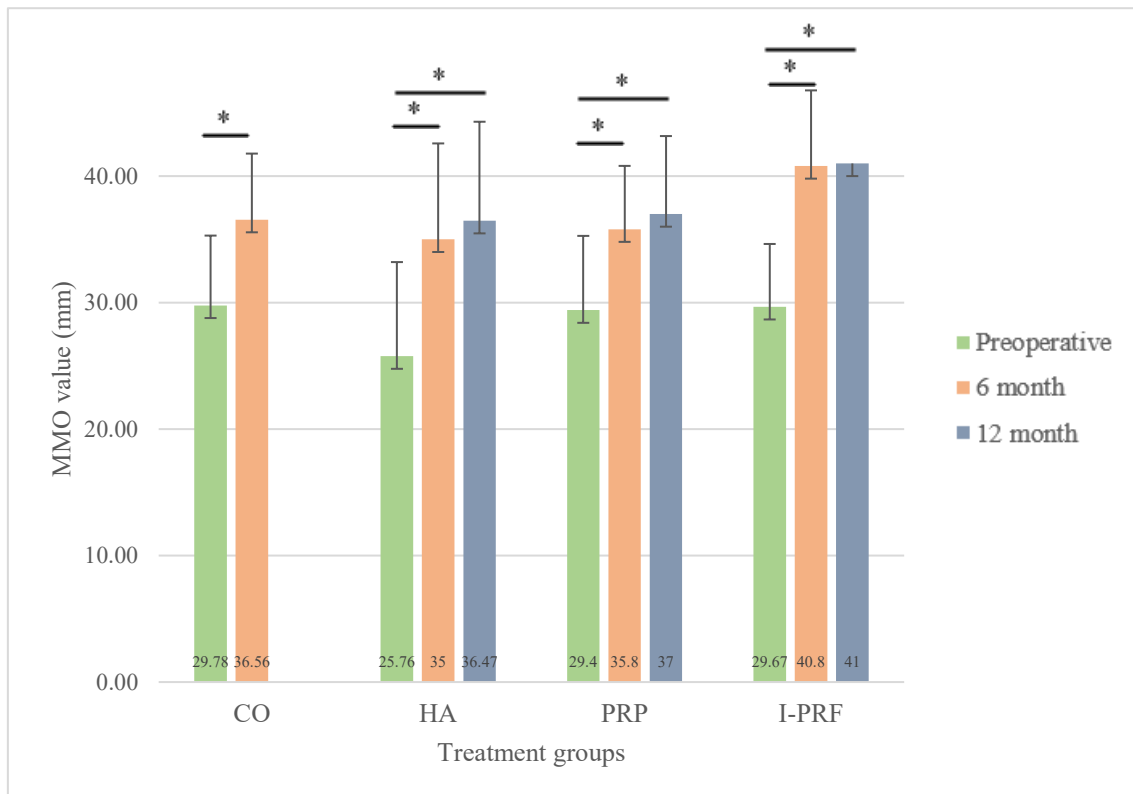


#### 4.2.1 Changes in different treatment groups

Hyaluronic acid significantly improved the degree of mouth opening during the 6<sup>th</sup> and 12<sup>th</sup>-month follow-up ( $p_{(T0-T6)} < 0.001$ ;  $p_{(T0-T12)} < 0.001$ ). Treatment with CO injection showed less improvement, but the change was still significant ( $p_{(T0-T12)} = 0.015$ ).

For PRP, both 6-month and 12-month values were significantly better than the initial values ( $p_{(T0-T6)} = 0.012$ ;  $p_{(T0-T12)} = 0.018$ ).

When using I-PRF, similar results were observed, with significantly higher mouth opening at both control assessments compared to pre-operative values ( $p_{(T0-T6)} = 0.041$ ;  $p_{(T0-T12)} = 0.042$ ), (Figure 6).

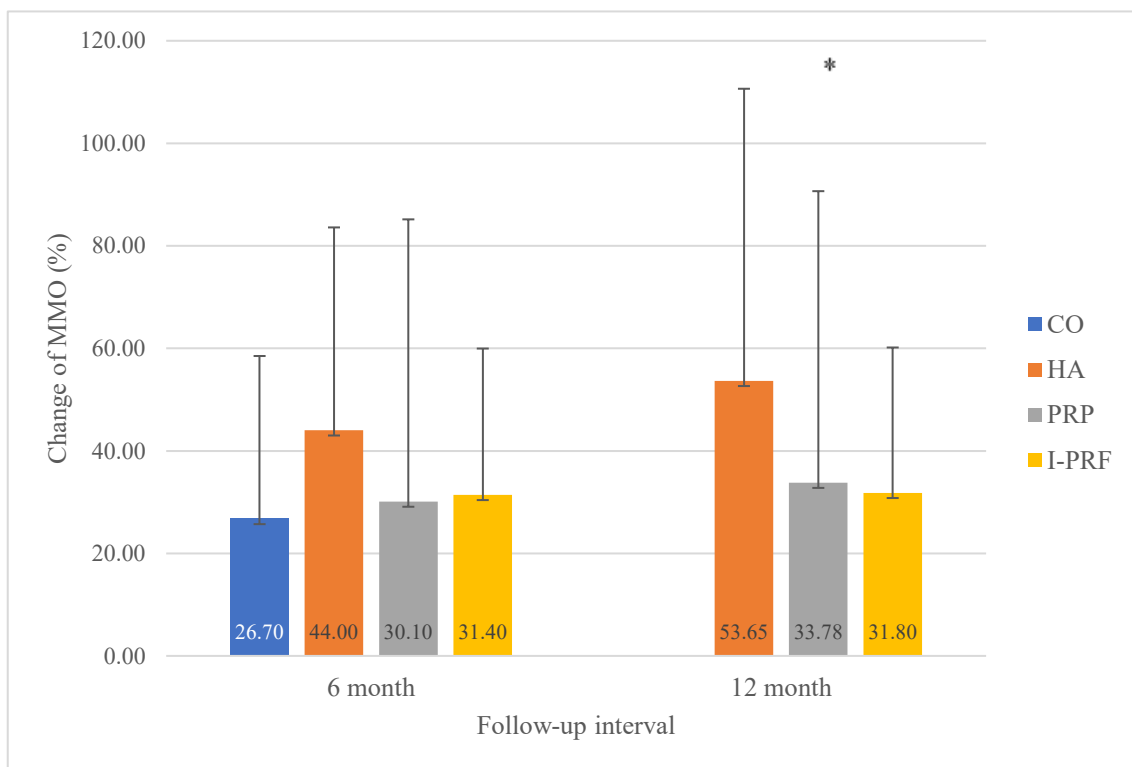


**Figure 6.** Pre-and postoperative measurements of maximal mouth opening in different intraarticular treatment groups.

MMO= maximal mouth opening, CO=corticosteroids, HA=hyaluronic acid, PRP=platelet-rich plasma, I-PRF=platelet-rich fibrin (Vingender et al., 2018; Vingender et al., 2023)

#### 4.2.2 Difference between the efficacy of the treatment groups

The difference between the effects of CO, HA, PRP, and I-PRF on mouth opening was investigated. Using the Kruskal-Wallis test, we did not find a significant difference between the groups during the 6-month postoperative measurement ( $p_{(T6)}=0.89$ ). On the second follow-up, a significant difference was observed when comparing the HA, the PRP, and the I-PRF groups, with hyaluronic acid providing the most remarkable change ( $p_{(T12)}=0.03$ ), (Figure 7).

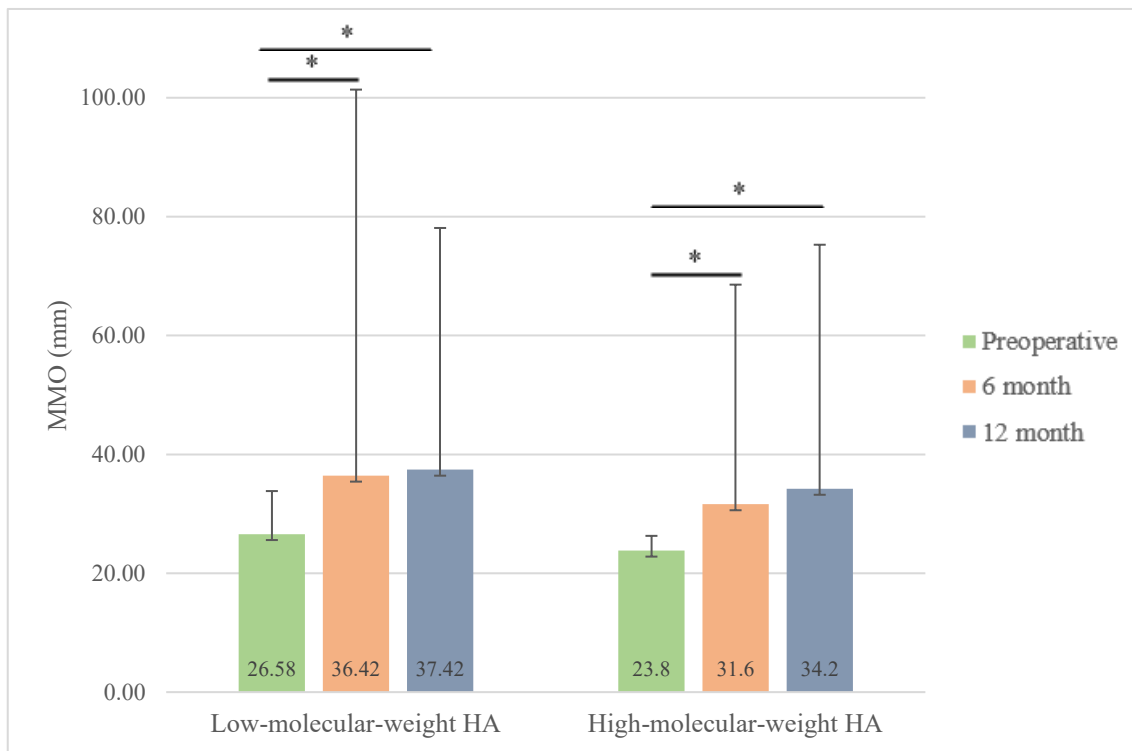


**Figure 7.** MMO percentage changes at 6- and 12-month follow-ups compared to the preoperative values in different treatment groups.

MMO=maximal mouth opening, CO=corticosteroids, HA=hyaluronic acid, PRP=platelet-rich plasma, I-PRF=platelet-rich fibrin. (Vingender et al., 2018; Vingender et al., 2023)

#### 4.2.3 Changes in MMO in different molecular weight hyaluronic acid groups

We found significant differences in both HA treatment groups during the 6-month and 12-month follow-ups ( $p_{\text{HA-L}(T_0-T_6)}=0.02$ ;  $p_{\text{HA-L}(T_0-T_{12})}=0.02$ ;  $p_{\text{HA-H}(T_0-T_6)}=0.041$ ;  $p_{\text{HA-H}(T_0-T_{12})}=0.042$ ). However, low-molecular-weight HA solution resulted in higher changes in mouth opening on average during the first follow-up (9.84 mm). On the second follow-up, the overall changes were similar in the two treatment groups (10.84 mm in the HA<sub>L</sub> and 10.4 mm in the HA<sub>H</sub> group), (Figure 8).

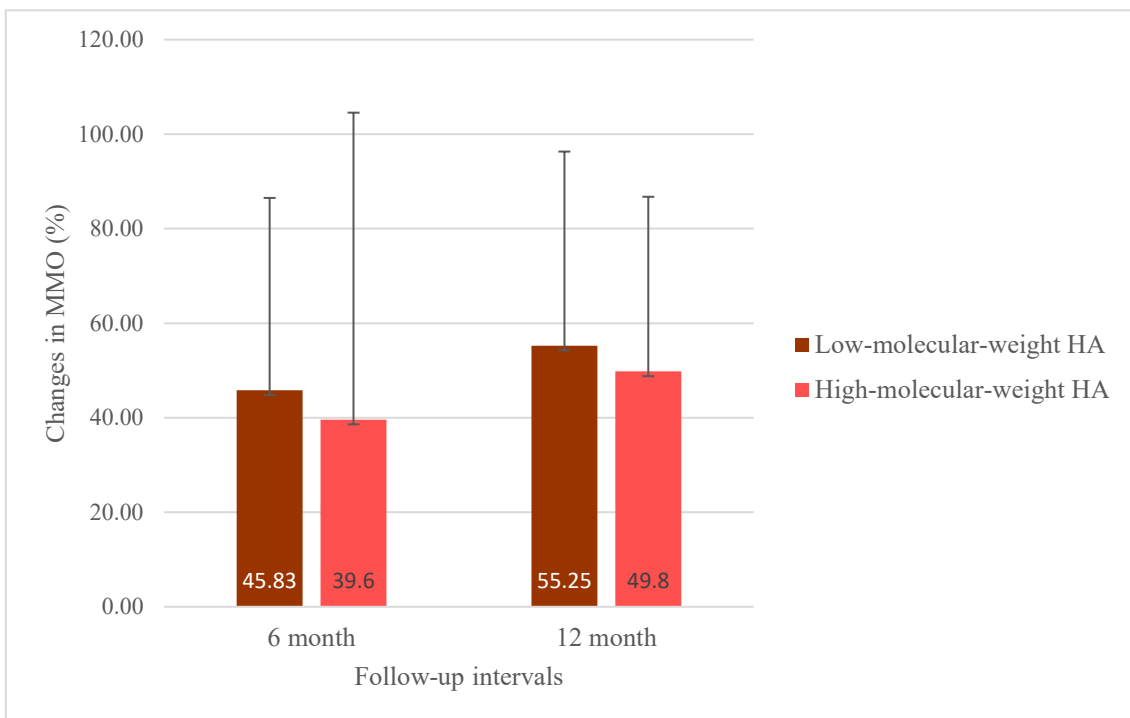


**Figure 8.** Pre-and postoperative measurements of maximal mouth opening in different molecular weight HA treatment groups.

MMO=maximal mouth opening, CO=corticosteroids, HA=hyaluronic acid, PRP=platelet-rich plasma, I-PRF=platelet-rich fibrin (Vingender et al., 2018; Vingender et al., 2023)

#### 4.2.4 Difference between the efficacy of the two different molecular weight hyaluronic acid treatment groups

There was no significant difference between the two molecular-weight forms related to the mouth opening during the two follow-ups ( $p_{(T6)}=0.383$ ;  $p_{(T12)}=0.721$ ). However, notably higher values were observed in the low-molecular-weight HA group (Figure 9).



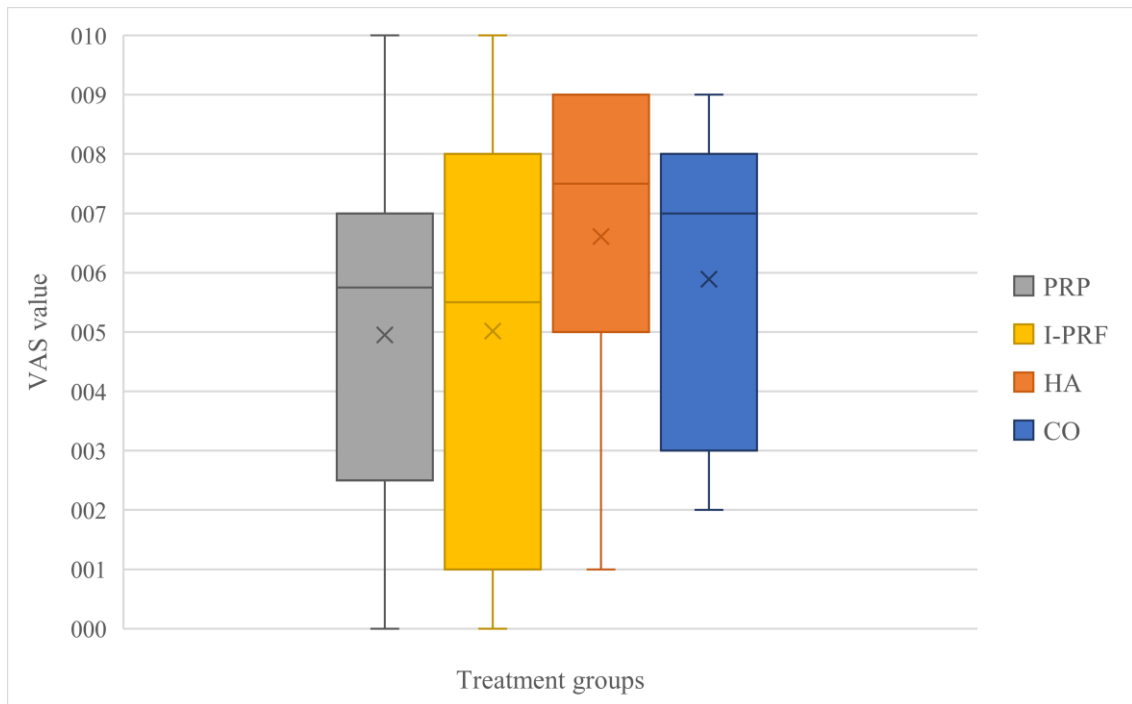
**Figure 9.** Changes in MMO in percentage in different forms of hyaluronic acid treatment groups during the 6- and 12-month follow-ups. MMO=maximal mouth opening, HA=hyaluronic acid (Vingender et al., 2018; Vingender et al., 2023)

#### 4.2.5 Assessment of the relapse

When comparing the values of changes, we did not find a significant relapse in mouth opening during the 12-month follow-up in any of the treatment groups. In contrast to relapse, there was more improvement experienced after the first checkup in mouth opening in HA, PRP, and I-PRF treatment groups. However, the difference was significant in only the hyaluronic acid group ( $p_{(HA)}<0.05$ ). (Figure 7.)

### 4.3 Visual Analog Scale

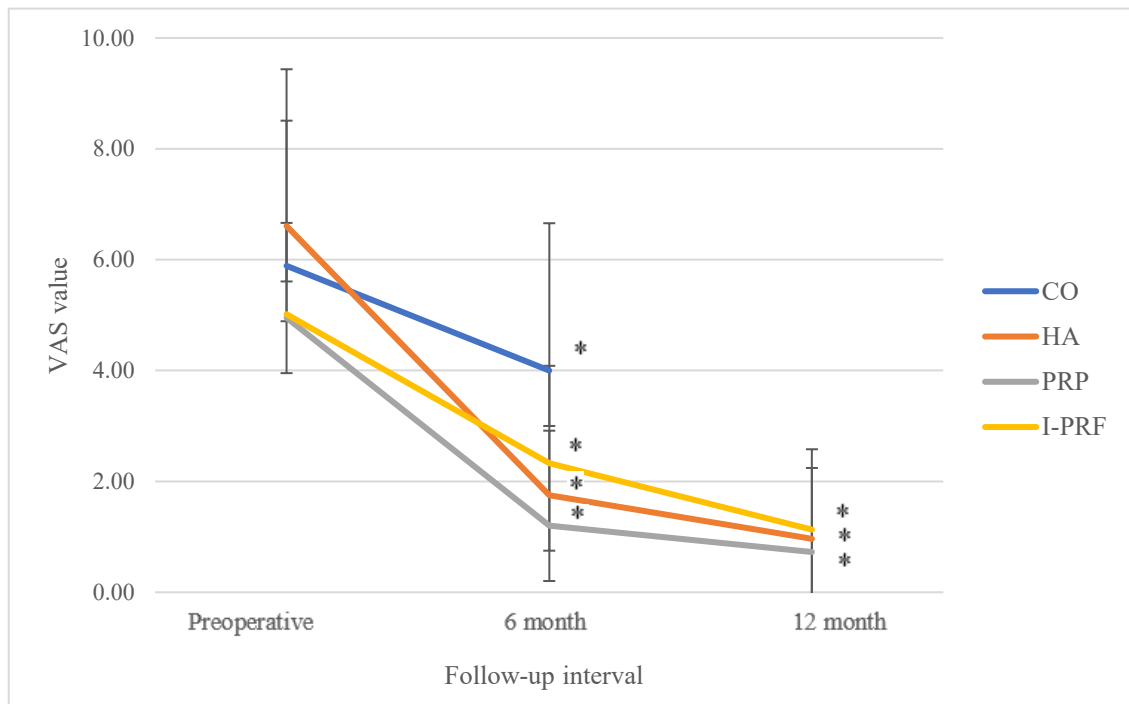
The effects of CO, HA, PRP, and I-PRF on pain levels were also analyzed. Using the Kruskal-Wallis test, we found no significant difference between the treatment groups at the base value ( $p=0.102$ ), (Figure 10).



**Figure 10.** Average preoperative VAS values in different treatment groups. VAS=Visual Analog Scale, CO=corticosteroids, HA=hyaluronic acid, PRP=platelet-rich plasma, I-PRF=platelet-rich fibrin (Vingender et al., 2018; Vingender et al., 2023)

### 4.3.1 Changes in different treatment groups

There was a significant difference in the pain level between pre- and postoperatively, including 6-month and 12-month follow-ups, in the CO, HA, PRP, and I-PRF treatment groups ( $p_{(CO-T6)}=0.039$ ;  $p_{(HA-T6)}<0.01$ ;  $p_{(PRP-T6)}<0.01$ ;  $p_{(I-PRF-T6)}<0.01$ ;  $p_{(HA-T12)}<0.01$ ;  $p_{(PRP-T12)}<0.01$ ;  $p_{(I-PRF-T12)}<0.01$ ), (Figure 11).

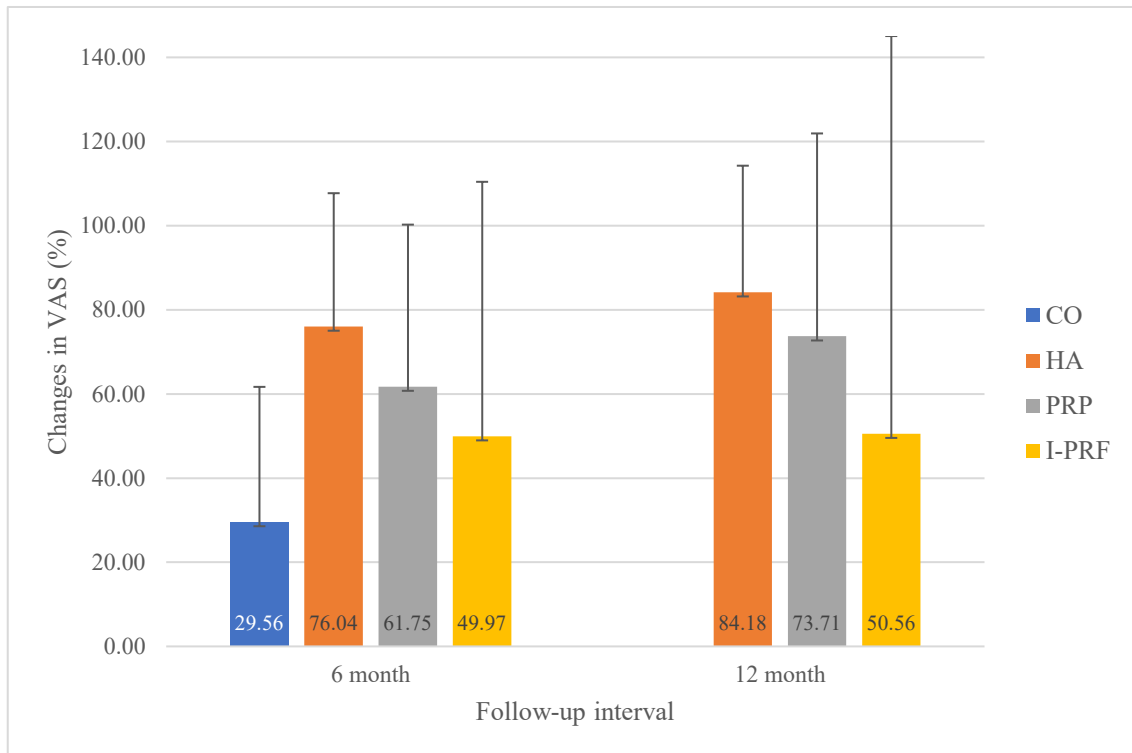


**Figure 11.** Pre-and postoperative measurements of VAS in different intraarticular treatment groups.

VAS=Visual Analog Scale, CO=corticosteroids, HA=hyaluronic acid, PRP=platelet-rich plasma, I-PRF=platelet-rich fibrin (Vingender et al., 2018; Vingender et al., 2023)

### 4.3.2 Difference between the efficacy of the treatment groups

Using the Kruskal-Wallis test, there was a significant difference between the treatment groups during the 6-month follow-up ( $p_{(T6)}=0.021$ ), but it was not found at the 12-month follow-up ( $p_{(T12)}=0.154$ ), (Figure 12).

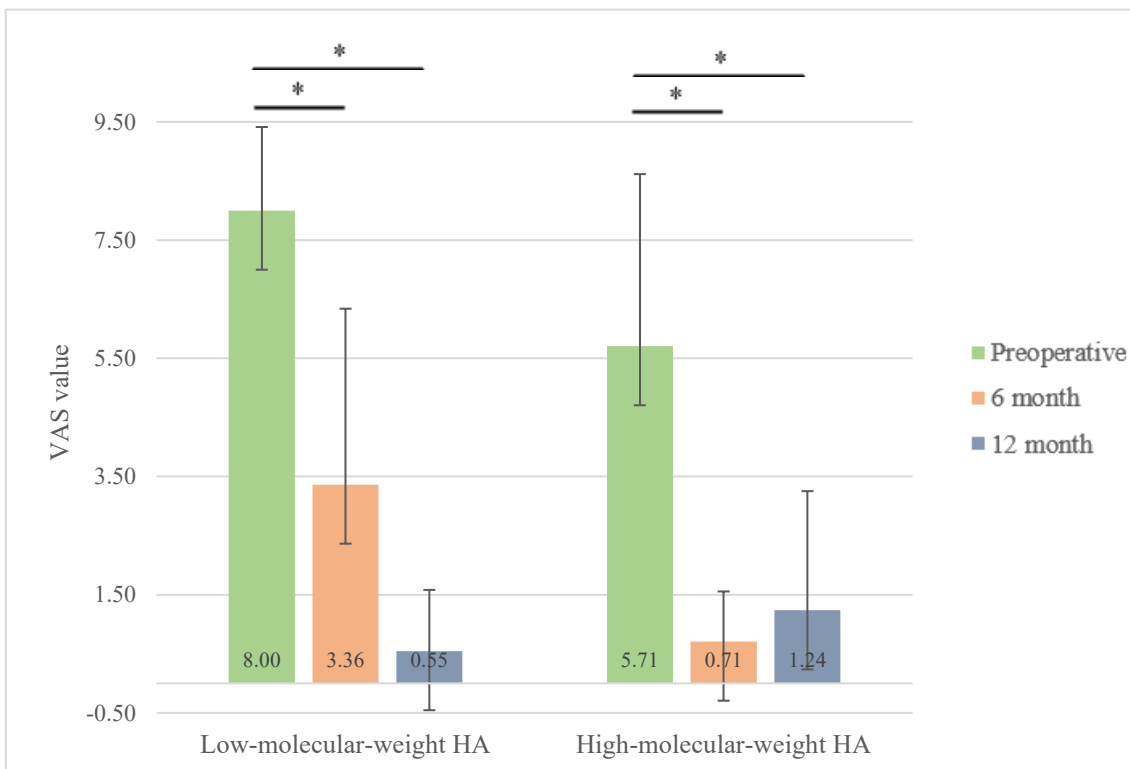


**Figure 12.** Changes of VAS in percentage at 6- and 12-month follow-up compared to the preoperative values in different treatment groups.

VAS=Visual Analog Scale, CO=corticosteroids, HA=hyaluronic acid, PRP=platelet-rich plasma, I-PRF=platelet-rich fibrin (Vingender et al., 2018; Vingender et al., 2023)

### 4.3.3 Changes in VAS in different molecular weight hyaluronic acid groups

We found significant differences in both HA treatment groups during the 6-month and 12-month follow-ups ( $p_{\text{HA-L}(T0-T6)}=0.08$ ;  $p_{\text{HA-L}(T0-T12)}=0.03$ ;  $p_{\text{HA-H}(T0-T6)}<0.01$ ;  $p_{\text{HA-H}(T0-T12)}<0.01$ ), (Figure 13).

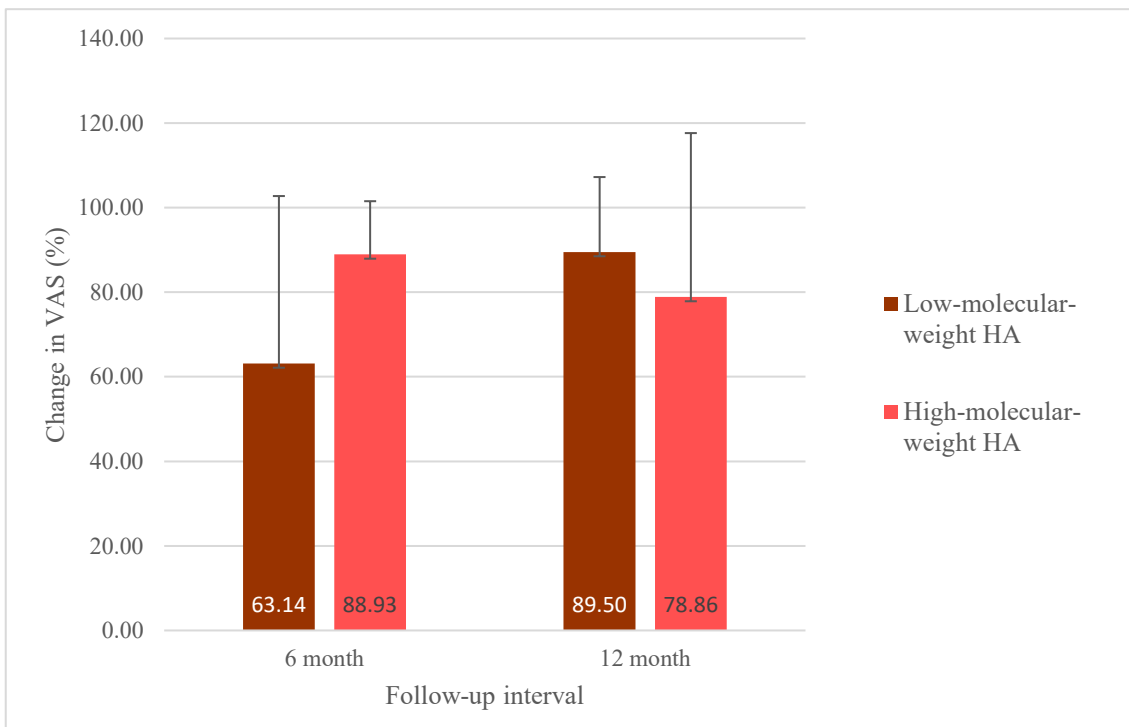


**Figure 13.** Changes in VAS values in low and high-molecular-weight HA treatment groups at the preoperative, first, and second checkups. VAS=Visual Analog Scale, HA=hyaluronic acid (Vingender et al., 2018; Vingender et al., 2023)



#### 4.3.4 *Difference between the efficacy of the two different molecular weight HA treatment groups*

There was no significant difference between the two molecular-weight forms related to the VAS values during the two follow-ups ( $p_{(T6)}=0.178$ ;  $p_{(T12)}=0.667$ ). Figure 13 shows that the change resulting from the low-molecular-weight form was lower than the high-molecular-weight form on the first follow-up. Still, this outcome was reversed on the second follow-up, when we observed a more remarkable change caused by the low-molecular-weight HA (Figure 14).



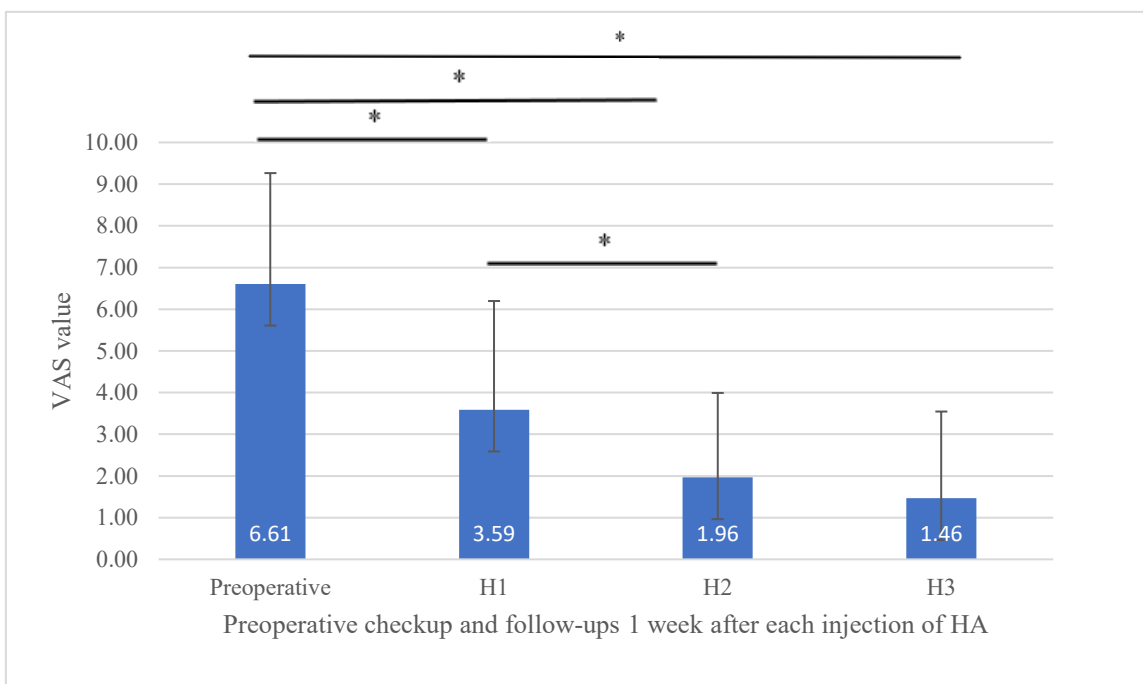
**Figure 14.** Changes of VAS in percentage in low and high-molecular-weight HA treatment groups at the first and second checkups.

VAS=Visual Analog Scale, HA=hyaluronic acid (Vingender et al., 2018; Vingender et al., 2023)

#### 4.3.5 Changes in VAS 1 week after each injection of consecutive HA treatment

In the hyaluronic acid treatment group, pain intensity was significantly reduced after the first injection compared to the preoperative status. There was also a significant decrease observed after the second and third injections compared to the preoperative value ( $p_{(H1)} < 0.01$ ;  $p_{(H2)} < 0.01$ ;  $p_{(H3)} < 0.01$ ).

When comparing the results after each injection, there was a significant difference between the first and second injections ( $p_{(H1-H2)} = 0.02$ ). In contrast, there was no significant difference between the second and third injections ( $p_{(H2-H3)} = 0.15$ ), (Figure 15).



**Figure 15.** Changes in VAS 1 week after each injection of consecutive HA treatment. VAS=Visual Analog Scale, HA=hyaluronic acid (Vingender et al., 2018; Vingender et al., 2023)

#### 4.3.6 Range of relapse related to VAS values

When comparing the values of changes, we found relapse during the 12-month follow-up only in the high molecular weight HA treatment group. Still, overall, the result was not significant in comparing the HA group to the others ( $p_{(HA)}=0.127$ ).

Regarding the continuous improvement experienced during the second follow-up, we did not find significant differences in HA, PRP, and I-PRF treatment groups (Figure 11).

#### 4.4 Differences between short-term and long-term results

Comparing the 6-month and 12-month follow-up results, no statistically significant differences were found in MMO and VAS in any treatment group (Table 5).

**Table 5.** P value table for comparison of 6-month and 12-month results of HA, PRP, and I-PRF in relation to the MMO and VAS.

$T_6$ =6-month follow-up,  $T_{12}$ =12-month follow-up, MMO=maximal mouth opening, VAS=Visual Analog Scale, HA=hyaluronic acid, PRP=platelet-rich plasma, I-PRF=platelet-rich fibrin (Vingender et al., 2018; Vingender et al., 2023)

	<i>Treatment group</i>	<i>T<sub>6</sub>-T<sub>12</sub></i>
<i>MMO</i>	HA	0.82
	PRP	0.90
	I-PRF	0.90
<i>VAS</i>	HA	0.58
	PRP	0.10
	I-PRF	0.90

## 5. Discussion

Internal derangement of the temporomandibular joint means an abnormal connection between the disc, condyle, and articular eminence (Trumpy et al., 1997). This pathological process is currently known as a progressive lesion caused mainly by altered biomechanical processes within the joint (Hancı et al., 2015).

In contrast to the treatment modalities of myofascial pain syndrome, where conservative treatment modalities are successful in most cases, it is well-known that treating internal derangement of the TMD is different. On the one hand, the therapy of the disease requires the teamwork of a prosthodontist, an orthodontist, a physiotherapist, and an oral surgeon, which means a complex approach to the therapy. On the other hand, there is no agreement on what treatment protocol should be applied generally. However, there is no controversy that the first step should be conservative treatment, which should be maintained during surgical therapy (Gundlach, 1990).

According to a conventional agreement, the goal of the treatment is permanently relieving pain and restoring joint functions.

Our study aimed to compare the treatment outcomes of patients treated with corticosteroids, hyaluronic acid, PRP, and I-PRF after an unsuccessful conservative therapy in internal derangement of the temporomandibular joint.

Our results showed that the intra-articular injection procedure is beneficial, with all administered agents effectively reducing pain intensity and improving joint function.

### 5.1 The age and sex ratio

According to some international reports in the literature, temporomandibular joint disorders primarily affect young and middle-aged adults. Some studies suggest that the average population aged 17-30 is the most frequently affected, while according to others, patients aged 20-40 are the most affected (Mazzetto et al., 2014; Warren & Fried, 2001). Others suggest that the average age of the patients is higher, 45-64 years (Maixner et al., 2016; Lora et al., 2016). A recent study in the United States indicated, although no

publications are available that focus on the higher age group, that a high (3-5%) proportion of the population over 65 years is affected (Yadav et al., 2018). This may be explained by the fact that has been previously published that the prevalence of degenerative TMJ lesions in the aging population also increases (Manfredini et al., 2010b; Guarda-Nardini et al., 2012).

The mean age in this study was 52 years, similar to the results of the abovementioned comprehensive studies.

Similar values were obtained when examining gender comparisons. The proportion of women in our study is 87%. Some studies suggested that women are four times more likely to have the disease and seek medical care for their TMD three times more often than men (Poveda et al., 2007). A recent study suggested that the higher proportion of women with TMD around 50 years is due to menopause and hormonal changes: as estrogen levels decrease, the mechanical strength and integrity of the joint decrease, thus increasing the risk of developing degenerative joint lesions (Yadav et al., 2018).

Higher rates in women can also be explained by behavioral, hormonal, anatomic, and psychosocial factors (Mazzetto et al., 2014).

## **5.2 Fonseca's grading system**

Prior to the intraarticular procedure, we examined the severity of the cases to examine the differences between the treatment groups and evaluate the efficacy of the following treatments. The Fonseca questionnaire is used for application in public service; it is simple and understandable by patients (Santana Jr et al., 2021). Our results showed that regardless of the severity of the disease, intraarticular treatment can be as effective in severe cases as in mild severity. We did not find a correlation between the higher score (severe TMD) and the efficacy of the treatment or the material applied. Using Fonseca's classification, Santana Jr. examined the correlation between the quality of life and the TMD treatment. Their outcomes showed that the treatment effectively improved patients' conditions, as we concluded in our study (Santana Jr et al., 2021).

### 5.3 The effect of substances on pain level and mouth opening

Given that the primary aim of therapy is to reduce pain and improve mouth opening, these symptoms are used as a guide to assess the effectiveness of treatment. In the international literature, the patients' subjective symptoms associated with internal derangement of the temporomandibular joint have been considered together. Pain and mouth opening limitation are closely related symptoms, yet the question of which parameter is significantly affected by a given method is not negligible (Greene & Marbach, 1982). Therefore, a complex evaluation of these results is needed to provide the appropriate conclusions.

Considering that our study was unique in comparing the efficacy of the four agents in treating TMDs, we cannot refer to comparisons in the literature that also used the same protocols we used.

The first substance used in the history of intra-articular treatment was the corticosteroid, the application of which goes back about 70 years (Mountziaris et al., 2009). Corticosteroids are physiological hormones produced by the adrenal glands involved in regulating carbohydrate metabolism and electrolyte balance. In addition, they are known to have anti-inflammatory and immunomodulatory effects, among other features. As an artificially produced anti-inflammatory therapeutic agent, they inhibit phospholipase A2, thereby inhibiting the release of arachidonic acid (Torres et al., 2020). In intracapsular temporomandibular joint diseases, they inhibit the production of proinflammatory cytokines such as interleukins, tumor necrosis factor-alpha, interferon-gamma, and factor-stimulating granulocytic and macrophage colonies. In addition, they inhibit the accumulation of macrophages and neutrophils in the inflamed area (Torres et al., 2020). Several studies reported its beneficial effects on temporomandibular joint disorders (Torres et al., 2020; Manfredini et al., 2012), similar to what we experienced in our research. Corticosteroids significantly improved the mouth opening and pain level on the 6-month follow-up.

The authors also identified potential local and systematic complications associated with injections; therefore, the prognosis of the disease is unpredictable in the long term (Alpaslan & Alpaslan, 2001). However, its effect on pain-relieving appears quickly but can only last briefly (Kapugi & Cunningham, 2019). The effect of the corticosteroids can

be expected for several weeks to months; therefore, in our study, we did not consider follow-up cases after the 6th month, following other studies' protocol (Sousa et al., 2020).

Hyaluronic acid, also known as hyaluronan or sodium hyaluronate, was considered a beneficial novelty following corticosteroid therapy as a naturally presented component that influences intra-articular processes. It has been used in intraarticular treatment for nearly 40 years. In addition to its beneficial anti-inflammatory effects, it also has lubricating and endogenous hyaluronic acid level-enhancing effects. It can be used with arthrocentesis for viscosupplementation or an injection alone. In a study by Tang et al., hyaluronic acid effectively reduced TMD symptoms without arthrocentesis compared to a saline control group (Tang et al., 2010). In our research, we, therefore, injected hyaluronic acid without arthrocentesis to minimize potential complications. The application protocol was also chosen according to this principle. Based on clinical practice, it can be seen that three injections of hyaluronic acid are helpful and reasonable, with an improvement in pain levels after each injection. However, it can be seen that after the second injection, pain levels decreased further, but the change was no longer significant. Therefore, from our point of view, after the three, further injections are not recommended.

Since its promising results in treating TMD, several studies have investigated the differences between hyaluronic acid and corticosteroids. A previous systemic review did not demonstrate a difference in effect between the two substances (Manfredini et al., 2010a; Shi et al., 2003). In contrast, a recent study published a more remarkable improvement in symptoms caused by hyaluronic acid (Bjørnland et al., 2007). In our study, both substances effectively reduced symptoms, but hyaluronic acid was more effective, as the later results showed. Derwich concluded that corticosteroids do not have an advantage over hyaluronic acid in treating TMD and that their disadvantages make their use in osteoarthritis inadvisable (Derwich et al., 2021b).

PRP and its second-generation version, I-PRF, are the latest developments in intra-articular therapy. Over the last decade, studies have been published about PRP usage in intraarticular treatment, but the methods and procedure protocols are controversial. Moreover, the exact mechanism of autologous blood products has yet to be fully understood. Still, it is assumed that they exert their regenerative effect to their high growth

factor content, the indirect macrocyte-activating property, and chondrocyte activation (Hancı et al., 2015). A larger number of studies have investigated the effect of PRP in osteoarthritis of the knee joint and found a more potent effect than hyaluronic acid and placebo (Campbell et al., 2015). Similarly, Hancı described a significant pain-reducing and function-improving effect of PRP compared to arthrocentesis (Hancı et al., 2015). Our results showed that PRP and I-PRF significantly improve short and long-term symptoms.

Several comparative studies have investigated the effects of CO, HA, and PRP. Gokçe Kutuk found no significant difference in the analgesic effect of the three agents in the short term, as we did in our study (Gokçe Kutuk et al., 2015). However, Jüni et al. pointed out that the short duration of action of corticosteroids leads to a disadvantage compared to hyaluronic acid and PRP, which resulted in a significant pain-free period after treatment (Jüni et al., 2015).

Sousa's short- and long-term studies also got the same results: PRP produced better results than CO and HA at both 6-month and 3-year follow-ups (Sousa et al., 2020; Sousa et al., 2022). In our research, PRP and hyaluronic acid resulted in a significant pain-free period after treatment compared to CO. Still, we did not find PRP more advantageous than HA, similarly to the outcomes in Pihut's study (Pihut & Gala, 2020). However, HA resulted in a greater change in MMO and VAS at the 12-month follow-up; it is assumed this difference could arise from the different applied protocols of the substances.

I-PRF is a recent development of PRP with a low-speed centrifugation technique that contains no additives such as anticoagulants. It can also allow a much longer time to release growth factors than PRP (Miron et al., 2017). Still, the evidence of its efficacy in TMD is limited. Only a few studies have investigated the effect of I-PRF on temporomandibular joint dysfunction. In combination with arthrocentesis, Karadayi found a significant effect of I-PRF compared to arthrocentesis alone at 3 months follow-up (Karadayi & Gursoytrak, 2021). Torul also described a more beneficial effect of I-PRF in his short-term study after arthrocentesis than arthrocentesis alone or arthrocentesis with hyaluronic acid injection (Torul et al., 2021).

Due to its similar properties with PRP, we got similar results at the 6-month and 12-month follow-ups. Both materials significantly improved the mouth opening and the pain level,



and there was no statistical difference between them. Although the I-PRF caused a slightly bigger change in mouth opening, this benefit was not experienced while examining the pain level. Therefore, there was no notable difference between the effects of the two autologous blood materials.

#### **5.4 The different forms of hyaluronic acid**

The molecular weight of hyaluronic acid naturally found in synovial fluid is  $6-7 \times 10^6$  Dalton (Snetkov et al., 2020). Hyaluronic acid's amount and molecular weight in the synovial fluid are reduced in osteoarthritis and chronic degenerative joint changes. With advancing age, chronic joint loading, or inflammation, hyaluronic acid biosynthesis also decreases, and depolymerization of hyaluronic acid molecules occurs (Derwich et al., 2021b). Further damage to the joint can be expected due to reduced viscoelasticity of the synovial fluid (Webner et al., 2021).

Intra-articular hyaluronic acid injections attempt to restore these endogenous hyaluronic acid parameters, promoting normal joint function. Hyaluronic acid products differ in production, molecular weight ( $0.5-7 \times 10^6$  Da), and structure. In addition, the literature has various opinions on the benefits of the different products of choice (Webner et al., 2021). Previous ideas that hyaluronic acid exerts its beneficial effects through viscosupplementation have been debated as the degradation time of the hyaluronic acid administered is relatively fast and has not been associated with long-term beneficial effects. Thus, laboratory studies have demonstrated anti-inflammatory and immunomodulatory effects and a regulatory mechanism through specific receptors (e.g., CD44). Nevertheless, the question of molecular weight still needs to be clarified. However, it can be said that within the range of  $0.5-1 \times 10^6$  Dalton molecular weight, hyaluronic acid has a therapeutic effect on the joint (Ghosh & Guidolin, 2002).

Several animal studies have investigated the effects of hyaluronic acid forms of different molecular weights. Some have found the high molecular weight version more effective in treating temporomandibular joint disorders (Lemos et al., 2015). In contrast, Iturriaga and colleagues have found the low molecular weight hyaluronic acid formulation to be more effective in repairing articular cartilage and disc (Iturriaga et al., 2021). It has also

been found that hyaluronic acid's rheological and biochemical properties depend on molecular weight. The high molecular weight variety is responsible for the viscosity of the synovial fluid and the protection of articular surfaces. In contrast, the low molecular weight variety is responsible for the natural properties of synovial fluid and the synthesis of endogenous hyaluronic acid by being more easily transported through the synovial extracellular matrix and in contact with synoviocytes due to its small size. (Ghosh & Guidolin, 2002)

In our study, we found no significant difference in the effect of the two molecular weight hyaluronic acid variants on either mouth opening or pain, nor was there a difference between the two in the study conducted by Guarda-Nardini (Guarda-Nardini, 2012). However, both significantly improved the patients' condition. In the first control examination, a greater reduction in pain was observed in the HA<sub>H</sub> group, which may be explained by the more favorable rheological properties of high molecular weight hyaluronic acid. However, given that in most of the cases in our study, there was a chronic process underlying the joint disease, low molecular weight hyaluronic acid could have resulted in further improvement. Regarding mouth opening, similar reasons explain the further progress in mouth opening. Despite its short half-life, exogenously administered hyaluronic acid can regenerate intra-articular processes, which is more evident regarding the low molecular weight formula.

### **5.5 Relapse or further improvement in the disease and complications**

In our study, we observed an overall improvement in pain levels in the HA, PRP, and I-PRF groups even after the 6-month follow-up, but the change was not significant in any group. We can explain this finding because all three substances favorably affect the joint's regenerative capacity, as already described in the literature. In addition to the effect of the high growth factor levels in autologous blood products, the enhancement of endogenous hyaluronic acid synthesis also contributes to the restoration of biochemical and biomechanical processes. In addition, the long-term beneficial results are also due to the expansion of the joint space and the release of joint adhesions caused by the extra fluid volume. Hancı et al. found similar results in their research with PRP and further explained the muscle and soft tissue relaxing effect of intra-articular relaxation (Hancı et al., 2015).

The only relapse we experienced in the long term was during the evaluation of high molecular weight hyaluronic acid therapy. On the second checkup, a mild relapse was observed; however, the positive result compared to the baseline level in pain relieving was still significant.

To summarize the consequences of the intraarticular treatment, we can confirm that both variations of HA, PRP, and I-PRF have long-term effects in temporomandibular joint disorders. In contrast, CO has a short-term effect and is less potent than the others.

During the intraarticular treatment, occasional temporary pain conditions were observed, possibly due to the number of injections into the TMJ. We did not experience any complications or undesired adverse effects, as some authors consider them related to corticosteroid injections (Torres et al., 2020). However, our protocol was followed strictly according to the recommendations to avoid possible damage.

After intraarticular treatment, short-term temporary facial palsy could occur due to local anesthetic blockage of the facial nerve. In that case, patients were asked to use artificial tears to prevent dry eyes during eye closure difficulty.

Other complications written in the literature did not occur in our study. However, biomaterials are becoming increasingly important to avoid these possible complications, such as allergic reactions and infections (Fernandez-Ferro et al., 2017).

## **5.6 Limitations and further considerations**

The limitations of the study are described below:

1. The weakest point of the study is the need for a control group. In this way, the effect of each substance was compared to each other, not to an independent value. Due to the variability of the study population, results should be considered with a critical attitude. In all cases, homogenization of treatment groups is essential for adequate evaluation of the results. Still, in this clinical trial, this is challenging to achieve due to the diversity of parameters. The degree of severity of the lesion at the time the patient presented, individual differences in the subjective perception of pain, anatomical characteristics of mouth opening, and personal cooperation

and compliance are all factors that may bias the results. We aimed to minimize this by ensuring that interventions, follow-ups, and measurements were always performed by the same two doctors using the same methods. In addition, the preoperative conditions of the patients were compared, and there were no statistical differences.

2. Another limitation is the difference in the number of intra-articular injections for each substance. It can be assumed that multiple intracapsular fluid injections may favorably influence the results compared to a single injection. In the literature, varied results are reported regarding the methods used. Differences in outcomes may also occur between injections after lavage with physiological saline and the no lavage version.
3. The generalizability of the results is limited by the low number of populations within treatment groups and their variability. Again, additional efforts would be needed to compensate for this.
4. We can mention the limitation that in publications of the international literature, the treatment groups are focused on specific intracapsular conditions of the temporomandibular joint, such as osteoarthritis and disc displacement with reduction or without reduction. However, in our study, patients with all conditions were involved, which belong to the term internal derangement.

In addition to correcting for the limiting factors of the research results, the following should be considered:

1. A recent study indicated that HA and PRP could potentiate each other's effects within a single treatment. Therefore, consideration of this method is recommended (Harba & Harfoush, 2021).
2. There is a need for publications on the topic of regenerative stem cells in intra-articular therapy of the temporomandibular joint in humans. Using stem cells of mesenchymal origin is a promising invention in regenerative medicine. Pluripotent stem cells with mesodermal origin are found in bone marrow, synovial tissue, and adipose tissue. They can be extracted from the bone marrow of the hip

and spine, abdomen, thigh, and hip adipose tissue (Francis et al., 2018). These cells can differentiate into bone, cartilage, muscle, tendon, and other tissues. Using abdominal adipose-derived stem cells (AD-MSCs) has advantages: the stem cells can be obtained in large quantities (five hundred times compared to bone marrow), are easy to obtain, and do not require a stressful procedure for the patient (Francis et al., 2018). The procedure can be performed with local anesthesia and minimal discomfort. According to the literature, extracted stem cells have a high in vitro proliferation rate, good proliferation in the culture plate, and there is a lower chance of subsequent rejection (Francis et al., 2018).

## 6. Conclusion

1. Intra-articular treatment effectively reduced symptoms of temporomandibular joint dysfunction, such as mouth opening and pain. All four materials significantly improved these parameters, thus significantly improving the patients' quality of life.
2. Corticosteroids are effective in joint therapy in the short term, but compared to the other examined intraarticular substances, their effect is more moderate. In addition, their potential side effects and short duration of action do not give them an advantage over hyaluronic acid and autologous blood products.
3. The hyaluronic acid showed slightly better long-term results in increasing mouth opening than autologous blood products, but this difference is not considered relevant in light of our results.
4. No significant difference was found between the two molecular weight forms of hyaluronic acid in the short and long term. The higher molecular weight version showed a slight relapse after the long-term follow-up, but the difference was not significant. Moreover, it did not change the significant improvement seen in this group at 12 months follow-up.
5. Three doses of hyaluronic acid are indicated and necessary, given the progressive pain reduction following injections.
6. The one-time administration of autologous blood products is effective, and its effect is not worse than the hyaluronic acid with three injections protocol. Therefore, we do not consider increasing the number of injections necessary.
7. No significant difference was found when comparing the two autologous blood products, with similar results overall. However, due to the simplicity of the preparation method and the more favorable biological properties reported in the literature, I-PRF seems beneficial to PRP.

8. We recommend using I-PRF in the intraarticular treatment of temporomandibular disorders, taking advantage of using 100% biocompatible material and avoiding potential allergic adverse effects.

New results:

1. Our study compared first the effects of a single corticosteroid injection, three times given hyaluronic acid injections, single PRP, and single I-PRF on the internal derangement of the temporomandibular joint.
2. To the best of our knowledge, this study compared first the HA, PRP, and I-PRF intraarticular injections without arthrocentesis, showing the efficacy of intraarticular injection without an additional flushing process.
3. Our research was the first in Hungary to compare the autologous blood products in TMD and conclude the beneficiary of using I-PRF.
4. This study first compared the four intraarticular materials in Hungary according to the Fonseca classification. The grading system effectively evaluates the preoperative status; it is quick, simple, and understandable for the patients.

## 7. Summary

Temporomandibular joint disorders (TMD) compose an umbrella term involving internal damage to the joint, degenerative changes, and myofascial components. These factors can lead to joint sounds, chronic pain, and limited joint movement, significantly affecting the quality of life. The disease mainly affects the middle-aged working population; therefore, it is a social burden worldwide. The treatment aims to relieve the pain and improve joint functions. Intraarticular treatment is a minimally invasive method that combines the advantages of non-invasive and surgical therapies and has become the focus of attention in recent decades.

Our prospective study included 77 patients who had undergone conservative treatment but whose residual symptoms required further care. During clinical examination, Fonseca's questionnaire was used to examine the severity of the TMD. The degree of mouth opening was measured by millimeters in the inter-incisional area. The Visual Analog Scale was used for the pain assessment. The intraarticular protocols recommended in the international literature were used for treatment. At the 6-month and 12-month postoperative follow-up, the extent of mouth opening was repeatedly measured, and the pain intensity was recorded. Pre- and postoperative results were compared based on these factors.

The effects of intraarticular corticosteroids, hyaluronic acid, PRP, and I-PRF were compared in the study. Each substance significantly improved the degree of mouth opening and pain reduction, but the corticosteroid showed the most moderate results. There was no significant difference between the two autologous blood products. The hyaluronic acid showed a slightly better effect on the mouth opening in the long term, but overall, the results were similar to PRP and I-PRF. No significant difference was found between hyaluronic acid formulations of different molecular weights.

We concluded that in light of our long-term results, the use of I-PRF is recommended in the internal derangement of the temporomandibular joint. Using the patient's blood product eliminates the risk of allergic reactions, minimizes the potential for contamination and complications, and reduces the discomfort for the patient to a single injection.



## 8. References

- Abate, M. & Salini, V. (2012). Hyaluronic acid in the treatment of osteoarthritis: What is new. In: Q. Chen (Ed.), *Osteoarthritis – diagnosis, treatment, and surgery* (pp 101-122). London, IntechOpen.
- Abd El Raouf, M., Wang, X., Miusi, S., Chai, J., Mohamed AbdEl-Aal, A. B., Nefissa Helmy, M. M., Ghanaati, S., Choukroun, J., Choukroun, E., Zhang, Y., & Miron, R. J. (2019). Injectable-platelet-rich fibrin using the low-speed centrifugation concept improves cartilage regeneration when compared to platelet-rich plasma. *Platelets*, *30*(2), 213–221.  
<https://doi.org/10.1080/09537104.2017.1401058>
- Al-Jundi, M. A., John, M. T., Setz, J. M., Szentpétery, A., & Kuss, O. (2008). Meta-analysis of treatment need for temporomandibular disorders in adult nonpatients. *Journal of orofacial pain*, *22*(2), 97–107.
- Alpaslan, G. H., & Alpaslan, C. (2001). Efficacy of temporomandibular joint arthrocentesis with and without injection of sodium hyaluronate in treatment of internal derangements. *Journal of oral and maxillofacial surgery: official journal of the American Association of Oral and Maxillofacial Surgeons*, *59*(6), 613–619.  
<https://doi.org/10.1053/joms.2001.23368>
- American Society of Temporomandibular Joint Surgeons. (2003). Guidelines for diagnosis and management of disorders involving the temporomandibular joint and related musculoskeletal structures. *Cranio : the journal of craniomandibular practice*, *21*(1), 68–76.
- Anand, A. (2018). The clinical efficacy of injectable platelet rich fibrin in the treatment of degenerative temporomandibular joint disease. *Novel Techniques in Arthritis & Bone Research*. *3*(1), 555-606.

- Anderson, D. M., Sinclair, P. M., & McBride, K. M. (1991). A clinical evaluation of temporomandibular joint disk plication surgery. *American journal of orthodontics and dentofacial orthopedics : official publication of the American Association of Orthodontists, its constituent societies, and the American Board of Orthodontics*, 100(2), 156–162. [https://doi.org/10.1016/S0889-5406\(05\)81522-7](https://doi.org/10.1016/S0889-5406(05)81522-7)
- Angyal, J. (2002). Az orofaciális fájdalom: 2. rész. *Magyar Fogorvos*. 11(3), 133-138.
- Barkin, S., & Weinberg, S. (2000). Internal derangements of the temporomandibular joint: the role of arthroscopic surgery and arthrocentesis. *Journal (Canadian Dental Association)*, 66(4), 199–203.
- Basterzi, Y., Sari, A., Demirkan, F., Unal, S., & Arslan, E. (2009). Intraarticular hyaluronic acid injection for the treatment of reducing and nonreducing disc displacement of the temporomandibular joint. *Annals of plastic surgery*, 62(3), 265–267. <https://doi.org/10.1097/SAP.0b013e31817dad1>
- Bezuur, N. J., Habets, L. L., & Hansson, T. L. (1988). The effect of therapeutic laser treatment in patients with craniomandibular disorders. *Journal of craniomandibular disorders : facial & oral pain*, 2(2), 83–86.
- Bicaj, T., Shala, K., Krasniqi, T. P., Ahmedi, E., Dula, L., & Lila-Krasniqi, Z. (2017). Frequency of Symptoms of Temporomandibular Disorders among Prishtina Dental Students. *Open access Macedonian journal of medical sciences*, 5(6), 781–784. <https://doi.org/10.3889/oamjms.2017.165>
- Bjørnland, T., Gjaerum, A. A., & Møystad, A. (2007). Osteoarthritis of the temporomandibular joint: an evaluation of the effects and complications of corticosteroid injection compared with injection with sodium hyaluronate. *Journal of oral rehabilitation*, 34(8), 583–589. <https://doi.org/10.1111/j.1365-2842.2007.01759.x>
- Bose, B., & Balzarini, M. A. (2002). Bone graft gel: autologous growth factors used with autograft bone for lumbar spine fusions. *Advances in therapy*, 19(4), 170–175. <https://doi.org/10.1007/BF02848692>

- Calderon, P.dosS., Tabaquim, M.deL., Oliveira, L. C., Camargo, A. P., Ramos Netto, T.deC., & Conti, P. C. (2011). Effectiveness of cognitive-behavioral therapy and amitriptyline in patients with chronic temporomandibular disorders: a pilot study. *Brazilian dental journal*, 22(5), 415–421. <https://doi.org/10.1590/s0103-64402011000500012>
- Campbell, K. A., Saltzman, B. M., Mascarenhas, R., Khair, M. M., Verma, N. N., Bach, B. R., Jr, & Cole, B. J. (2015). Does Intra-articular Platelet-Rich Plasma Injection Provide Clinically Superior Outcomes Compared With Other Therapies in the Treatment of Knee Osteoarthritis? A Systematic Review of Overlapping Meta-analyses. *Arthroscopy : the journal of arthroscopic & related surgery : official publication of the Arthroscopy Association of North America and the International Arthroscopy Association*, 31(11), 2213–2221. <https://doi.org/10.1016/j.arthro.2015.03.041>
- Campos, J. A., Carrascosa, A. C., Bonafé, F. S., & Maroco, J. (2014). Severity of temporomandibular disorders in women: validity and reliability of the Fonseca Anamnestic Index. *Brazilian oral research*, 28, 16–21. <https://doi.org/10.1590/s1806-83242013005000026>
- Carvajal, W. A., & Laskin, D. M. (2000). Long-term evaluation of arthrocentesis for the treatment of internal derangements of the temporomandibular joint. *Journal of oral and maxillofacial surgery : official journal of the American Association of Oral and Maxillofacial Surgeons*, 58(8), 852–857. <https://doi.org/10.1053/joms.2000.8201>
- Civinini, R., Macera, A., Nistri, L., Redl, B., & Innocenti, M. (2011). The use of autologous blood-derived growth factors in bone regeneration. *Clinical cases in mineral and bone metabolism : the official journal of the Italian Society of Osteoporosis, Mineral Metabolism, and Skeletal Diseases*, 8(1), 25–31.
- Conti, P. C. (1997). Low level laser therapy in the treatment of temporomandibular disorders (TMD): a double-blind pilot study. *Cranio : the journal of craniomandibular practice*, 15(2), 144–149. <https://doi.org/10.1080/08869634.1997.11746005>

- Conti, P. C., Pinto-Fiamengui, L. M., Cunha, C. O., & Conti, A. C. (2012). Orofacial pain and temporomandibular disorders: the impact on oral health and quality of life. *Brazilian oral research*, *26 Suppl 1*, 120–123. <https://doi.org/10.1590/s1806-83242012000700018>
- Costen, J.B. (1934). Syndrome of Ear and Sinus Symptoms, Dependent on Disturbed Function of the TM Joint. *Annals of Otology, Rhinology & Laryngology*, *43*, 1-15. <https://doi.org/10.1177/000348943404300101>
- Cömert, K. S. (2021). Does glucosamine, chondroitin sulfate, and methylsulfonylmethane supplementation improve the outcome of temporomandibular joint osteoarthritis management with arthrocentesis plus intraarticular hyaluronic acid injection. A randomized clinical trial. *Journal of cranio-maxillo-facial surgery : official publication of the European Association for Cranio-Maxillo-Facial Surgery*, *49(8)*, 711–718. <https://doi.org/10.1016/j.jcms.2021.02.012>
- DelRossi, A. J., Cernaianu, A. C., Vertrees, R. A., Wacker, C. J., Fuller, S. J., Cilley, J. H., Jr, & Baldino, W. A. (1990). Platelet-rich plasma reduces postoperative blood loss after cardiopulmonary bypass. *The Journal of thoracic and cardiovascular surgery*, *100(2)*, 281–286.
- Derwich, M., Mitus-Kenig, M., & Pawlowska, E. (2021a). Is the Temporomandibular Joints' Reciprocal Clicking Related to the Morphology and Position of the Mandible, as Well as to the Sagittal Position of Lower Incisors?-A Case-Control Study. *International journal of environmental research and public health*, *18(9)*, 4994. <https://doi.org/10.3390/ijerph18094994>
- Derwich, M., Mitus-Kenig, M., & Pawlowska, E. (2021b). Mechanisms of Action and Efficacy of Hyaluronic Acid, Corticosteroids and Platelet-Rich Plasma in the Treatment of Temporomandibular Joint Osteoarthritis-A Systematic Review. *International journal of molecular sciences*, *22(14)*, 7405. <https://doi.org/10.3390/ijms22147405>
- Dohan, D. M., Choukroun, J., Diss, A., Dohan, S. L., Dohan, A. J., Mouhyi, J., & Gogly, B. (2006). Platelet-rich fibrin (PRF): a second-generation platelet concentrate. Part I: technological concepts and evolution. *Oral surgery, oral medicine, oral*

*pathology, oral radiology, and endodontics*, 101(3), e37–e44.  
<https://doi.org/10.1016/j.tripleo.2005.07.008>

Dworkin, S. F., & LeResche, L. (1992). Research diagnostic criteria for temporomandibular disorders: review, criteria, examinations and specifications, critique. *Journal of craniomandibular disorders : facial & oral pain*, 6(4), 301–355.

Duygu, G., Güler, N., Cam, B., & Kürkcü, M. (2011). The effects of high molecular weight hyaluronic acid (Hylan G-F 20) on experimentally induced temporomandibular joint osteoarthritis: part II. *International journal of oral and maxillofacial surgery*, 40(12), 1406–1413.  
<https://doi.org/10.1016/j.ijom.2011.07.909>

Egészségügyi Szakmai Kollégium. (2020). Egészségügyi szakmai irányelv – a temporomandibuláris fájdalom és diszfunkció diagnosztikájáról és terápiájáról. Retrieved 2021 dec 10 from <http://kollegium.aeek.hu>

Escoda-Francolí, J., Vázquez-Delgado, E., & Gay-Escoda, C. (2010). Scientific evidence on the usefulness of intraarticular hyaluronic acid injection in the management of temporomandibular dysfunction. *Medicina oral, patologia oral y cirugia bucal*, 15(4), e644–e648. <https://doi.org/10.4317/medoral.15.e644>

Evans, C. H., Kraus, V. B., & Setton, L. A. (2014). Progress in intra-articular therapy. *Nature reviews. Rheumatology*, 10(1), 11–22.  
<https://doi.org/10.1038/nrrheum.2013.159>

Fernández-Ferro, M., Fernández-Sanromán, J., Blanco-Carrión, A., Costas-López, A., López-Betancourt, A., Arenaz-Bua, J., & Stavaru Marinescu, B. (2017). Comparison of intra-articular injection of plasma rich in growth factors versus hyaluronic acid following arthroscopy in the treatment of temporomandibular dysfunction: A randomised prospective study. *Journal of cranio-maxillo-facial surgery : official publication of the European Association for Cranio-Maxillo-Facial Surgery*, 45(4), 449–454. <https://doi.org/10.1016/j.jcms.2017.01.010>

Ferreira, N., Masterson, D., Lopes de Lima, R., de Souza Moura, B., Oliveira, A. T., Kelly da Silva Fidalgo, T., Carvalho, A. C. P., DosSantos, M. F., & Grossmann, E. (2018). Efficacy of viscosupplementation with hyaluronic acid in

- temporomandibular disorders: A systematic review. *Journal of cranio-maxillo-facial surgery : official publication of the European Association for Cranio-Maxillo-Facial Surgery*, 46(11), 1943–1952.  
<https://doi.org/10.1016/j.jcms.2018.08.007>
- Fonseca, D. M., Bonfante G., Valle A. L., & De Freitas S. F. T. (1994). Diagnóstico pela anamnese da disfunção craniomandibular. *Revista Gaucha de Odontologia*, 4(1), 23–32.
- Francis, S. L., Duchi, S., Onofrillo, C., Di Bella, C., & Choong, P. F. M. (2018). Adipose-Derived Mesenchymal Stem Cells in the Use of Cartilage Tissue Engineering: The Need for a Rapid Isolation Procedure. *Stem cells international*, 8947548.  
<https://doi.org/10.1155/2018/8947548>
- Frost, D. E., & Kendell, B. D. (1999). Part II: The use of arthrocentesis for treatment of temporomandibular joint disorders. *Journal of oral and maxillofacial surgery : official journal of the American Association of Oral and Maxillofacial Surgeons*, 57(5), 583–587. [https://doi.org/10.1016/s0278-2391\(99\)90080-0](https://doi.org/10.1016/s0278-2391(99)90080-0)
- Gallatz, K. (2006). Articulatio temporomandibularis és a ráható izmok. In: E. Fehér (Ed.), *Maxillofacialis anatómia* (pp. 25-32). Medicina Könyvkiadó Zrt.
- Gam, A. N., Thorsen, H., & Lønnberg, F. (1993). The effect of low-level laser therapy on musculoskeletal pain: a meta-analysis. *Pain*, 52(1), 63–66.  
[https://doi.org/10.1016/0304-3959\(93\)90114-5](https://doi.org/10.1016/0304-3959(93)90114-5)
- Gebhardt, S., Heinzl-Gutenbrunner, M., & König, U. (2016). Pain Relief in Depressive Disorders: A Meta-Analysis of the Effects of Antidepressants. *Journal of clinical psychopharmacology*, 36(6), 658–668.  
<https://doi.org/10.1097/JCP.0000000000000604>
- Ghosh, P., & Guidolin, D. (2002). Potential mechanism of action of intra-articular hyaluronan therapy in osteoarthritis: are the effects molecular weight dependent?. *Seminars in arthritis and rheumatism*, 32(1), 10–37.  
<https://doi.org/10.1053/sarh.2002.33720>
- Gokçe Kutuk, S., Gökçe, G., Arslan, M., Özkan, Y., Kütük, M., & Kursat Arıkan, O. (2019). Clinical and Radiological Comparison of Effects of Platelet-Rich Plasma, Hyaluronic Acid, and Corticosteroid Injections on Temporomandibular Joint

- Osteoarthritis. *The Journal of craniofacial surgery*, 30(4), 1144–1148.  
<https://doi.org/10.1097/SCS.00000000000005211>
- Goldstein, R. E., & Auclair Clark, W. (2017). The clinical management of awake bruxism. *Journal of the American Dental Association (1939)*, 148(6), 387–391.  
<https://doi.org/10.1016/j.adaj.2017.03.005>
- González, L. V., López, J. P., Díaz-Báez, D., & Gómez-Delgado, A. (2021). Correlation between MRI-diagnosed joint effusion and demographic, clinical, imaging, and arthroscopic findings of the temporomandibular joint. *Journal of cranio-maxillo-facial surgery : official publication of the European Association for Cranio-Maxillo-Facial Surgery*, 49(12), 1169–1174.  
<https://doi.org/10.1016/j.jcms.2021.06.019>
- Greene, C. S., & Marbach, J. J. (1982). Epidemiologic studies of mandibular dysfunction: a critical review. *The Journal of prosthetic dentistry*, 48(2), 184–190.  
[https://doi.org/10.1016/0022-3913\(82\)90110-x](https://doi.org/10.1016/0022-3913(82)90110-x)
- Guarda-Nardini, L., Masiero, S., & Marioni, G. (2005). Conservative treatment of temporomandibular joint osteoarthrosis: intra-articular injection of sodium hyaluronate. *Journal of oral rehabilitation*, 32(10), 729–734.  
<https://doi.org/10.1111/j.1365-2842.2005.01505.x>
- Guarda-Nardini, L., Piccotti, F., Mogno, G., Favero, L., & Manfredini, D. (2012). Age-related differences in temporomandibular disorder diagnoses. *Cranio : the journal of craniomandibular practice*, 30(2), 103–109.  
<https://doi.org/10.1179/crn.2012.015>
- Guarda-Nardini, L., Cadorin, C., Frizziero, A., Ferronato, G., & Manfredini, D. (2012). Comparison of 2 hyaluronic acid drugs for the treatment of temporomandibular joint osteoarthritis. *Journal of oral and maxillofacial surgery : official journal of the American Association of Oral and Maxillofacial Surgeons*, 70(11), 2522–2530. <https://doi.org/10.1016/j.joms.2012.07.020>
- Gundlach, K. K. (1990). Long-term results following surgical treatment of internal derangement of the temporomandibular joint. *Journal of cranio-maxillo-facial surgery : official publication of the European Association for Cranio-Maxillo-Facial Surgery*, 18(5), 206–209. [https://doi.org/10.1016/s1010-5182\(05\)80412-3](https://doi.org/10.1016/s1010-5182(05)80412-3)

- Hancı, M., Karamese, M., Tosun, Z., Aktan, T. M., Duman, S., & Savaci, N. (2015). Intra-articular platelet-rich plasma injection for the treatment of temporomandibular disorders and a comparison with arthrocentesis. *Journal of cranio-maxillo-facial surgery : official publication of the European Association for Cranio-Maxillo-Facial Surgery*, 43(1), 162–166. <https://doi.org/10.1016/j.jcms.2014.11.002>
- Hansson, T. L. (1989). Infrared laser in the treatment of craniomandibular disorders, arthrogenous pain. *The Journal of prosthetic dentistry*, 61(5), 614–617. [https://doi.org/10.1016/0022-3913\(89\)90287-4](https://doi.org/10.1016/0022-3913(89)90287-4)
- Harba, A. N., & Harfoush, M. (2021). Evaluation of the participation of hyaluronic acid with platelet-rich plasma in the treatment of temporomandibular joint disorders. *Dental and medical problems*, 58(1), 81–88. <https://doi.org/10.17219/dmp/127446>
- Hayes, M.H.S. & Patterson, D.G. (1921). Experimental development of the graphic rating method. *Psychological Bulletin*. 18, 98-99.
- Helkimo, M. (1974). Studies on function and dysfunction of the masticatory system. II. Index for anamnestic and clinical dysfunction and occlusal state. *Svensk tandlakare tidskrift. Swedish dental journal*, 67(2), 101–121.
- Hepguler, S., Akkoc, Y. S., Pehlivan, M., Ozturk, C., Celebi, G., Saracoglu, A., & Ozpinar, B. (2002). The efficacy of intra-articular sodium hyaluronate in patients with reducing displaced disc of the temporomandibular joint. *Journal of oral rehabilitation*, 29(1), 80–86. <https://doi.org/10.1046/j.1365-2842.2002.00807.x>
- Herpich, C. M., Amaral, A. P., Leal-Junior, E. C., Tosato, J.deP., Gomes, C. A., Arruda, É. E., Glória, I. P., Garcia, M. B., Barbosa, B. R., Rodrigues, M. S., Silva, K. L., El Hage, Y., Politti, F., Gonzalez, T.deO., Bussadori, S. K., & Biasotto-Gonzalez, D. A. (2015). Analysis of laser therapy and assessment methods in the rehabilitation of temporomandibular disorder: a systematic review of the literature. *Journal of physical therapy science*, 27(1), 295–301. <https://doi.org/10.1589/jpts.27.295>
- Horton, C. P. (1953). Treatment of arthritic temporomandibular joints by intra-articular injection of hydrocortisone. *Oral surgery, oral medicine, and oral pathology*, 6(7), 826–829. [https://doi.org/10.1016/0030-4220\(53\)90286-2](https://doi.org/10.1016/0030-4220(53)90286-2)



- Hosgor, H. (2020). Is arthrocentesis plus hyaluronic acid superior to arthrocentesis alone in the treatment of disc displacement without reduction in patients with bruxism?. *Journal of cranio-maxillo-facial surgery : official publication of the European Association for Cranio-Maxillo-Facial Surgery*, 48(11), 1023–1027. <https://doi.org/10.1016/j.jcms.2020.07.008>
- Huang, G. J., LeResche, L., Critchlow, C. W., Martin, M. D., & Drangsholt, M. T. (2002). Risk factors for diagnostic subgroups of painful temporomandibular disorders (TMD). *Journal of dental research*, 81(4), 284–288. <https://doi.org/10.1177/154405910208100412>
- Huber, M. A., & Hall, E. H. (1990). A comparison of the signs of temporomandibular joint dysfunction and occlusal discrepancies in a symptom-free population of men and women. *Oral surgery, oral medicine, and oral pathology*, 70(2), 180–183. [https://doi.org/10.1016/0030-4220\(90\)90115-9](https://doi.org/10.1016/0030-4220(90)90115-9)
- Ingawalé, S., & Goswami, T. (2009). Temporomandibular joint: disorders, treatments, and biomechanics. *Annals of biomedical engineering*, 37(5), 976–996. <https://doi.org/10.1007/s10439-009-9659-4>
- Iturriaga, V., Vásquez, B., Bornhardt, T., & Del Sol, M. (2021). Effects of low and high molecular weight hyaluronic acid on the osteoarthritic temporomandibular joint in rabbit. *Clinical oral investigations*, 25(7), 4507–4518. <https://doi.org/10.1007/s00784-020-03763-x>
- Jász, M., Schmidt, P., Angyal, J., Balogh, I. & Hermann, P. (2009). A vizsgálat menete és terápiás lehetőségek a temporomandibuláris ízület megbetegedéseinél 2. rész. *Magyar Fogorvos*, 18, 273-278.
- Jász M. & Schmidt P. (2018). Klinikai betegvizsgálat. In P. Hermann (Ed.), *Gnatológia* (pp. 306-313). Semmelweis Kiadó.
- Jerolimov, V. (2009). Temporomandibular Joint Disorders and Orofacial Pain. *Medical Sciences*. 33, 53-57.
- Jüni, P., Hari, R., Rutjes, A. W., Fischer, R., Sillelta, M. G., Reichenbach, S., & da Costa, B. R. (2015). Intra-articular corticosteroid for knee osteoarthritis. *The Cochrane database of systematic reviews*, 2015(10), CD005328. <https://doi.org/10.1002/14651858.CD005328.pub3>

- Kapugi, M., & Cunningham, K. (2019). Corticosteroids. *Orthopedic nursing*, 38(5), 336–339. <https://doi.org/10.1097/NOR.0000000000000595>
- Karadayi, U., & Gursoytrak, B. (2021). Randomized controlled trial of arthrocentesis with or without PRF for internal derangement of the TMJ. *Journal of cranio-maxillo-facial surgery : official publication of the European Association for Cranio-Maxillo-Facial Surgery*, 49(5), 362–367. <https://doi.org/10.1016/j.jcms.2021.01.018>
- Kircos, L. T., Ortendahl, D. A., Mark, A. S., & Arakawa, M. (1987). Magnetic resonance imaging of the TMJ disc in asymptomatic volunteers. *Journal of oral and maxillofacial surgery : official journal of the American Association of Oral and Maxillofacial Surgeons*, 45(10), 852–854. [https://doi.org/10.1016/0278-2391\(87\)90235-7](https://doi.org/10.1016/0278-2391(87)90235-7)
- Klatkiewicz, T., Gawriołek, K., Pobudek Radzikowska, M., & Czajka-Jakubowska, A. (2018). Ultrasonography in the Diagnosis of Temporomandibular Disorders: A Meta-Analysis. *Medical science monitor : international medical journal of experimental and clinical research*, 24, 812–817. <https://doi.org/10.12659/msm.908810>
- Laskin, D. M. (1969). Etiology of the pain-dysfunction syndrome. *Journal of the American Dental Association (1939)*, 79(1), 147–153. <https://doi.org/10.14219/jada.archive.1969.0234>
- Lemos, G. A., Rissi, R., Pimentel, E. R., & Palomari, E. T. (2015). Effects of high molecular weight hyaluronic acid on induced arthritis of the temporomandibular joint in rats. *Acta histochemica*, 117(6), 566–575. <https://doi.org/10.1016/j.acthis.2015.05.003>
- Li, C., Su, N., Yang, X., Yang, X., Shi, Z., & Li, L. (2012). Ultrasonography for detection of disc displacement of temporomandibular joint: a systematic review and meta-analysis. *Journal of oral and maxillofacial surgery : official journal of the American Association of Oral and Maxillofacial Surgeons*, 70(6), 1300–1309. <https://doi.org/10.1016/j.joms.2012.01.003>

- Li, D. T. S., & Leung, Y. Y. (2021). Temporomandibular Disorders: Current Concepts and Controversies in Diagnosis and Management. *Diagnostics (Basel, Switzerland)*, *11*(3), 459. <https://doi.org/10.3390/diagnostics11030459>
- Linde, C., Isacsson, G., & Jonsson, B. G. (1995). Outcome of 6-week treatment with transcutaneous electric nerve stimulation compared with splint on symptomatic temporomandibular joint disk displacement without reduction. *Acta odontologica Scandinavica*, *53*(2), 92–98. <https://doi.org/10.3109/00016359509005953>
- List, T., & Jensen, R. H. (2017). Temporomandibular disorders: Old ideas and new concepts. *Cephalalgia: an international journal of headache*, *37*(7), 692–704. <https://doi.org/10.1177/0333102416686302>
- Lora, V. R., Canales, G.deL., Gonçalves, L. M., Meloto, C. B., & Barbosa, C. M. (2016). Prevalence of temporomandibular disorders in postmenopausal women and relationship with pain and HRT. *Brazilian oral research*, *30*(1), e100. <https://doi.org/10.1590/1807-3107BOR-2016.vol30.0100>
- Maixner, W., Fillingim, R. B., Williams, D. A., Smith, S. B., & Slade, G. D. (2016). Overlapping Chronic Pain Conditions: Implications for Diagnosis and Classification. *The journal of pain*, *17*(9 Suppl), T93–T107. <https://doi.org/10.1016/j.jpain.2016.06.002>
- Man, D., Plosker, H., & Winland-Brown, J. E. (2001). The use of autologous platelet-rich plasma (platelet gel) and autologous platelet-poor plasma (fibrin glue) in cosmetic surgery. *Plastic and reconstructive surgery*, *107*(1), 229–239. <https://doi.org/10.1097/00006534-200101000-00037>
- Manfredini, D., Piccotti, F., & Guarda-Nardini, L. (2010a). Hyaluronic acid in the treatment of TMJ disorders: a systematic review of the literature. *Cranio : the journal of craniomandibular practice*, *28*(3), 166–176. <https://doi.org/10.1179/crn.2010.023>
- Manfredini, D., Piccotti, F., Ferronato, G., & Guarda-Nardini, L. (2010b). Age peaks of different RDC/TMD diagnoses in a patient population. *Journal of dentistry*, *38*(5), 392–399. <https://doi.org/10.1016/j.jdent.2010.01.006>

- Manfredini, D. & Guarda-Nardini, L. (2010). TMD epidemiology and classification. In D. Manfredini (Ed.), *Current concepts on temporomandibular disorders* (pp 25-39). Berlin: Quintessence.
- Manfredini, D., Rancitelli, D., Ferronato, G., & Guarda-Nardini, L. (2012). Arthrocentesis with or without additional drugs in temporomandibular joint inflammatory-degenerative disease: comparison of six treatment protocols\*. *Journal of oral rehabilitation*, 39(4), 245–251. <https://doi.org/10.1111/j.1365-2842.2011.02265.x>
- Matsumoto, K., Honda, K., Ohshima, M., Yamaguchi, Y., Nakajima, I., Micke, P., & Otsuka, K. (2006). Cytokine profile in synovial fluid from patients with internal derangement of the temporomandibular joint: a preliminary study. *Dento maxillo facial radiology*, 35(6), 432–441. <https://doi.org/10.1259/dmfr/77288976>
- Mazzetto, M. O., Rodrigues, C. A., Magri, L. V., Melchior, M. O., & Paiva, G. (2014). Severity of TMD related to age, sex and electromyographic analysis. *Brazilian dental journal*, 25(1), 54–58. <https://doi.org/10.1590/0103-6440201302310>
- McCarty, W. L., & Farrar, W. B. (1979). Surgery for internal derangements of the temporomandibular joint. *The Journal of prosthetic dentistry*, 42(2), 191–196. [https://doi.org/10.1016/0022-3913\(79\)90174-4](https://doi.org/10.1016/0022-3913(79)90174-4)
- McNeill, C., Mohl N. D., Rugh J. D., & Tanaka T. T. (1990). Temporomandibular Disorders: Diagnosis, Management, Education, and Research. *The Journal of the American Dental Association*, 120(3), 253-263. <https://doi.org/10.14219/jada.archive.1990.0049>.
- Moreland, L. W. (2003). Intra-articular hyaluronan (hyaluronic acid) and hylans for the treatment of osteoarthritis: mechanisms of action. *Arthritis research & therapy*, 5(2), 54–67. <https://doi.org/10.1186/ar623>
- Mountziaris, P. M., Kramer, P. R., & Mikos, A. G. (2009). Emerging intra-articular drug delivery systems for the temporomandibular joint. *Methods (San Diego, Calif.)*, 47(2), 134–140. <https://doi.org/10.1016/j.ymeth.2008.09.001>
- Murakami, K. (2013). Rationale of arthroscopic surgery of the temporomandibular joint. *Journal of oral biology and craniofacial research*, 3(3), 126–134. <https://doi.org/10.1016/j.jobcr.2013.07.002>

- Nitzan, D. W., Dolwick, M. F., & Martinez, G. A. (1991). Temporomandibular joint arthrocentesis: a simplified treatment for severe, limited mouth opening. *Journal of oral and maxillofacial surgery : official journal of the American Association of Oral and Maxillofacial Surgeons*, 49(11), 1163–1170. [https://doi.org/10.1016/0278-2391\(91\)90409-f](https://doi.org/10.1016/0278-2391(91)90409-f)
- Ohrbach, R., & Dworkin, S. F. (2016). The Evolution of TMD Diagnosis: Past, Present, Future. *Journal of dental research*, 95(10), 1093–1101. <https://doi.org/10.1177/0022034516653922>
- Ohnishi, M. (1990). Arthroscopy and arthroscopic surgery of the temporomandibular joint (T.M.J.). *Revue de stomatologie et de chirurgie maxillo-faciale*, 91(2), 143–150.
- Okeson, J. P., & Bell W. E. (1995). *Bell's Orofacial Pains*. 5th ed. Chicago: Quintessence. pp 348–55.
- Okeson, J. P. (1996). Orofacial pain: guidelines for assessment, diagnosis, and management, ed.3. Quintessence. pp 45-52.
- Pietrzak, W. S., & Eppley, B. L. (2005). Platelet rich plasma: biology and new technology. *The Journal of craniofacial surgery*, 16(6), 1043–1054. <https://doi.org/10.1097/01.scs.0000186454.07097.bf>
- Pihut, M., Szuta, M., Ferendiuk, E., & Zeńczak-Więckiewicz, D. (2014). Evaluation of pain regression in patients with temporomandibular dysfunction treated by intra-articular platelet-rich plasma injections: a preliminary report. *BioMed research international*, 132369. <https://doi.org/10.1155/2014/132369>
- Pihut, M., & Gala, A. (2020). The Application of Intra-Articlr Injections for Management of the Consequences of Disc Displacement without Reduction. *International journal of environmental research and public health*, 17(13), 4726. <https://doi.org/10.3390/ijerph17134726>.
- Pihut, M., Pac, A., & Gala, A. (2021). Frequency of occurrence of the pain form of the temporomandibular disorders and gender distribution. *Folia medica Cracoviensia*, 61(2), 25–33.
- Plesh, O., Curtis, D., Levine, J., & McCall, W. D., Jr (2000). Amitriptyline treatment of chronic pain in patients with temporomandibular disorders. *Journal of oral*

*rehabilitation*, 27(10), 834–841. <https://doi.org/10.1046/j.1365-2842.2000.00572.x>

Poveda Roda, R., Bagan, J. V., Díaz Fernández, J. M., Hernández Bazán, S., & Jiménez Soriano, Y. (2007). Review of temporomandibular joint pathology. Part I: classification, epidemiology and risk factors. *Medicina oral, patología oral y cirugía bucal*, 12(4), E292–E298.

Poveda Roda, R., Díaz Fernández, J. M., Hernández Bazán, S., Jiménez Soriano, Y., Margaix, M., & Sarrión, G. (2008). A review of temporomandibular joint disease (TMJD). Part II: Clinical and radiological semiology. Morbidity processes. *Medicina oral, patología oral y cirugía bucal*, 13(2), E102–E109.

Ramfjord S. P., & Ash M. M. (1971). Occlusion. Philadelphia: WB Saunders

Rani, S., Pawah, S., Gola, S., & Bakshi, M. (2017). Analysis of Helkimo index for temporomandibular disorder diagnosis in the dental students of Faridabad city: A cross-sectional study. *Journal of Indian Prosthodontic Society*, 17(1), 48–52. <https://doi.org/10.4103/0972-4052.194941>

Rugh, J. D., & Solberg, W. K. (1976). Psychological implications in temporomandibular pain and dysfunction. *Oral sciences reviews*, 7, 3–30.

Sampson, S., Gerhardt, M., & Mandelbaum, B. (2008). Platelet rich plasma injection grafts for musculoskeletal injuries: a review. *Current reviews in musculoskeletal medicine*, 1(3-4), 165–174. <https://doi.org/10.1007/s12178-008-9032-5>

Sanders, A. E., Maixner, W., Nackley, A. G., Diatchenko, L., By, K., Miller, V. E., & Slade, G. D. (2012). Excess risk of temporomandibular disorder associated with cigarette smoking in young adults. *The journal of pain*, 13(1), 21–31. <https://doi.org/10.1016/j.jpain.2011.08.003>

Santana JR, C. M. R., Bento, V. A. B., Zafalon E. J., Mesquita M. C. & Castillo D. B. (2021). Evaluation of the quality of life and the impact of pain in patients with temporomandibular disorder. *Archives of health investigation*. 10(2), 215-220. <http://dx.doi.org/10.21270/archi.v10i2.5201>

- Schiffman, E., Ohrbach, R., Truelove, E., Look, J., Anderson, G., Goulet, J. P., List, T., Svensson, P., Gonzalez, Y., Lobbezoo, F., Michelotti, A., Brooks, S. L., Ceusters, W., Drangsholt, M., Ettlin, D., Gaul, C., Goldberg, L. J., Haythornthwaite, J. A., Hollender, L., Jensen, R., ... Orofacial Pain Special Interest Group, International Association for the Study of Pain (2014). Diagnostic Criteria for Temporomandibular Disorders (DC/TMD) for Clinical and Research Applications: recommendations of the International RDC/TMD Consortium Network\* and Orofacial Pain Special Interest Group†. *Journal of oral & facial pain and headache*, 28(1), 6–27. <https://doi.org/10.11607/jop.1151>
- Schindler, C., Paessler L., Eckelt U., & Kirch W. (2005). Severe temporomandibular dysfunction and joint destruction after intra-articular injection of triamcinolone. *J Oral Pathol Med*. 34(3):184-186.  
<https://doi.org/10.1111/j.1600-0714.2004.00247.x>
- Schmidt, P. (2018). A Craniomandibuláris diszfunkció epidemiológiája és etiológiája. In P. Hermann (Ed.), *Gnatológia* (pp. 278-295). Semmelweis Kiadó.
- Schwartz, L. (1959). Disorders of the temporomandibular joint. Philadelphia: WB Saunders
- Scrivani, S. J., Keith, D. A., & Kaban, L. B. (2008). Temporomandibular disorders. *The New England journal of medicine*, 359(25), 2693–2705.  
<https://doi.org/10.1056/NEJMra0802472>
- Sousa, B. M., López-Valverde, N., López-Valverde, A., Caramelo, F., Fraile, J. F., Payo, J. H., & Rodrigues, M. J. (2020). Different Treatments in Patients with Temporomandibular Joint Disorders: A Comparative Randomized Study. *Medicina (Kaunas, Lithuania)*, 56(3), 113.  
<https://doi.org/10.3390/medicina56030113>
- Sousa, B. M., López-Valverde, N., López-Valverde, A., Caramelo, F., Rodrigues, M. J. & López-Valverde, N. (2022). Medium-Term Effect of Treatment with Intra-Articular Injection of Sodium Hyaluronate, Betamethasone and Platelet-Rich Plasma in Patients with Temporomandibular Arthralgia: A Retrospective Cohort Study. *Life (Basel, Switzerland)*, 12(11), 1739.  
<https://doi.org/10.3390/life12111739>

- Miron, R. J., Fujioka-Kobayashi, M., Hernandez, M., Kandalam, U., Zhang, Y., Ghanaati, S., & Choukroun, J. (2017). Injectable platelet rich fibrin (i-PRF): opportunities in regenerative dentistry?. *Clinical oral investigations*, *21*(8), 2619–2627. <https://doi.org/10.1007/s00784-017-2063-9>
- Shi, Z., Guo, C., & Awad, M. (2003). Hyaluronate for temporomandibular joint disorders. *Cochrane Database of Systematic Reviews*. 1. CD002970. DOI: 10.1002/14651858.CD002970.
- Snetkov, P., Zakharova, K., Morozkina, S., Olekhovich, R., & Uspenskaya, M. (2020). Hyaluronic Acid: The Influence of Molecular Weight on Structural, Physical, Physico-Chemical, and Degradable Properties of Biopolymer. *Polymers*, *12*(8), 1800. <https://doi.org/10.3390/polym12081800>
- Stasiak, G., Maracci, L. M., de Oliveira Chami, V., Pereira, D. D., Tomazoni, F., Bernardon Silva, T., Ferrazzo, V., & Marquezan, M. (2020). TMD diagnosis: Sensitivity and specificity of the Fonseca Anamnestic Index. *Cranio : the journal of craniomandibular practice*, 1–5. <https://doi.org/10.1080/08869634.2020.1839724>
- Stoustrup, P., Kristensen, K. D., Kùseler, A., Gelineck, J., Cattaneo, P. M., Pedersen, T. K., & Herlin, T. (2008). Reduced mandibular growth in experimental arthritis in the temporomandibular joint treated with intra-articular corticosteroid. *European journal of orthodontics*, *30*(2), 111–119. <https://doi.org/10.1093/ejo/cjm096>
- Szentpétery, A., Fazekas, A., & Mari, A. (1987). An epidemiologic study of mandibular dysfunction dependence on different variables. *Community dentistry and oral epidemiology*, *15*(3), 164–168. <https://doi.org/10.1111/j.1600-0528.1987.tb00507.x>
- Tanaka, E., Detamore, M. S., Tanimoto, K., & Kawai, N. (2008). Lubrication of the temporomandibular joint. *Annals of biomedical engineering*, *36*(1), 14–29. <https://doi.org/10.1007/s10439-007-9401-z>
- Tang, Y. L., Zhu, G. Q., Hu, L., Zheng, M., Zhang, J. Y., Shi, Z. D., & Liang, X. H. (2010). Effects of intra-articular administration of sodium hyaluronate on plasminogen activator system in temporomandibular joints with



- osteoarthritis. *Oral surgery, oral medicine, oral pathology, oral radiology, and endodontics*, 109(4), 541–547. <https://doi.org/10.1016/j.tripleo.2009.11.007>
- Taylor, D. W., Petrera, M., Hendry, M., & Theodoropoulos, J. S. (2011). A systematic review of the use of platelet-rich plasma in sports medicine as a new treatment for tendon and ligament injuries. *Clinical journal of sport medicine : official journal of the Canadian Academy of Sport Medicine*, 21(4), 344–352. <https://doi.org/10.1097/JSM.0b013e31821d0f65>
- Toller, P. A. (1977). Use and misuse of intra-articular corticosteroids in treatment of temporomandibular joint pain. *Proceedings of the Royal Society of Medicine*, 70(7), 461–463.
- Torres, D., Zaror, C., Iturriaga, V., & Tobias, A. (2020). Intra-articular corticosteroids for treatment of temporomandibular joint internal disorders: protocol for systematic review and network meta-analysis. *BMJ open*, 10(9), e034327. <https://doi.org/10.1136/bmjopen-2019-034327>
- Torul, D., Cezairli, B., & Kahveci, K. (2021). The efficacy of intra-articular injectable platelet-rich fibrin application in the management of Wilkes stage III temporomandibular joint internal derangement. *International journal of oral and maxillofacial surgery*, 50(11), 1485–1490. <https://doi.org/10.1016/j.ijom.2021.03.004>
- Trumpy, I. G., Eriksson, J., & Lyberg, T. (1997). Internal derangement of the temporomandibular joint: correlation of arthrographic imaging with surgical findings. *International journal of oral and maxillofacial surgery*, 26(5), 327–330. [https://doi.org/10.1016/s0901-5027\(97\)80790-4](https://doi.org/10.1016/s0901-5027(97)80790-4)
- Türp, J. C., & Schindler, H. (2012). The dental occlusion as a suspected cause for TMDs: epidemiological and etiological considerations. *Journal of oral rehabilitation*, 39(7), 502–512. <https://doi.org/10.1111/j.1365-2842.2012.02304.x>
- Tvrđy, P. (2007). Methods of imaging in the diagnosis of temporomandibular joint disorders. *Biomedical papers of the Medical Faculty of the University Palacky, Olomouc, Czechoslovakia*, 151(1), 133–136. <https://doi.org/10.5507/bp.2007.026>

- Uyanik, J.M., & Murphy, E. (2003). Evaluation and management of TMDs, Part 1. History, epidemiology, classification, anatomy, and patient evaluation. *Dentistry today*. 22. 140-5.
- Vasconcellos, H. A., & Vasconcellos, B. P. H. (2006). Andreae Vesalii: The Temporomandibular Joint. *International Journal of Morphology*, 24(1), 105-109.  
<https://dx.doi.org/10.4067/S0717-95022006000100019>
- Vaszilkó, M. (2018): Az állkapocsízületi diszfunkció invazív kezelési lehetőségei. In: *Gnatológia*, Semmelweis Kiadó (ed: Hermann P). p453-464.
- Vingender, S., Restár, L., Csomó, K. B., Schmidt, P., Hermann, P., & Vaszilkó, M. (2018). Az állkapocsízületi károsodás kezelése szteroiddal, illetve hialuronsavval [Intra-articular steroid and hyaluronic acid treatment of internal derangement of the temporomandibular joint]. *Orvosi hetilap*, 159(36), 1475–1482.  
<https://doi.org/10.1556/650.2018.31138>
- Vingender, S., Dóri, F., Schmidt, P., Hermann, P., & Vaszilkó, M. T. (2023). Evaluation of the efficiency of hyaluronic acid, PRP and I-PRF intra-articular injections in the treatment of internal derangement of the temporomandibular joint: A prospective study. *Journal of cranio-maxillo-facial surgery : official publication of the European Association for Cranio-Maxillo-Facial Surgery*, 51(1), 1–6.  
<https://doi.org/10.1016/j.jcms.2023.01.017>
- Wang, X., Zhang, Y., Choukroun, J., Ghanaati, S., & Miron, R. J. (2017). Behavior of Gingival Fibroblasts on Titanium Implant Surfaces in Combination with either Injectable-PRF or PRP. *International journal of molecular sciences*, 18(2), 331.  
<https://doi.org/10.3390/ijms18020331>
- Warburton, G. (2021). Internal Derangements of the Temporomandibular Joint. In: Bonanthaya, K., Panneerselvam, E., Manuel, S., Kumar, V.V., Rai, A. (eds) *Oral and Maxillofacial Surgery for the Clinician*. Springer, Singapore.
- Warren, M. P., & Fried, J. L. (2001). Temporomandibular disorders and hormones in women. *Cells, tissues, organs*, 169(3), 187–192.  
<https://doi.org/10.1159/000047881>

- Webner, D., Huang, Y., & Hummer, C. D., 3rd (2021). Intraarticular Hyaluronic Acid Preparations for Knee Osteoarthritis: Are Some Better Than Others?. *Cartilage*, *13*(1\_suppl), 1619S–1636S.  
<https://doi.org/10.1177/19476035211017320>
- Wernecke, C., Braun, H. J., & Dragoo, J. L. (2015). The Effect of Intra-articular Corticosteroids on Articular Cartilage: A Systematic Review. *Orthopaedic journal of sports medicine*, *3*(5), 2325967115581163.  
<https://doi.org/10.1177/2325967115581163>
- Wilder-Smith P. (1988). The soft laser: therapeutic tool or popular placebo?. *Oral surgery, oral medicine, and oral pathology*, *66*(6), 654–658.  
[https://doi.org/10.1016/0030-4220\(88\)90311-8](https://doi.org/10.1016/0030-4220(88)90311-8)
- Wilkes, C. H. (1989). Internal derangements of the temporomandibular joint. Pathological variations. *Archives of otolaryngology--head & neck surgery*, *115*(4), 469–477.  
<https://doi.org/10.1001/archotol.1989.01860280067019>
- Wobig, M., Bach, G., Beks, P., Dickhut, A., Runzheimer, J., Schwieger, G., Vetter, G., & Balazs, E. (1999). The role of elastoviscosity in the efficacy of viscosupplementation for osteoarthritis of the knee: a comparison of hylan G-F 20 and a lower-molecular-weight hyaluronan. *Clinical therapeutics*, *21*(9), 1549–1562. [https://doi.org/10.1016/s0149-2918\(00\)80010-7](https://doi.org/10.1016/s0149-2918(00)80010-7)
- Woodall, J., Jr, Tucci, M., Mishra, A., Asfour, A., & Benghuzzi, H. (2008). Cellular effects of platelet rich plasmainterleukin1 release from prp treated macrophages. *Biomedical sciences instrumentation*, *44*, 489–494.
- Yadav, S., Yang, Y., Dutra, E. H., Robinson, J. L., & Wadhwa, S. (2018). Temporomandibular Joint Disorders in Older Adults. *Journal of the American Geriatrics Society*, *66*(6), 1213–1217. <https://doi.org/10.1111/jgs.15354>
- Yeung, R. W., Chow, R. L., Samman, N., & Chiu, K. (2006). Short-term therapeutic outcome of intra-articular high molecular weight hyaluronic acid injection for nonreducing disc displacement of the temporomandibular joint. *Oral surgery, oral medicine, oral pathology, oral radiology, and endodontics*, *102*(4), 453–461.  
<https://doi.org/10.1016/j.tripleo.2005.09.018>

## 9. Bibliography of the candidate's publications

### **Publications on the topic of the thesis**

**Vingender, S.**, Restár, L., Csomó, K. B., Schmidt, P., Hermann, P., & Vaszilkó, M.

Az állkapocsízületi károsodás kezelése szteroiddal, illetve hialuronsavval [Intra-articular steroid and hyaluronic acid treatment of internal derangement of the temporomandibular joint].

*Orvosi hetilap*, 2018. 159(36), 1475–1482.

**IF: 0.564**

**Vingender, S.**, Dóri, F., Schmidt, P., Hermann, P., & Vaszilkó, M. T.

Evaluation of the efficiency of hyaluronic acid, PRP and I-PRF intra-articular injections in the treatment of internal derangement of the temporomandibular joint: A prospective study.

*Journal of cranio-maxillo-facial surgery: official publication of the European Association for Cranio-Maxillo-Facial Surgery*, 2023. 51(1), 1–6.

**IF: 3.1**

### **Dr. Vingender Szonja**

Az osteoarthritis és kezelésének története. [A brief history of the osteoarthritis and its treatment].

*Kaleidoscope Művelődés- Tudomány- és orvostörténeti folyóirat*. 2022. Vol. 12. No. 24.

### **Dr. Vingender Szonja**

A temporomandibuláris ízület és betegségeinek története [The history of the temporomandibular joint and its diseases].

*Kaleidoscope Művelődés- Tudomány- és orvostörténeti folyóirat*. 2020. Vol. 10. No. 21

### **Presentations on the topic of the thesis**

**Vingender Szonja**, Valentovics Anna, Schmidt Péter, Dóri Ferenc, Vaszilkó Mihály  
Temporomandibuláris ízületi diszfunkció kezelése hyaluronsavval, illetve PRP-vel  
*Magyar Arc-, Állcsont-, és Szájsebészeti Társaság XX. Jubileumi Nemzeti  
Kongresszusa, 2016*

**Vingender Szonja**, Vaszilkó Mihály, Schmidt Péter  
Temporomandibularis ízületi diszfunkciók intraarticularis kezelése szteroiddal, illetve  
hyaluronsavval  
*A magyar Arc- Állcsont és Szájsebészeti Társaság XVII. Nemzeti Kongresszusa, 2013*

**Vingender Szonja**, Vaszilkó Mihály, Schmidt Péter  
Temporomandibularis ízületi diszfunkciók intraarticularis kezelése szteroiddal, illetve  
hyaluronsavval  
*XV. Arc- Állcsont és Szájsebészeti Kongresszus és VIII. Danubius Symposium, 2011*

**Vingender Szonja**, Vaszilkó Mihály, Schmidt Péter  
Temporomandibularis ízületi diszfunkciók intraarticularis kezelése szteroiddal, illetve  
hyaluronsavval  
*A Magyar Fogpótlástani Társaság XIX. Kongresszusa, 2011*

### **Presentations on other topics**

**Vingender Szonja**, Pataky Levente, Bogdán Sándor, Joób-F. Árpád  
Rizikótényező-e az impaktált alsó bölcsességfog? Profilaktikus bölcsességfog  
eltávolítás szerepe  
*A magyar Arc- Állcsont és Szájsebészeti Társaság XVIII. Nemzeti Kongresszusa, 2014*

## 10. Acknowledgements

First, I would like to express my gratitude to my supervisor, **Dr. Mihály Vaszilkó**, for teaching and helping me throughout my research since I was a student at Semmelweis University. I thank him for his encouragement, for motivating me throughout the many years, and for helping me learn a method rarely done in Hungary and how to present our results in national and international publications and presentations.

Thanks to **Dr. Szófia Szentpétery**, **Dr. Liza Pelyhe** (the Corvinus University of Budapest, Master of Science), **Dr. László Restár** and **Dr. Krisztián Csomó** for their help in statistical evaluations throughout those long years of researching.

Thanks to **Dr. Péter Lillik**, who was a great help during patient care and administration.

I want to thank my chief, **Dr. Árpád Joób-Fancsaly**, for always supporting me.

I want to thank my colleagues for supporting my research and helping me with my work.

Last but not least, I would like to thank my father, **Dr. István Vingender** (Faculty of Health Sciences, Semmelweis University), who always helped me with wise suggestions and special thanks to my whole family and my friends for their encouragement and support throughout my research journey.

## 11. List of figures and tables

<b>Figure 1.</b> <i>Visual Analog Scale (VAS) (Hayes &amp; Patterson, 1921)).</i> .....	14
<b>Figure 2.</b> <i>MMO (Own work)</i> .....	16
<b>Figure 3.</b> <i>Prevalence of TMD in Hungary (Jász et al., 2009)</i> .....	18
<b>Figure 4.</b> <i>The proportion of the different treatment groups (Vingender et al., 2018; Vingender et al., 2023)</i> .....	33
<b>Figure 5.</b> <i>Average preoperative MMO values in different treatment groups (Vingender et al., 2018; Vingender et al., 2023)</i> .....	38
<b>Figure 6.</b> <i>Pre-and postoperative measurements of maximal mouth opening in different intraarticular treatment groups (Vingender et al., 2018; Vingender et al., 2023)</i> .....	39
<b>Figure 7.</b> <i>MMO percentage changes at 6- and 12-month follow-ups compared to the preoperative values in different treatment groups (Vingender et al., 2018; Vingender et al., 2023)</i> .....	40
<b>Figure 8.</b> <i>Pre-and postoperative measurements of maximal mouth opening in different molecular weight HA treatment groups (Vingender et al., 2018; Vingender et al., 2023)</i> .....	41
<b>Figure 9.</b> <i>Changes in MMO in percentage in different forms of hyaluronic acid treatment groups during the 6- and 12-month follow-ups (Vingender et al., 2018; Vingender et al., 2023)</i> .....	42
<b>Figure 10.</b> <i>Average preoperative VAS values in different treatment groups (Vingender et al., 2018; Vingender et al., 2023)</i> .....	43
<b>Figure 11.</b> <i>Pre-and postoperative measurements of VAS in different intraarticular treatment groups (Vingender et al., 2018; Vingender et al., 2023)</i> .....	44
<b>Figure 12.</b> <i>Changes of VAS in percentage at 6- and 12-month follow-up compared to the preoperative values in different treatment groups (Vingender et al., 2018; Vingender et al., 2023)</i> .....	45
<b>Figure 13.</b> <i>Changes in VAS values in low and high-molecular-weight HA treatment groups at the preoperative, first, and second checkups (Vingender et al., 2018; Vingender et al., 2023)</i> .....	46

<b>Figure 14.</b> <i>Changes of VAS in percentage in low and high-molecular-weight HA treatment groups at the first and second checkups (Vingender et al., 2018; Vingender et al., 2023)</i> .....	47
<b>Figure 15.</b> <i>Changes in VAS 1 week after each injection of consecutive HA treatment (Vingender et al., 2018; Vingender et al., 2023)</i> .....	48
<b>Table 1.</b> <i>Classification of RDC/TMD, Axis I. (Dworkin &amp; LeResche, 1992)</i> .....	9
<b>Table 2.</b> <i>Classification scheme of temporomandibular diseases (ESZK, 2020)</i> .....	10
<b>Table 3.</b> <i>Fonseca questionnaire (Fonseca et al., 1994)</i> .....	15
<b>Table 4.</b> <i>Distribution of the cases within different treatment groups according to Fonseca's grading system (Vingender et al., 2018; Vingender et al., 2023)</i> .....	37
<b>Table 5.</b> <i>P value table for comparison of 6-month and 12-month results of HA, PRP, and I-PRF in relation to the MMO and VAS (Vingender et al., 2018; Vingender et al., 2023)</i> .....	49