


Factors influencing the intra-abdominal adhesions formation: consequences and the possibility of prevention

The research of adhesion formation in experimental animal models

PhD Thesis

Györgyi Szabó

Semmelweis University
Basic Medicine PhD School



Supervisor: Dr. György Wéber, university professor, Ph.D.
Official reviewers: Dr. Éva Toronyi Éva, associate professor, Ph.D.
Dr. Gábor Jancsó, associate professor, Ph.D.
President of the Final Examination Committee:
Dr. Ferenc Perner, professor emeritus,
member of MTA
Members of the Final Examination Committee:
Dr. Piroska Anderlik, professor emerita, Ph.D.
Dr. János Lantos, associate professor, Ph.D.

Budapest
2014

Introduction

The recognition of the unfavourable patho-physiologic effects of intra-abdominal adhesions had been discovered in the early history of medicine. Intra-abdominal adhesions remain to be one of the most important clinical problem following abdominal surgery, causing pain, infertility, mobility and motility disturbances. Intra-abdominal adhesions can affect the quality of life, and enhance the degree of morbidity and mortality of the patient, consequently a great importance should be focused to inhibit it's formation. Surgical intervention e.g. adhesiolysis, to solve the problem essentially leads to the formation of more adhesions.

The main reason for adhesion formation is the surgical intervention, but it can be caused due to inflammation, intra-peritoneal infection, abdominal trauma or the so-called „charitable adhesion”, as a result of the defensive mechanism of body organs.

The formation of the adhesion is a consequence of the changes occuring in the peritoneal wound healing process, which involves the growth and differentiation of

cells appearing in the adhesion, the deposition of the extracellular matrix (ECM) and angiogenesis. Adhesion formation is estimated to reach a rate of 95%, depending on the extent of the surgical intervention, the intra- and postoperative complications and the intra-peritoneally implanted and used foreign materials.

Following the injury of the peritoneum, instantly a reaction of blood coagulation and vascular vessel vasoconstriction takes place. This is followed by vasodilatation resulting in emergence and invasion of the inflammatory cells to the injured area, promoting the formation of a fibrin matrix. Fibrin matrix forms to bind the injured surfaces, separate the injured tissue from the outer environment, thus protecting it from any microbiological agents. 2–3 days following the injury the activity and function of the fibrin matrix decreases, then it is terminated and disappears by fibrinolytic process, and the cicatrix heals without adhesion formation. If there are any disturbing circumstances the fibrinolytic process can be inhibited and the fibrin matrix stabilizes. Thus with time the composition of the adhesion changes, enhancing the development of vessels and nerves.

The activity and co-operation of three important systems play an important role in the process of adhesion formation: the inflammation, the coagulation and the fibrinolytic systems. They correlate with each other through their multiple cellular and molecular activities, to determine the fate of the fibrin matrix.

The plasmin-plasminogen activator inhibitor-1 system plays the main role in this process. Plasmin supports the fibrinolysis, while its indirect inhibitor, the plasminogen activator inhibitor-1 (PAI-1) supports adhesion formation. Under normal conditions, one of the specific properties of the PAI-1 molecule is the conformation to a latent form within 1-2 hours. For this reason it will not exert its inhibiting effect. In turn, vitronectin (VN) molecule, binding to PAI-1 molecule, supports its active form. This relationship had been investigated by many researchers under other pathophysiological circumstances eg. tumor and thrombosis, but it was never investigated in relation with adhesions.

Some researchers referred to the fact that in stabilized adhesions there are substance-P immuno-reactive axons. These nerves play an important role in the transmission

of pain, for this reason the pain experienced by patients may be due to adhesions. The presence of nerve fibres in stabilized adhesions is well known, but its presence in the early postoperative period was not yet investigated.

Aims

Our aim is to give a comprehensive review about the cellular and molecular processes of adhesion formation using animal models and animal experiments, with supporting data from the literature.

I. First experimental series: to examine the macroscopic and microscopic consequences of laparoscopic cholecystectomy (LC) and open cholecystectomy (OC) in experimental animals.

In this first experimental series we searched the answers for the following questions:

1. How does the minimally invasive laparoscopic technique effects the degree of adhesion formation following LC compared with the OC?
2. Is there a significant difference between LC and OC groups in the aspect of the various laboratory parameters?

3. Are there any histologic differences in the area of the gallbladder bed?

II. Second experimental series: our aim was to elaborate a suitable experimental adhesion model to determine the critical stages of adhesion formation in the early postoperative period (the first 7 days), with continues follow up and monitoring of the macroscopic, cellular and molecular events and changes.

In these experimental series we searched the answers for the following questions:

1. What are the main factors influencing the adhesion formation during the work up of the model?
2. When does the process of adhesion stabilization starts?
3. How can we determine the objective methodology to know the type, size and degree of stabilization of the formed adhesion?
4. How do the histological findings change in the early postoperative period?
5. Which cells are affected by apoptosis in this time interval?

6. Does PAI-1 and VN (molecules that play a main role in the process of adhesion formation) appear in the adhesive tissue?
7. Is there any relationship between the appearance of apoptosis and the appearance of PAI-1 and vitronectin?
8. Do the presence of inflammatory processes and foreign bodies influence the appearance of vitronectin and PAI-1 in the adhesive tissue?
9. When does the innervation of adhesion tissue begin?

Materials and Methods

First experiment: adhesion formation after LC and OC

20 mongrel dogs were used, weighing 20-25 kg. The animals were divided in two groups: in the first group OC was performed (n=10), and in the second group the surgical intervention was LC (n=10). For anaesthesia intramuscular Xylavet (0,05 mg/kg) and Ketamin (0,1 mg/kg) mixture was used.

In the HC group the operation was performed through median laparotomy. Following the operation a drain was

inserted under the gallbladder bed and it was fixed in the skin. In the LC group 15 mmHg pneumoperitoneum was created. Following the operation a drain was inserted under the gallbladder bed and fixed in as in the other group. The abdominal wall incision was closed by absorbable suture material, with simple interrupted suture line, and the skin with interrupted non-absorbable sutures.

Blood samples were taken in the 1st, 2nd, 5th, 7th, 10th and 14th postoperative (po.) day for hematological (anticoagulant: K₃-EDTA), and haemorheological (anticoagulant: Na-heparine) examination. In hemorheology Relative Cell Transit Time and Initial Relative Filtration Rate was determined. Immunologic examinations were also performed. Stimulation Index was counted by the activation of macrophages.

Peritoneal lavage was collected on the 1st, 5th, 7th és 14th po. day by re-laparoscopy. The lavage samples were centrifugated, smears were prepared and white blood cells were counted using Bürker chamber.

On the 14th po. day the animals were reoperated and tissue samples were taken from the adhesion sites –

gallbladder bed, trocar sites - for Hematoxilin-Eosin staining.

Second experiment:

In this project a a.) peliminary study and a b.) research study was performed.

a.) 1. table. The surgical interventions in adhesion models.

| Materials and methods performed during laparotomy | Numer of cases |
|--|-----------------------|
| Stitch in the parietal peritoneum with 2/0 Dagofil thread (B.Braun) | 3 |
| 1x1 cm Parietex Progrid mesh (Covidien) inserted in the parietal peritoneum without stitches | 2 |
| 1x1 cm-es Polipropilén mesh (Ethicon) sutured in the parietal peritoneum with 3/0-s Premilene (B.Braun) thread | 2 |
| one stitch in the liver with 3/0-s Premilene thread | 2 |
| ischemia was induced by two hemostatic clamps for 1 minute (n=1) and for 3 minutes (n=2) | 3 |
| the parietal peritoneum was injured with a scalpel in a 1x2 cm area | 2 |
| the parietal peritoneum was injured with a scalpel in 0.5x1 cm area | 2 |
| 5 small bleeding points were incised in the liver | 2 |

For the preliminary study 11 male rats were used weighing 350-450 g. The abdominal cavity was opened with a median laparotomy, and different surgical interventions were performed as described and summarized in table 1. Both of the sides of peritoneum were under surgical interventions through median laparotomy. The abdominal cavity was closed by Donati suture line.

Reoperation was performed on the 12th-14th po. day when the localization and extension of adhesion formation was determined.

b.) The next model was created without application of any foreign body performing invasive interventions. 90 male Wistar rats were used weighted 200-350 g. 16 animals consisted a control group and in 74 animals an adhesion model was created. Ketamin/Xylazine (4:1) anesthesia was used intraperitoneally.

In the control animals a 4 cm long median laparotomy was performed and the abdominal cavity was instantly closed in two layers.

In the adhesion model animals a 4 cm long median laparotomy was performed and a 1x2 cm area in the

surface of the right side parietal peritoneum was excised. The serosal surface of coecum was incised 4 times, and every incision was 2 cm long. The aim was to cause slight bleeding which promotes the adhesion formation. The injured surfaces were desiccated under lamp light for 10 minutes. During this period the coecum was placed exteriorized out from the abdominal cavity and the injured parietal peritoneum was isolated taken apart away from the abdominal organs. Following this period the coecum was replaced into the abdominal cavity. The injured surfaces were placed together. The abdominal wall was then closed in two layers. The surgical intervention was carried out in the same in all animals, and only the surviving time differed, between 1 to 7 days. (2nd table)

Following the given period all the animal were re-operated. The abdominal cavity was opened through median laparotomy.

The localization and the extension of adhesion was determined. *The type of the adhesion was defined to be columnar, curtain-like or large surface cohesive.*

2. table. The number of the animals in each research

| po. days | numbers of operated animals | numbers of control animals |
|----------|-----------------------------|----------------------------|
| 1 | 10 | 2 |
| 1,5 | 7 | 2 |
| 2 | 9 | 2 |
| 2,5 | 7 | 2 |
| 3 | 10 | 2 |
| 4 | 12 | 2 |
| 5 | 9 | 2 |
| 7 | 10 | 2 |

group.

The types of the adhesion was determined by the extension of the adhered surfaces. The adhesion is considered to be *columnar* when the

extension between the tissues is equal or less than 0.5 cm in length and width. *Curtain-like* adhesion looks like a curtain where the adhered surface is longer (more than 0.5 cm), but the width is equal to or less than 0.5 cm. *Large surface cohesive* adhesion's dimensions are more than 0.5 cm in all directions. ***The stability of the adhesion*** was determined by our own score system. 3 degrees were identified: instable, moderate stable, stable. *Instable* category means that the adhered surfaces can be separated easily during the sample taking procedure

without any traction. The adhesion is *moderately stable* when the adhered surfaces remain together during the reoperation and sample taking procedure, but they can be separated easily by a moderate traction without heavy bleeding. *Stable* adhesion surfaces cannot be separated by any strong traction. The only way to remove them from each other is a sharp incision which can cause serious bleeding. Tissue samples were taken for following-up of the cellular events (Hematoxilin-Eosin-, Bielschowsky- and Nissl-staining), for the detection of apoptosis, (ApopTag Peroxidase In Situ Kit (ApopTag® Peroxidase In Situ Apoptosis Detection Kit S7100, Millipore)) and for immunohistochemical examination. Our aim was to detect the presence of PAI-1 and vitronectin in the adhesion tissue. In 30 animals vitronectin was detected by rabbit monoclonal antibody (Vitronectin rabbit monoclonal antibody: AJ1817b, Abgent), and PAI-1 was detected by rabbit polyclonal antibody (PAI-1 (H-135): sc-8979, Santa Cruz). PolyScan HRP Label was used for marking. In 37 animals another rabbit monoclonal antibody was used

(Acris, NB110-57650), PAI-1 was detected by rabbit polyclonal antibody (Acris, AP20625PU-N).

Results

First experiment: adhesion formation after LC and OC

Following LC intervention either there was no adhesion formation or the formed adhesion was located in the gallbladder bed. The extension of the adhered surface only in one case exceeded 1 cm². The other values were between 0-0.6 cm². The average adhesion surface was 0.5 cm². HC caused adhesion formation in every animal. Most of the cases the adhesion was curtain-like especially between the peritoneum and liver or bowel.

The surface of adhesion in most of the cases was more than 1 cm² but in some animals this was 6-8-10 cm².

The number of white blood cells in HC group elevated over 17 G/l. On the 10th po. day statistical difference can be seen between the groups, p=0.034. There was no any statistical difference in other hematological parameters. There was no statistical differences in hemorheological parameters except in some individual cases. Stimulation Index showed great difference on the 14th po. day

between the groups but the number of the cases was not enough for statistical evaluation.

| | foreign body gran. | inflammation including the following cells: | | | sidero. | fibropl. |
|-----------|--------------------------|--|----------|--------|---------|----------|
| | | macro. histio. | granulo. | giant. | | |
| LC | 2/6 | 3/6 | 2/6 | 2/6 | 2/6 | 4/6 |
| HC | 8/9 | 8/9 | 4/9 | 2/9 | 5/9 | 8/9 |

3. table. Cellular differences between HC and LC groups.
(number of cases/all animals in the group)

Abbreviations: gran. = granuloma makro. = macrophage, histio. = histiocyte, granulo. = granulocyte, giant. = giant cells, sidero. = siderophage, fibropl. = fibroplasia

The most important histological findings can be seen in the table 3.

2.a.) *The results of the preliminary adhesion model can be seen in the table 4.*

| Surgical intervention | Type of adhesion |
|--|---|
| Stitch in the parietal peritoneum with 2/0 Dagrofil thread | columnar adhesion to the stitch (n=1) |
| 1x1 cm Parietex Progrid mesh inserted in the parietal peritoneum without stitches | courtain-like adhesion which involves the omentum, the liver and the small bowel (n=1), the mesh shifted between the bowels (n=1) |
| 1x1 cm-es Polipropilén mesh fixed to the parietal peritoneum and fixed by 3/0-s Premilene thread | the omentum covered the mesh, curtain-like adhesion formed (n=2) |

| Surgical intervention | Type of adhesion |
|--|--|
| one stitch in the liver with 3/0-s Premilene thread | columnar adhesion between the omentum and thread (n=2) |
| peritoneum ischemia induced by two hemsotatic clamps for 1 min. (n=1) and for 3 min. (n=2) | columnar adhesion between the liver and the peritoneum (n=1) |
| the parietal peritoneum was injured with a scalpel in 1x2 cm area | columnar adhesion (n=1) |
| the parietal peritoneum was injured with a scalpel in 0.5x1 cm area | - |
| 5 tiny bleeding was established int he liver surface | - |

4. table. Adhesion formation in the preliminary adhesion models

2.b.) Adhesion model caused by tissue injury

The first figure shows the types of adhesion in different postoperative days. The large-surface cohesive adhesion was detected in 39.7% of all the adhesions. The adhered surface was 2 cm² in most of the animals. The most largest extension was 3.75 cm².

Stabilized adhesion appeared on the 3rd po. days and the number and proportion increased in comparison with the other two categories. By the 7th po. day all of the adhesions became stabile.

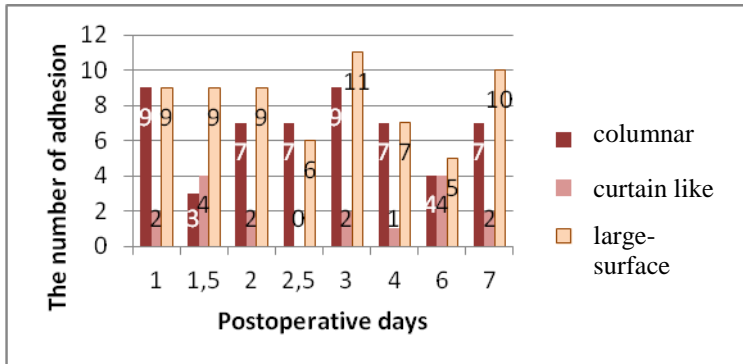


Fig. 1. The types of adhesion.

Histological examination: In the early po. period we could observe the disappearance of the damaged muscle fibres and the invading neutrophil granulocytes. From the 3rd po. days active fibroblast and endothelial cells appeared instead of the inflammatory processes. In histological study we could observe the ‘unifying’ process of the tissues. In stabilized adhesion the original borders of the tissues could not be detected. In the adhesion tissue stabilized connective tissue, new vessels and nerve fibers appeared.

Apoptosis can be detected in the ruined muscle fibers in the early period, later in fibroblasts and endothelial cells.

VN could be seen between the muscle fibers in the early po. period, later these molecules are observed in the

superficial connective tissue, especially in the adhesion tissue or in the surrounding area. In our examination period there we found inflammatory areas and foreign bodies where VN could be detected.

PAI-1 could be observed in the superficial connective tissue either in mesothelial cells or in fibroblasts. PAI-1 often appeared like a thin layer on the surface of peritoneum. PAI-1 could be not detected neither around the vessels nor in the inflammatory region.

The most important new findings is my research

1. We have established our own new system for the evaluation of the form and size of the adhesions, which classifies them to three categories in a range of measurement by mm. Thus with the combined use of the two properties of the adhesion type (form and size), an easy and fast objective evaluation could be achieved.

2. International literature data provides that the degradation of the fibrin matrix occurs in the 48th postoperative hour, but there is no any references for the time of beginning, duration of the process and the timing of finishing of the stabilization. In our experiments we

found a new novelty for the timing of the stabilization of adhesion, which is defined to be between the 2,5 – 5th po. day.

3. By all means, the adhesion is stabilized by the 7th postoperative day and histologically forms a unified tissue, and any maneuver of adhesiolysis by sharp dissection will lead to tissue injuring and bleeding, which consists a background for more new adhesion formation. Researches should concentrate to give targeted anti-adhesive agents instead of surgical adhesiolysis.

4. According to our findings, the nerve fibers appear in the adhesive tissue in the 7th postoperative day. We did not find any traces of nerves in the specimens extracted before the 7th postoperative day. According to data in the literature, it is found that in many cases they studied the presence of nerve innervations and sensory neuron molecules in the chronic adhesive tissues, We did not find any data in the postoperative period regarding the day to day follow up of the process of innervation, as we did.

5. We first stated that VN is present in a large number in the adhesive tissue from the 3-4 postoperative day,

between the adhesion surfaces. PAI-1 was also detected in those adhesion tissues. So many data in the international literature is dealing with the joint occurrence and linkage of VN and PAI-1 in tumour tissue and process of thrombosis, but no any data refers to the fact that there are researches which had been performed to search for the role of VN in adhesion formation, and no any traces for investigations are done in case of their linkage in the adhesive tissue. We are the first who searched for their occurrence in the adhesive tissue and proved their occurrence.

6. Supported by the literature data we found that vitronectin is present in the inflammatory areas and in the surroundings of the foreign bodies, which can be in relation with it's effect to the migration with cell migration. Also the activation of the complement system induces the upregulation of VN.

7. According to the international literature these two molecules protect the cells from apoptosis. Our histology results also confirm that neither VN, nor PAI-1 are present in the adhesion area, where the apoptosis is taking place.

Publications related to my PhD thesis

1. **Szabó Gy**, Gamal EM, Sándor J, Ferencz A, Lévay B, Csukás D, Dankó T, Wéber Gy. (2013) Az adhaesioképződés mechanizmusa és modellezésének lehetőségei. Előkísérleti modellek. *Magy Seb*, 66: 263-269.
2. **Szabó G**, Mikó I, Nagy P, Bráth E, Pető K, Furka I, Gamal EM. (2007) Adhesion formation with open versus laparoscopic cholecystectomy: an immunologic and histologic study. *Surg Endosc* 21: 253-257. **IF=2,242**
3. **Szabó Gy**, Mikó I, Pető K, Bráth E, Nagy P, Gamal EM. (2005) Laparoszkoópos versus nyitott cholecystectomy: válaszreakciók a májagyban. *Magy Seb* 58: 106-110.
4. Gamal EM, Metzger P, **Szabó Gy**, Bráth E, Pető K, Oláh A, Kiss J, Furka I, Mikó I. (2001) The influence of intraoperative complications on adhesion formation during laparoscopic and conventional cholecystectomy in an animal model. *Surg Endosc* 15: 873-877. **IF=2,374**

5. Gamal EM, Metzger P, **Szabó Gy**, Bráth E, Seli A, Ender F, Polányi Cs, Furka I, Mikó I. (2001) Az intraoperatív szövődmények hatása a posztoperatív hasúri adhesiók kialakulására laparoszkópos cholecystectomiát követően: összehasonlító állatkísérlet. *Magy Seb* 54: 180-184.

6. Gamal EM, Metzger P, Mikó I, **Szabó G**, Bráth E, Kiss J, Furka I. (1999) The Judgement of Adhesion Formation Following Laparoscopic and Conventional Cholecystectomy in an Animal Model. *Acta Chir Hung* 38: 169-172.

Other publications

1. Levay B, **Szabó Gy**, Szijarto A, Gamal EM. (2013) Epekövekben lévő baktériumok előfordulásának gyakorisága. *Magy Seb* 66: 353-356.
2. Sándor J, Haidegger T, Kormos K, Ferencz A, Csukás D, Bráth E, **Szabó G**, Wéber G. (2013) Robotsebészet. *Magy Seb* 66: 236-244.
3. Nedvig K, Wéber Gy, Sándor J, **Szabó Gy**, Csukás D, Reglődi D, Ferencz A. (2013) A PACAP-38 citoprotektív és antiinflammatoricus hatásának vizsgálata vékonybél-autotranszplantációs modellben. *Magy Seb* 66: 102.
4. Kormos K, Sándor J, Haidegger T, Ferencz A, Csukás D, Bráth E, **Szabó Gy**, Wéber G. (2013) Új lehetőségek a sebészet gyakorlati oktatásában. *Magy Seb* 66: 256-262.
5. Gamal EM, **Szabó Gy**, Metzger P, Furka I, Miko I, Peto K, Ferencz A, Sandor J, Szentkereszty Z, Sapi P, Weber G. (2013) A trokárak helyén kialakult hasfali sérvekről (Trocar Site Hernia) laparoscopos cholecystectomy után: incidencia és megelőzés - állatkísérletes tanulmány. *Magy Seb* 66: 270-273.

6. Agócs L, Lévay B, Kocsis Á, **Szabó Gy**, Gamal EM, Rojkó L, Sándor J, Wéber Gy. (2013) Aspergillus empyema kezelése nyitott thoracostomiával és izomplasztikával, a tüdő funkciójának megőrzésével – esetismertetés. *Magy Seb* 66: 274-276.

7. Gamal EM, **Szabó Gy**, Szokoly M, Janecskó M, Wéber Gy. (2013) Az egynapos sebészet múltja, jelene és jövője. *Orvostovábbk Szle* 20: 11-19.

8. Gyertyán I, Kiss B, Sággy K, Laszy J, **Szabó Gy**, Szabados T, Gémesi L, Pásztor G, Zájér-Balázs M, Kapás M, Ágai Csongor É, Domány Gy, Tihanyi K, Szombathelyi Zs. (2011) Cariprazine (RGH-188), a potent D3/D2 dopamine receptor partial agonist, binds to dopamine D3 receptors in vivo and shows antipsychotic-like and procognitive effects in rodents. *Neurochem Int* 59: pp. 925-935. **IF=2,857**

9. Miko I, Nemeth N, Sajtos E, Brath E, Peto K, Furka A, **Szabó Gy**, Kiss F, Imre S, Furka I. (2010) Splenic function and red blood cell deformability: The beneficial effects of spleen autotransplantation in animal experiments. *Clin Hemorheol Micro* 45: 281-288.

IF=2,838

10. Németh N, Lesznyák T, Szokoly M, Bráth E, Pető K, **Szabó Gy**, Gulyás A, Kiss F, Imre S, Furka I, Mikó I. (2005) A haemorheológiai vizsgálatok jelentősége kísérletes végtagi ischaemia-reperfúziós károsodások kapcsán [The importance of hemorheological examinations in experimental limb ischemia-reperfusion injuries]. *Magy Seb* 58: 144-147.

11. Gamal E M, **Szabó Gy**, Nagy P, Bráth E, Pető K, Oláh A, Tamás R, Kovács A, Mikó I. (2005) A peritoneum és a „kémény effektus” szerepe a port site metastasis kialakulásában. Furka féle lép suspensióval végzett új állatkísérletes modell. *Magy Seb* 58: 89-92.

12. Pap M, **Szabó Gy**, Göncziné Szabó T. Bőrredővastagság variációi és a testösszetétel. In: Pap M. (szerk), *Humánökológia és humánbiológia*. Kossuth Egyetemi Kiadó, Debrecen, 1998: 125-136.

13. Pap M, **Szabó Gy**, Göncziné Szabó T: A gyermekek metrikus jellegvariációi a Bódva-völgyi populációkban. In: Pap M. (szerk), *Humánökológia és humánbiológia*. Kossuth Egyetemi Kiadó, Debrecen, 1998: 93-123.

14. Pap M, **Szabó Gy**: A Bódva-völgy mikrorégió humánökológiai, népességdinamikai, szociodemográfiai sajátosságai. In: Pap M. (szerk) Humánökológia és humánbiológia. Kossuth Egyetemi Kiadó, Debrecen, 1998: 71-92.

15. **Szabó Gy**, Pap M. (1997) Physical development and obesity in children in the Bódva valley. Acta Biol Szeged 42: 307-314.

16. Pap M, **Szabó Gy**, Gönczi-Szabó T. (1997) Trait variations in children as indicators. Preliminary data of a research project. Acta Biol Szeged 42: 271-278.

17. **Szabó Gy**, Püspöki Z. (1996) A geobotanika elméleti alapjai és gyakorlati alkalmazhatósága. Calandrella 10: 161-174.