

Asymptomatic free-floating thrombus of the internal carotid artery

CSABA CSOBAY-NOVÁK¹, ZSUZSANNA JÁRÁNYI¹, EDIT DÓSA^{1*}, KÁLMÁN HÜTTL²

¹Department of Vascular Surgery, Faculty of Medicine, Semmelweis University, Budapest, Hungary

²Heart Center, Faculty of Medicine, Semmelweis University, Budapest, Hungary

*Corresponding author: Edit Dósa MD PhD; Városmajor u. 68, H-1122 Budapest, Hungary; Phone/Fax: +36-1-458-6880; E-mail: dosaedit@yahoo.com

(Received: June 16, 2011; Accepted after revision: August 22, 2011)

Abstract: Free-floating thrombus (FFT) of the internal carotid artery, which is almost always symptomatic and is usually discovered by ultrasound or angiography performed after a transient cerebrovascular event, is a highly uncommon diagnosis. Here, we report a case of an asymptomatic free-floating internal carotid artery thrombus most probably caused by an atherosclerotic plaque rupture. It was detected by carotid ultrasound and was treated with eversion endarterectomy without any neurologic complications. Six weeks after surgery, the patient is doing well.

Keywords: ultrasound, free-floating thrombus, plaque rupture, carotid artery, endarterectomy, stroke

Introduction

Free-floating thrombus (FFT) is usually seen either in the right atrium/ventricle or in the pulmonary vessels [1, 2]. FFT of the major arteries of the systemic circulation – especially of the internal carotid artery – is a very uncommon diagnosis. Although, the exact etiology of FFT remains unknown, most cases are related to complicated atherosclerotic plaques [3]. Several other pathological conditions, such as traumatic vascular injury, dissection, aneurysm, hypercoagulability state, iron deficiency with thrombocytosis, and cocaine usage, have also been reported to be involved in its development [4–8]. Symptoms are present in almost every case and can be either the consequence of preexisting stenosis worsened by the presence of FFT (transient vision loss, one side extremity weakness, and aphasia) or distal embolization of the thrombus (cerebral infarction) [5]. The treatment of free-floating internal carotid artery thrombus is controversial, mostly based on expert opinions, and can be conservative management alone (anticoagulation and/or antiplatelet therapy), surgery (carotid endarterectomy), or carotid stenting [3, 5]. However, it should be mentioned that FFT can also be developed on a residual carotid intimal flap after carotid endarterectomy and stent implantation may further increase the risk of distal embolization due to the endovascular manipulation [3, 9].

Here, we present a case of an asymptomatic free-floating internal carotid artery thrombus, which was discovered by ultrasound and was treated successfully with eversion endarterectomy. Six weeks after surgery, the patient is doing well without any neurologic deficits.

Case Report

An 83-year-old male patient's past medical history consisted of hypertension, hyperlipidemia, and acute myocardial infarction. The patient underwent percutaneous coronary intervention in 2005. He visited his cardiologist for a regular medical check-up in February 2011. A systolic bruit was heard in the left carotid region of the neurologically asymptomatic patient, and hence a carotid duplex scan was performed, which revealed a circular heteroechoic plaque at the origin of the internal carotid artery. The degree of stenosis was ~50% (the maximum peak systolic velocity was 150 cm/s while the maximum end-diastolic velocity was 65 cm/s at the site of plaque). In addition, a small FFT was noted on the surface of the plaque (*Fig. 1*). The size of the FFT was 6×4×4 mm. Examination of the contralateral carotid artery revealed no wall abnormalities; the hemodynamic parameters were within normal limits. The patient had no previous history of thrombophilia, nor did laboratory findings show any signs of hypercoagulability state. Urgent surgical intervention was advised to the patient, because the thrombus was considered highly embologenic. However, he refused hospitalization; therefore, as a fall-back option, 2×0.4 mL of subcutaneous enoxaparin was added to his medication, and the patient was dismissed. Three days later, the patient showed up again, still without any symptoms, and gave his informed consent to the procedure. On the next day, eversion endarterectomy was performed. The ultrasound findings were verified at operation. Plaque rupture was hypothesized to be the cause of FFT, but no pathological examination was per-

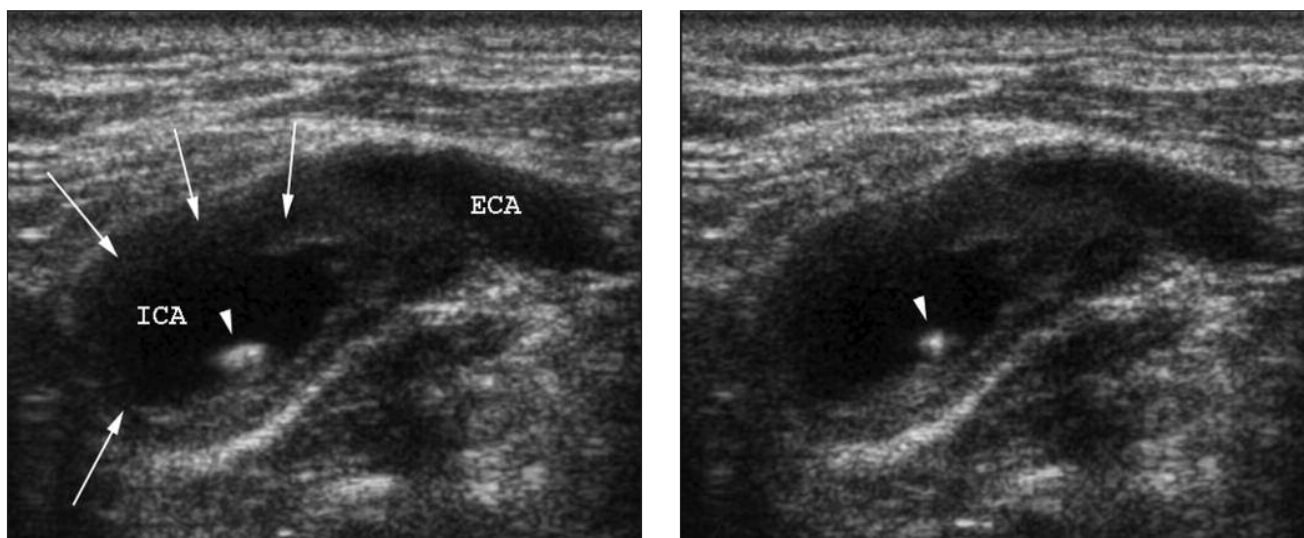


Fig. 1. Cross-sectional ultrasound images of the left internal carotid artery. The images captured in different phases show the circular heteroechoic plaque (arrows) and the mobility of the echogenic thrombus attached to the surface of the plaque (arrowhead). (Abbreviations: ICA=internal carotid artery; ECA=external carotid artery)

formed to reveal the exact cause of the surgically removed thrombus. Double antiplatelet therapy was started, and the patient was discharged in a good overall condition on the fourth postoperative day. Six weeks after surgery, the carotid duplex scan showed minimal irregularity of the operated vessel wall and normal hemodynamic parameters.

Discussion

FFT is usually found in the right atrium/ventricle or in the pulmonary trunk/arteries, and it is only rarely seen in the systemic circulation. FFT of the internal carotid artery is mainly discovered by digital subtraction or CT angiography in patients with a history of transient cerebral ischemic event.

In most of the published papers, a strong association was noted between the presence of unstable carotid plaques and FFT; however, approximately one-third of the cases happen without preexisting atherosclerotic lesions [5]. The most common non-atherosclerotic causes of FFT formation are traumatic vascular injury [6], dissection, aneurysm [8], hypercoagulability state [5], iron deficiency with thrombocytosis [4], and cocaine usage [7]. The pathophysiology of plaque rupture has been thoroughly investigated, because it plays an important role in the development of acute myocardial infarction. It can be spontaneous and stress evoked, latter being either psychological or physical. Plaque rupture can also be triggered by electric cardioversion [10]. Since the ruptured plaque acts as a highly thrombogenic surface, platelet aggregation and thrombus formation are immediately activated at its location. Traumatic injuries of the neck can also cause small intimal tears, which may lead to throm-

bus formation. Dissections and aneurysms are also known to provide a thrombogenic surface. The exact pathomechanism of other non-atherosclerotic factors of FFT is much less clear.

The reported incidence of carotid FFT varies from one author to another. This can be due to the fact that the definition of FFT is different in each study. In three retrospective studies based on the analysis of carotid angiograms, the incidence of FFT was 0.4% (9/2250), 0.7% (7/1000), and 0.62% (16/2572), respectively [11–13]. Similarly, Arning and Herrmann and Lane et al. retrospectively evaluated carotid duplex scans and found an FFT incidence of 0.05% (1/2000) and 0.12% (6/5000), respectively [14, 15].

On the basis of a review of previous case reports dealing with FFT in the carotids, Bhatti et al. revealed that only 4% of the patients were asymptomatic [5]. Symptoms can be due to a preexisting stenosis worsened by the presence of thrombus (sudden transient vision loss, one side extremity weakness, and aphasia) or can be the consequence of distal embolization (infarction of the brain supplied by the ipsilateral anterior and middle cerebral artery) [5].

There are several treatment options in the management of patients with FFT. The most conservative method is medical treatment alone: anticoagulation, anticoagulation plus antiplatelet therapy, or antiplatelet therapy alone. The rate of complete dissolution of the FFT without any neurologic symptoms can be as high as 86% [5]. Carotid endarterectomy is usually the preferred invasive treatment option, whereas carotid stenting is seldom used. Surgery is recommended to be performed within a week of diagnosis; however, some of the surgeons put the patient on anticoagulation for at least 1 week prior to surgery.

Summary

FFT of the carotid artery is a rare pathological condition, usually requiring urgent surgical intervention. However, conservative treatment can also be considered, as its results are not proven to be inferior to the results of surgery. Here, we report a case of a free-floating internal carotid artery thrombus, most probably caused by an atherosclerotic plaque rupture, which was discovered incidentally in an asymptomatic patient and was treated by eversion endarterectomy. Six weeks after surgery, the patient is doing well without any neurologic symptoms.

References

1. Grzelakowski P, Lugowski T, Kurzyna M, Missima M, Maciejewski M, Balcerzak M, Romanek R, Stelak M, Lugowski A, Goch A: Acute intermediate-risk pulmonary embolism with right-sided free-floating intracardiac thrombus, systemic inflammatory reaction syndrome, multiple organ dysfunction syndrome, disseminated intravascular coagulation and acute ischaemia of a limb. *Kardiol Pol* 68, 1140–1144 (2010)
2. Hou X, Liu W, Zhang Z, Li Z: Free-floating right atrial thrombus with acute pulmonary embolism. *Thorax* 64, 736 (2009)
3. Parodi JC, Rubin BG, Azizzadeh A, Bartoli M, Sicard GA: Endovascular treatment of an internal carotid artery thrombus using reversal of flow: a case report. *J Vasc Surg* 41, 146–150 (2005)
4. Akins PT, Glenn S, Nemeth PM, Derdeyn CP: Carotid artery thrombus associated with severe iron-deficiency anemia and thrombocytosis. *Stroke* 27, 1002–1005 (1996)
5. Bhatti AF, Leon LR Jr, Labropoulos N, Rubinas TL, Rodriguez H, Kalman PG, Schneck M, Psalms SB, Biller J: Free-floating thrombus of the carotid artery: literature review and case reports. *J Vasc Surg* 45, 199–205 (2007)
6. Ferrero E, Gaggiano A, Ferri M, Nessi F: Mobile floating carotid plaque post-trauma. Diagnosis and treatment. *Interact Cardiovasc Thorac Surg* 8, 496–497 (2009)
7. Konzen JP, Levine SR, Garcia JH: Vasospasm and thrombus formation as possible mechanisms of stroke related to alkaloidal cocaine. *Stroke* 26, 1114–1118 (1995)
8. Spiegel M, Kopp H, Treese N.: Extensive aneurysm of the internal carotid artery with free floating round thrombus. *Vasa* 23, 367–369 (1994)
9. Ferrero E, Ferri M, Gaggiano A, Viazzo A, Piazza S, Cumbo P, Berardi G, Nessi F: Free floating thrombus developed on a residual carotid intimal flap after carotid endarterectomy. Diagnosis and treatment. *Ann Vasc Surg* 24, 573–574 (2010)
10. Becker D, Maurovich-Horváth P, Merkely B: Coronary plaque rupture triggered by electrical cardioversion. *Interv Med Appl Sci* 2, 186 (2010)
11. Biller J, Adams HP Jr, Boarini D, Godersky JC, Smoker WR, Kongable G: Intraluminal clot of the carotid artery. A clinical-angiographic correlation of nine patients and literature review. *Surg Neurol* 25, 467–477 (1986)
12. Roberson GH, Scott WR, Rosenbaum AE: Thrombi at the site of carotid stenosis. Radiographic diagnosis. *Radiology* 109, 353–356 (1973)
13. Ferrero E, Ferri M, Viazzo A, Labate C, Pecchio A, Berardi G, Piazza S, Cumbo P, Nessi F: Free-floating thrombus in the internal carotid artery: diagnosis and treatment of 16 cases in a single center. *Ann Vasc Surg* 25, 805–812 (2011)
14. Arning C, Herrmann HD: Floating thrombus in the internal carotid artery disclosed by B-mode ultrasonography. *J Neurol* 235, 425–427 (1988)
15. Lane TR, Shalhoub J, Perera R, Mehta A, Ellis MR, Sandison A, Davies AH, Franklin IJ: Diagnosis and surgical management of free-floating thrombus within the carotid artery. *Vasc Endovascular Surg* 44, 586–593 (2010)