

Foreign body impaction in the sigmoid colon: A twenty euro bet

Katalin E Müller, András Arató, Péter László Lakatos, Mária Papp, Gábor Veres

Katalin E Müller, András Arató, Gábor Veres, 1st Department of Pediatrics, Semmelweis University, 1083 Budapest, Hungary
Péter László Lakatos, 1st Department of Medicine, Semmelweis University, 1083 Budapest, Hungary

Mária Papp, 2nd Department of Medicine, University of Debrecen, 4032 Debrecen, Hungary

Author contributions: Müller KE collected data and prepared the manuscript; Arató A critically revised the manuscript; Lakatos PL interpreted clinical data and critically revised the manuscript; Papp M interpreted clinical data and revised the manuscript; Veres G collected data, supervised preparation of the manuscript and critically revised the manuscript.

Supported by János Bolyai Research Grant, to Veres G; A Hungarian Scientific Research Fund Grant, No. OTKA-K 105530

Correspondence to: Gábor Veres, MD, PhD, 1st Department of Paediatrics, Semmelweis University, 53 Bokay Street, 1083 Budapest, Hungary. vergab@gyer1.sote.hu

Telephone: +36-20-8258163 Fax: +36-1-3036077

Received: July 23, 2012 Revised: October 26, 2012

Accepted: November 14, 2012

Published online: June 28, 2013

Abstract

Foreign body ingestion is a common clinical problem in early childhood. However, it may occur even in adults, unknowingly. Most ingested foreign bodies entering the stomach pass through the gastrointestinal tract uneventfully. Here we report on a 13-year-old boy who presented with chronic abdominal pain, weight loss and occult gastrointestinal bleeding for 6 mo. Colonoscopy was negative; however, a ballpoint pen was impacted in the sigmoid region. Subsequently, the child admitted swallowing a pen as a 20-euro bet 6 mo previously. Crohn's disease is a chronic relapsing inflammatory gastrointestinal disease. It is often difficult to diagnose due to the fact that there is no single pathognomonic sign or symptom. This case is a description of an adolescent with chronic gastrointestinal symptoms due to a foreign body. Therefore, an ingested foreign body should be included in the differ-

ential diagnostic procedure related to gastrointestinal symptoms.

© 2013 Baishideng. All rights reserved.

Key words: Foreign bodies; Pen; Differential diagnosis; Crohn's disease; Child

Müller KE, Arató A, Lakatos PL, Papp M, Veres G. Foreign body impaction in the sigmoid colon: A twenty euro bet. *World J Gastroenterol* 2013; 19(24): 3892-3894 Available from: URL: <http://www.wjgnet.com/1007-9327/full/v19/i24/3892.htm> DOI: <http://dx.doi.org/10.3748/wjg.v19.i24.3892>

INTRODUCTION

Foreign body ingestion is a common problem in everyday emergency practice, primarily in children. Fortunately, the majority of the ingested foreign objects pass through the gastrointestinal tract without complications. Foreign body ingestion may present without symptoms^[1], and in some cases results in perforation with gastrointestinal bleeding or an obstruction^[1]. Rarely, an abscess or a fistula occurs^[1]. It has been reported to mimic other diseases (renal stone or irritable bowel syndrome)^[1]; however, there are no literature data concerning differential diagnostic difficulties of Crohn's disease (CD) and a foreign body.

CD is a chronic relapsing inflammatory gastrointestinal disease. It is often difficult to diagnose due to the fact that there is no single pathognomonic sign or symptom. Here we report on a case with chronic abdominal symptoms, weight loss and occult bleeding suggesting CD. However, at colonoscopy, a swallowed pen was impacted in the sigmoid region causing the aforementioned symptoms.

CASE REPORT

A 13-year-old boy was admitted to the First Depart-

ment of Paediatrics at Semmelweis University with 10-kg weight loss in the last 6 mo and intermittent colicky abdominal pain. Past medical history revealed that 6 mo previously he was admitted to hospital for 2 d due to acute abdominal pain and vomiting. He was given intravenous fluids and his complaints improved. However, anorexia persisted, abdominal pain returned intermittently, and he lost 10 kg during this period. Stool blood test was positive twice, while stool culture, parasite and assays for *Clostridium difficile* toxins A and B were all negative. Considering the age of the patient, weight loss, chronic abdominal pain and positive stool blood test, as well as negative stool culture, inflammatory bowel disease was suspected and he was referred to our clinic.

Physical examination revealed normal vital signs without any clinical abnormalities. His abdomen was soft, non-tender, without guarding or palpable masses. There was normal sphincter tone, no perianal abscess, skin tag or fistula at rectal examination. Laboratory tests showed normal red blood cell count, white blood cell count and thrombocyte count. C-reactive protein, total protein and albumin were within the normal limits. Abdominal ultrasound showed slight wall thickening in the descending colon. There was no family history of inflammatory bowel disease.

The upper endoscopy was negative. There were no ulcers, no sign of bleeding, and no antral or bulbar lymphonodular hyperplasia. The terminal ileum and the colon appeared normal, confirmed by multiple mucosal biopsies at histology. Surprisingly, at withdrawal of the colonoscope, an impacted foreign body (plastic half-ball pen, Figure 1) was observed embedded in the sigmoid region. The surrounding mucosa was inflamed, with no visible mucosal vessels. The plastic, numbered ballpoint pen could not be removed by Dormia set and polypectomy snare despite several attempts. After the diagnostic procedures, the patient admitted swallowing a half-plastic pen as a 20-euro bet with his friend 6 mo ago. At first, he thought there might have been a connection between the swallowed pen and his symptoms as he had a hospital admission for 2 d due to acute abdominal pain and vomiting (see above). Later, he was embarrassed and hoped that these two events were just a coincidence. He never disclosed his bet.

Plain abdominal X-ray and abdominal ultrasound were performed the next day after endoscopy, but the foreign body could not be visualized. The pen passed through the colon spontaneously hence the control colonoscopy showed no foreign body after 5 d. The patient had no symptoms during 21 mo of follow-up; his weight gain is normal, and there is no occult bleeding.

DISCUSSION

We report on a case of an ingested foreign body as a twenty-euro bet. To our knowledge, this is the first description of a swallowed object causing chronic gastrointestinal symptoms in a paediatric patient. However,

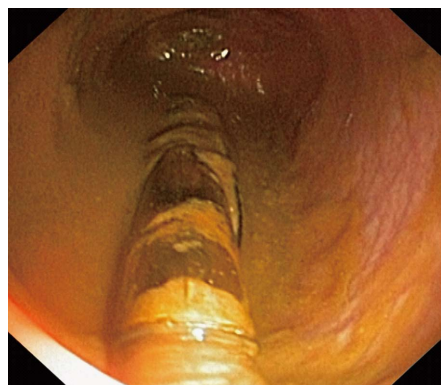


Figure 1 Half-plastic pen impacted in the sigmoid region.

ingested foreign bodies are a common event in the paediatric population.

The first recorded paediatric foreign body ingestion was described by Frederick the Great in 1692^[2]. Most accidentally ingested foreign bodies go undetected and pass through without any incident. However, 10%-20% require endoscopic removal and 1% or less require surgical intervention^[3]. In general, the passing of an ingested foreign body depends on the anatomic conditions of the gastrointestinal tract and on factors related to the ingested foreign body. Long, thin objects as seen in our case are less likely to pass the pylorus or the duodenum^[2]. The presenting features vary according to the site and include pancreatitis, hepatic abscess, appendicitis, intussusceptions and irritable bowel syndrome^[1,2].

There are only a few reports of foreign bodies imitating CD in the English literature. Ioannidis *et al*^[4] reported on a case of incidental toothpick ingestion which caused an ileum fistula and mimicked CD. In addition, a patient presented with recurrent, subacute obstruction and right iliac mass mimicking the presentation of CD^[5]. Subsequent lower endoscopy revealed small bowel phytobezoar which passed spontaneously.

To our knowledge, only one paediatric case of an ingested foreign body mimicking CD has been reported^[6]; nevertheless, this was an acute event. A 7-year-old boy presented with a 2-wk history of cramping abdominal pain and low grade fever. Colonoscopy revealed an oedematous, friable rectosigmoid junction with a solitary fistula or ulcer. Hydrocortisone enemas were prescribed with minimal improvement. Seven days later his condition became more serious, and a computed tomography scan revealed a right iliopsoas abscess. Repeated colonoscopy showed a toothpick in the lumen of the rectosigmoid colon.

Foreign bodies usually cause acute symptoms of perforation, obstruction or gastrointestinal bleeding. However, our patient had chronic symptoms. This is probably due to the lack of perforation or obstruction. Meanwhile, his symptoms were similar to the reported cases, in which perforation or fistula was diagnosed.

We were presented with a healthy, young adolescent with chronic abdominal pain, weight loss and occult bleeding - classic presenting features of paediatric inflam-

matory bowel disease. Our working hypothesis was CD, though the laboratory tests were negative. Colonoscopy revealed a plastic, half-ball pen embedded in the sigmoid mucosa. The patient concealed swallowing a half-pen as a 20-euro bet with his friend. His subsequent hospital admission due to vomiting and acute abdominal symptoms may be explained as due to gastric irritation. Later the foreign body passed through the upper gastrointestinal tract and impacted in the sigmoid region. We speculate that occult bleeding was caused by the chronic mucosal irritation around the embedded pen. Anorexia and abdominal pain can be explained by the increased bowel peristalsis around the logged pen^[7].

The value of imaging studies for an ingested foreign body seems to be questionable based on our case. Hence, plain abdominal X-ray (plastic pen) and abdominal ultrasound (sigmoid localization) could not identify the pen. Nevertheless, the role of imaging studies is crucial to determine the inflammatory reaction in and around the bowel wall and to exclude findings requiring surgical intervention^[7].

The majority of ingested foreign bodies that reach the stomach pass through the alimentary tract without complication. If not, the management of ingested foreign bodies is dependent on their size, shape, material and location. After imaging studies, endoscopy should be considered as the crucial step in management since it is a potent and safe diagnostic tool. On the other hand, surgical treatment is mandatory in the presence of complications such as abscesses and fistulas^[7]. In our patient, we attempted the removal of the embedded pen, but due to the increased possibility of perforation, we did not prevail. Subsequently, the pen was spontaneously passed after the first endoscopy as a result of the previous attempts of removal.

In summary, we report on an adolescent patient with

chronic gastrointestinal symptoms due to a swallowed plastic pen that mimicked CD. Therefore, an ingested foreign body should be included in the differential diagnostic procedure related to chronic gastrointestinal symptoms.

ACKNOWLEDGMENTS

We thank Alexandra Horvath for her language editing.

REFERENCES

- 1 **Komninos ID**, Tsiligianni IG. Foreign body ingestion mimicking irritable bowel syndrome: a case report. *J Med Case Rep* 2010; **4**: 244 [PMID: 20684775 DOI: 10.1186/1752-1947-4-244]
- 2 **Antao B**, Foxall G, Guzik I, Vaughan R, Roberts JP. Foreign body ingestion causing gastric and diaphragmatic perforation in a child. *Pediatr Surg Int* 2005; **21**: 326-328 [PMID: 15645252]
- 3 **Eisen GM**, Baron TH, Dominitz JA, Faigel DO, Goldstein JL, Johanson JF, Mallory JS, Raddawi HM, Vargo JJ, Waring JP, Fanelli RD, Wheeler-Harborough J. Guideline for the management of ingested foreign bodies. *Gastrointest Endosc* 2002; **55**: 802-806 [PMID: 12024131 DOI: 10.1016/S0016-5107(02)70407-0]
- 4 **Ioannidis O**, Kakoutis E, Sakkas L, Konstantara A, Chatzopoulos S, Kotronis A, Makrantonakis N. Ingested toothpick fistula of the ileum mimicking Crohn's disease. *Acta Gastroenterol Belg* 2010; **73**: 527-529 [PMID: 21299167]
- 5 **Prior A**, Martin DF, Whorwell PJ. Small bowel phytobezoar mimicking presentation of Crohn's disease. *Dig Dis Sci* 1990; **35**: 1431-1435 [PMID: 2226106 DOI: 10.1007/BF01536753]
- 6 **O'Gorman MA**, Boyer RS, Jackson WD. Toothpick foreign body perforation and migration mimicking Crohn's disease in a child. *J Pediatr Gastroenterol Nutr* 1996; **23**: 628-630 [PMID: 8985858 DOI: 10.1007/BF0153675]
- 7 **Zeos P**, Oikonomou A, Souftas V, Gkotsis D, Pitiakoudis M, Kouklakis G. Endoscopic removal of a toothpick perforating the sigmoid colon and causing chronic abdominal pain: a case report. *Cases J* 2009; **2**: 8469 [PMID: 19918434 DOI: 10.4076/1757-1626-2-8469]

P- Reviewer Devanarayana NM **S- Editor** Gou SX
L- Editor Logan S **E- Editor** Li JY

